

# Face Mask Ventilation in Edentulous Patients

## *A Comparison of Mandibular Groove and Lower Lip Placement*

Stéphane X. Racine, M.D., Ph.D.,\* Audrey Solis, M.S.,† Nora Ait Hamou, M.S.,† Philippe Letoumelin, M.D.,‡ David L. Hepner, M.D.,§ Sadek Beloucif, M.D., Ph.D.,|| Christophe Baillard, M.D., Ph.D.||

### ABSTRACT

**Background:** In edentulous patients, it may be difficult to perform face mask ventilation because of inadequate seal with air leaks. Our aim was to ascertain whether the “lower lip” face mask placement, as a new face mask ventilation method, is more effective at reducing air leaks than the standard face mask placement.

**Methods:** Forty-nine edentulous patients with inadequate seal and air leak during two-hand positive-pressure ventilation using the ventilator circle system were prospectively evaluated. In the presence of air leaks, defined as a difference of at least 33% between inspired and expired tidal volumes, the mask was placed in a lower lip position by repositioning the caudal end of the mask above the lower lip while maintaining the head in extension. The results are expressed as mean  $\pm$  SD or median (25th–75th percentiles).

**Results:** Patient characteristics included age ( $71 \pm 11$  yr) and body mass index ( $24 \pm 4$  kg/m<sup>2</sup>). By using the standard method, the median inspired and expired tidal volumes were 450 ml (400–500 ml) and 0 ml (0–50 ml), respectively, and the median air leak was 400 ml (365–485 ml). After placing the mask in the lower lip position, the median expired tidal volume increased to 400 ml (380–490), and the median air leak decreased to 10 ml (0–20 ml) ( $P < 0.001$  vs. standard method). The lower lip face mask placement with two hands reduced the air leak by 95% (80–100%).

**Conclusions:** In edentulous patients with inadequate face mask ventilation, the lower lip face mask placement with two hands markedly reduced the air leak and improved ventilation.

\* Staff Anesthesiologist, † Medical Student, || Professor, Department of Anesthesiology and Critical Care Medicine, ‡ Statistician, Public Health Unit, School of Medicine, Avicenne Hospital, Paris 13 University–Assistance Publique–Hôpitaux de Paris, Bobigny, France. § Assistant Professor, Department of Anesthesiology, Perioperative and Pain Medicine, Brigham and Women’s Hospital, Harvard Medical School, Boston, Massachusetts.

Received from the Department of Anesthesiology and Critical Care Medicine, Avicenne Hospital, Paris 13 University–Assistance Publique–Hôpitaux de Paris, Bobigny, France. Submitted for publication April 8, 2009. Accepted for publication December 28, 2009. Support was provided solely from institutional and/or departmental sources.

Address correspondence to Prof. Baillard: Department of Anesthesiology and Critical Care Medicine, Avicenne University Hospital, 125, Route de Stalingrad, Bobigny 93009, France. christophe.baillard@avc.aphp.fr. Information on purchasing reprints may be found at [www.anesthesiology.org](http://www.anesthesiology.org) or on the masthead page at the beginning of this issue. ANESTHESIOLOGY’s articles are made freely accessible to all readers, for personal use only, 6 months from the cover date of the issue.

### What We Already Know about This Topic

- ❖ Mask ventilation can be difficult in edentulous patients because of failure to obtain a good mask seal on the face

### What This Article Tells Us That Is New

- ❖ In 49 edentulous patients with difficult mask ventilation after induction of anesthesia, repositioning of the caudal end of the mask above the lower lip while maintaining neck extension significantly improved ventilation as measured by reduced air leak and increased expiratory volume

**M**ASK ventilation is an essential component of airway management during anesthesia.<sup>1,2</sup> Difficult mask ventilation (DMV) may lead to complex situations with potential serious adverse outcomes.<sup>3</sup> The underlying pathogenesis of DMV is not fully understood. Upper airway obstruction and air leaks may promote inadequate mask seal and contribute to this problem.<sup>1,4</sup> The mechanisms and the suitable approaches to overcome airway obstruction or air leak have been previously investigated. The jaw thrust and insertion of an oropharyngeal airway device prevent the backward fall of the tongue, a well-known cause of airway obstruction.<sup>1,4,5</sup> Liang *et al.*<sup>6</sup> recently showed the effectiveness of nasal ventilation in reducing airway obstruction compared with oral-nasal ventilation. An air leak is usually observed when an adequate seal cannot be achieved, a situation encountered mainly in edentulous patients with a beard. Both lack of teeth and a beard are known risk factors for DMV.<sup>7–9</sup> In edentulous patients, the air leak is the result of a reduced contact between the cheeks and the mask. Elderly patients are more likely to be edentulous and require general anesthesia. Some have proposed not to remove dentures before induction of anesthesia.<sup>8</sup> A supraglottic airway is another option, which is successful in most cases when dealing with DMV.<sup>10</sup> In addition, Crooke<sup>11</sup> showed that placing the caudal end of the mask between the inferior lip and the alveolar ridge reduces air leak because a good seal forms around a significant part of the mask. We have observed in clinical practice that a similar approach may be effective, but to our knowledge, it has never been investigated. We named this method the “lower lip” face mask placement, a noninvasive

approach requiring no additional equipment and being potentially effective. We hypothesized that in edentulous patients requiring general anesthesia, the lower lip face mask placement with two hands would be more effective in reducing air leaks than the standard face mask placement.

## Materials and Methods

The study design was approved by the institutional review board (Paris-North Hospital, Paris 7 University, Assistance Publique des hôpitaux de Paris, France), and informed consent was obtained from all patients. Edentulous adult patients scheduled for orthopedic or abdominal surgery, or gastrointestinal endoscopy, and general anesthesia were prospectively evaluated for inclusion in this study during a 12-month period. Patients with a contraindication to mask ventilation (*e.g.*, emergency cases requiring a rapid sequence induction, planned awake intubation) were excluded. All patients were in the supine position and routinely monitored using electrocardiography, noninvasive blood pressure measurement, pulse oximetry, and end-tidal carbon dioxide tension before general anesthesia induction. After 10 ml/kg of crystalloid and preoxygenation, standard induction included 1–2 mg/kg propofol injected intravenously over 60 s with or without 0.2–0.3  $\mu$ g/kg sufentanil. After loss of consciousness and cough reflex, an oropharyngeal airway device was inserted (Comepa<sup>®</sup>; Guedel canula, Bagnolet, France). Positive-pressure ventilation holding the face mask with two hands and using the ventilator circle system was prospectively evaluated. The size (3, 4, or 5) of the single-use face-mask (Intersurgical Limited, Wokingham, United Kingdom) was chosen to achieve the best fit for each patient. A volume-controlled anesthesia machine ventilator (Primus Dräger, Lübeck, Germany) was used at a preset gas flow of 10–12 l/min, a tidal volume of 8–10 ml/kg, and a respiratory rate of 12 breaths/min. One hundred percent oxygen was inspired throughout the study period.

Standard face mask ventilation was achieved by placing the thumb and index finger on the body of the mask, whereas the other fingers moved the mandible toward the upper teeth and extended the head. In the presence of persistent air leaks for five consecutive breaths, defined as a difference of at least 33% between inspired and expired tidal volume, the mask was changed to the lower lip placement by repositioning the caudal end of the mask above the lower lip while maintaining the head in extension (figs. 1 and 2). The cephalad end of the mask remained in the same location for both positions. Tidal volume was measured with two Spirolog flow sensors<sup>®</sup>, Dräger Medical S.A.S., Antony, France (hot-wire anemometer technology), placed in the inspired and expired flow of the anesthesia ventilator. Face mask ventilation was performed the same way by six experienced anesthesiologists participating in this study.

## Statistical Analyses

A Wilcoxon signed-rank test was used to compare tidal volumes in the standard and lower lip face mask placements.

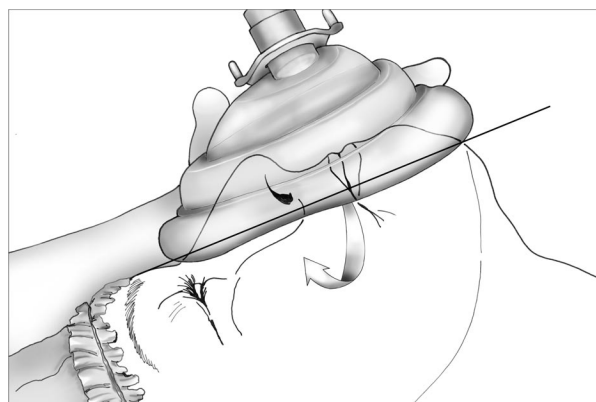


Fig. 1. Illustration of the position of the face mask. The standard face mask ventilation consists of placing the thumb and index finger on the body of the mask, whereas the other fingers move the mandible toward the upper teeth and extend the head. The continuous line represents the plane between the nose and the mandible. The arrow represents air leaks. Only one hand is pictured, and the oropharyngeal airway has been removed to see the position of the mask.

The data were analyzed as ordinal variables. The results are expressed as mean  $\pm$  SD or median (25th–75th percentiles). All statistics were performed using SAS version 9 (SAS Institute, Cary, NC). *P* values of less than 0.05 were considered statistically significant. One-tailed significance testing was used because our hypothesis stated that the lower lip face mask placement would improve mask ventilation when the standard method failed to adequately ventilate the patient.

## Results

Forty-nine (16%) of 300 edentulous patients exhibited inadequate seal with air leak during face mask ventilation. Twenty-six patients underwent orthopedic, 18 gastrointestinal endoscopic, and 5 abdominal procedures. Patient characteristics included age ( $71 \pm 11$  yr), sex (male/female, 16/33), weight ( $66 \pm 11$  kg), height ( $164 \pm 6$  cm), body mass

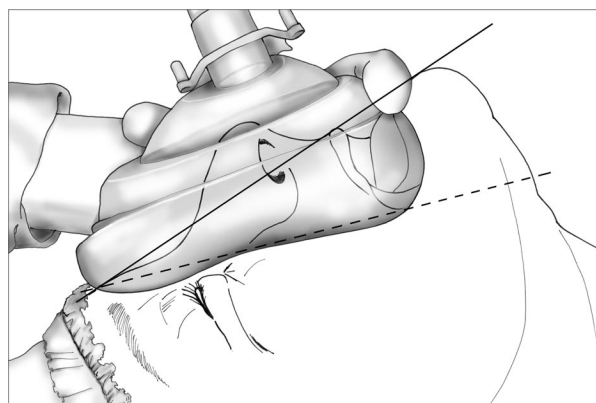


Fig. 2. Illustration of the position of the face mask. The mask was moved in the lower lip placement by repositioning the caudal end of the mask above the lower lip while maintaining the head extension. The continuous line represents the plane between the nose and the mandible. The dashed line represents the contact achieved between the mask and the face. Only one hand is pictured, and the oropharyngeal airway has been removed to see the position of the mask.

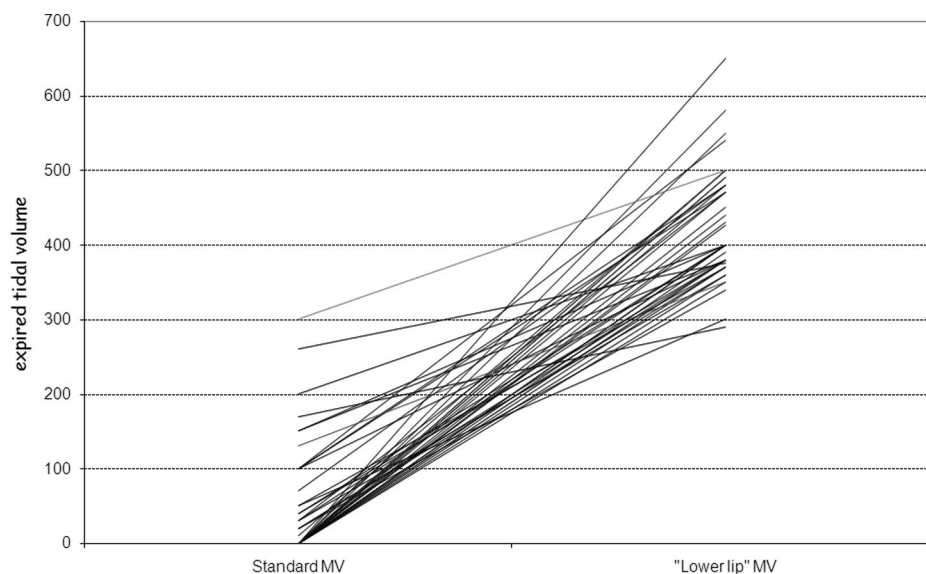


Fig. 3. Expired tidal volume for each patient ( $n = 49$ ) with the standard and lower lip mask ventilation (MV) positions, median value 0 ml (0–50 ml) versus 400 ml (365–485 ml), respectively,  $P < 0.001$ .

index ( $24 \pm 4 \text{ kg/m}^2$ ), American Society of Anesthesiologists score 2 (1–3), and Mallampati score 2 (1–3). Three patients had limited mouth opening ( $< 3 \text{ cm}$ ), six had limited flexion and extension of the neck (flexion + extension  $< 90^\circ$ ), two had a beard, and two had a history of snoring. No patients with prognathia or retrognathia were identified.

With the standard mask placement, the inspired and expired tidal volumes were 450 ml (400–500 ml) and 0 ml (0–50 ml), respectively. The corresponding air leak was 400 ml (365–485 ml). After placing the mask in the lower lip placement, the inspired and expired tidal volumes were 450 ml (400–500 ml) and 400 ml (380–490 ml), respectively. The corresponding air leak was 10 ml (0–20 ml). The lower lip face mask placement with two hands increased the median expired tidal volume in all patients: 400 ml (380–490 ml) versus 0 ml (0–50 ml),  $P < 0.001$ , and significantly reduced the air leak by 95% (80–100%),  $P < 0.001$  (fig. 3). The air leak remained 40% in one patient who had four other predictive features of difficult ventilation<sup>7,8</sup>: advanced age (59 yr), presence of a beard, increased body mass index ( $41 \text{ kg/m}^2$ ), and a history of snoring. Fortunately, the patient was easily intubated. After mask ventilation, 21 patients were successfully intubated on the first attempt, in 9 patients, a laryngeal mask airway was used, and in the remaining 19, face mask ventilation was used throughout the anesthesia procedure. No patient experienced an oxyhemoglobin desaturation ( $\text{SpO}_2$ ) below 95% during the study period.

## Discussion

This study investigated for the first time face mask ventilation using a lower lip face mask placement with two hands. In the presence of air leaks during standard face mask ventilation, this approach increased the expired tidal volume in all patients and markedly improved the ventilation in edentu-

lous patients. In addition, the lower lip face mask placement reduced the air leaks by 95%.

DMV has been investigated over the last decade, with an incidence of 1.5–5% in the general population.<sup>7,8,12</sup> DMV was observed in 12% of edentulous patients, and the lack of teeth was an independent predictive factor for DMV.<sup>8</sup> The incidence of DMV was 16% in our study. In contrast, Kheterpal *et al.*<sup>7</sup> did not identify lack of teeth as an independent predictor for DMV.

Mask ventilation is often not effective and, in some cases, almost impossible in edentulous patients because of the lack of facial support. This lack of support leads to an inadequate external mask fit and significant air leaks. Langeron *et al.*<sup>8</sup> suggested not to remove dentures before induction of anesthesia to maintain a proper facial support. However, this may be a dangerous approach because the dentures may be swallowed or aspirated. Nasal positive pressure may be used in edentulous patients because the mask contact is only on the maxillary plane.<sup>6</sup> Another approach consists of placing the caudal end of the mask between the inferior lip and the alveolar ridge.<sup>11</sup> The lower lip face mask placement used in this study was similar to that described by Croke,<sup>11</sup> except that the caudal end of the mask was placed just above the inferior lip, which was not everted. Mouth opening, which is a component of the triple airway maneuvers for improvement of upper airway patency, was automatically achieved by our lower lip face mask placement technique.

Because it has been shown that it can be difficult to maintain adequate seal with only one hand,<sup>1</sup> we decided to use the two-hand technique in our study in an attempt to reach adequate ventilation.<sup>1,13,14</sup> In the study by Langeron *et al.*,<sup>8</sup> the two-hand mask ventilation was not used as a primary technique but only as a rescue maneuver. Although the method was not fully described, a one-hand technique was used first (Professor Olivier Langeron, M.D., Ph.D., Depart-

ment of Anesthesiology and Critical Care Medicine, Pitié-Salpêtrière University hospital, September 2009, verbal communication). Moreover, regarding the grading scale for mask ventilation proposed by Han *et al.*,<sup>12</sup> our practice could be viewed as a method for grade 3 DMV (DMV requiring two practitioners) because the ventilator played the role of a second practitioner. For the purpose of this study (*i.e.*, assessment of air leaks), we chose an objective measurement of the ventilation efficiency. Baseline characteristics of ventilation were all controlled and similar. A difference of at least 33% between inspired and expired tidal volumes was defined as inadequate ventilation. Such a cutoff is somewhat arbitrary but came from the clinical experience that air leaks of lower magnitude are not usually clinically relevant. Because airway obstruction may promote mask leak, it is difficult to differentiate the precise underlying mechanism of DMV. The use of the oropharyngeal airway in all of our patients minimized the contribution of airway obstruction to changes in the expired tidal volume. Therefore, we consider that the expired tidal volume changes resulted mostly from the mask leak. However, an absolute distinction of the two factors remains speculative. We did not report end-tidal carbon dioxide or airway pressures because these values are unreliable under these circumstances. In our study, the median expired tidal volume, end-tidal carbon dioxide, and airway pressure were all 0 ml before applying the lower lip face mask placement with two hands. There was no delay in the use of the lower lip face mask placement because the maneuver did not require any specific equipment but only to change the placement of the face mask.

Although recent studies have been performed to predict the occurrence of DMV, the management with alternative solutions has been studied less often.<sup>2,7,8,12</sup> Some have even suggested to shave the patient before the surgery.<sup>7,8,15</sup> Because obesity contributes to DMV, losing weight may be beneficial in the long term.<sup>8</sup> Nasal ventilation has been shown to be more effective than face mask ventilation in selected patient populations.<sup>6</sup> Further studies are warranted to confirm this issue in patients with obesity and/or obstructive sleep apnea, both well-identified risk factors for DMV. In edentulous patients, Langeron *et al.*<sup>8</sup> suggested not to remove dentures before induction of anesthesia. This study shows that the lower lip face mask placement with two hands is a suitable and alternative approach in the presence of DMV. It is important to point out that if mask ventilation

remains impossible, the laryngeal mask airway could be used as a rescue device, especially if there are also difficulties intubating the patient. None of our patients necessitated the placement of an endotracheal tube or laryngeal mask airway for this reason.<sup>10</sup>

In summary, in the presence of air leaks during usual face mask ventilation of apneic edentulous patients, the lower lip face mask placement with two hands markedly improved ventilation. Because this maneuver increased the expired tidal volume in all patients and did not require additional equipment, we suggest its use as soon as possible when a DMV is encountered.

## References

1. Ortega R, Mehio AK, Woo A, Hafez DH: Videos in clinical medicine: Positive-pressure ventilation with a face mask and a bag-valve device. *N Engl J Med* 2007; 357:e4
2. Adnet F: Difficult mask ventilation: An underestimated aspect of the problem of the difficult airway? *ANESTHESIOLOGY* 2000; 92:1217-8
3. Caplan RA, Posner KL, Ward RJ, Cheney FW: Adverse respiratory events in anesthesia: A closed claims analysis. *ANESTHESIOLOGY* 1990; 72:828-33
4. Safar P, Escarraga LA, Chang F: Upper airway obstruction in the unconscious patient. *J Appl Physiol* 1959; 14:760-4
5. Defalque RJ, Wright AJ: Who invented the "jaw thrust"? *ANESTHESIOLOGY* 2003; 99:1463-4
6. Liang Y, Kimball WR, Kacmarek RM, Zapol WM, Jiang Y: Nasal ventilation is more effective than combined oral-nasal ventilation during induction of general anesthesia in adult subjects. *ANESTHESIOLOGY* 2008; 108:998-1003
7. Kheterpal S, Han R, Tremper KK, Shanks A, Tait AR, O'Reilly M, Ludwig TA: Incidence and predictors of difficult and impossible mask ventilation. *ANESTHESIOLOGY* 2006; 105:885-91
8. Langeron O, Masso E, Huraux C, Guggiari M, Bianchi A, Coriat P, Riou B: Prediction of difficult mask ventilation. *ANESTHESIOLOGY* 2000; 92:1229-36
9. Kheterpal S, Martin L, Shanks AM, Tremper KK: Prediction and outcomes of impossible mask ventilation: A review of 50,000 anesthetics. *ANESTHESIOLOGY* 2009; 110:891-7
10. Practice guidelines for management of the difficult airway: An updated report by the American Society of Anesthesiologists Task Force on Management of the Difficult Airway. *ANESTHESIOLOGY* 2003; 98:1269-77
11. Crouke J: The bearded airway. *Anaesthesia* 1999; 54:500
12. Han R, Tremper KK, Kheterpal S, O'Reilly M: Grading scale for mask ventilation (letter). *ANESTHESIOLOGY* 2004; 101:267
13. Devitt JH, Brooks DA, Oakley PA, Webster PM: Mask lung ventilation by ambulance personnel: A performance assessment. *Can J Anaesth* 1994; 41:111-5
14. Isono S: One hand, two hands, or no hands for maximizing airway maneuvers? *ANESTHESIOLOGY* 2008; 109:576-7
15. Johnson JO, Bradway JA, Blood T: A hairy situation (letter). *ANESTHESIOLOGY* 1999; 91:595