

## Successful Airway Management with Combined Use of Glidescope® Videolaryngoscope and Fiberoptic Bronchoscope in a Patient with Cowden Syndrome

Deepak Sharma, M.D., D.M.,\*  
Louis J. Kim, M.D.,† Basavaraj Ghodke, M.D.‡

**C**OWDEN syndrome is a rare autosomal dominant disorder caused by mutation in the *phosphatase and tensin homolog* gene.<sup>1</sup> It is characterized by multiple mucocutaneous hamartomas, malignancies of breast, thyroid, and genitourinary system, and a variety of intracranial abnormalities including meningiomas and vascular malformations.<sup>2,3</sup> Difficulties in airway management can be encountered in these patients because of the presence of papillomatous lesions on the mucosa of pharyngeal wall, lingual tonsils, and epiglottis.<sup>4,5</sup> In fact, critical airway obstruction and bleeding during induction of anesthesia requiring emergent tracheostomy has been described in association with Cowden syndrome.<sup>5</sup> We describe a case of successful airway management with combined use of a Glidescope® videolaryngoscope (Verathon Medical, Bothell, WA) and a fiberoptic bronchoscope in a patient with Cowden syndrome with papillomatous lesions of the airway.

### CASE REPORT

A 37-yr-old woman, weighing 83 kg, with Cowden syndrome being followed up for dural arteriovenous fistula pre-

\* Assistant Professor, Department of Anesthesiology and Pain Medicine, † Assistant Professor, Department of Neurological Surgery, ‡ Assistant Professor, Departments of Neurological Surgery and Neuroradiology, Harborview Medical Center, University of Washington, Seattle, Washington.

Received from the Department of Anesthesiology and Pain Medicine, Harborview Medical Center, University of Washington, Seattle, Washington. Submitted for publication January 6, 2010. Accepted for publication March 22, 2010. Support was provided solely from institutional and/or departmental sources.

Address correspondence to Dr. Sharma: Department of Anesthesiology and Pain Medicine, Harborview Medical Center, 325 Ninth Avenue, Box 359724, Seattle, Washington 98104. dsharma@uw.edu. Information on purchasing reprints may be found at [www.anesthesiology.org](http://www.anesthesiology.org) or on the masthead page at the beginning of this issue. ANESTHESIOLOGY's articles are made freely accessible to all readers, for personal use only, 6 months from the cover date of the issue.

sented with worsening headaches, tremors, and left-sided bruit. Her fistula had been previously embolized twice during general anesthesia uneventfully, and she had also received  $\gamma$ -knife radiotherapy. Her medical history was significant for Graves disease (treated with thyroidectomy at age 28 yr and I-131 followed by thyroid replacement therapy), breast cancer (treated with lumpectomy at age 31 yr followed by tamoxifen), and trichilemmoma on the skin of face. Her family history was unknown, because she was adopted as a child and she had no children. On examination, she had macrocephaly and multiple trichilemmoma lesions on the face. Airway examination showed Mallampati class IV and numerous 2–3 mm nodules on gingival mucosa and tongue. Her vital signs were within normal limits. She had no obvious neurologic deficits, and the rest of the physical examination and laboratory investigations were unremarkable. Cerebral angiogram demonstrated stenosis of the right transverse sinus and a new left jugular bulb region dural arteriovenous fistula. She was scheduled for transvenous stenting and venoplasty of the right transverse sinus and transarterial embolization of the new fistula. Although the anesthetic details for thyroidectomy and breast surgery were not available, there was no apparent problem that the patient was aware of. Her previous two anesthetics for embolization (both at age 35 yr) were at our institution, one of them by the same anesthesiologist. She required a Glidescope® intubation on the first occasion after Cormack-Lehane grade IV view was seen on direct laryngoscopy. On the next occasion, she was intubated electively using Glidescope®. A grade II view was achieved, and multiple small papillae were seen on the pharyngeal wall. However, intubation was straightforward.

After institution of standard monitors and preoxygenation, anesthesia was induced with 150  $\mu$ g fentanyl, 200 mg propofol, and 50 mg rocuronium. After mask ventilation for 3 min, laryngoscopy was performed using Glidescope®, and a grade II view of the glottis was achieved. Numerous small papillae were seen on the pharyngeal wall, epiglottis, and arytenoids. Their number and size were clearly increased compared with the previous anesthetic (1 year before). A 7.0-mm regular Sheridan/HVT® endotracheal tube (ETT) (Hudson RCI, Temecula, CA) loaded on the Glidescope® rigid stylet (Verathon Medical) was advanced. Despite satisfactory visualization of vocal cords, it was difficult to direct the tube toward the vocal cords and intubate the trachea. The ETT was rotated and maneuvered to negotiate it anteriorly toward the glottis. This led to the tube hitting the arytenoids and initiated slight bleeding from the papillomas. The ETT was withdrawn immediately, and the pharynx was carefully suctioned under Glidescope® vision with a soft suction catheter. Because further attempts at passing the tube could potentially increase the bleeding and jeopardize the airway, we decided to change the Glidescope® stylet for a fiberoptic bronchoscope. While the oxygen saturation was still 99%, a fiberoptic bronchoscope was used as a stylet for the ETT while glottis was visualized through the Glidescope®. We did not use the optics of the bronchoscope for glottic visualization. The tip of bronchoscope, as visualized on the Glidescope® screen, could

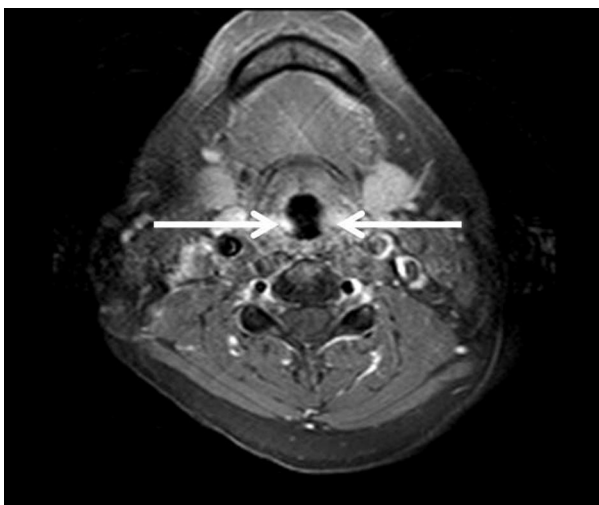
be maneuvered easily using the control lever toward the glottis and passed rapidly through the vocal cords without any further trauma, followed by smooth railroading of ETT with its bevel directed posteriorly. The ETT cuff was inflated and ventilation resumed. Anesthesia was maintained with sevoflurane (0.8–1.0 minimum alveolar concentration), and boluses of fentanyl and rocuronium were administered intermittently. After completion of the procedure, check laryngoscopy with Glidescope<sup>®</sup> showed complete resolution of the bleeding. Residual neuromuscular block was reversed with neostigmine and glycopyrrolate and after resumption of adequate spontaneous ventilation; trachea was extubated when the patient started following commands. The postoperative period was uneventful, and she was discharged next day. Postoperative review of magnetic resonance imaging axial postcontrast T1 fat-saturated image clearly demonstrated the contrast enhancing lesions in hypopharynx, consistent with the papillomas (fig. 1).

## Discussion

The important observations in this patient with Cowden syndrome were as follows: (1) airway management may be complicated by bleeding from the papillomas; (2) although Glidescope<sup>®</sup> is useful in glottic visualization, attempts at directing the ETT toward the cords may lead to airway bleeding from trauma to the papillae; and (3) trachea can be intubated atraumatically with combined use of Glidescope<sup>®</sup> and fiberoptic bronchoscope.

### Cowden Syndrome and the Airway

Cowden syndrome is characterized by mucocutaneous lesions such as facial trichilemmomas and papillomatous lesions.<sup>2,3</sup> Upper airway involvement with papillomatous lesions in these patients can complicate laryngoscopy and intubation.<sup>5</sup> Sharma *et*



**Fig. 1.** Magnetic resonance imaging axial postcontrast T1 fat-saturated image. Arrows indicate contrast enhancing lesions in hypopharynx projecting into the airway from right and the left sides, suggestive of hypervascular lesions consistent with the papillomas.

*al.*<sup>6</sup> have reported airway obstruction because of the involvement of Waldeyer ring with mucosal papillomas in a father and son duo with phosphatase and tensin homolog hamartoma-tumor syndrome. The father remained tracheostomy-dependent for several years, whereas the son's obstructive sleep apnea resolved after adenotonsillectomy. Involvement of the vocal folds in Cowden syndrome is also known.<sup>7</sup> The airway anatomy may be distorted by the presence of extensive papillomatous lesions, and identification of the epiglottis and surrounding structures may not be possible on direct laryngoscopy.<sup>5</sup> Bleeding from the fragile papillomas during intubation, causing complete airway obstruction necessitating emergent tracheostomy, followed by prolonged intensive care and therapeutic hypothermia for cerebral protection, have been described in a case of Cowden syndrome.<sup>5</sup>

### Combined Use of Glidescope<sup>®</sup> Videolaryngoscope and Intubating Bronchoscope

Our patient had uneventful intubation on two previous occasions using Glidescope<sup>®</sup> and had no symptoms suggestive of airway obstruction. Therefore, we decided to perform intravenous induction of anesthesia followed by Glidescope<sup>®</sup>-assisted intubation. Like the two previous occasions, good view of the glottis was obtained. However, the difficulty was directing the tube toward the cords. This is a known limitation of Glidescope<sup>®</sup> attributable to the curvature of the blade.<sup>8</sup> Despite the use of stylet, advancing the ETT toward the vocal cords can be difficult and can cause airway trauma,<sup>9–11</sup> which may be catastrophic in the presence of fragile lesions around the glottis. Therefore, immediately after we noticed bleeding, the ETT was withdrawn, and the airway suctioned instead of making further attempts at intubation. Because the tip of the fiberoptic bronchoscope is easily maneuverable, we decided to use it to guide the tube passage while maintaining glottic view on Glidescope<sup>®</sup>. We did not use the optics of the bronchoscope for laryngoscopy because satisfactory glottic view was readily achieved with Glidescope<sup>®</sup>, and we wanted to rapidly secure the airway without further trauma. The airway could have been secured possibly by other means in this scenario such as the use of a pliable metal stylet, but we preferred the fiberoptic bronchoscope because intubation with the former may require multiple attempts and may cause further trauma, whereas the latter has the advantage of being easily maneuverable. Other devices such as an optical stylet could also be potentially useful.

Elective fiberoptic intubation is frequently preferred by anesthesiologists in anticipated difficult airways. However, inability to advance the bronchoscope near the larynx has been reported in Cowden syndrome because of the presence of extensive papillomas in the hypopharynx.<sup>5</sup> Moreover, the difficulty in passing the ETT over bronchoscope is well known,<sup>12</sup> and airway trauma because of the tube impinging on glottic structures with multiple attempts to overcome the resistance has been reported.<sup>13</sup> Because the most common site for the tube being caught is the arytenoids,<sup>12</sup> this may lead to avulsion of any fragile lesions on arytenoids, resulting

in airway bleeding. A number of techniques such as rotating the ETT anticlockwise while intubating<sup>14</sup> and a variety of tube designs (*e.g.*, Parker tube, Oxford tube, and intubating laryngeal mask tube)<sup>15–18</sup> have been suggested to overcome this problem. For use with the Glidescope<sup>®</sup>, the manufacturers recommend using the GlideRite<sup>®</sup> tube (Verathon Medical) to avoid hold-up at the cords. The combined use of Glidescope<sup>®</sup> with fiberoptic bronchoscope in this case allowed easy visualization of glottis by the Glidescope<sup>®</sup> while the bronchoscope functioned as an easily maneuverable stylet. Moreover, ETT could be railroaded over the fiberoptic bronchoscope under Glidescope<sup>®</sup> vision, such that any maneuvering of the tube, if required, could be performed under vision, avoiding trauma to the glottic structures. A similar technique involving the use of fiberoptic bronchoscope as a rescue stylet to overcome difficulty in intubating with a Glidescope<sup>®</sup> has been described previously, although the patient described did not have airway lesions like our patient.<sup>19</sup>

However, in retrospect, we do realize that we were fortunate that our patient did not have extensive fragile papillomas at the base of tongue, in which case laryngoscopy with Glidescope<sup>®</sup> could have potentially caused trauma and bleeding. It may be safe to use Glidescope<sup>®</sup> or other type of laryngoscope blade in patients with Cowden syndrome only after excluding upper airway involvement by preoperative radiologic imaging.

### Importance of Preoperative Airway Assessment in Cowden Syndrome

Cowden syndrome is a rare but an important disease for anesthesiologists because of the possibility of occurrence of airway disaster. A high degree of suspicion of difficulty in airway management is warranted in patients with this syndrome despite documented uneventful intubations in the past because the lesions can progress over a period of time, complicating subsequent airway management. Hence, extensive preoperative airway assessments may be desirable in these patients. This may include preoperative sleep study for assessing possible difficulties or impossible mask ventilation and airway obstruction in addition to airway imaging with magnetic resonance imaging or computed tomography for detecting airway pathology and its location. When possible difficult mask ventilation is indicated, awake intubation should be considered as recommended by the American Society of Anesthesiologists guidelines.

In conclusion, we describe a case of successful airway management with combined use of Glidescope<sup>®</sup> and fiberoptic bronchoscope in a patient with Cowden syndrome with papillomatous lesions of the airway. We recommend keeping a high degree of suspicion of difficulty in airway management in patients with this syndrome despite documented uneventful intubations in the past, because the lesions can progress rapidly, complicating subsequent airway management. Extra preparedness with the availability of adequate equipment and assistance is warranted.

## References

1. Marsh DJ, Coulon V, Lunetta KL, Rocca-Serra P, Dahia PL, Zheng Z, Liaw D, Caron S, Duboue B, Lin AY, Richardson AL, Bonnetblanc JM, Bressieux JM, Cabarro-Moreau A, Chompret A, Demange L, Eeles RA, Yahanda AM, Fearon ER, Fricker JP, Gorlin RJ, Hodgson SV, Huson S, Lacombe D, LePrat F, Odent S, Toulouse C, Olopade OI, Sobol H, Tishler S, Woods CG, Robinson BG, Weber HC, Parsons R, Peacocke M, Longy M, Eng C: Mutation spectrum and genotype-phenotype analyses in Cowden disease and Bannayan-Zonana syndrome, two hamartoma syndromes with germline PTEN mutation. *Hum Mol Genet* 1998; 7:507–15
2. Lloyd KM, Dennis M: Cowden's syndrome: A possible new symposium complex with multiple system involvement. *Ann Intern Med* 1963; 58:136–42
3. Weary PE, Gorlin RJ, Gentry WC Jr, Comer JE, Greer KE: Multiple hamartoma syndrome (Cowden's disease). *Arch Derm* 1972; 106:682–90
4. Devlin MF, Barrie R, Ward-Booth RP: Cowden's disease: A rare but important manifestation of oral papillomatosis. *Br J Oral Maxillofac Surg* 1992; 30:335–6
5. Omote K, Kawamata T, Imaizumi H, Namiki A: Case of Cowden's disease that caused airway obstruction during induction of anesthesia. *ANESTHESIOLOGY* 1999; 91:1537–40
6. Sharma MR, Petty EM, Lesperance MM: Airway obstruction caused by PTEN hamartoma (Bannayan-Riley-Ruvalcaba) syndrome. *Arch Otolaryngol Head Neck Surg* 2007; 133:1157–60
7. To EW, Tsang WM, Pak MW, Cheng JH, Tse GM, van Hasselt CA: Cowden's disease with vocal fold involvement. *Ear Nose Throat J* 2001; 80:754–6
8. Doyle DJ: The GlideScope video laryngoscope. *Anaesthesia* 2005; 60:414–5
9. Cooper RM: Complications associated with the use of the GlideScope videolaryngoscope. *Can J Anaesth* 2007; 54:54–7
10. Hsu WT, Hsu SC, Lee YL, Huang JS, Chen CL: Penetrating injury of the soft palate during GlideScope intubation. *Anesth Analg* 2007; 104:1609–10
11. Malik AM, Frogel JK: Anterior tonsillar pillar perforation during GlideScope video laryngoscopy. *Anesth Analg* 2007; 104:1610–1
12. Johnson DM, From AM, Smith RB, From RP, Maktabi MA: Endoscopic study of mechanisms of failure of endotracheal tube advancement into the trachea during awake fiberoptic orotracheal intubation. *ANESTHESIOLOGY* 2005; 102:910–4
13. Maktabi MA, Hoffman H, Funk G, From RP: Laryngeal trauma during awake fiberoptic intubation. *Anesth Analg* 2002; 95:1112–4
14. Sharma D, Bithal PK, Rath GP, Pandia MP: Effect of orientation of a standard polyvinyl chloride tracheal tube on success rates during awake flexible fiberoptic intubation. *Anaesthesia* 2006; 61:845–8
15. Kristensen MS: The Parker Flex-Tip tube *versus* a standard tube for fiberoptic orotracheal intubation: A randomized double-blind study. *ANESTHESIOLOGY* 2003; 98:354–8
16. Jones HE, Pearce AC, Moore P: Fiberoptic intubation: Influence of tracheal tube tip design. *Anaesthesia* 1993; 48:672–4
17. Greer JR, Smith SP, Strang T: A comparison of tracheal tube tip designs on the passage of an endotracheal tube during oral fiberoptic intubation. *ANESTHESIOLOGY* 2001; 94:729–31
18. Lucas DN, Yentis SM: A comparison of the intubating laryngeal mask tracheal tube with a standard tracheal tube for fiberoptic intubation. *Anaesthesia* 2000; 55:358–61
19. Moore MS, Wong AB: GlideScope intubation assisted by fiberoptic scope. *ANESTHESIOLOGY* 2007; 106:885