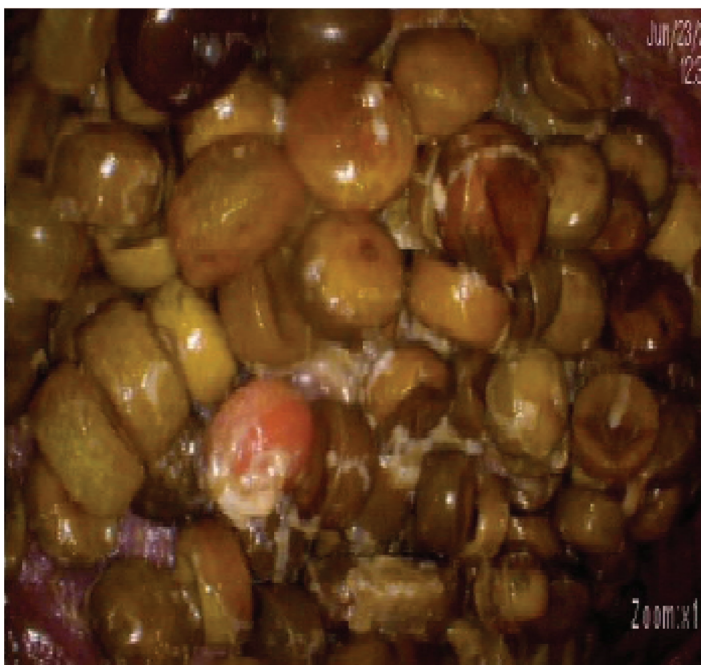
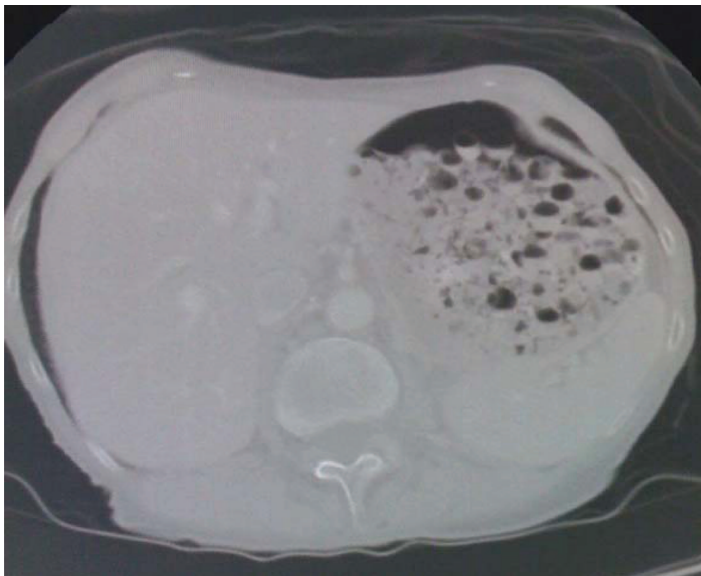


## Images in Anesthesiology: A Large Gastric Bezoar: Preanesthetic Considerations

Jaydev Sarma, M.D.,\* Matthias Eikermann, M.D., Ph.D.

\*Department of Anesthesia, Critical Care and Pain Medicine, Massachusetts General Hospital and Harvard Medical School, Boston, Massachusetts  
jsarma@partners.org



A 76-YR-OLD emaciated woman came to the emergency department with a history of increasing shortness of breath. Her medications included atenolol and extended-release nifedipine. A mass was detected on the chest x-ray, and subsequent computer tomography scan (*top*) revealed a possible large pharmacobezoar that was confirmed by endoscopy (*bottom*).

Two preanesthetic considerations must be taken into account in patients presenting with pharmacobezoar. First, acute intake of large doses of the active component can induce toxic symptoms. Medications reported to form bezoars occasionally include clomipramine, amitriptyline, potassium chloride, procainamide, nifedipine, carbamazepine, meprobamate, iron, verapamil, theophylline, and enteric-coated aspirin.<sup>1,2</sup> The patient's medical history and physical examination did not reveal evidence of acute intoxication. Second, risk of aspiration during deep sedation or general anesthesia is increased. There is no evidenced-based guideline for the anesthetic management of such a patient. Therefore, the clinical anesthesiologist needs to decide how best to proceed, based on a risk-benefit analysis. Our patient denied abdominal pain, vomiting, and any alteration in bowel habits.

Bezoar fragmentation and endoscopic removal of retained tablets was conducted. Approximately 150 pills, about one-third of the total number of retained pills, were safely removed.

### References

1. Höjer J, Personne M: Endoscopic removal of slow release clomipramine bezoars in two cases of acute poisoning. *Clin Toxicol (Phila)* 2008; 46:317-9
2. Taylor JR, Streetman DS, Castle SS: Medication bezoars: A literature review and report of a case. *Ann Pharmacother* 1998; 32:940-6