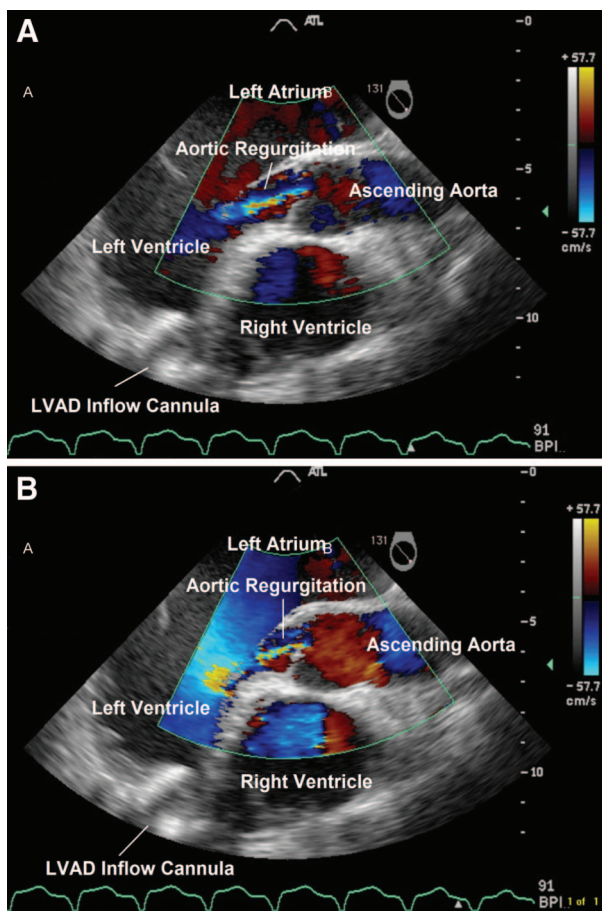


Continuous Aortic Regurgitation with Ventricular Assist Device

Jiapeng Huang, M.D., Ph.D., F.A.S.E.,* Mark S. Slaughter, M.D.

* Department of Anesthesia, Jewish Hospital and St. Mary's Healthcare, Department of Anesthesiology and Perioperative Medicine, University of Louisville, Louisville, Kentucky
jiapenghuang@yahoo.com



A 57-YR-OLD man with a history of nonischemic cardiomyopathy treated with a HeartMate 2 left ventricular assist device (LVAD) (Thoratec, Pleasanton, CA) 1 yr ago presented for orthotopic heart transplantation. The modern LVAD receives blood from the left ventricular apex and provides continuous flow to the ascending aorta with minimal pulsatility.^{1,2} Native regular cardiac rhythm is still critical for the right heart to pump blood to supply inflow to the LVAD. Total cardiac output is the sum of the LVAD flow and left ventricular cardiac output. Mild aortic regurgitation was present in both systole (*panel A*) and diastole (*panel B*) by color flow Doppler (see video, Supplemental Digital Content 1, <http://links.lww.com/ALN/A745>, which shows continuous aortic regurgitation). In the presence of the LVAD, the left ventricular systolic pressure might be lower than the constant back pressure generated from the device. A structurally incompetent aortic valve will demonstrate aortic regurgitation in diastole as well as in systole if the left ventricular systolic pressure remains low. Aortic regurgitation causes blood backflow to the left ventricle and a circuitry between the left ventricle and ascending aorta. LVAD flow will read artificially higher than the effective flow delivered to vital organs. Therapeutic interventions consist of afterload reduction, decreasing LVAD pump speed, volume loading, and inotropic support both for the right ventricle to pump more blood to the left and to increase left ventricular systolic pressure. Aortic regurgitation usually progresses over time while on LVAD support because of either structural changes or increased aortic back pressure. Our patient tolerated this mild continuous aortic regurgitation well before cardiopulmonary bypass and underwent successful heart transplantation.

References

1. Frazier OH: Unforeseen consequences of therapy with continuous-flow pumps. *Circulation Heart Fail* 2010; 3:647-9
2. Slaughter MS, Pagani FD, Rogers JG, Miller LW, Sun B, Russell SD, Starling RC, Chen L, Boyle AJ, Chillcott S, Adamson RM, Blood MS, Camacho MT, Idrissi KA, Petty M, Sobieski M, Wright S, Myers TJ, Farrar DJ, HeartMate II Clinical Investigators: Clinical management of continuous-flow left ventricular assist devices in advanced heart failure. *J Heart Lung Transplant* 2010; 29:S1-39

Supplemental digital content is available for this article. Direct URL citations appear in the printed text and are available in both the HTML and PDF versions of this article. Links to the digital files are provided in the HTML text of this article on the Journal's Web site (www.anesthesiology.org).