

# Intraoperative Pneumothorax Identified with Transthoracic Ultrasound

Kenichi Ueda, M.D.,\* Waseemuddin Ahmed, M.D.,† Alan F. Ross, M.D.‡

**P**NEUMOTHORAX is an uncommon but potentially serious occurrence during anesthesia. Initial clinical signs may be subtle, but progression to a tension pneumothorax can result in significant cardiorespiratory instability. Because therapy for pneumothorax may require invasive chest tube placement, definitive diagnosis by chest radiography is necessary. However, intraoperative chest radiograph may be inconvenient and difficult, causing the diagnosis to be delayed until completion of operation. We describe two cases in which intraoperative transthoracic ultrasound rapidly established a diagnosis of pneumothorax and facilitated timely utilization of resources for definitive treatment.

## CASE REPORTS

### Case 1

A 67-yr-old male was undergoing elective laparoscopic Nissen fundoplication for a large paraesophageal hernia. Past medical conditions included gastroesophageal reflux disease, sleep apnea, hypertension, hyperlipidemia, and a distant smoking history. The preoperative chest radiograph demonstrated the hernia, but was otherwise normal. Anesthetic induction was rapid sequence using lidocaine, fentanyl, propofol, and succinylcholine. Intubation was without difficulty, and breath sounds were equal bilaterally. Pressure control ventilation at 20 cm H<sub>2</sub>O and 5 cm H<sub>2</sub>O of peak-end expiratory pressure produced tidal volumes of 600–700 ml. Maintenance anesthesia was isoflurane in air and oxygen (fraction of inspired oxygen = 0.4), and the operative course was uneventful.

\* Clinical Assistant Professor, Department of Anesthesia, University of Iowa, Iowa City, Iowa. † Resident Physician, Department of Anesthesia, University of Iowa. ‡ Associate Professor, Department of Anesthesia, University of Iowa.

Received from the Department of Anesthesia, University of Iowa, Iowa City, Iowa. Submitted for publication Feb. 16, 2011. Accepted for publication May 19, 2011. Support was provided solely from institutional and/or departmental sources.

Address correspondence to Dr. Ahmed: Department of Anesthesia, University of Iowa, 200 Hawkins Drive, Iowa City, Iowa 52242. waseemuddin-ahmed@uiowa.edu. This article may be accessed for personal use at no charge through the Journal Web site, www.anesthesiology.org.

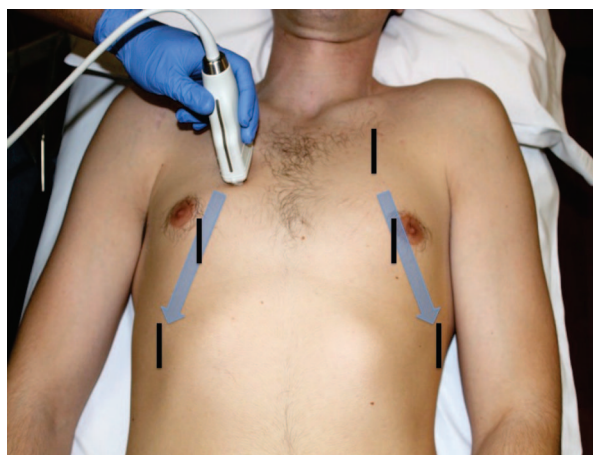
Copyright © 2011, the American Society of Anesthesiologists, Inc. Lippincott Williams & Wilkins. Anesthesiology 2011; 115:653–5

During abdominal wall closure, the patient's oxygen saturation gradually decreased from 100% into the low 90s, and the delivered tidal volume decreased. Manual recruitment maneuvers were not effective at restoring the saturation. Auscultation revealed normal breath sounds over the left thorax but distant breath sounds on the right. Fiberoptic bronchoscopy confirmed that the endotracheal tube was proximal to the carina, and both mainstem bronchi were clear of obstruction. A pneumothorax was suspected, and a postoperative chest radiograph was planned. While the surgeons were closing, the right and left hemithoraces were examined with ultrasound (surface probe: S12-4 Sector Array Transducer, ultrasound machine: HD-11; Philips Electronics North America Corporation, Andover, MA). The ultrasound probe was placed on the anterior chest wall at multiple intercostal spaces using a depth setting of 5 cm. The left chest exam demonstrated respiratory movement at the pleural line, a phenomenon known as "lung sliding." (See Video, Supplemental Digital Content 1, <http://links.lww.com/ALN/A765>, which is a video clip showing lung sliding.) However, the lung-sliding sign was absent on right chest exam, which was consistent with pneumothorax. (See Video, Supplemental Digital Content 2, <http://links.lww.com/ALN/A766>, which is a video clip showing the absence of lung sliding.) A portable chest x-ray film confirmed the presence of a 2.2-cm right-sided pneumothorax. Chest tube placement resulted in immediate improvement of tidal volumes and oxygen saturation and the return of bilateral equal breath sounds. Repeat chest x-ray showed reexpansion of the right lung. Repeat ultrasound imaging now demonstrated "lung sliding" for both the left and right chest exams. The patient was extubated at the end of the case and taken to the postanesthesia care unit with no further respiratory issues. The ultrasound evaluation took less than 2 min to complete.

- ◆ This article is accompanied by an Editorial View. Please see: Johnson DW, Oren-Grinberg A: Perioperative point-of-care ultrasonography: The past and the future are in anesthesiologists' hands. ANESTHESIOLOGY 2011; 115:460–2.
- ⊕ Supplemental digital content is available for this article. Direct URL citations appear in the printed text and are available in both the HTML and PDF versions of this article. Links to the digital files are provided in the HTML text of this article on the Journal's Web site ([www.anesthesiology.org](http://www.anesthesiology.org)).

## Case 2

A 58-yr-old male with multiple psychiatric disorders, including schizophrenia, was brought to the emergency treatment center after jumping from the second story of a building. Injuries included multiple bilateral rib fractures, right femur fracture, and a proximal descending thoracic aorta dissection. The patient was immediately transported to the operating room for endovascular repair of the aorta dissection. He was uncooperative and wearing a rigid cervical collar. Anesthesia was induced with etomidate, and muscle paralysis was achieved with rocuronium. A single lumen endotracheal tube was placed in the trachea with a fiberoptic bronchoscope and positioned 3 cm above the carina. Breath sounds were equal bilaterally, and oxygen saturation was 100% after intubation. Ventilator parameters included volume control mode, tidal volume 600 ml, peak-end expiratory pressure of 5 cm H<sub>2</sub>O, and peak inspiratory pressure of 20 cm H<sub>2</sub>O. Isoflurane in air and oxygen (fraction of inspired oxygen = 0.6) were used for the maintenance of general anesthesia. Over the course of the following 5 min, the patient's oxygen saturation acutely decreased to the low 80s. Endotracheal tube position had not changed. Despite an increase to 100% oxygen, oxygen saturation remained in the low 80s. On auscultation, breath sounds were diminished on the left. Using ultrasound, the right and left hemithoraces were examined (surface probe: S12-4, machine HD-11). The ultrasound probe was placed on the anterior chest wall at multiple intercostal spaces. Lung sliding was demonstrated on the right lung after the exam, but not on the left lung. Because of the patient's respiratory instability, a 14-gauge intravenous catheter was placed superior to the rib at the second intercostal space along the midclavicular line. An immediate return of air resulted. A chest tube was placed, and the patient's oxygen saturation returned to 100%. Subsequent ultrasound imaging showed lung sliding on the left side, indicating that the pleura had been reapproximated. The remainder of the intraoperative course was uneventful.



**Fig. 1.** The ultrasound probe should initially be placed on the anterior chest wall along the midclavicular line. If no lung sliding is evident, multiple intercostal spaces should be examined for the presence of lung sliding. Both the right and left hemithoraces should be scanned with ultrasound.

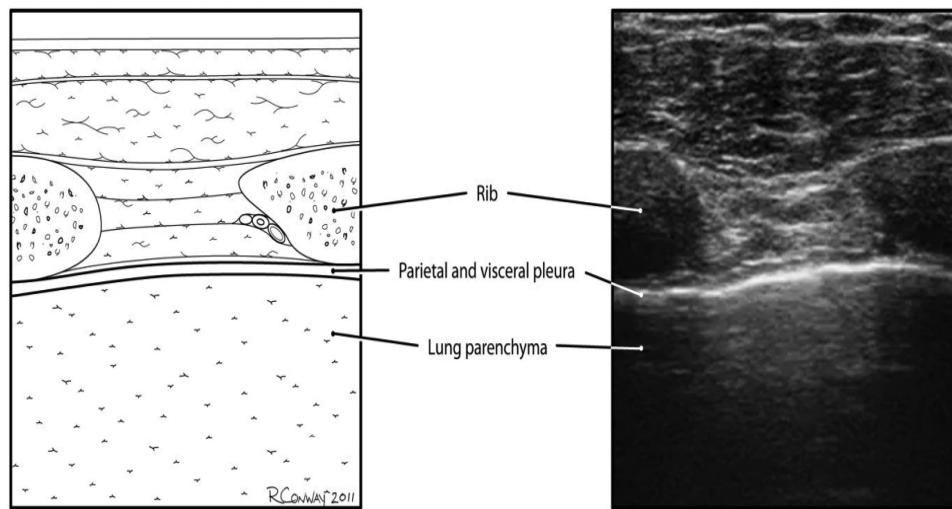
procedure. The examination should be performed in an organized fashion. For the supine patient, the ultrasound probe is positioned on the anterior chest wall to generate a longitudinal image of the “pleural line” (fig. 1). This pleural line represents apposition of the visceral and parietal pleura and a small amount of interpleural fluid. The interfaces of these components reflect ultrasound. This pleural line is located at a depth of between 2 and 3 cm and is bordered by rib images at each intercostal space (fig. 2). During breathing, the visceral pleura moves with respect to the parietal pleura, creating a sliding motion in the image. This is the “lung-sliding” sign (see Supplemental Digital Content 1, <http://links.lww.com/ALN/A765>). Because air does not reflect ultrasound, a pneumothorax will disrupt the lung-sliding sign (see Supplemental Digital Content 2, <http://links.lww.com/ALN/A766>). The parietal pleura border may still be seen, but the visceral pleura will not be visible. Thus, the presence of lung sliding rules out pneumothorax.

Studies have shown the finding of lung sliding to be a highly sensitive indicator to rule out pneumothorax.<sup>3,7-10</sup> Compared with portable chest x-ray, ultrasound has a higher sensitivity to rule out pneumothorax. In two published reports comparing ultrasound and chest radiographs, the sensitivity of ultrasound to rule out pneumothorax varied from 86 to 100%. The sensitivity of chest radiographs to rule out pneumothorax in these reports ranged from 28 to 75%. Although the specificity of ultrasound to confirm the presence of a pneumothorax ranged from 97 to 100%, the specificity of chest radiographs was 100%.<sup>7,8</sup> It is important to note that the absence of lung sliding is only suggestive of a pneumothorax.<sup>3,7-9</sup> Failure to identify lung sliding may result from poor technique, inappropriate ultrasound probe frequency, or the presence of dynamic noise filters. In patients with emphysema or pleural calcifications, acoustic artifacts can limit visualization of the pleural line. Loss of lung compli-

## Discussion

The ability to timely diagnose a pneumothorax is an important skill for the anesthesiologist. Pneumothorax can occur from various causes such as upper extremity blocks, subclavian or internal jugular vein central lines, mechanical ventilation barotrauma, surgical entry into the pleural space, or trauma patients who develop pneumothorax with institution of positive-pressure ventilation. Traditionally the chest radiograph has been the primary method for the diagnosis of pneumothorax. In the cases described, the anesthesiologist utilized ultrasound as the first imaging modality to assess for pneumothorax.

Thoracic ultrasound detection of pneumothorax has been reported in emergency medicine,<sup>1,2</sup> critical care,<sup>3,4</sup> and military literature.<sup>5,6</sup> The ultrasound examination of the chest is simple, economical, expeditious, and free of radiation. Using ultrasound to specifically rule out pneumothorax allows clinicians to forego obtaining a chest x-ray to make this diagnosis. The cost of obtaining the chest x-ray is bypassed, and the patient is not exposed to the radiation associated with the



**Fig. 2.** This illustration shows an optimal ultrasound window to observe lung sliding. Upon inspiration, lung sliding manifests as a back-and-forth, to-and-fro movement of the lung parenchyma at the visceral-parietal pleura border. Reprinted with permission from Ryan K. Conway, M.D., creator of the figure.

ance, as occurs with atelectasis, pleural fibrosis, and pleural symphysis, may also result in the absence of lung sliding, although no pneumothorax is present.<sup>9</sup> Thus, chest radiograph assessment is still the gold standard to confirm pneumothorax when lung sliding is absent.

Key features of ultrasound include its immediate availability and ease of application. In the first case, the patient's cardiorespiratory status was sufficiently stable to wait for chest radiograph before proceeding with chest tube placement. In the second case, rapidly deteriorating respiratory status necessitated needle thoracostomy shortly after a left-sided pneumothorax was suggested by transthoracic ultrasound. In this situation, bilateral rib fractures had already established a high degree of suspicion for pneumothorax development, and left thoracotomy was the planned procedure. The key utility of transthoracic ultrasound was to rule out pneumothorax on the right.

The true value of transthoracic ultrasound for pneumothorax detection remains to be characterized. Effectiveness depends on the operator's skills, including familiarity with optimal windows, depth, gain, and landmark identifications. In our cases, the anesthesiologists had prior experience with transesophageal and transthoracic ultrasound. Because of high pretest probability, there was also significant suspicion for pneumothorax before transthoracic ultrasound examination. Further investigation is needed to determine the efficacy of ultrasound to detect pneumothorax among anesthesiologists with different levels of expertise.

In summary, we report two cases of intraoperative pneumothorax in which transthoracic ultrasound was utilized as the initial imaging modality and contributed to correct diagnosis and timely treatment. In conjunction with clinical in-

formation, transthoracic ultrasound can provide critical information pertaining to diagnosis of a pneumothorax in the operation room setting.

## References

1. Stone MB: Ultrasound diagnosis of traumatic pneumothorax. *J Emerg Trauma Shock* 2008; 1:19–20
2. Wilkerson RG, Stone MB: Sensitivity of bedside ultrasound and supine anteroposterior chest radiographs for the identification of pneumothorax after blunt trauma. *Acad Emerg Med* 2010; 17:11–7
3. Lichtenstein DA, Menu Y: A bedside ultrasound sign ruling out pneumothorax in the critically ill: Lung sliding. *Chest* 1995; 108:1345–8
4. Bouhemad B, Zhang M, Lu Q, Rouby JJ: Clinical review: Bedside lung ultrasound in critical care practice. *Crit Care* 2007; 11:205–13
5. Madill JJ: In-flight thoracic ultrasound detection of pneumothorax in combat. *J Emerg Med* 2010; 39:194–7
6. Monti J, Younggren B, Blankenship R: Ultrasound detection of pneumothorax with minimally trained sonographers: A preliminary study. *J Spec Oper Med* 2009; 9:43–6
7. Wilkerson RG, Stone MB: Sensitivity of bedside ultrasound and supine anteroposterior chest radiographs for the identification of pneumothorax after blunt trauma. *Acad Emerg Med* 2010; 17:11–7
8. Rowan KR, Kirkpatrick AW, Liu D, Forkheim KE, Mayo JR, Nicolaou S: Traumatic pneumothorax detection with thoracic ultrasound: Correlation with chest radiography and CT—initial experience. *Radiology* 2002; 225:210–4
9. Lichtenstein DA, Mezière G, Lascols N, Biderman P, Courret JP, Gepner A, Goldstein I, Tenoudji-Cohen M: Ultrasound diagnosis of occult pneumothorax. *Crit Care Med* 2005; 33:1231–8
10. Lichtenstein D, Mezière G, Biderman P, Gepner A: The comet-tail artifact: An ultrasound sign ruling out pneumothorax. *Intensive Care Med* 1999; 25:383–8