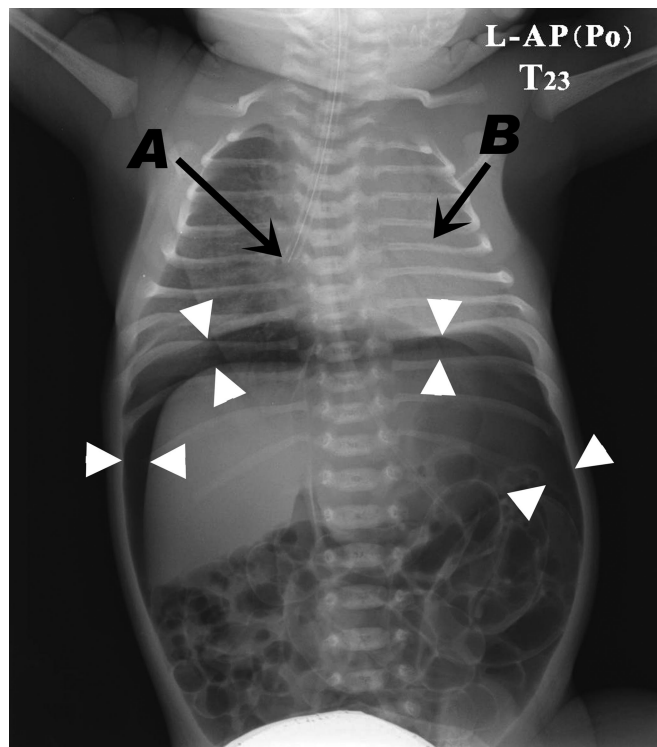


Two Complications of Tracheal Intubation in a Neonate: Gastric Perforation and Lung Collapse

Jae Jun Lee, M.D.,* Byoung Yoon Ryu, M.D., Ph.D., Ji Su Jang, M.D., Sung Mi Hwang, M.D., Ph.D.

* Department of Anesthesiology and Pain Medicine, School of Medicine, Hallym University, Chuncheon, Korea

iloveu59@hallym.or.kr



AN infant delivered in a private hospital after 33 weeks' gestation weighed 2,050 g, had persistent tachypnea, and had associated hypoxia requiring intubation. After three esophageal intubations, the neonate's trachea was successfully intubated. Despite mechanical ventilation, the infant had persistent tachycardia, hypoxemia (80–90% oxygen saturation) and a distended abdomen. A preoperative radiograph of this child shows the endotracheal tube tip in the right main bronchus (*arrow A*), atelectasis of the entire left lung (*arrow B*), pneumoperitoneum (*white arrows*), and increased abdominal gas. At surgery, a 1.5-cm perforation of the anterior wall of the lesser curvature of the stomach was identified and repaired.

The radiograph emphasizes critical complications that can occur during airway management of a neonate. Inadvertent esophageal intubation is one of the most common causes of neonatal intubation failure, which can lead to catastrophic consequences.¹ This condition can be rapidly detected by using end-tidal carbon dioxide monitoring, because it is the single most useful method in confirming endotracheal tube position.² In this neonate, gastric perforation likely occurred as a result of distension associated with positive pressure ventilation after esophageal intubation. Endobronchial intubation is another common problem associated with airway management in

a neonate. This child's atelectasis likely developed after main stem intubation, when the endotracheal tube depth was noted to be 11 cm. As a guide to proper tracheal placement of an endotracheal tube, 1-, 2-, or 3-kg babies are intubated to a depth of 7, 8, or 9 cm, respectively.³

These two complications reinforce the need for specialized training and experience in neonatal airway management.

References

1. Bhende MS: End-tidal carbon dioxide monitoring in pediatrics: Clinical applications. *J Postgrad Med* 2001; 47:215–8
2. Sullivan KJ, Kissoon N, Goodwin SR: End-tidal carbon dioxide monitoring in pediatric emergencies. *Pediatr Emerg Care* 2005; 21:327–32; quiz 333–5
3. Tochen ML: Orotracheal intubation in the newborn infant: A method for determining depth of tube insertion. *J Pediatr* 1979; 95:1050–1