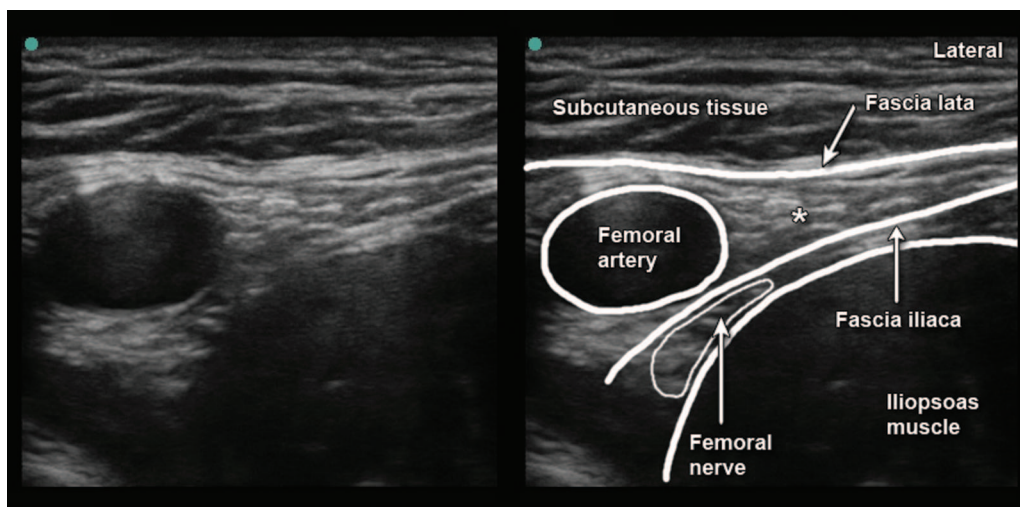


# Ultrasonographic Identification of an Anomalous Femoral Nerve

## *The Fascia Iliaca as a Key Landmark*

Ki Jinn Chin, F.R.C.P.C.,\* Cyrus Tse, B.Sc., Vincent Chan, F.R.C.P.C.

\* Department of Anesthesia, Toronto Western Hospital, University of Toronto, Toronto, Ontario, Canada  
gasgenie@gmail.com



**A**NATOMIC variation of the femoral nerve in the inguinal region is rare and its incidence unclear.<sup>1</sup> Precise localization of the femoral nerve is possible with ultrasound but requires a clear understanding of the relevant sonoanatomy. This report of an anomalous relationship between the femoral nerve and the femoral artery illustrates the importance

of the fascia lata and fascia iliaca as key ultrasonographic landmarks. A 25-yr-old man presented for a left anterior cruciate ligament repair under general anesthesia, preceded by an ultrasound-guided femoral nerve block for postoperative analgesia. We expected to find the femoral nerve in its usual position 1–2 cm lateral to the femoral artery<sup>2</sup>; however, upon identifying the fascia lata and fascia iliaca, we observed that the hyperechoic area lateral to the femoral artery (asterisk) lay superficial to the fascia iliaca and was therefore unlikely to contain the femoral nerve. The fascia iliaca was traced medially where it descended posterior to the femoral artery. We identified the femoral nerve (an ovoid structure with hyperechoic and hypoechoic elements) sandwiched between fascia iliaca and the iliopsoas muscle as expected, but located immediately adjacent to the posterolateral aspect of the femoral artery. We confirmed its identity by eliciting a quadriceps motor response with electrostimulation. The nerve was clearly delineated after injection of 20 ml 0.5% bupivacaine and a clinically successful block ensued. The patient later reported that an identical procedure performed on the same side several months previously had been prolonged and painful; this was most likely due to failure to recognize the aberrant anatomy.

### References

1. Bergman RA, Thompson SA, Afifi AK: Lumbar Plexus. In: Catalog of Human Variation. Baltimore, Urban & Schwarzenberg, 1984, p 159
2. Fingerman M, Benonis JG, Martin G: A practical guide to commonly performed ultrasound-guided peripheral-nerve blocks. *Curr Opin Anaesthesiol* 2009; 22:600–7

Dr. Vincent Chan receives ultrasound equipment support from Sonosite (Markham, Ontario, Canada), GE Healthcare (Mississauga, Ontario, Canada), and Philips Healthcare (Markham, Ontario, Canada).

Copyright © 2011, the American Society of Anesthesiologists, Inc. Lippincott Williams & Wilkins. *Anesthesiology* 2011; 115:1104