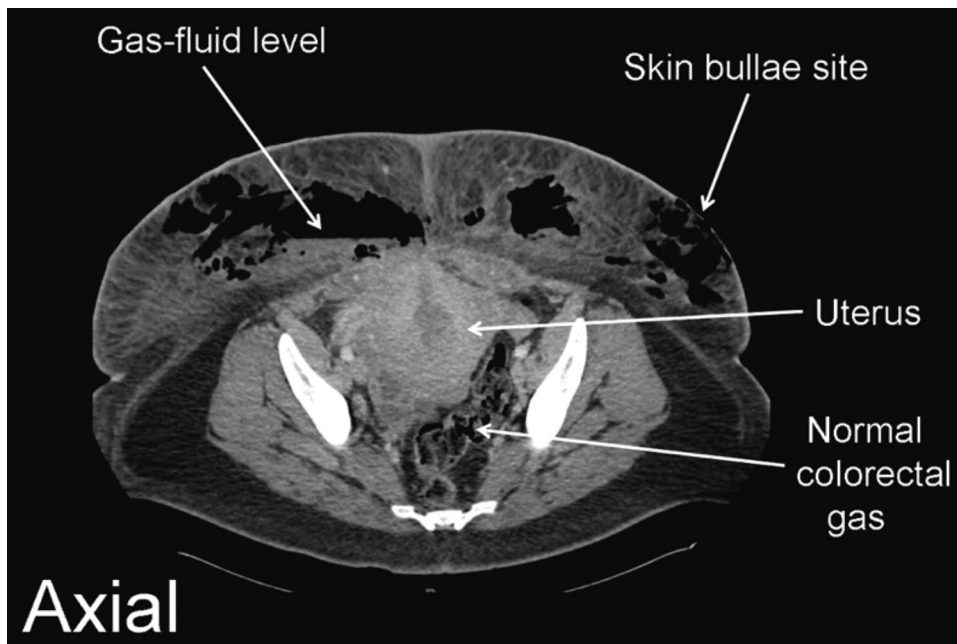


## Necrotizing Fasciitis after Cesarean Delivery

Kathleen W. Nissman, M.D., Daniel B. Nissman, M.D., Barbara L. Leighton, M.D.,\*  
Swarup S. Varaday, M.B.B.S., Ellen M. Lockhart, M.D.

\* Washington University in St. Louis School of Medicine, St. Louis, Missouri  
leightob@wustl.edu



**T**HIS 27-yr-old patient (preoperative body mass index, 32 kg/m<sup>2</sup>) presented 12 days after a repeat cesarean delivery. The patient complained of pain, swelling, and a 6 × 4-cm complex mass of blood-filled bullae on her abdominal panniculus, 7 cm from her well-healed incision. She was afebrile and not diabetic. Her hemoglobin concentration was 8.3 g/dl; leukocyte count, 23,200/ml; and creatinine concentration, 3.9 mg/dl. Bleeding, not infection, was suspected; necrotizing fasciitis was not diagnosed until the computed tomographic scan was examined (fig.). Surgical debridement required removal

of 75% of the panniculus. The patient went to intensive care intubated, on a phenylephrine infusion, with her open wound packed. She was discharged home with negative-pressure wound therapy. The wound healed completely, and the patient's renal function normalized.

Necrotizing fasciitis is a rapidly progressing, usually polymicrobial, infection of subcutaneous tissue. The infection can spread up to 2.5 cm/h, with minimal change in the overlying skin.<sup>1</sup> Erythema, swelling, and severe pain are generally seen at presentation.<sup>1</sup> Bullae and soft tissue gas (fig.) are late signs.<sup>1</sup> Anemia, hyponatremia, hypoglycemia, and increased creatinine, C-reactive protein, and leukocyte count are laboratory risk indicators for necrotizing fasciitis.<sup>1</sup> Magnetic resonance imaging or computed tomography can establish the diagnosis and guide the extensive surgical debridement.<sup>1</sup> Obesity is a risk factor for postcesarean necrotizing fasciitis, which has an incidence of 2 per 1,000 cesarean deliveries.<sup>2</sup> Because necrotizing fasciitis-associated mortality increases as the time to intervention lengthens, anesthesiologists can improve care for these patients by facilitating prompt surgical debridement.<sup>1</sup>

### References

1. Sarani B, Strong M, Pascual J, Schwab CW: Necrotizing fasciitis: Current concepts and review of the literature. *J Am Coll Surg* 2009; 208:279–88
2. Goepfert AR, Guinn DA, Andrews WW, Hauth JC: Necrotizing fasciitis after cesarean delivery. *Obstet Gynecol* 1997; 89:409–12