

# Back To Blockers?

## The Continued Search for the Ideal Endobronchial Blocker

**I**N this issue of ANESTHESIOLOGY, Mourisse *et al.*<sup>1</sup> evaluated the efficiency, efficacy, and safety of a new endobronchial blocker, the EZ-Blocker (EZ-B) (Teleflex Medical Europe Ltd, Athlone, Ireland) and compared it with a left-sided double-lumen tube (DLT) for one-lung ventilation (OLV). The EZ-B represents another step in the quest for the ideal endobronchial blocker as it joins other novel blockers that have become available clinically in the past several years.<sup>2,3</sup>

The EZ-B is a new endobronchial blocker recently introduced into clinical practice. It is a 7.0-French, quadruple-lumen, 75-cm long disposable catheter; it is Y-shaped and has two distal extensions, each of which has an inflatable cuff and a central lumen. Designed to overcome the need to steer the blocker to the selected mainstem bronchus, this bifurcated catheter straddles the carina so that each lung can be selectively deflated.<sup>4</sup> The current study evaluated two groups of 50 patients scheduled for thoracic surgery requiring OLV. One group received an appropriately sized left-sided DLT and the other was managed with the EZ-B passed through a single-lumen tube (SLT).

The authors concluded that both groups had comparable incidences of initial malposition. There were significant differences in the time needed to place the EZ-B *versus* the DLT, mainly because placing an SLT and an EZ-B requires two separate actions. The surgeons were blinded to the lung separation technique used and scored the quality of lung collapse. No difference between the two groups was found in the quality of the lung collapse after 10 min and at the completion of OLV or in the oxygenation parameters.

There was a higher incidence of postoperative new or worsened airway injury (tracheal hematoma, redness, and bronchial hematoma) in the DLT-group as assessed by fiberoptic bronchoscopy in the preintubation and postoperative examinations. It was somewhat surprising that the bifurcation of the EZ-B that overrides the carina did not injure the carina from continuous direct contact with the tracheal mucosa. The explanation for the observed lack of injury is that the EZ-B is secured between the carina and the seal at the proximal end of the tracheal tube, which prevents it from moving and damaging the carina. These differences must be considered in context.

***“The anesthesiologist should be familiar with other devices in his ‘tool box’ and use them as alternatives to [the double lumen tube].”***

It takes a longer time to position the EZ-B *versus* the DLT by an average 25 s *versus* 13 s! Although this time difference may be statistically significant it is of no clinical significance for a surgical procedure that usually lasts several hours.

The findings of the current study are in agreement with those of the evaluation of the EZ-B reported

by Kuetner *et al.*,<sup>5</sup> although those authors studied a smaller sample with only 20 patients in each group. Narayanaswamy *et al.*<sup>6</sup> evaluated the use of the Cohen blocker, the Arndt blocker, the Uniblocker, and a DLT in four groups of patients. They found that, on average, it took a few seconds longer to place the blockers but there were no differences among the groups in the placement times and the quality of the lung collapse as graded by the surgeon who was blinded to the method of lung separation.

In the study by Mourisse *et al.* study, at the end of surgery the tubes (SLT or DLT) were removed, a laryngeal mask was inserted, and a pulmonologist examined the airway fiberoptically for possible damage caused by the DLT or EZ-B. There was no difference in injuries at the vocal cords and main carina, but there were more lesions such as hematoma or redness at the tracheal and bronchial levels in the DLT group. In addition, more patients in the DLT group complained of sore throat on postoperative day 1.

Postoperative airway injuries from the use of DLT *versus* endobronchial blocker (EBB) were reported by Knoll *et al.*<sup>7</sup> Postoperative hoarseness, sore throat, and vocal cord lesions occurred significantly more frequently in the DLT group compared with the EBB group: 44% *versus* 17%, respectively. Although there have been rare reports of bronchial laceration from the insertion of a DLT, both devices are clinically safe to use for OLV. Although a bronchial laceration may be uncomfortable for the patient, it is generally transient and self-limiting.

Mourisse *et al.* neglect to address the most important limitation of the EZ-B: the inability to apply any effective suction or to remove any secretions through this blocker. The EZ-B blocker has a 7.0 French diameter, which is split into two lumens leaving a minimal diameter for each lumen. Practically, it is impossible to apply any suction through, or to apply oxygen insufflation to, the nondependent lung in

Accepted for publication December 7, 2012.

Dr. Cohen developed “The Cohen Flexi tip Endobronchial Blocker” with Cook Critical Care (Bloomington, IN). He receives lectures honoraria from Cook Critical Care.

Copyright © 2013, the American Society of Anesthesiologists, Inc. Lippincott Williams & Wilkins. Anesthesiology 2013; 118:490-3

◆ This editorial accompanies the following article: Mourisse J, Liesveld J, Verhagen A, van Rooij G, van der Heide S, Schuurbiens-Siebers O, Van der Heijden E: Efficiency, efficacy, and safety of EZ-Blocker compared to left-sided double-lumen tube for one-lung ventilation. ANESTHESIOLOGY 2013; 118:550–61.

cases of hypoxemia. For comparison, the single-lumen diameters of the other three available blockers (Arndt, Cohen, and Uniblocker) have a 9.0-French single lumen that provides a 1.6–1.8 mm diameter port for suctioning.<sup>8–10</sup>

When OLV is being considered, the use of an EBB may offer several advantages. Until relatively recently, the only independent blocking device available to provide OLV was the Fogarty embolectomy catheter. This catheter was less-than-ideal because it lacked a directing mechanism, had no central channel, and had a high-pressure, low-volume cuff. In modern thoracic anesthesia practice, three independent 9-French EBBs have been available, all of which have a steering mechanism and a patent 1.-mm lumen. The lumen allows the application of suction to facilitate the collapse of the lung or insufflation of oxygen to the nondependent lung to improve oxygenation during OLV. For positioning the Arndt blocker uses a wire-guided mechanism, whereas the Cohen blocker has a rotating wheel that enables it to flex the tip of the blocker. Both blockers use a multiport adapter. The Arndt blocker is also available in 7-French and 5-French sizes for small adults and the pediatric population. More recently, the Uniblocker, which has a molded curve similar to a hockey stick, was introduced into clinical practice. It is essentially the same blocker used in the Univent tube now made available as an independent blocker. The EZ-B is the latest addition to the family of EBBs. Indeed, over the past 10 yr more newly designed EBBs have been introduced to clinical practice, than new designs of DLT.<sup>11</sup>

The main issue is not whether the EBB is better than the DLT for lung isolation, or *vice versa*. Neither is the question which of these devices provides superior lung separation. That can be answered by the individual practitioner's experience and comfort using the devices. The issue is that practicing anesthesiologists should recognize that the DLT is not the only means of providing lung separation. There are alternatives available for the practitioner. Furthermore, there are many clinical situations where the use of an EBB may be the preferred choice.<sup>12</sup>

For the most part, DLT is used for intrathoracic procedures to provide a still surgical field for the surgeon. This is particularly important during the widespread use of video-assisted thoracoscopic procedures in modern thoracic surgery. These procedures can be effectively and safely performed using EBBs. There are several clinical settings in which the use of a DLT is mandatory, for example, all procedures that require lung isolation and the nondiseased contralateral lung must be protected from life-threatening contamination. These include the presence of massive bleeding, sepsis, and pus or bronchopulmonary lavage. The seal provided by the EBB cuff is low-pressure, high-volume, which is less reliable than that of a DLT when the endobronchial catheter occupies most of the lumen of the mainstem bronchus.

If a tumor mass occupies the mainstem bronchus or a sleeve resection is planned that requires that bronchus to be isolated, a contralateral DLT should be placed. Bilateral procedures such as a double lung transplant, or bilateral

sympathectomy should be managed using a DLT. Thoracoabdominal aneurysm repair, which may involve significant bleeding from the lung and which requires extensive pulmonary toilet, should be managed with a DLT.

Double-lumen tubes are stiff, bulky, and often difficult to insert and position. In addition, a patient's airway that is considered easy for insertion of a single-lumen tube may present a challenge for a DLT insertion. Anesthesiologists may face the need to use an alternative method to provide lung separation. One of the most significant advantages of the EBB is the elimination of the need to change the tube several times during the procedure with an unprotected airway. Often a flexible bronchoscopy is initially performed through an 8.0-mm SLT. It is then replaced with a DLT and, if at the end of the procedure, the patient requires ventilatory support, the DLT needs to be replaced with an SLT. Depending on the extent and duration of the surgical procedure, an airway, initially not classified as difficult, may become difficult as a result of facial edema, secretions, and laryngeal trauma from the initial intubation.

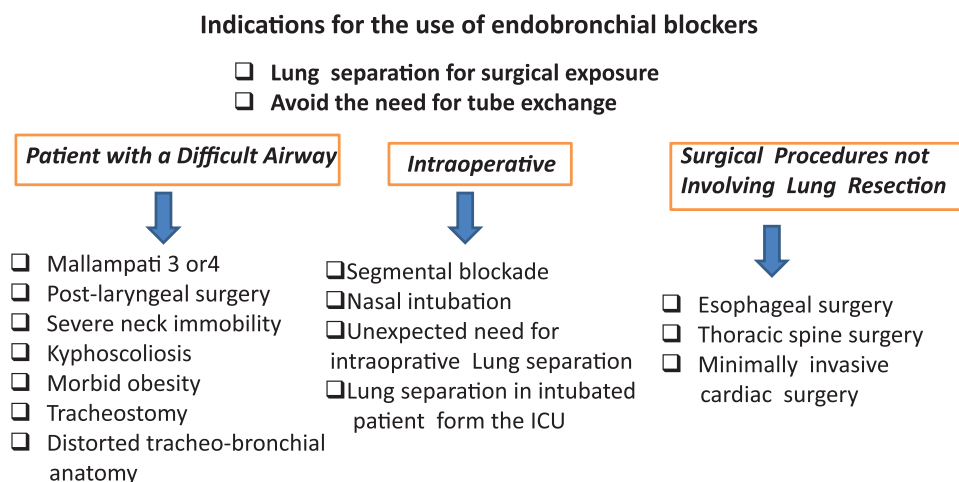
There are many other clinical circumstances where use of an EBB may be advantageous (fig. 1). Patients with morbid obesity or a difficult airway, often undergo procedures that require lung separation. Tracheal intubation of patients with limited mouth-opening, protruding teeth, large tongues, limited neck extension, and small glottic openings may be difficult, and even more so when it comes to placement of a DLT.

Other groups of patients who may benefit from EBB rather than a DLT are those with distorted tracheobronchial tree from previous lung resection, or present for surgical procedures not involving lung resection that requires a collapsed lung for optimal surgical exposure such as esophagectomies, tumors of the thoracic spine, and minimally invasive cardiac surgery. These procedures are frequently associated with a large fluid shift and extended surgical time and often require postoperative ventilatory support. If a DLT was used, it would be necessary to change to an SLT because DLTs are too bulky to keep for an extended period of time.<sup>3,13</sup>

Patients with an existing tracheostomy are best managed with an EBB through the stoma rather than inserting a rigid large-diameter DLT.<sup>3,14</sup> In patients with severe respiratory compromise or with a previous lung resection in the dependent lung, and who cannot tolerate OLV, it is possible to provide selective lobar blockade using an EBB to prevent the collapse of the entire lung.<sup>3,15</sup>

Finally, a patient may arrive at the operating room from the intensive care unit intubated or may already be in the lateral position when an unexpected need for lung collapse arises intraoperatively. In such situations, insertion of EBB would be the best option to avoid changing of the existing SLT.

The use of EBBs is increasing worldwide, and there are several issues that need to be addressed when considering their use. The most important issue is the practitioner's level of comfort with the use of EBB. Like any other device, there is a significant learning curve for the use of the EBB so that one should gain experience on routine elective cases rather



**Fig. 1.** The indications for endobronchial blockers. ICU = intensive care unit.

than on rare emergency occasions. It is unlikely that one would use an intubating laryngeal mask airway, perform an awake fiberoptic intubation, or use a video laryngoscope for the first time on a patient with a difficult airway. The same would apply to the use of the EBB.

The management of an EBB requires close attention. The EBB tends to move and dislocate more often than a DLT. That is not a problem with left-sided blockade because there is at least a 5-cm distance between the main carina and the bronchial carina, which provides a comfortable margin of safety. However, right-side blockade has a narrow margin of safety. The EBB cuff must be placed in proximity to the carina to block the right upper lobe orifice and can be dislocated easily into the trachea. During lobectomy, if the lung is accidentally expanded before the resection of the lobar artery, it may result in significant lung engorgement and render the resection difficult. In addition, because the EBB cuffs are low-pressure, high-volume cuffs, there is a need to avoid high peak airway pressures. These ideally should be kept below 30 mmHg to prevent air from entering the collapsed lung. In addition, many surgeons are not familiar with the EBB and are often reluctant to try something new, or they may have had a negative experience with EBBs in the past when management of OLV was less than ideal.

Another issue is the need for a fiberoptic bronchoscopy. This is a must for placing an EBB, whereas the DLT can be positioned by clinical signs. Although it is routine practice to confirm the DLT position by fiberoptic bronchoscopy, this is not absolutely necessary. Unfortunately, in many parts of the world, a 4.0-mm fiberscope that is needed to be passed alongside of the EBB within the SLT, is not available. This remains one of the most limiting factors for the routine use of an EBB.<sup>16,17</sup>

The cost of the EBB can be two to three times that of a DLT. In the current economic environment, equipment expenses are a major consideration in a department's budget. However, the additional cost of an EBB is insignificant compared with the total cost of lung surgery. The risks/benefits

for the patient and the best quality of care should be the primary factor in choosing the appropriate device for a particular patient.

In summary, Mourisse *et al.*, described their experience with the new EZ-B. At present, there is limited clinical experience with this device. However, based upon their data, the EZ-B seems to be effective and safe during OLV. Double-lumen tubes have been used for more than 50 yr. They are and will remain the definitive standard for lung separation. However, there are many clinical situations where DLT may not be the method of choice. The anesthesiologist should be familiar with other devices in his "tool box" and use them as alternatives to DLT. Endobronchial blockers can be safely and effectively used for simple procedures such as a brief wedge resection, or for more complex extended procedures such as lobectomy or pneumonectomy.<sup>18</sup> The fact that there are several EBBs now available for clinical use is a reflection of the quest for the ideal blocker. It is beneficial to the patient to avoid changing tubes and exposing them to a period of an unprotected airway. Whether a DLT or an EBB is used, it is ultimately the level of familiarity and comfort of the anesthesiologist and surgeon to decide what is best for the management of their patient.

**Edmond Cohen, M.D.**, Department of Anesthesiology, Mount Sinai Medical Center, New York, New York. edmond.cohen@msnyuhealth.org

## References

1. Mourisse J, Liesveld J, Verhagen A, Rooij GV, Heide S, Schuurbiens-Siebers O, Van der Heijden, E: Efficiency, efficacy and safety of EZ-blocker compared to left-sided double-lumen tube for one-lung ventilation. *ANESTHESIOLOGY* 2013; 118:550–61
2. Brodsky JB, Lemmens HJ: Left double-lumen tubes: Clinical experience with 1,170 patients. *J Cardiothorac Vasc Anesth* 2003; 17:289–98
3. Cohen E: Pro: The new bronchial blockers are preferable to double-lumen tubes for lung isolation. *J Cardiothorac Vasc Anesth.* 2008; 22: 920–4

4. Mungroop HE, Wai PT, Morei MN, Loef BG, Epema AH: Lung isolation with a new Y-shaped endobronchial blocking device, the EZ-Blocker. *Br J Anaesth* 2010; 104:119–20
5. Ruetzler K, Grubhofer G, Schmid W, Papp D, Nabecker S, Hutschala D, Lang G, Hager H: Randomized clinical trial comparing double-lumen tube and EZ-Blocker for single-lung ventilation. *Br J Anaesth* 2011; 106:896–902
6. Narayanaswamy M, Lacroix M, Kanellakos G, McRae K, Darling G, Johnston M: A clinical comparison of three designs of bronchial blockers with double-lumen tubes for lung isolation. *Anesth Analg* 2009; 108:1097–101
7. Knoll H, Ziegeler S, Schreiber JU, Buchinger H, Bialas P, Semyonov K, Graeter T, Mencke T: Airway injuries after one-lung ventilation: A comparison between double-lumen tube and endobronchial blocker. A randomized, prospective, controlled trial. *ANESTHESIOLOGY* 2006; 105:471–7
8. Campos JH: Progress in lung separation. *Thorac Surg Clin* 2005; 15:71–83
9. Prabhu MR, Smith JH: Use of the Arndt wire-guided endobronchial blocker. *ANESTHESIOLOGY* 2002; 97:1325
10. Cohen E: Recommendations for airway control and difficult airway management in thoracic anesthesia and lung separation procedures. Are we ready for the challenge? *Minerva Anesthesiol* 2009; 75:3–5
11. Campos JH, Hallam EA, Van Natta T, Kernstine KH: Devices for lung isolation used by anesthesiologists with limited thoracic experience: Comparison of double-lumen endotracheal tube, Univent torque control blocker, and Arndt wire-guided endobronchial blocker. *ANESTHESIOLOGY* 2006; 104:261–6
12. Cohen E: The Cohen flexitip endobronchial blocker: An alternative to a double lumen tube. *Anesth Analg* 2005; 101:1877–9
13. Campos JH: Which device should be considered the best for lung isolation: double-lumen endotracheal tube versus bronchial blockers. *Curr Opin Anaesthesiol* 2007; 20:27–31
14. Andros TG, Lennon PF: One-lung ventilation in a patient with a tracheostomy and severe tracheobronchial disease. *ANESTHESIOLOGY* 1993; 79:1127–8
15. Sumitani M, Matsubara Y, Mashimo T, Takeda S: Selective lobar bronchial blockade using a double-lumen endotracheal tube and bronchial blocker. *Gen Thorac Cardiovasc Surg* 2007; 55:225–7
16. Klein U, Karzai W, Bloos F, Wohlfarth M, Gottschall R, Fritz H, Gugel M, Seifert A: Role of fiberoptic bronchoscopy in conjunction with the use of double-lumen tubes for thoracic anesthesia: A prospective study. *ANESTHESIOLOGY* 1998; 88:34
17. Seymour AH, Prasad B, McKenzie RJ: Audit of double-lumen endobronchial intubation. *Br J Anaesth* 2004; 93:525–7
18. Klafuta J: Bronchial blockers offer certain advantages for lung separation. *Amer Soc Cardiovasc Anesthesiol*; 2002