

Axial Inclination of Teeth in Extraction Cases

ROBERT H. W. STRANG, M.D., D.D.S.
Bridgeport, Connecticut

I believe that I am safe in saying that the most important reasons for tooth extraction in the treatment of malocclusion can be summarized as follows: to assure stability in the final result; to increase functional efficiency; to improve esthetics and as an important prophylactic measure, thus adding to longevity of the teeth and their supporting structures.

I am glad that the sub-topic "*Axial Inclination of Teeth in Extraction Cases*" has been assigned to me for, with the passing of time, I have become convinced that root movement, for the production of correct axial adjustment, is far more important than most operators realize. Hence it has been my rule to have most of my finishing adjustments directed toward attaining correct root positioning as well as crown locating. There is no question but that stability in the completed case depends to a great extent upon the correct axial adjustment of each individual tooth. Good esthetics also demands that the incisor teeth be properly inclined.

The axial positioning of dental units, both in normal and in malocclusion, is purposeful, just as is arch form and tooth alignment. It is dictated by force balance, both functional and environmental. We have come to recognize the influence of these two factors in treatment, as far as arch form and tooth alignment is concerned. Hence we no longer move teeth into positions wherein these balanced forces are violated. In other words, denture expansion is no

longer considered practical if stability in the final result is to be acquired.

On the other hand, the writer has reviewed many cases treated by expert operators and noted that incisors have been retained with lingual axial inclination quite in evidence; with canines in distal axial inclination; with premolars in marked mesial axial inclination and molars either distally, mesially, lingually or buccally inclined to the extent that functional and environmental forces are violated as far as balance is concerned. Undoubtedly the lingual axial inclination of treated incisors, the distal axial inclination of canines and the mesial axial inclination of second premolars are the most frequent manifestations of failures to establish correct axial inclinations in completed cases.

Let us analyze the danger of such oversights. All of these teeth are eventually going to readjust themselves to the lines of the force in action upon them. *They are going to do this by crown movement and not by root shifting.*

In the case of the incisors, the crowns will move labially, usually the maxillary more than the mandibular because of the difference in normal axial positioning of these two groups of teeth. Hence a space will appear, lingually to the lingual surface of the maxillary crowns. This will afford a favorable wedging area for the lower lip in some cases and this space will gradually enlarge, upsetting esthetic improvement.

In the canine area, the uprighting of distally tipped canines will open the extraction space and coincidentally begin to usurp the incisor area, manifested in crowding and rotation of these

Read before the Twenty-fifth Anniversary Meeting of the Edward H. Angle Society of Orthodontia, Chicago, Illinois, November 1955.

latter teeth, particularly evident in the mandibular incisors. In the premolar area the greatest relapse will be manifested by a recurrence of spacing in the extraction area.

Exaggerated buccal axial inclination of maxillary buccal teeth, combined with exaggerated lingual axial inclination of mandibular buccal teeth or a reversed condition is apt to lead to eventual lingual occlusion of the maxillary buccal teeth or even a crossbite adjustment of the two dentures, the result of an effort to gain better functional efficiency. Exaggerated mesial tipping of buccal teeth encourages mesial shifting of buccal segments. Exaggerated distal tipping, on the other hand, is the least dangerous of failure to establish correct axial positioning. This is due to the fact that the subsequent uprighting of these teeth produces a forward pressure which is favorable in maintaining close proximal contact and holding the extraction space inviolate. When excessive, however, the eventual uprighting by the forward movement of these molar crowns may cause forward shifting of entire buccal segments, manifested

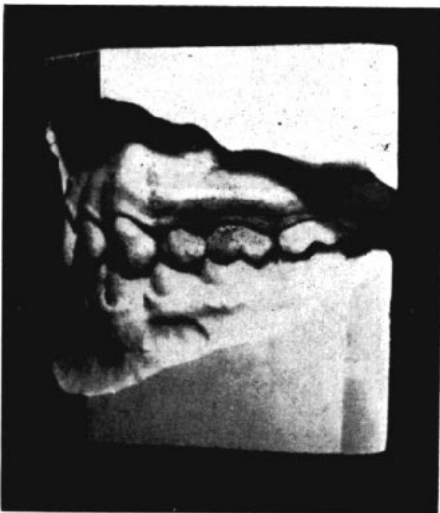

Fig. 1 Faulty axial positioning of maxillary and mandibular canines.

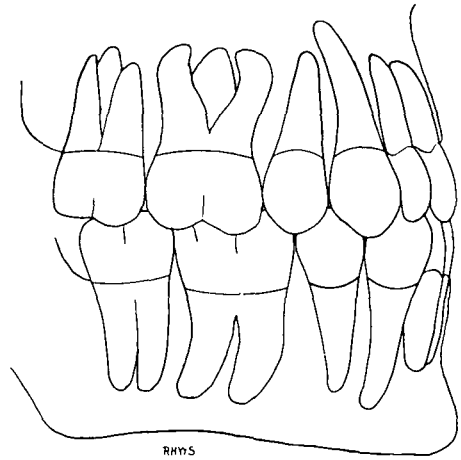


Fig. 2 Diagram of correct axial positioning at end of extraction treatment.

by the canines overlapping the lateral incisors, by jumbling and rotating of the incisor teeth or by blocking out of premolar teeth.

Technical procedures, associated with root movement, demand expert appliance manipulation. Crown positions must often be held at zero which necessitates both lingual torque action and lingual crown pressure applied to the incisor teeth, mesial tipping action and distal crown pressure against canine teeth, distal tipping bends and distal crown force against premolars and mild

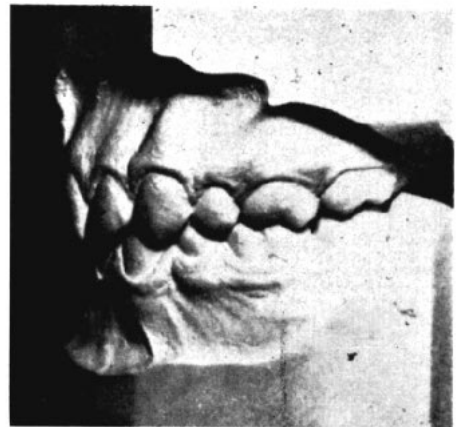


Fig. 3 Correct axial positioning in an extraction case.

mesial crown force against the molar teeth. Fortunately, with bracket location where it normally should be placed, force applied for root movement is advantageously in action mostly upon the roots. Yet, it must be remembered that resistance to root movement is far and beyond that against crown movement. Hence the necessity of always applying additional anchorage to the crown portion of certain of these teeth. Consequently either intermaxillary elastics or action derived from an occipital anchorage is a very essential adjunct to torque or tipping adjustments of the incisor, canine and premolar crowns in order to keep their crowns from moving forward. Uprighting the molar teeth, on the other hand, should not be coincidentally attempted with the root movement in action upon the above mentioned dental units as a mild forward movement of the molar crowns is advantageous in establishing close proximal contact and thus preventing space opening between second premolars and canines. Furthermore, from previously established anchorage, the roots of the molar teeth are already well forward so we are only concerned with the crown movement of these dental units.

If the molars of the maxillary denture are in exaggerated buccal inclination, lingual torque action combined with buccal crown force must be the adjustment. In the mandibular denture the molars are most apt to be in hyperlingual axial inclination and to overcome this the adjustment should be buccal torque force combined with lingual crown action. In using buccal or lingual torque on the molar teeth, the operator must be sure that the archwire fits the buccal tubes snugly. Far too often, the fit is very loose and hence no results are obtainable. At times the .0215 x .028 archwire is wisely used for this action.

I do not feel that I can emphasize too strongly the importance of carefully analyzing the relationship in the vertical plane of that portion of the tooth that is invisible to the eye, to the segment that is plainly in view. Nature abhors imbalance of structures and to leave the dental units in an axial position of faulty balance is courting instability in the final product of treatment and greatly detracting from desirable esthetics.

114 State St.