

Comparative Integumental Relationships

LEONARD A. ALTEMUS, D.D.S., D.Sc.

Washington, D.C.

The integumental or soft tissue mass of the human face is of importance and concern to the orthodontist. The soft tissue covers the dentoskeletal complex and can be influenced by orthodontic treatment. Variations of this soft tissue mass have been reported by Subtelny,¹ Bowker and Meredith,² Burstone³ and others. This variability has no relationship to the configuration of the hard tissues. The correction of occlusal disharmonies alone is not always sufficient for optimum results from orthodontic treatment because the denture relates differently to the soft tissue profile in different individuals. This is especially true where diverse racial groups are being treated. The races of man are classified in part on the basis of their facial features. Several of these features are especially important to the orthodontist for they occur in the dental area of the face. Measurable differences have been reported in the dentoskeletal configurations of the heads and faces of various North American racial groups.⁴ There are also observable differences in the integumental or soft tissue mass of these racial groups. It was the purpose of this investigation to consider various methods of measuring this soft tissue profile and to make certain comparisons of these measurements and, if there are measurable differences, to present these new and different measurements as guides for use in orthodontic diagnosis and treatment planning.

The literature was reviewed and the methods of Burstone³ were selected.

College of Dentistry, Howard University. This study was financed in part by U.S. Public Health Service Grant Number 331-331 C5.

This selection was made for several reasons as follows: First, our samples were similar. They consisted of children of approximately the same ages who had acceptable faces. Our definition of an acceptable face was similar to our interpretation of Burstone's definition. Our cases were not chosen for beauty or for any particular criterion except that they were acceptable in the sense of being representative and not disfigured or ugly, i.e., they were average faces. Secondly, we chose Burstone's method of analysis because his measurements were predominantly in the lower face with most emphasis in the orodental area. Thirdly, Burstone used a grid as a means of presenting his extension patterns. We accept this as practical because it can be easily prepared and made a part of the orthodontic treatment records.

This study compared the soft tissue mass of the profiles of two groups of North American children of approximately the same age. One group consisted of 37 North American Caucasian children, 11 males and 26 females, aged 13.4-15.6 years. The other group consisted of 50 North American Negro children, 25 males and 25 females, aged 12-16 years. Both groups were chosen as having acceptable facial form. The group of North American Negro children had normal occlusion of their teeth. Their dentitions were complete except for the third molars and they had received no orthodontic treatment.

METHODS

Lateral headplates of the Howard group were taken in a Margolis cephalostat. Standard procedures of head

positioning and exposure were used. The exposure time was especially adapted to show the soft tissue outlines of the children's faces as well as the dentoskeletal tissues. The roentgenograms were traced and the hard and soft tissues of the profile were carefully copied. The measurements were made from the soft tissue to the adjacent hard tissue points using a common plane reference. Both horizontal and vertical measurements were used. The plane of reference for the horizontal measurements was the nasal floor (a line connecting anterior and posterior nasal spines) and a perpendicular to this plane was used as a reference for the vertical measurements. As explained by Burstone,³ these measurements do not represent exactly "thickness and length" but horizontal and vertical extensions. This method is used because of the variability in the positions of adjacent hard and soft tissue landmarks.

Horizontal extension (Fig. 1A) represents the distance in millimeters between a dental or skeletal landmark and an integumental landmark as measured along the nasal floor. The horizontal extension readings are listed below and the dental or skeletal (S) and integumental (I) landmark for each is operationally defined.

GLABELLA (I) — determined by a tangent to the forehead from a line passing through subnasale.

GLABELLA (S) — the intersection of the outer plate of the frontal bone with a horizontal line (parallel to nasal floor) drawn from frontal point (1).

SUBNASALE (I) — the point where maxillary lip and nasal septum form a definite angle. If the depression is a gentle curve, subnasale is interpreted as the most concave point in this area as measured by a line angled 45 degrees from nasal floor.

SUBSPINALE (S) — the deepest

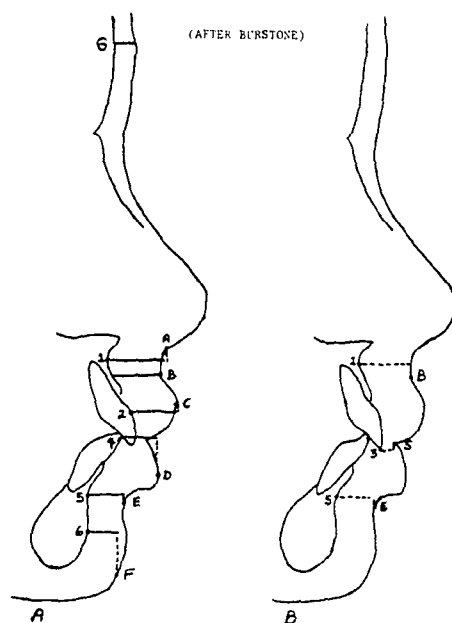


Fig. 1 Integumental and skeletal landmarks demonstrating extension measurements, A, horizontal extension, B, vertical extension. Skeletal landmarks: 1) subspinale, 2) incision superius, 3) incision inferius, 4) incision inferius, 5) supramentale, 6) pogonion. Integumental landmarks: A) subnasale, B) superior labial sulcus, C) labrale superius, D) labrale inferius, E) inferior labial sulcus, F) menton, G) glabella, S) stomion.

point between anterior nasal spine and prosthion relative to nasal floor.

SUPERIOR LABIAL SULCUS (I) — the deepest point on the upper lip as determined by a line drawn from subnasale inclined so that it forms a tangent with labrale superius.

LABRALE SUPERIUS (I) — the most prominent point on the upper lip as measured from a perpendicular to nasal floor.

INCISION SUPERIUS (S) — the most prominent point on the maxillary incisor as determined by a tangent to the incisor passing through subspinale.

LABRALE INFERIUS (I) — the most prominent point on the lower lip

TABLE I
COMPARISONS OF INTEGUMENTAL EXTENSION VALUES
OF ACCEPTABLE ADOLESCENT PROFILES

Extension Measurements	MALES				FEMALES			
	Mean		S.D.		Mean		S.D.	
	Burstone	Howard	Burstone	Howard	Burstone	Howard	Burstone	Howard
Glabella	7.0	6.6	1.11	1.17	6.6	6.5	0.82	1.22
Subnasale	18.7	16.3	2.33	2.10	16.9	15.6	1.45	1.73
Superior Labial Sulcus	16.2	17.8	1.61	2.49	14.7	16.5	1.88	2.11
Labrale Superius	15.5	16.4	1.88	3.04	12.1	14.2	1.83	2.43
Labrale Inferius	16.1	17.1	1.54	2.57	13.4	14.5	1.29	1.97
Inferior Labial Sulcus	12.9	15.1	2.20	3.11	11.6	13.0	1.31	2.01
Menton	12.8	12.7	2.19	3.67	12.2	12.6	1.85	2.77
Subspinale-Superior Sulcus	-4.4	-5.4	1.90	2.55	-3.4	-6.0	1.78	2.56
Supramentale-Inferior Sulcus	1.3	-0.13	1.69	3.48	1.6	0.76	1.94	2.86
Incision-Stomion	3.1	3.2	2.21	1.61	3.5	2.9	1.64	1.82

as determined by a perpendicular from nasal floor.

INCISION INFERIUS (S) — the most anterior point on the lower incisor determined from a line tangent to the chin and mandibular incisor.

INFERIOR LABIAL SULCUS (I) — the most concave point as measured by a line tangent to menton and labrale inferius.

SUPRAMENTALE (S) — deepest point between pogonion and infra-dentale as determined from a line tangent to lower incisor and pogonion.

MENTON (I) — most anterior point on chin determined by a line tangent to lower lip and the chin.

POGONION (S) — most anterior point on the chin as determined from a perpendicular to nasal floor.

Vertical extension (Fig. 1B) is the distance in millimeters between a dental or skeletal and integumental landmark measured along a perpendicular to nasal floor. If the integumental point is superior to the dental or skeletal one, the

reading is given a plus sign; if inferior, a minus sign.

SUPERIOR LABIAL SULCUS (I) — as above.

SUBSPINALE (S) — as above.

INFERIOR LABIAL SULCUS (I) — as above.

STOMION (I) — the juncture in the midline of the upper and lower lips.

SUPRAMENTALE (S) — as above.

INCISION SUPERIUS (S) — as above.

INTEGUMENTAL EXTENSION COMPARISONS

The mean measurements and the standard deviations for the two groups are given in Table I. These values are given separately for males and females. The mean values of glabella, incision-stomion, and menton are essentially similar with measurements of 7.0 and 6.6 millimeters for glabella, 12.8 and 12.7 millimeters for menton, and 3.1 and 3.2 for incision-stomion for the

Burstone and the Howard groups respectively. The mean value for subnasale is less for the Howard group, 16.3 millimeters compared with 18.7 millimeters for the Burstone group. The relationship of supramentale to the inferior sulcus finds the mean inferior sulcus to be 1.3 millimeters superior to supramentale in the Burstone group, and -0.13 millimeters inferior to supramentale in the Howard group. Superior labial sulcus was 17.8 to 16.2 for Howard and Burstone respectively. Labrale superius was 16.4 millimeters to 15.5 millimeters, labrale inferius was 17.1 millimeters to 16.1 millimeters, and superior sulcus was inferior to subspinale -5.4 millimeters to -4.4 millimeters. The minus readings indicate that the soft tissue points are below the

skeletal or dental landmarks.

The mean integumental extension figures for females were essentially similar to those of males. The mean relationship of superior sulcus was slightly more inferior to subspinale than in the males, -6.0 millimeters to -3.4 millimeters for the Howard and the Burstone groups respectively. Stomion was slightly less superior to incision in the females, 2.9 millimeters to 3.5 millimeters. The mean values for the Howard group are presented graphically in Figure 2. The left grid compares the means of the two groups and the right grid presents a polygon that can be used as a guide in orthodontic diagnosis and treatment planning.

DISCUSSION

A previous study of comparative tracings of the heads and faces of North American Negro and Caucasian children indicated that one of the major areas of dissimilarity between these two groups was found in the orodental area. The lips and teeth were more protrusive. These and other findings have been published.⁴ This study was planned to measure these differences and to provide certain indices that would be useful in orthodontic diagnosis and treatment planning. The mean values have been compared for two North American racial groups and the similarities and differences enumerated. These mean values are not greatly different in any category. The differences of one or two millimeters rather indicate a similarity. To show the variability of the soft tissue mass the range of the measurements for the Howard group is listed in Table II.

These data clearly indicate the wide range of individual differences in each of the areas measured. Fortunately, the extremes in each category were not found in any single child.

One of the important factors about

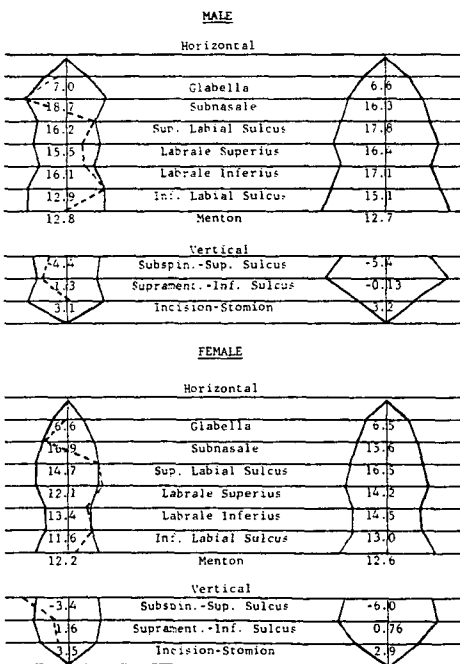


Fig. 2 Integumental extension of acceptable adolescent profiles. The left grid has the mean values of Burstone along the center line. The broken line depicts the mean values for the Howard group. The right grid has the mean values for the Howard group along the center line.

TABLE II
RANGE OF INTEGUMENTAL
EXTENSION MEASUREMENTS
(Howard Group)

Measurements	Males		Females	
Glabella	4.3 to	8.7	4.1 to	8.8
Subnasale	12.7	21.4	12.6	18.8
Superior Labial Sulcus	13.7	24.3	13.2	21.8
Labrale Superius	10.3	21.4	9.8	18.4
Labrale Inferius	11.4	22.3	11.3	17.6
Inferior Labial Sulcus	11.1	23.5	9.6	18.5
Menton	5.7	20.7	6.8	18.7
Subspinale-Superior Sulcus	—10.3	3.3	—1.0	—10.2
Supramentale-Inferior Sulcus	—5.3	7.5	—3.8	9.2
Incision- Stomion	0.8	6.6	0.0	7.0

the children in the Howard group is that they had normal occlusion. Therefore, this configuration of their soft tissue mass can be accepted as a guide to a good profile in orthodontic treatment planning. This group has shown a protrusiveness of hard and soft tissues to be normal when compared with standards prepared for North American Caucasian children. Their protrusiveness is acceptable and does not require reduction as a criterion for successful orthodontic treatment. Even so, there is a great variability within this group and each individual must be judged for harmony and balance in his face.

SUMMARY

1. Two groups of North American children were radiographed cephalometrically and their integumental profiles studied using the methods of Burstone.
2. These children had acceptable faces. They were of approximately the same age. The Howard group had normal occlusion.

3. The means for the Howard group were similar to the Burstone group in the areas of glabella, menton and incision-stomion. The means for the Howard group were larger in all other areas with the exception of subnasale; here the mean soft tissue coverage was thinner.
4. Graphic means of depicting these differences are presented.
5. There is great variability in the soft tissue covering of the faces of individuals.
6. Consideration should be given to the relationship of the soft tissues in orthodontic treatment planning.

Howard Univ.

REFERENCES

1. Subtelny, J. D.: A Longitudinal Study of Soft Tissue Facial Structures & Their Profile Characteristics, Defined in Relation to Underlying Skeletal Structures. *Am. J. Ortho.*, 45: No. 7, 481, July 1959.
2. Bowker, W.D., Meredith, H. V.: A Metric Analysis of the Facial Profile. *Angle Ortho.*, 29: No. 3, 149, July 1959.
3. Burstone, C. J.: Integumental Contour & Extension Patterns. *Angle Ortho.*, 29: 93-104, April 1959.
4. Altemus, L. A.: A Comparison of Cephalofacial Relationships. *Angle Ortho.*, 30: No. 4, October 1960.