

## Case Report KH

### Juvenile rheumatoid arthritis: a 14-year posttreatment evaluation

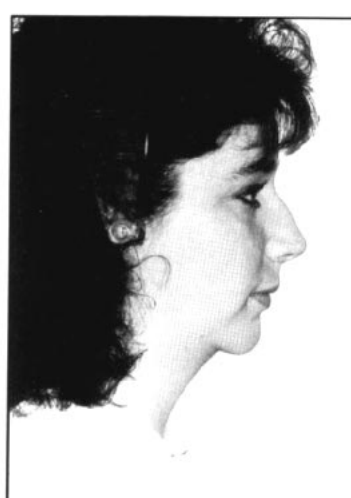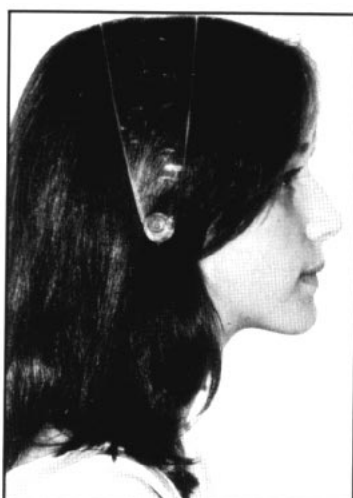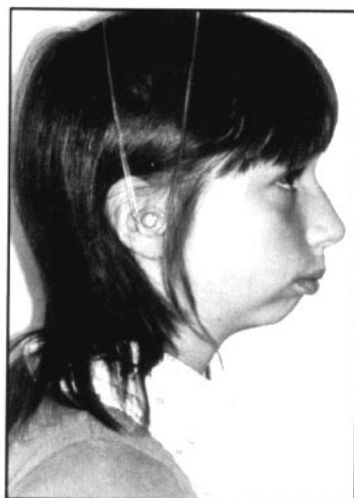Questions left unanswered when this case report was first published (*Am. J. Orthod.* 73:312-320, March 1978) can now be addressed after examination of long-term orthodontic records.<sup>1</sup> Although the original diagnosis, plan of treatment and final treatment results were satisfactory, the question of long-term stability remained unanswered due to the presence of rather marked condylar resorption. Would the condyles stabilize as the individual's rheumatoid condition moved into remission or would the mandible continue to change in its relationship to the midface, recreating a severe skeletal disharmony? A review of diagnostic records gathered 14 years after surgical advancement of the mandible provides a few of the answers to these and other questions.

By David L. Turpin, DDS, MSD

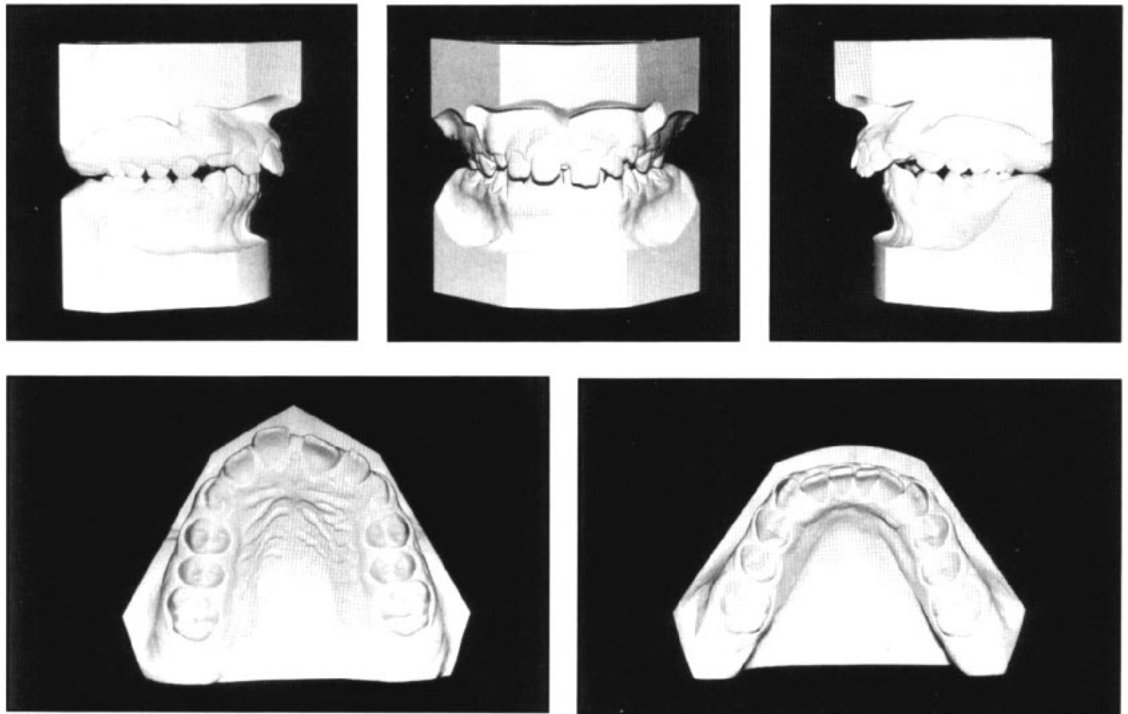
Juvenile rheumatoid arthritis (JRA) is a chronic disease of childhood, characterized by chronic synovitis at the articulation and resulting in the proliferation of epithelium, increased synovial fluid, and inflammation. Synovial inflammation can progressively damage the cartilage and subchondral bone which may, in turn, change the articular portion of the joint. Like any synovial joint in the body, the temporomandibular joint (TMJ) can be affected. Since normal condylar development is important to mandibular growth, pathologic changes in the articular surface may result in alterations in size and form of the mandible as well as the lower third of the face. Serial records have shown that

the deformity may become progressively worse as the patient matures.<sup>2-4</sup>

The precise cause of juvenile rheumatoid arthritis is still unknown. Infection, autoimmunity, heredity, and psychological stresses have been suggested as possible contributing factors. The disease affects girls three times more frequently than boys. Juvenile rheumatoid arthritis often has an unpredictable course, but the prognosis is usually favorable if early diagnosis is made and proper management instituted.<sup>5</sup> The question of stability is particularly important with individuals treated at such an early age. This makes the study of long-term records even more valuable.



**Pretreatment (11 years 8 months), posttreatment (14 years 9 months), and long-term postretention photographs show continued postretention profile changes.**



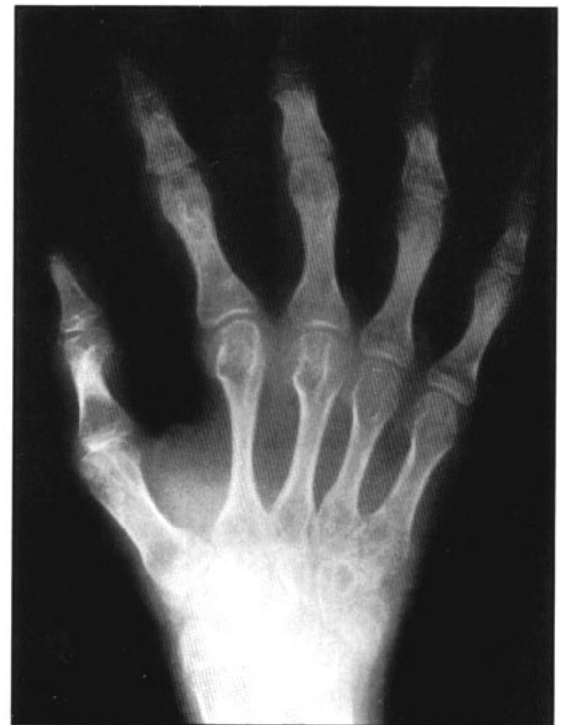Radiograph shows symmetric destruction of joints in the hand due to JRA.

#### Diagnosis and treatment plan

The following history and general clinical factors are reprinted from the original paper as published in the *American Journal of Orthodontics* in 1978.

The patient was first seen in the children's arthritis clinic at the University of Washington when she was ten years old. Her arthritis began insidiously the year before. Joints affected included the small hand joints (metacarpopharyngeal and proximal interphalangeal joints), wrists, knees, ankles, and interphalangeal joints of the toes. Sacroiliac joint films were normal. Micrognathia was noted, although there was no clear history of temporomandibular joint pain. Tests for rheumatoid factors and antinuclear antibodies were negative. The patient responded to salicylate therapy and eventually experienced remission of her arthritis, with no evidence of increased joint destruction or loss of function. Periodic slit-lamp examinations revealed no evidence of iridocyclitis; nor did she have fevers or extra-articular manifestations of juvenile rheumatoid arthritis.

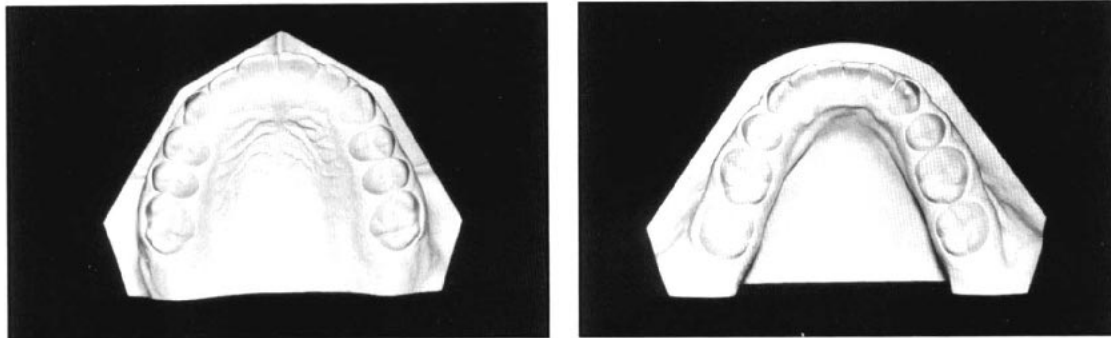
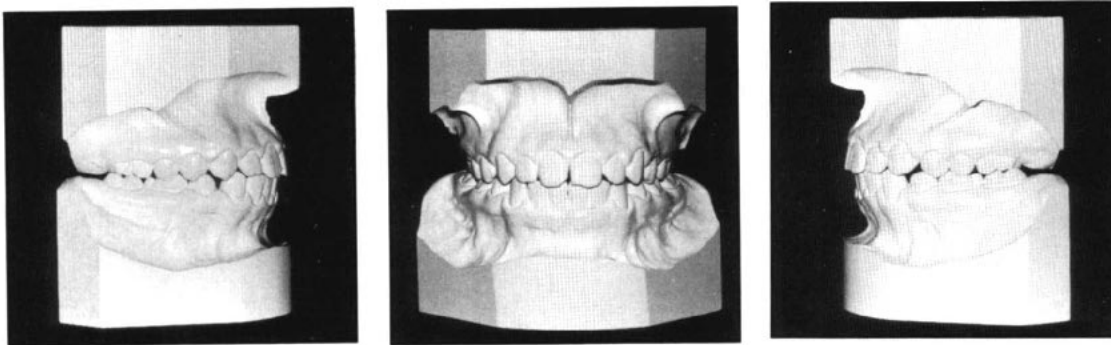
Clinical examination of the patient at the age of 11 years 8 months revealed her to be of slender, prepubertal stature. The most striking clinical feature was the markedly retrusive appearance of the lower jaw. In contrast to relatively normal midfacial growth and development, the mandible appeared small, both vertically and anteroposteriorly. The relationship of the maxillary incisors and upper lip of the midface and nose was esthetically acceptable. The patient



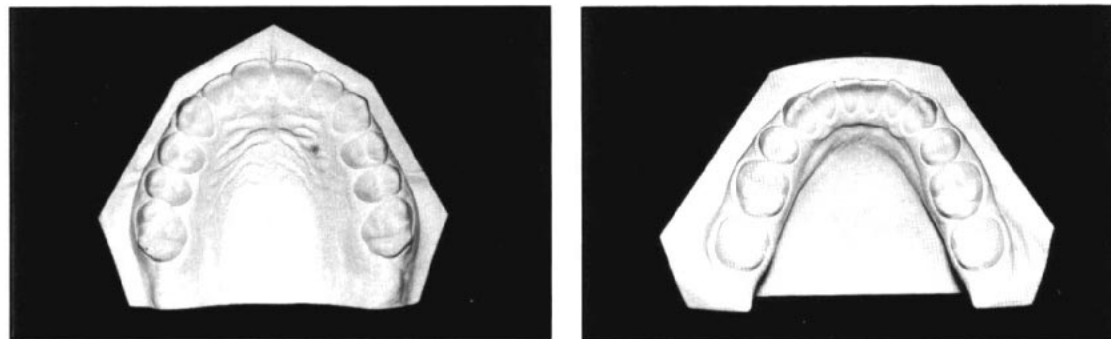
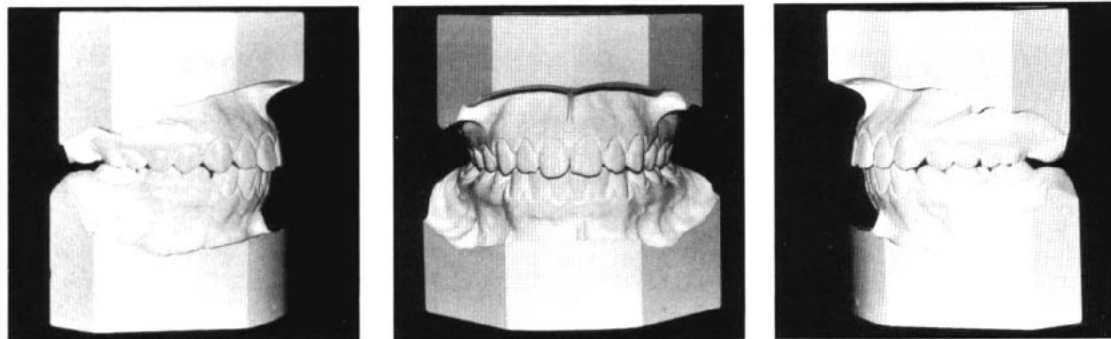
had an acute nasolabial angle with a satisfactory vertical relationship of the maxillary incisors to the upper lip. However, when compared to the mandible, the maxillary incisors appeared to be protrusive. The mandible was small and the angle between the submental soft tissues and the anterior surface of the neck was obtuse. This combination of mandibular deformity and compromised soft-tissue contours resulted in a severely retrognathic profile.

Palpation of the posterior borders, angles,

Posttreatment study casts, 14 years 9 months



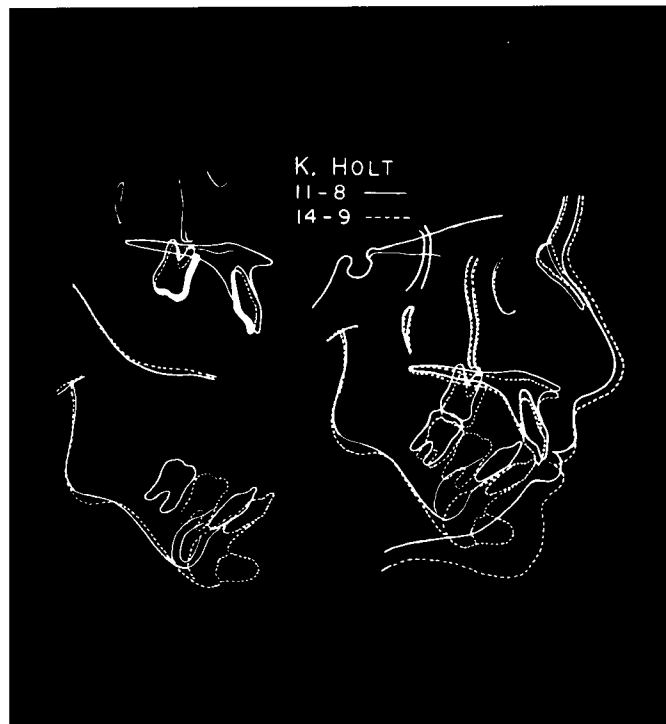
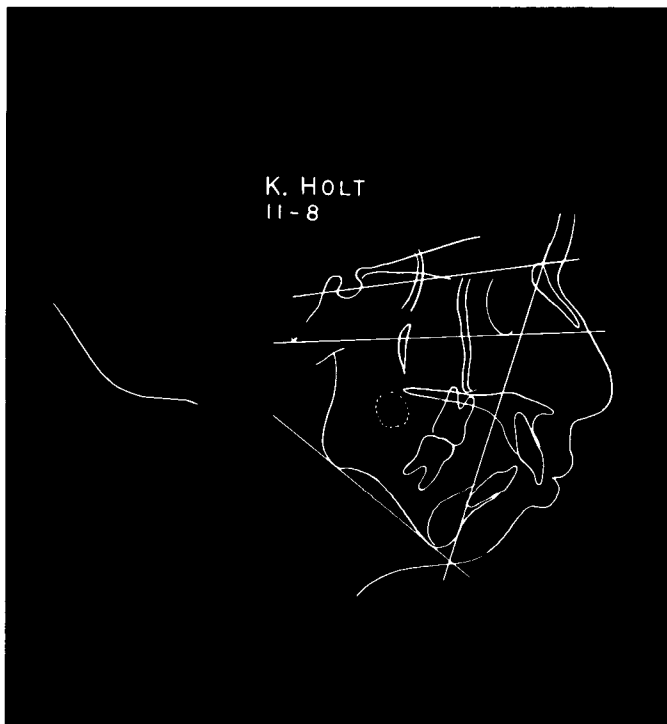
Postretention study casts, 27 years 5 months



and inferior borders of the mandible showed the vertical rami to be foreshortened and the angles obtuse. The inferior border of the mandible was concave with the broad curve of "antegonial notching" that is characteristic of patients with juvenile rheumatoid arthritis.<sup>6</sup> Palpation of the temporomandibular joints with the patient opening and closing revealed motion bilaterally. However, the condyles were difficult to palpate unless a finger was inserted into the external auditory canals. There was no limitation of inci-

sal opening, and the border movements and protrusion of the mandible appeared to be within normal limits.

Intraoral examination revealed a bilateral Class II molar relationship, slightly spaced anterior maxillary teeth, and a significant overjet. Maxillary and mandibular arch forms were comparable. The periodontium appeared to be satisfactory, with adequate margins of attached tissues over the labial and buccal segments. Oral hygiene was good and all teeth were free of carious



**Pretreatment cephalometric tracing at 11 years 8 months. The ANB is 14 degrees.**

**Superimposed tracings at 11 years 8 months and 14 years 9 months. Note presence of Proplast implant.**

involvement. During deglutition the tongue was observed to protrude between the incisors. Review of intraoral radiographs revealed the presence of a full complement of permanent teeth. Tomograms of the temporomandibular joints showed both condyles to be dramatically foreshortened with flattened irregular articular surfaces and "lipping" of the margins of the condyles. Radiographs of the condyles taken in both the open and closed positions revealed symmetrical, unrestricted motion.

Analysis of the initial lateral cephalometric radiographs showed the distortion of the mandible, dentition, and overlying soft tissues which existed secondary to the lack of normal condylar growth. Maxillary position was found to be within normal limits, with the ANB angle of 14 degrees and the 48-degree mandibular plane to Frankfort horizontal angle reflecting an aberrant pattern of mandibular growth and development. In contrast to satisfactory upper facial height (nasion to anterior nasal spine), lower facial height (anterior nasal spine to gnathion) was markedly reduced.

The axial inclination of the maxillary central incisors was found to be within normal limits when compared to the cranium but protrusive in relationship to the maxilla. While the apices of the maxillary molars were at the level of the palatal plane, the maxillary incisors appeared to be lower with an increased distance between the floor of the nose and the apices of the incisors. Mandibular incisor position was found to be protrusive when compared to both the man-

dibular plane and the chin point. A Holdaway ratio of 12:0 dramatically reflected the degree of incisor protrusion and skeletal retrusion.

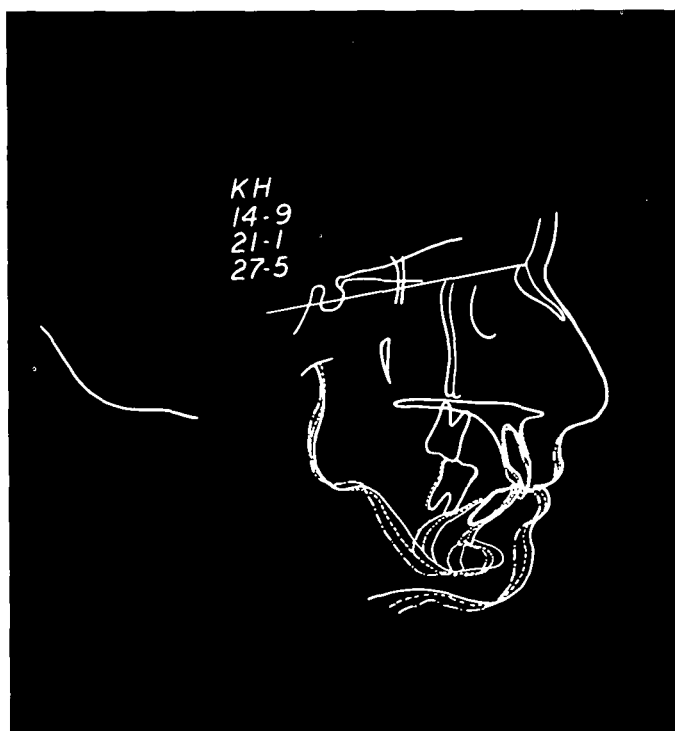
Comparing the relationship of the nose, upper lip, lower lip, and chin proved meaningless because of the marked distortion of mandibular position. The nasolabial angle was satisfactory when considered by itself. By comparing the position of the soft-tissue chin to the upper face (zero meridian), the chin was found to be 21 millimeters deficient.

Based on diagnostic findings, the following treatment plan was established:

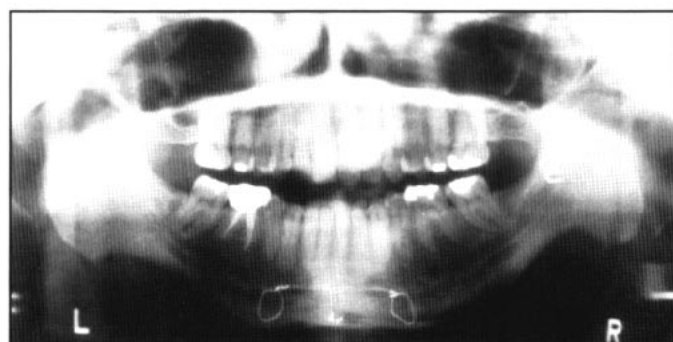
1. Extraction of mandibular first premolars with maximum retraction of mandibular incisors.
2. Alignment of the maxillary dentition (nonextraction), maintaining maxillary incisor position, both anteroposteriorly and vertically.
3. Surgical lengthening of the mandible to a Class I canine relationship.
4. Augmentation of chin prominence by insertion of an alloplastic implant.
5. Postsurgical monitoring of serial cephalometric radiographs to evaluate skeletal stability.
6. Completion of postsurgical orthodontic treatment to establish an optimal occlusal relationship.

#### Treatment results

Cephalometric superimpositions, with the cranial base used as reference, showed satisfactory mandibular stability four months postoperatively. During this time, the patient continued to wear Class II elastics, an occlusal splint, high-



Superimposed tracings over a period of nearly 14 years following surgical advancement of the mandible. Note gradual shortening and posterior movement of the mandible.



Panoramic radiograph at 27 years 5 months. Normal temporomandibular joint anatomy is lacking.

pull headgear, and a soft cervical collar. In this manner, dental compensation was maintained until the achievement of skeletal stability. At the time of band removal, a maxillary Hawley retainer and mandibular splint were fabricated. Retainers were worn full time for several months then nightly for a few years.

The decision to provide treatment at an early age was based upon the following considerations:

1. Only two to three percent of patients with mandibular retrognathism not associated with an identifiable disease process such as JRA will experience "catch-up" growth. In the remaining 97 to 98 percent, growth of the maxilla and mandible will remain proportional, maintaining the skeletal disparity to the completion of growth.
2. Because of the destruction of the growth centers secondary to JRA, additional mandibular growth was not anticipated.
3. Surgical correction of the severe retrognathism would minimize continued distortion of vertical maxillary growth. Personal experience gained from treating adults with JRA in which vertical maxillary growth has been allowed to proceed to completion has been more complex. In these instances treatment must correct not only the mandibular deformity but the secondary vertical maxillary dysplasia as well.

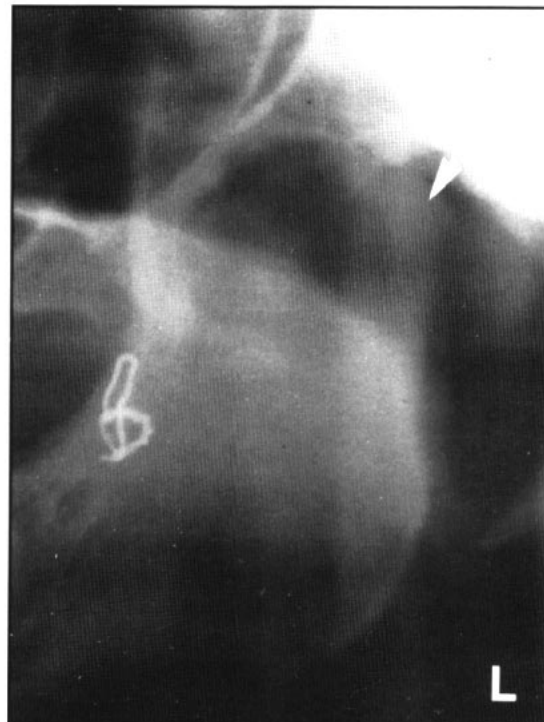
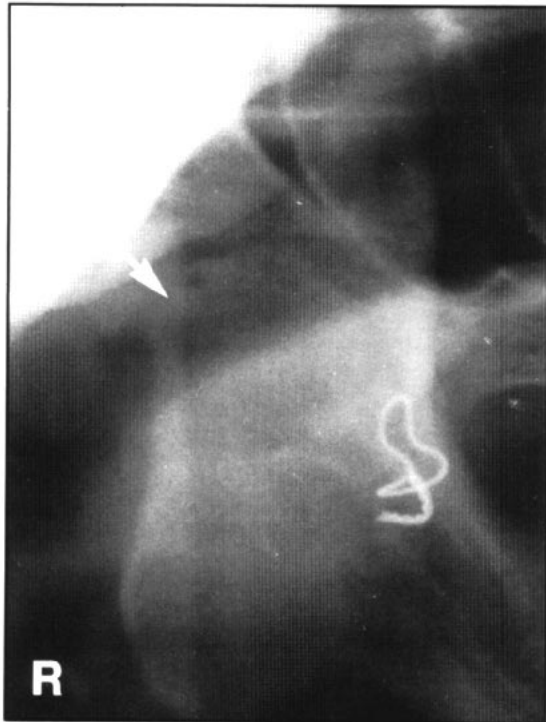
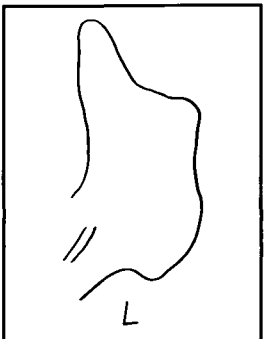

The timing of treatment was thought to be important, not only as it related to the factors already mentioned but also as it pertained to the psychosocial ramifications of the patient's facial

deformity. According to the patient's friends, she became more "outgoing" than she was prior to the initiation of treatment.

Posttreatment records initially showed (1) minimal change in mandibular position, (2) slight increase in overjet with maintenance of coincidence of the centric occlusion/centric relation, (3) posterior "migration" of the Proplast implant into the symphysis of the mandible with minimal overlying soft-tissue change, (4) improved facial esthetics, and (5) no evidence that treatment compromised mandibular mobility. Although the mandibular condyles on both sides appeared radiographically diminutive and flattened, the patient continued to have normal function when opening and closing.

#### Long-term change

Two concerns have predominated throughout the posttreatment period and long-term records validate the reasons for being concerned. Prior to the start of treatment it was feared that continued resorption and remodeling of the condyles would result in loss of mandibular length and a return of the Class II skeletal relationship. From the current panoramic radiographs as well as headfilms taken seven and ten years post-treatment, it is obvious that reversal of the correction is progressive. The condyles continue to resorb making it difficult to distinguish any Glenoid Fossa or normal joint anatomy. On the other hand, the coronoid process seems to compensate with what appears to be excessive bone deposition and increase in size. Joint function is



**Figure 9A-D**  
The "right" and "left" condylar areas appear to have flattened, irregular surfaces. The coronoid processes are large, almost as if they were compensating for the lack of normal condylar function.

normal with no limitation in opening and no pain.

The Proplast chin implant also continues to show change. Bone resorption and movement of the implant posteriorly into the symphysis is observed in both follow-up headfilms. The implant has remained symmetrical and all tissues appear healthy. The net result of change in mandibular position combined with posterior movement of the Proplast implant has been a gradual alteration in facial profile.

Records taken 14 years after orthognathic surgery show the mandible is moving posteriorly in relation to the maxilla. This shortening of mandibular length seems to be related to

progressive condylar resorption as well as to changes of the alloplastic chin implant. These changes are likely to continue as the patient ages.

Overall treatment goals, according to most pediatricians and students of juvenile rheumatoid disease, must include:<sup>7</sup>

1. the preservation of joint function without iatrogenic harm, and
2. support for the family and child in achieving optimal psychosocial development.

It is the opinion of this clinician that these objectives have been achieved. In another 14 years the remainder of the story may be known.

—David L. Turpin, DDS, MSD

### References

1. Turpin, D.L. and West, R.A.: Juvenile Rheumatoid Arthritis: Report of surgical/orthodontic treatment, *Am. J. Orthod.* 73:312-320, 1978.
2. Engle, M.B., Richmond, J. and Brodie, A.G.: Mandibular growth disturbance in rheumatoid arthritis of childhood, *Am. J. Dis. Child.* 78:728-743, 1949.
3. Barriga, G., Lewis, T.M. and Law, D.B.: An investigation of the dental occlusion in children with juvenile rheumatoid arthritis, *Angle Orthod.* 44: 329-335, 1974.
4. Martel, W., Holt, J.F. and Cassidy, J.T.: Roentgenological manifestations of juvenile rheumatoid arthritis, *Am. J. Roentgenol.* 88:400-423, 1962.
5. Schaller, J.: Rheumatic Diseases. In *Introduction to Clinical Pediatrics*, Philadelphia, W.B. Saunders Company, p 220, 1972.
6. Roberts, F.G., Pruzansky, S. and Aduss, H.: An x-radioccephalometric study of mandibulofacial dystosis in man, *Arch. Oral Biol.* 20:265-281, 1975.
7. Schaller, J.G. and Wedgwood, R.J.: Rheumatic Diseases. In *Nelson Textbook of Pediatrics*, Philadelphia, W.B. Saunders Company, p 521, 1987.