

Craniofacial morphology of adolescent mandibular prognathism

Yu Chieh-Li Lu, DDS; Kazuo Tanne DDS, DDS; Yoshiko Hirano, DDS; and Mamoru Sakuda, DDS, DDS

Orthopedic approaches with chin cup and/or maxillary protraction appliances are sometimes needed for the correction of mandibular prognathism in adolescent Class III patients with various skeletal discrepancies. Orthognathic surgery is occasionally preferable for some patients manifesting abnormal mandibular growth during puberty. In particular, chin cup therapy has long been applied to patients with large and/or anteriorly-positioned mandibles to control and redirect mandibular growth. Thus, craniofacial growth, especially mandibular growth, is of great importance to orthodontists in their efforts to achieve desirable results from such orthopedic treatment.

In order to elucidate the nature of craniofacial

growth in patients with mandibular prognathism during chin cup therapy, various studies have been conducted.¹⁻¹⁵ Most of the cephalometric and experimental studies indicate that mandibular growth was altered during orthodontic and orthopedic treatment. Retardation of mandibular growth, vertical growth of the ramus in particular, distal displacement of the mandible and closure of the gonial angle were demonstrated by morphological studies.^{3,6-8,12,14} Some of these findings were also elucidated by experimental studies;^{1,4,5} Asano¹ studied growth retarding in rat mandibles, Janzen and Bluher⁴ worked with monkeys and Matsui⁵ with rabbits; their work suggested permanent bony changes occur in the mandible which help correct a prognathic profile.

Abstract

Morphological features of the craniofacial complex during orthopedic chin cup therapy were investigated in growing patients with mandibular prognathism. Lateral cephalograms of 30 subjects (15 boys and 15 girls, mean age: 9.04 ± 1.29 years), taken at four different stages during treatment, were analyzed for 14 measurements. These measured values were standardized by use of Japanese controls and then evaluated to investigate longitudinal changes in the craniofacial morphology at the four different stages. Further, factor analysis was used to compare factors describing the craniofacial morphology for the initial and final stages. Dimensional changes of the mandible were not easily produced even if orthopedic treatment was conducted, whereas the maxilla exhibited a tendency to approach the normal range of the controls. Positional changes of the complex, the backward and downward repositioning of the mandible in particular, played an important role in altering a profile from prognathic before treatment to orthognathic at the end of treatment. Craniofacial morphology was similar pretreatment and posttreatment, although the orthognathic factor became more prominent when associated with positional changes of the mandible at the end of treatment.

Key words

Chin cup therapy • Mandibular prognathism • Mandibular growth • Cephalometrics • Factor analysis

Submitted: September 1992

Revised and accepted for publication: February 1993

Angle Orthod 63:277-282

Table 1
Age of the subjects at four stages

	Pretreatment	After crossbite correction	2 yrs after correction	Posttreatment
Mean ± s.d.	9.04 ± 1.29	10.89 ± 1.70	12.42 ± 1.59	15.47 ± 1.12
Range	6.17 - 11.00	6.83 - 13.92	8.42 - 15.42	14.00 - 17.50

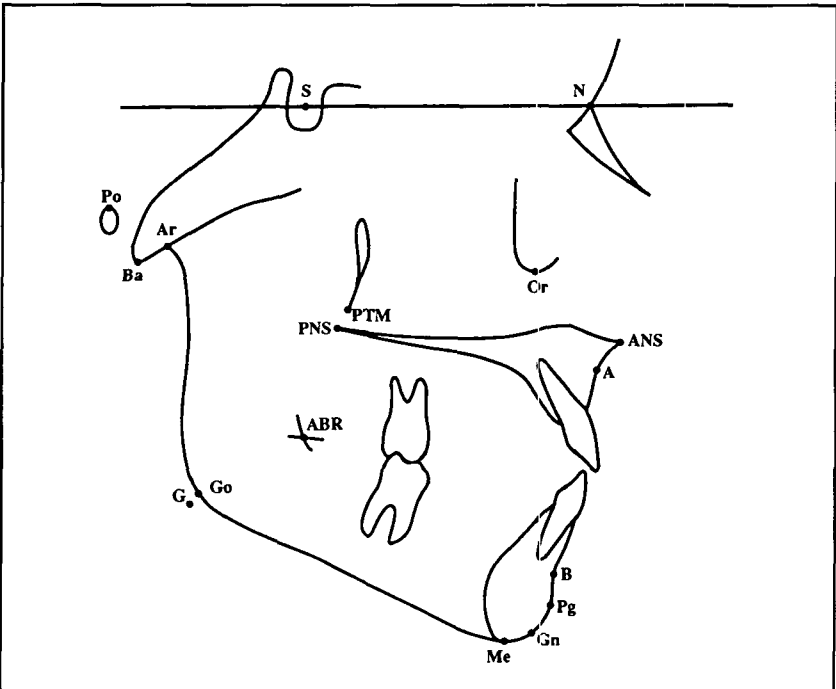


Figure 1

- Figure 1**
A coordinate system and landmarks defined for the analysis:
- S: Sella turcica
 - N: Nasion
 - Or: Orbitale
 - ANS: Anterior Nasal Spine
 - A: A point
 - B: B point
 - Pg: Pogonion
 - Gn: Gnathion
 - Me: Menton
 - G: G point
 - Go: Gonion
 - Ar: Articulare
 - Ba: Basion
 - Po: Porion
 - PTM: Pterygomaxillary fissure
 - PNS: Posterior Nasal Spine
 - ABR: Anterior Border of Ramus

Other studies⁹⁻¹¹ conclude that the general growth pattern can not be modified by orthopedic chin cup therapy.

Thus, different conclusions about the clinician's ability to modify the craniofacial morphology of patients with mandibular prognathism can be derived from these studies.¹⁻¹⁵ Therefore, it is important to elucidate morphological changes orthopedic chin cup treatment produce in the craniofacial skeleton with mandibular prognathism. To do this, the craniofacial morphology must be clearly described by a small number of components or factors as well as by the conventional cephalometric analyses conducted in previous studies.^{3,6-8,12,14}

The purpose of this study was to investigate the morphological features of the craniofacial skeleton in growing patients with mandibular prognathism who have undergone chin cup therapy during adolescence

Materials and methods

Thirty Japanese children (15 boys and 15 girls) with mandibular prognathism were used as subjects. The subjects were selected based on the following criteria: 1) anterior crossbite; 2) large or anteriorly positioned mandible; 3) maxilla within the normal range in size and anteroposterior position; 4) no congenital deformities. The mean and standard deviation of the initial age were 9.04 ± 1.29 years. The patients underwent orthopedic chin cup therapy for the correction of anterior crossbite associated with skeletal mandibular prognathism for an average of 5 years 1 month (Table 1). Lateral cephalograms were taken at four different stages (A to D) during treatment, as shown in Table 1. Each lateral cephalogram was traced on acetate paper and 17 landmarks were defined in a X-Y coordinate system (Figure 1). The X and Y coordinates were digitized and the following 14 measurement items, describing the morphology of the anterior cranial base, maxilla and mandible, were calculated by use of a personal computer system.

- Anterior cranial base: NSBa angle, SN
- Maxilla: SNA angle, PTM-A / Pal. pl.
- Mandible: SNPg, Facial and SNB angles, Go-Me, Ar-Me, Mand. pl. to SN, Gonial and Ramus pl. to SN angles
- Maxillo-mandibular relation: ANB angle, A-B / Pal. pl.

All the measured values were standardized by use of the means and standard deviations of the Japanese controls developed in the Department of Orthodontics, Osaka University Faculty of Dentistry. Values were converted to Z-scores to eliminate the influence of sex and age on the measured values, and to evaluate therapeutic changes of the craniofacial complex excluding normal growth in the control group.

These values were compared with those of the control group (the means and standard deviations for all the measurement items are 0.0 and 1.0 after the conversion, respectively) by means of Student's t-test. Further, the data for stages A and D were subjected to factor analysis, where a set of factors is extracted on the basis of such criteria that the eigenvalue is more than the mean or approximately 1.0 and rotated factor loadings are more than 0.5.¹⁶ Thus, the nature of morphological features of the craniofacial complex before and after treatment could be investigated in terms of changes in the factors for the two stages.

Results

Means and standard deviations of the standardized data (Z-score) are shown for stages A to D

Downloaded from http://meridian.allenpress.com/angle-orthodontist/article-pdf/63/4/277/3724110003-3219/1993/063_0277_0_0_2.pdf by guest on 11 February 2025

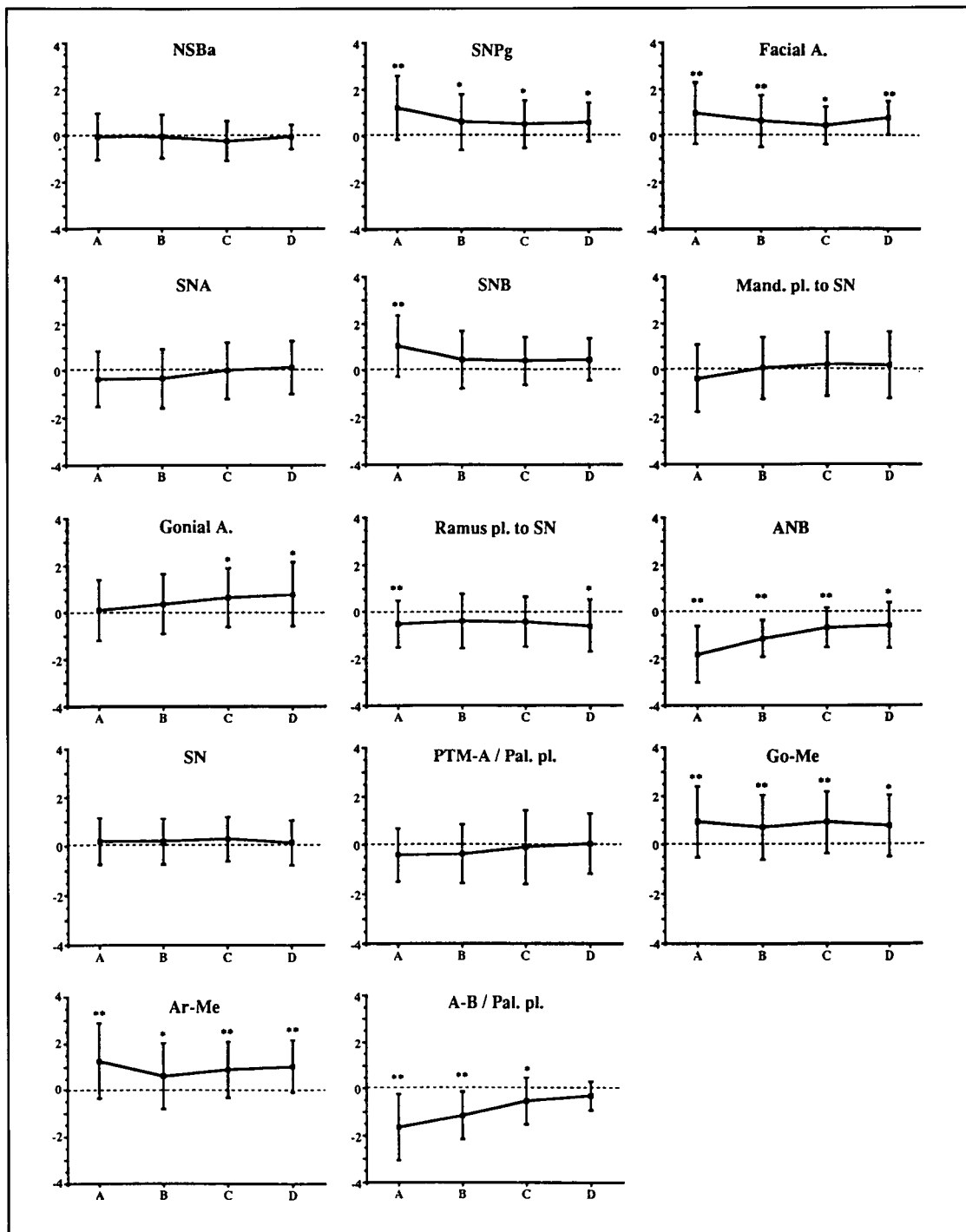


Figure 2
Means and standard deviations of the standardized values for 14 measurement items.
* : significantly different from the controls at 5% level of confidence.
** : significantly different from the controls at 1% level of confidence.

during the treatment (Figure 2). The dimension and shape of the anterior cranial base were almost within the normal range of the controls for all stages, as noted by changes in the NSBa angle and S-N distance. The dimension and anteroposterior position of the maxilla, denoted by the Ptm-A/pal. pl. and SNA angle, were slightly deviated from the means in the controls before treatment, but not significantly so, and they exhibited a tendency to approach the normal range of the con-

controls at stages C and D. The mandible was significantly larger in the study group than in the controls for all the stages, as indicated by changes in the Go-Me and Ar-Me. Mandibular position, evaluated by the SNPg, SNB and facial angles, was more anterior to the anterior cranial base at the initial stage and became progressively posterior during treatment. The mandible rotated gradually in a clockwise direction, as noted by changes in the Mand. pl. to SN, and gonial angles. The

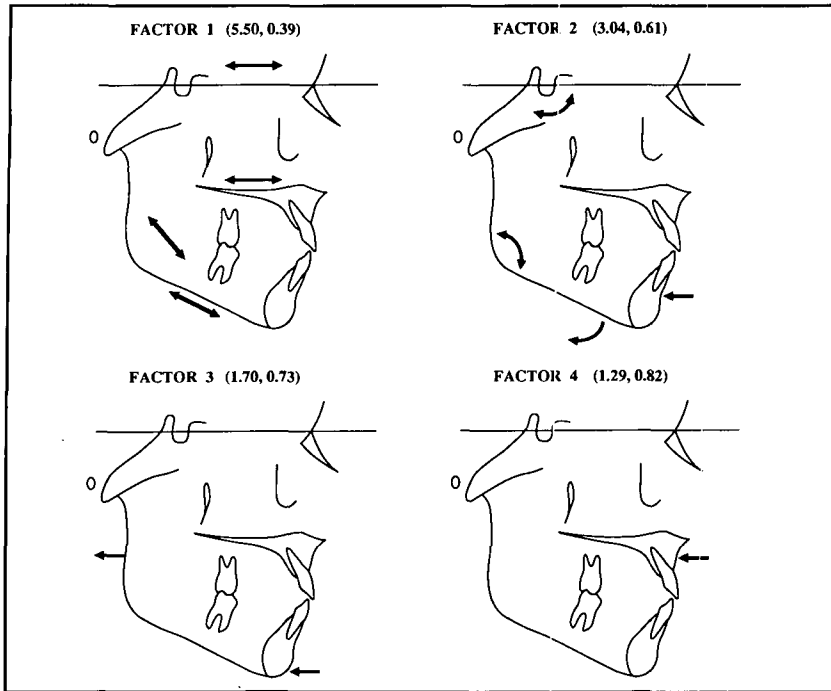


Figure 3
Schematic representation of extracted factors for the stage A. Eigenvalue and cumulative contribution ratio are shown in the parenthesis for each factor.

maxillo-mandibular relation was prognathic at the initial stage and then tended to gradually approach the means of the controls, as noted by changes in the ANB angle and A-B distance.

Figures 3 and 4 show schematic representations of the extracted factors for stages A and D. More than 80% of the variations were explained for the two stages by use of the factors.

For the initial stage A, the first factor exhibited high correlation with dimensions of the anterior cranial base, maxilla and mandible, and hence this factor was regarded as a size factor for the craniofacial skeleton. The second and third factors were shape-determining factors, although both exhibited somewhat different meanings, i.e. the second factor determined downward rotation of the complex, whereas the third one was for backward rotation. The fourth factor was related to the retrognathic maxilla and prognathic profile (Figure 3). For the final stage D, the first factor was regarded as a size factor associated with downward rotation of the mandible. The second factor was related to backward rotation of the maxillo-mandibular skeleton. The third and fourth factors were related to an orthognathic profile and the shape of the anterior cranial base, respectively (Figure 4). Thus, the nature of craniofacial morphology at the two stages were very similar in terms of changes in the factors, although an orthognathic factor became more prominent by positional changes of the mandible at the end of treatment.

Discussion

Morphology of the craniofacial complex in adolescent patients with mandibular prognathism has been investigated extensively by means of cephalometric approaches.^{3,6-15} Most of these studies employed an evaluation of arbitrary dimensional and angular measurements; overall characteristics of the craniofacial morphology have not been investigated. Multivariate analyses are effective for this purpose,^{12,17-20} in particular factor analysis is available for extracting principal components or factors which may account for more overall morphological variations in the craniofacial complex.¹⁶⁻¹⁸

In this study, four factors were extracted from 14 measurement items for two treatment stages. Since more than 80% of the variations in the cephalometric variables were explained by these factors, they seem available to describe the subjects' overall craniofacial morphology.^{12,16-18} The present analyses revealed that 1) the size factor for the craniofacial complex is a dominant factor for determining the morphology in mandibular prognathism, 2) the shape factor for determining backward and downward rotations of the complex is regarded as the second or third factor, 3) the fourth factor relevant to a prognathic profile, observed at the initial phase of the treatment, becomes a principal factor which describes an orthognathic profile at the end of treatment. Further, the cephalometric appraisal revealed that 1) the maxilla exhibits a tendency to approach the controls after the correction of anterior crossbites, or catch-up growth,¹² and 2) the mandible is significantly larger in the study group than in the controls throughout treatment, however, the anteroposterior position becomes progressively posterior during the treatment.

From these results, the following clinical implications are derived: 1) dimensional changes of the mandible are not easily produced even if orthopedic treatment is conducted, 2) positional changes of the complex, particularly rotational changes of the mandible, play an important role in changing a profile from prognathic to orthognathic.

The chin cup appliance has been successfully used to treat mandibular prognathism. The mechanisms of the appliance are well documented in the literature,^{2,3,6-10,12-14} i.e. redirection of mandibular growth from horizontal to more vertical, and posterior displacement of the mandible with clockwise rotation. Experimental studies^{1,4,5,21} using animals demonstrated a decrease in the prechondroblastic layer of the condyle, inhibition of new bone formation on the condyle, closure of the gonial angle and deformation of the entire

mandible, which are assumed to produce retardation of mandibular growth. In the present study, permanent changes in the dimension of the mandible were not observed. Incremental growth of the mandible was controlled to some extent—measurement items on size tended to gradually approach the controls, indicating that more substantial growth of the mandible may be generated if chin cup therapy is not carried out. Meanwhile, backward and/or downward repositioning of the mandible, which is highly associated with repositioning of the anterior cranial base and middle cranial fossa as described by Enlow,²¹ is thought to be one of the principal factors related to orthognathic profile at the end of treatment. Thus, an orthopedic approach to the mandible may be used to control mandibular growth by redirecting and/or restricting growth in this particular population.

Our preliminary study showed that some patients with mandibular prognathism exhibit a more severe prognathic profile progressively during puberty, even though the anterior cross bite was corrected before pubertal growth.²³ The craniofacial morphology of patients with mandibular prognathism is altered by rotational repositioning of the skeleton, not by dimensional changes of the complex. Therefore, craniofacial growth, particularly mandibular growth, should be observed carefully until its completion.

Conclusions

The present study was conducted to investigate the nature of craniofacial morphology in adolescent patients with mandibular prognathism during orthopedic chin cup therapy. Lateral cephalograms of 30 subjects (15 boys and 15 girls), taken at four different stages during the treatment, were analyzed for 14 measurement items. The measured values were converted to standardized data by use of the Japanese controls, and further subjected to factor analysis to extract morphological characteristics before and after the treatment. The following results were obtained.

1. Maxillae in the study group tended to approach those of the controls after correction of anterior cross bite or catch-up growth.
2. Mandibles were significantly larger in the study group than in the controls throughout treatment, however, the anteroposterior position became progressively posterior during the treatment.
3. The nature of craniofacial morphology before

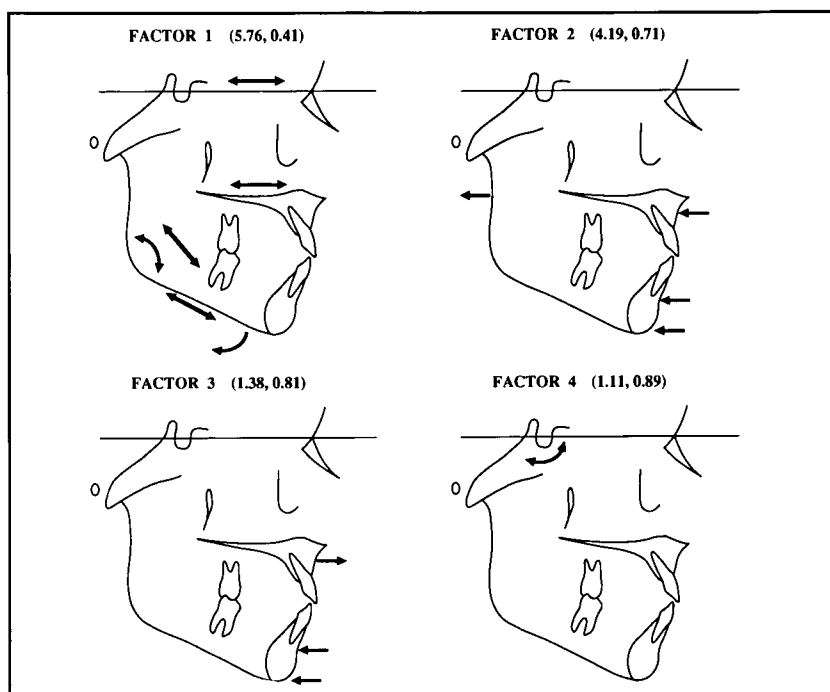


Figure 4

and after treatment were very similar in terms of changes in the factors, although the orthognathic factor became more prominently associated with positional changes of the mandible at the end of treatment.

Change in the shape of the complex, determined by backward and downward rotation of the skeleton, is a principal factor related to orthognathic profile, whereas dimensional alteration of the craniofacial skeleton is less substantial during orthopedic chin cup therapy.

Author Address

Dr. Kazuo Tanne
Department of Orthodontics
Hiroshima University
1-2-3 Kasumi, Minami-Ku
Hiroshima 734, Japan

Dr. Lu is Graduate Student in the Graduate Institute of Dental Sciences, Kaohsiung Medical College.

Dr. Hirano is Clinical Associate in Osaka Medical Center and Research Institute for Maternal and Child Health.

Dr. Tanne is Professor and Chairman, Department of Orthodontics, Hiroshima University School of Dentistry.

Dr. Sakuda is Professor and Chairman of the Department of Orthodontics, Osaka University Faculty of Dentistry

Figure 4

Schematic representation of extracted factors for the stage D. Eigenvalue and cumulative contribution ratio are shown in the parenthesis for each factor.

References

- Asano T. The effects of mandibular retractive force on the growing rat mandible. *Am J Orthod Dentofac Orthop* 1986;90: 464-474.
- Graber LW. Chin cup therapy for mandibular prognathism. *Am J Orthod* 1977;72: 23-41.
- Irie M, Nakamura S. Orthopedic approach to severe skeletal Class III malocclusion. *Am J Orthod* 1975;67: 377-392.
- Janzen EK, Bluher JA. The cephalometric, anatomic, and histologic changes in *Macaca mulatta* after application of a continuous-acting retraction force on the mandible. *Am J Orthod* 1965;51: 823-855.
- Matsui Y. Effect of chin cap on the growing mandible. *J Jpn Orthod Soc* 1965;24: 165-181.
- Sugawara J, Asano T, Endo N, Mitani H. Long-term effects of chin cap therapy on skeletal profile in mandibular prognathism. *Am J Orthod Dentofac Orthop* 1990;98: 127-133.
- Suzuki N. A cephalometric observation on the effect of the chin cap. *J Jpn Orthod Soc* 1972;31: 64-74.
- Wendell PD, Nanda R. The effect of chin cup therapy on the mandible: a longitudinal study. *Am J Orthod* 1985;87: 265-274.
- Mitani H, Fukazawa H. Effects of chin cap force on the timing and amount of mandibular growth associated with anterior reversed occlusion (Class III malocclusion) during puberty. *Am J Orthod Dentofac Orthop* 1986;90: 454-463.
- Mitani H, Sakamoto T. Chin cap force to a growing mandible. Long-term clinical reports. *Angle Orthod* 1984;54: 93-122.
- Thilander B. Treatment of Angle Class III malocclusion with chin cup. *Trans Eur Orthod Soc* 1963;39: 384-398.
- Ohyama Y, Sakuda M. A longitudinal cephalometric study on craniofacial growth of the orthodontically treated patients with mandibular prognathism. *J Osaka Univ Dent Sch* 1982;22: 175-191.
- Ritucci R, Nanda R. The effect of chin cup therapy on the growth and development of the cranial base and midface. *Am J Orthod Dentofac Orthop* 1986;90: 475-483.
- Sakamoto T. Effective timing for the application of orthopedic force in the skeletal Class III malocclusion. *Am J Orthod* 1981;80: 411-416.
- Schulhof RJ, Nakamura S, Williamson WV. Prediction of abnormal growth in Class III malocclusion. *Am J Orthod* 1977;71: 421-430.
- Okuno T, Kume H, Haga T, Yoshizawa T. Multivariate analysis. 13th ed. Tokyo: Nikka-giren Co. 1977; pp. 159-257, pp. 323-372.
- Landauer CA. A factor analysis of the facial skeleton. *Human Biol* 1962;34:239-253.
- Lieb Gott B. Factors of human skeletal craniofacial morphology. *Angle Orthod* 1977;47:222-230.
- Nakata M, Yu PL, Nance W.E. Multivariate analysis of craniofacial measurements in twin and family data. *Am J Phys Anthropol* 1974;41:423-430
- Suzuki A, Takahama Y. Parental data used to predict growth of craniofacial form. *Am J Orthod Dentofac Orthop* 1991;99:107-121.
- Joho JP. The effects of extraoral low-pull traction to the mandibular dentition of *Macaca mulatta*. *Am J Orthod* 1973;64:555-577.
- Enlow DH. Handbook of facial growth. Philadelphia: W.B. Saunders Co. 1975;186-225.
- Lu Y C-L, Tanne K, Sakuda M. The effects of orthopedic treatment with chin cap on craniofacial growth in adolescent Class III patients. *J Osaka Univ Dent Sch* 1991;31:85-94