

# Early mixed dentition treatment: postretention evaluation of stability and relapse

Steven A. Dugoni, DMD, MSD; Jetson S. Lee, DDS, MSD;  
Jaime Varela MD, DDS, MSD; Arthur A. Dugoni, DDS, MSD

Orthodontists have been looking for the answer to mandibular incisor stability for decades. Many studies have been conducted to evaluate stability of mandibular incisors following treatment in the permanent dentition. These studies have shown unsatisfactory long-term alignment of the mandibular anterior teeth following orthodontic treatment with either expansion of the dental arches, nonextraction treatment, or extraction of permanent teeth. This study evaluates the results of early mixed dentition treatment with a passive lingual arch and the long-term alignment of the mandibular anterior teeth.

In 1907, Angle<sup>1</sup> wrote: "The best balance, the best harmony, the best proportions of the mouth in its relations to other features require that there be the full complement of teeth, and that each

tooth position shall be made to occupy its normal position—normal occlusion." Since Angle's statement was made, there has been an ongoing debate on the merits of extraction versus nonextraction treatment.

Nonextraction treatment for the correction of mandibular incisor crowding usually involves arch enlargement procedures. Many orthodontists have concluded that these types of procedures are unstable in the permanent dentition. Some practitioners engage in arch enlargement in the mixed dentition in the hope that this type of treatment will be more stable than treatment in the permanent dentition. Most of the studies of arch enlargement in the mixed dentition have been case reports without thorough postretention records to evaluate stability.

The use of a lingual arch in early mixed denti-

## Abstract

Twenty-five patients who underwent early mixed dentition treatment were evaluated during the following stages: pretreatment (early mixed dentition), phase 2 (early permanent dentition), and postretention (average of 9.5 years). All patients were treated with a removable passive lingual arch. The mandibular incisors were judged to have satisfactory alignment at phase 2 evaluation and had no further orthodontic treatment.

Nineteen of 25 cases (76%) demonstrated clinically satisfactory mandibular alignment postretention. Inter canine width decreased in 72% of the cases postretention and arch length decreased in 100% postretention. Intermolar width increased in 18 of 25 (72%) of the cases during treatment and remained stable in 17 of 25 (68%) of the cases. No predictors or associations could be found to help clinicians in determining the long-term prognosis of dental stability.

## Key Words

Early mixed dentition • Irregularity index • Stability • Relapse • Lingual arch • Postretention

Submitted: September 1994

Revised and accepted: November 1994

Angle Orthod 1995;65(5):311-320

tion treatment has been evaluated by several authors, including Wright and Kennedy<sup>2</sup> and Eastwood,<sup>3</sup> who all stressed the need for the lingual arch to be passive to minimize the side effects of labial displacement of the lower incisors. Singer<sup>4</sup> studied the use of a passive lingual arch and found that the appliance does have an active effect on the dentition and can change incisor and molar position. Odom<sup>5</sup> found that the lingual arch is effective in maintaining leeway space and does not prevent the normal horizontal or vertical growth changes of the mandibular incisors and molars.

To help separate the effects of growth from those of treatment changes in stability studies, several authors have studied arch dimension changes in untreated samples. Moorrees,<sup>6</sup> in an untreated sample, found that the mandibular intermolar distance increased between the ages of 9 and 14, but thereafter remained constant. Arch length decreased between the ages of 9 and 14, corresponding to the replacement of the deciduous teeth by the permanent teeth, and remained constant after 14 years of age.

Intercanine width changes in untreated samples have been studied by Barrow and White,<sup>7</sup> Moorrees,<sup>6</sup> and Sillman.<sup>8</sup> They all observed that there is a rapid increase in intercanine width from 6 to 9 years of age, due to permanent incisor and canine eruption. From 10 to 12 years of age intercanine width decreases, and the decrease remains stable according to Moorrees and Sillman but continues to decrease according to other authors. Moorrees suggested that the decreasing incisor-canine circumference noted from 13 to 18 years is associated with a decrease in arch length rather than a narrowing of arch width.

Sinclair and Little<sup>9</sup> examined 65 untreated normal occlusions and revealed a consistent trend toward a decrease in arch length in the mixed dentition to early adulthood. There was a slight decrease in intercanine width, especially in females from 13 to 20 years old. Molar width generally remained the same. Incisor irregularity increased in the 13- to 20-year-old females, with females exhibiting more incisor irregularity than males in all stages. No association or predictors of clinical value were found.

In an effort to better quantify crowding of the mandibular anterior teeth, Little<sup>10</sup> proposed the use of the irregularity index (IRI). The irregularity index measures displaced contact points and provides an objective value to quantify crowding. It has not been found to be a predictor of future crowding when used in the permanent or

mixed dentition. This index does not take into account the mixed dentition "leeway space." Several arch length analyses in the mixed dentition can be used to help predict crowding by measuring the size of unerupted canines and premolars. Gardner<sup>11</sup> evaluated four mixed dentition analyses to determine which was most accurate. He found that the Hixon-Oldfather<sup>12</sup> analysis was the best predictor of an arch length deficiency.

Little, Wallen, and Riedel<sup>13</sup> studied the stability of mandibular anterior alignment in cases treated with traditional edgewise appliances and first premolar extraction. Their 10-year follow-up study found that long-term alignment was variable and unpredictable and that the success of maintaining satisfactory anterior alignment is less than 30%. Arch length and width typically decreased during retention, whereas crowding increased regardless of treatment expansion or constriction. Little, Riedel and Årtun<sup>14</sup> re-evaluated these cases with 20-year follow-up postretention records and found that crowding continued to increase during the 10 to 20 years postretention phase, but to a lesser extent than during the first 10 years postretention. Only 10% of the 20-year postretention cases had clinically acceptable mandibular alignment.

McReynolds and Little<sup>15</sup> examined postretention stability of cases treated with edgewise appliances and mandibular second premolar extractions. They found that arch length and width decreased with time and incisor irregularity increased throughout the postretention period. Little, Riedel, and Engst<sup>16</sup> examined postretention stability following first premolar serial extraction and found clinically unsatisfactory mandibular anterior alignment in 73% of the cases and decreases in intercanine width and arch length in 29 of 30 cases.

In their paper evaluating stability with mandibular incisor extraction, Riedel, Little, and Bui<sup>17</sup> showed that 29% of single-incisor extraction cases and 56% of the two-incisor extraction cases demonstrated unacceptable mandibular incisor alignment in the postretention stage. These results were considered more favorable than the results of the premolar extraction cases.

Stability with treatment to increase mandibular arch length and arch width was evaluated by Little, Riedel, and Stein.<sup>18</sup> Treatment for these cases was started in the late mixed dentition with fixed edgewise appliances, active lingual arches, lip bumpers, or removable appliances. The researchers found that enlargement of mandibular arch length in the mixed dentition to

	Male	Female	Pooled
Class I	5	8	13
Class II	3	9	12
Total	8	17	25

	Mean $\pm$ S.D.	Range
Pretreatment (T1)	8y 2m $\pm$ 0y 9m	7y 3m to 10y 11m
Phase 2 evaluation (T2)	13y 7m $\pm$ 1y 6m	10y 1m to 16y 7m
Postretention (T3)	27y 11m $\pm$ 4y 9m	20y 11m to 35y 11m
Postretention period	9y 6m	5y 0m to 22y 3m

accommodate an arch length deficiency offered no better solution. "This enlargement method of treatment revealed the poorest stability results compared to their other studies of mandibular incisor stability."

### Purpose

The purpose of this paper was to assess the long-term stability of mandibular incisors in patients treated in the early mixed dentition by the preservation of leeway space with a passive lingual arch.

### Materials and methods

The sample consisted of 25 early mixed dentition patients (8 males and 17 females) from the office of Drs. Arthur and Steven Dugoni. Thirteen patients were Class I and 12 were Class II (Table 1A). These cases exhibited inadequate pretreatment mandibular arch length. The mixed dentition treatment was designed to preserve leeway space with a removable passive lingual arch. All cases had a maxillary 2 x 4 appliance consisting of bands or brackets on the first permanent molars and incisors and a continuous archwire. The 2 x 4 appliance was in place for approximately 12 to 18 months. Class II cases involved headgear therapy to the maxillary arch. The lower first primary molars had been extracted in most cases to encourage distal drifting of the primary and permanent canines and to allow space for unraveling of the lower incisors. At a later stage, some cases had lower second primary molars removed if the first premolars and canines erupted into a crowded position.

The treatment goals of early orthodontic treatment (phase 1) were to eliminate or significantly reduce the extent of treatment needed in the permanent dentition. The lingual arch appliance used was a removable, pre-formed .030 stainless steel wire (Unitek, Monrovia, Calif) with an adjustment loop. The wire was inserted into horizontal sheaths on the lower first permanent molars. It was constructed to rest at the contact

points (incisal third) of the lower incisors. The lingual arch was typically adjusted monthly during the first 6 months of treatment until there was good alignment of the incisors with the lingual arch contacting the incisal third of all the lower incisors. In a severely crowded case (e.g. patient #10) the lingual arch would initially contact only the most lingually positioned tooth with a light anterior and inferior pressure. In these cases the lingual arch would be adjusted monthly by opening the adjustment loop to move the most lingual tooth labially to the position of the other lower incisors. In most cases there was no attempt to advance all of the incisors forward, tip the lower first molars back, or expand the dentition. The lingual arch was left in place until the canines and premolars erupted. A maxillary retainer was worn for 5 to 10 years after phase 1 treatment.

Patients in this sample did not receive any edgewise orthodontic treatment in the permanent dentition. These cases were either deemed to have an acceptable occlusion in the permanent dentition or the parents decided not to pursue a second phase of treatment. In most cases the lingual arch was removed and a lower fixed canine-to-canine retainer was placed. This retainer was usually removed after the extraction of the third molars. Posttreatment records were taken a minimum of 5 years after removal of the mandibular retention appliances. Sixteen patients received "sulcus slice" (circumferential supracrestal fiberotomy) and 18 had "stripping" (interproximal enamel reduction) following removal of the lower fixed canine-to-canine retainer.

All patients had three sets of diagnostic study casts collected (Table 1B). Full mouth x-rays (long cone technique) were evaluated at the start of treatment (T1) in order to perform the Hixon-Oldfather mandibular arch length analysis. Patients had study casts at the start of phase 1 treatment (T1). The second set of casts (T2) were taken when all the canines and premolars had erupted. The third set of casts (T3) were taken a

**Table 2**  
Dental cast measurements (N = 25, Mean ± SD)

Variable	Pretreatment T1	Phase 2 evaluation T2	Postretention T3	Treatment T1 - T2	Postretention T2 - T3
Incisor irregularity	7.81 ± 5.25 ~(N=20)	1.04 ± 0.88	2.65 ± 2.09	-6.77 ± 4.87** ~(N=20)	+1.61 ± 1.77**
Arch length	61.40 ± 2.90	61.74 ± 2.51	58.42 ± 2.41	0.33 ± 2.65	-3.32 ± 1.19**
Intercanine	23.91 ± 1.95 ~(N=20)	26.20 ± 1.37	24.53 ± 1.42	+2.41 ± 1.80** ~(N=20)	-1.67 ± 0.96**
Intermolar	41.63 ± 2.40	43.63 ± 1.98	43.64 ± 2.36	+2.05 ± 2.66**	-0.44 ± 1.80**
Overjet	6.26 ± 2.36	2.91 ± 0.95	3.46 ± 0.95	-3.34 ± 2.88**	+0.65 ± 1.24**
Overbite	3.90 ± 2.03	2.43 ± 0.94	3.25 ± 0.97	-1.47 ± 2.09**	+0.64 ± 1.23**
Hixon-Oldfather	-0.25 ± 3.38				

Statistical significance \*\*P<.01; \*P<.05

~Irregularity index or intercanine width could not be determined because of missing primary canine

minimum of 5 years out of retention. Patients were selected without consideration of the long-term quality of the result. All efforts were made to select cases without bias. The patients were not consecutively treated but rather were selected on the basis of whether they fit the definition for inclusion. The criteria for selection were:

1. Mandibular anterior crowding of 3 mm or more measured on the initial casts (T1). Some patients showed less incisor crowding but had premature exfoliation of a primary canine with a decrease in arch length.
2. Treatment during phase 1 with a mandibular lingual arch.
3. No edgewise orthodontic treatment in the permanent dentition.
4. Good alignment of the lower dentition at the phase 2 evaluation (T2).

To reduce examiner bias, each cast was measured twice in random order by an independent examiner. An average value of the two measurements was used. The Pearson correlation analysis showed correlation coefficients greater than 0.93 for cast and x-ray measurements. Dial calipers were used (at 0.01 mm) to measure the casts and x-rays. The following measurements were performed:

*Irregularity Index (IRI)* - Sum of five linear displacements of the anatomic contact points of the lower anterior teeth from canine to canine, either deciduous or permanent. In five cases, this value could not be determined because one or both

primary canines had exfoliated.

*Mandibular arch length* - Sum of the left and right distances from the mesial anatomic contact points of the mandibular first permanent molars to the midpoint between the central incisors.

*Mandibular intercanine width* - Distance between the cusp tips or estimated cusp tips in cases with wear facets, either deciduous or permanent. Five cases were missing one or both lower primary canines at T1 and this value could not be measured.

*Mandibular intermolar width* - Distance between the mesiobuccal cusp tips or estimated cusp tips in cases with wear facets.

*Overjet* - Distance parallel to the occlusal plane from the incisal edge of the most labial maxillary incisor to the opposing mandibular central incisor.

*Overbite* - Mean overlap of the upper and lower central incisors.

*Hixon-Oldfather Analysis* - Performed on all T1 casts measuring the mesiodistal width of the four lower incisors, posterior space available, lower incisor space available, and mesiodistal width of the lower first and second premolars taken from the radiographs.

The revised prediction graph<sup>19</sup> was used to predict the size of the unerupted lower canines and first and second premolars using the above measurements. The standard error of estimate for the prediction graph is 0.44 mm. Use of the graph and the standard error of measurement yields a predicted sum of the canine and premolar

**Table 3**  
Mandibular anterior irregularity index values (mm)

	N	Class I Mean $\pm$ SD	N	Class II Mean $\pm$ SD	N	All Classes Mean $\pm$ SD	Range
Pretreatment (T1)							
Male	2	11.97 $\pm$ 7.89	3	14.16 $\pm$ 7.30	5	13.29 $\pm$ 6.60	
Female	7	7.07 $\pm$ 4.19	8	5.03 $\pm$ 1.99	15	5.98 $\pm$ 3.25	
Pooled	9	8.16 $\pm$ 5.06	11	7.52 $\pm$ 5.62	~20	7.81 $\pm$ 5.25	2.11 to 17.55
Phase 2 evaluation (T2)							
Male	5	1.20 $\pm$ 0.97	3	1.73 $\pm$ 0.44	8	1.41 $\pm$ 0.28	
Female	8	0.92 $\pm$ 1.12	9	0.82 $\pm$ 0.64	17	0.86 $\pm$ 0.87	
Pooled	13	1.03 $\pm$ 1.03	12	1.05 $\pm$ 0.72	25	1.04 $\pm$ 0.88**	0.00 to 3.19
Postretention (T3)							
Male	5	3.74 $\pm$ 3.24	3	4.58 $\pm$ 3.41	8	4.04 $\pm$ 3.08	
Female	8	2.15 $\pm$ 0.97	9	1.85 $\pm$ 1.04	17	1.99 $\pm$ 0.99	
Pooled	13	2.75 $\pm$ 2.16	12	2.53 $\pm$ 2.10	25	2.65 $\pm$ 2.09**	0.00 to 8.51

Statistical significant \*\* $P < .01$ ; \* $P < .05$

~Irregularity index could not be determined for 5 of 25 cases because primary canine was missing.

widths at the 84th percentile.

Statistical analysis involved the use of means, standard deviations and ranges for the three time periods. Differences were assessed by Student's test and one-way analysis of variance. Associations between variables were evaluated by the Pearson correlation analysis.

## Results

Mean ages for the study at the pretreatment records, phase 2 evaluation records, and postretention records (T1, T2, and T3) are shown in Table 1B. The mean age at T1 was 8 years 2 months, which is the start of early mixed dentition treatment. The mean age of 13 years 7 months at T2 represents when most of the permanent teeth had erupted for phase 2 evaluation records. The mean age at the postretention records (T3) was 27 years 11 months. There was an average postretention time of 9 years 6 months with a range of 5 years to 22 years.

Irregularity index - (Tables 2 and 3). Pretreatment values ranged considerably from 2.11 mm to 17.55 mm with a mean of 7.81 mm ( $\pm 5.2$ ). Early treatment produced acceptable alignment of the mandibular incisors at T2 (phase 2 evaluation) with a reduction of the irregularity index to 1.04 mm ( $\pm 0.88$ ). There was a significant decrease of the irregularity index of 6.77 mm ( $P < .01$ ) from T1 to T2.

At the postretention records the irregularity index was 2.65 mm ( $\pm 2.09$ ). This increase of the irregularity index from T2 to T3 of 1.61 mm showed only slight relapse of the lower incisors

during postretention. This slight relapse was statistically significant ( $P < .01$ ), but not clinically significant.

The intercanine width (Table 2) of this sample increased significantly ( $P < .01$ ) during early treatment (T1 to T2) from 23.91 mm ( $\pm 1.95$ ) to 26.20 mm ( $\pm 1.37$ ). This decreased significantly ( $P < .01$ ) during the postretention period (T2 to T3) to 24.53 mm ( $\pm 1.42$ ). Intermolar width (Table 2) increased significantly ( $P < .01$ ) during early treatment (T1 to T2) from 41.63 mm ( $\pm 2.40$ ) to 43.68 mm ( $\pm 1.98$ ). Molar width remained unchanged during the postretention period (T2 - T3). Arch length (Table 2) at T1 was 61.40 mm ( $\pm 2.90$ ) and did not change during early treatment (T1 - T2). During the postretention period, arch length was reduced to 58.42 mm ( $\pm 2.41$ ), which was statistically significant ( $P < .01$ ).

Overjet (Table 2) decreased significantly ( $P < .01$ ) during treatment (T1 - T2) from 6.26 mm ( $\pm 2.36$ ) to 2.91 mm ( $\pm 1.32$ ). During the postretention period (T3), there was a statistically significant increase in overjet. However, the increase was clinically insignificant ( $X = +0.55$  mm  $\pm 1.24$ ).

Overbite (Table 2) reduction was significant ( $P < .01$ ) during early treatment (T1 - T2) with a change from 3.90 mm ( $\pm 2.03$ ) to 2.43 mm ( $\pm 0.94$ ). The change during postretention (T2 - T3) was statistically significant, but not clinically significant with an increase in overbite of  $\pm 0.82$  mm ( $\pm 3.38$ ) with a range from -6.73 mm to +4.22 mm. The mean Hixon-Oldfather value at T1 was -0.25

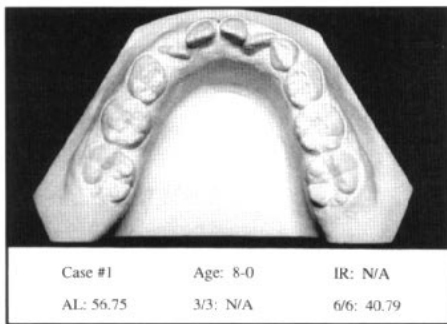


Figure 1A

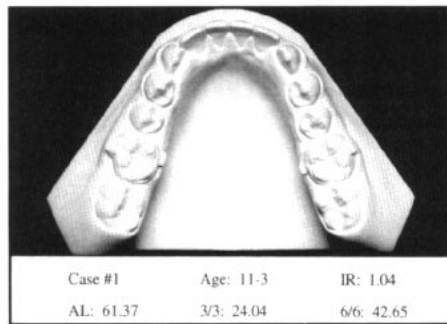


Figure 1B

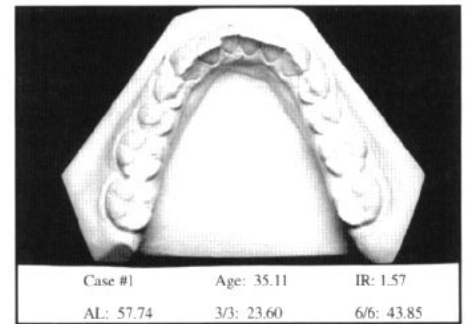


Figure 1C

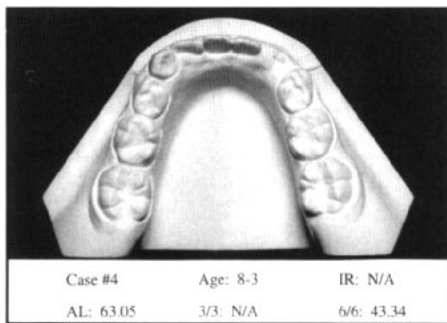


Figure 2A

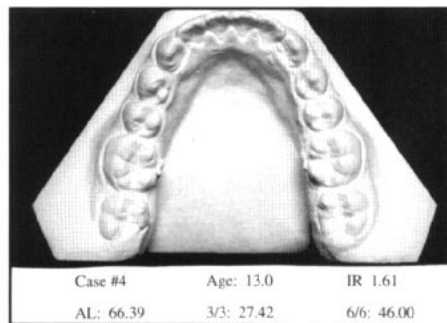


Figure 2B

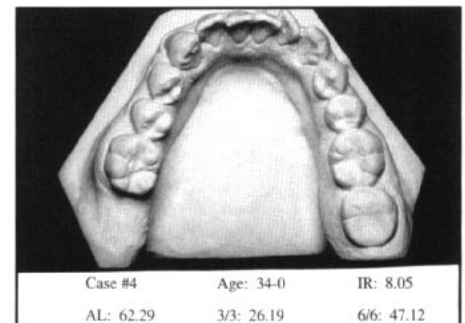


Figure 2C

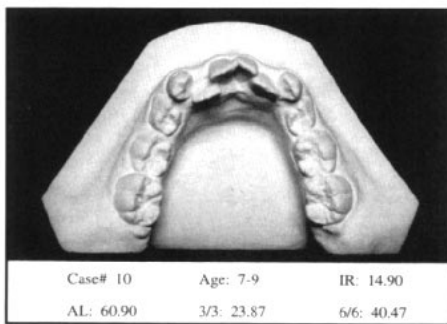


Figure 3A

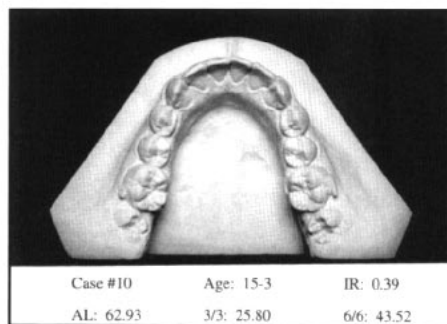


Figure 3B

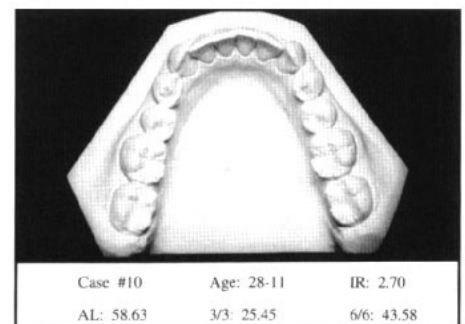


Figure 3C

**Figures 1-6** Pretreatment (A), phase 2 evaluation (B), and postretention (C) casts. Data shown represent case number, age in years and months, irregularity index, arch length, intercanine width, and intermolar width.

mm ( $\pm 3.38$ ) with a range from -6.73 mm to +4.22 mm.

**Examples**

Several typical examples are shown to help illustrate the variations in response during the posttreatment period.

**Patient #1 (Figure 1)**

This patient demonstrates typical loss of arch length during the postretention stage with an increase in the intermolar width and an acceptable irregularity index (1.57 mm) at age 35. Intercanine width showed a decrease of less than 1 mm in the postretention stage.

**Patient #4 (Figure 2)**

Similar to patient #1, arch length increased 3 mm but then decreased 4 mm in the postretention stage. Intercanine width decreased approximately 1 mm. Intermolar width typically increased and remained stable during the postretention stage. The patient demonstrated severe relapse of the lower incisors with a

postretention irregularity index of 8.05 mm.

**Patient #10 (Figure 3)**

Postretention crowding was minimal with this mixed dentition patient. Arch length increased 2 mm during treatment and decreased 4 mm in the postretention stage. However, intercanine and intermolar widths increased and remained stable postretention.

**Patient #18 (Figure 4)**

Minimal postretention incisor irregularity was noted in this case. Arch length decreased during treatment and postretention. Intercanine and intermolar widths increased during treatment and remained relatively stable postretention.

**Patient #20 (Figure 5)**

This case began with an irregularity index of 8 mm and had an acceptable irregularity index at postretention stage of 2.65 mm. Arch length increased by 4 mm during treatment and decreased by 3 mm postretention. Intercanine width increased by approximately 2.5 mm and decreased

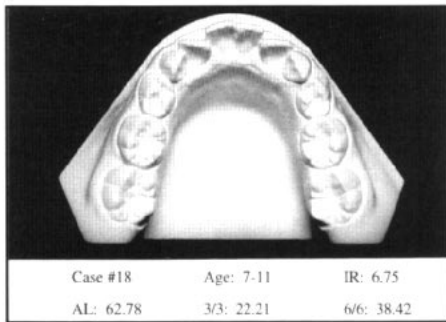


Figure 4A

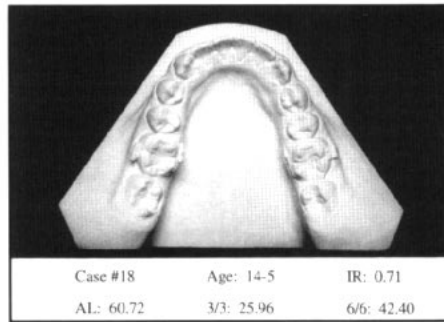


Figure 4B

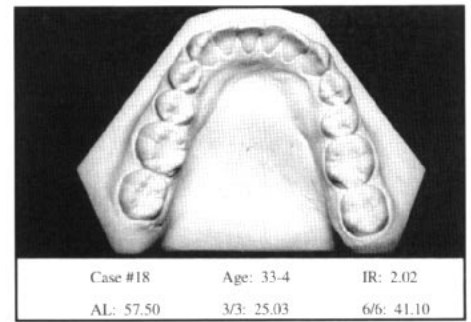


Figure 4C

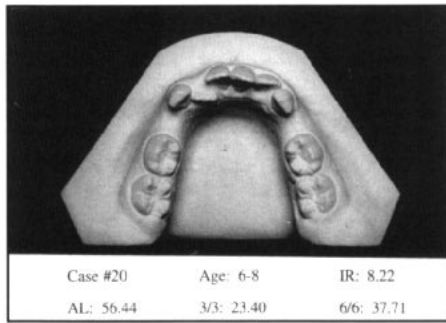


Figure 5A

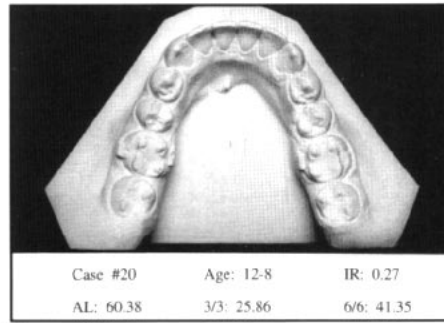


Figure 5B

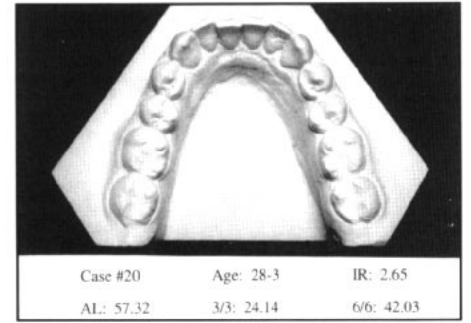


Figure 5C

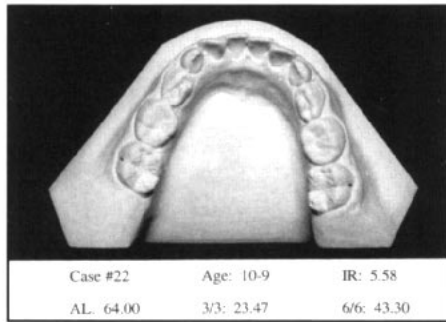


Figure 6A

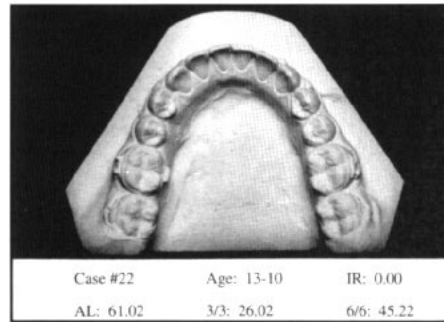


Figure 6B

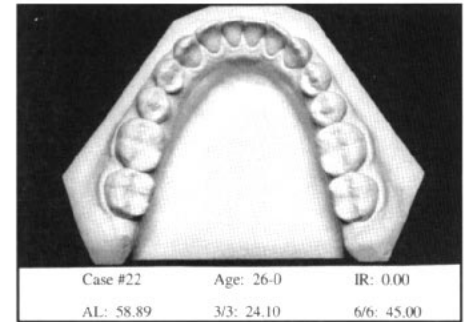


Figure 6C

by 1.5 mm postretention. This case also shows a typical intermolar width increase with treatment and stability of intermolar width postretention. **Patient #22 (Figure 6)**

This patient had perfect alignment of the lower incisors at 26 years of age (8 years postretention). Inter-canine and intermolar widths increased during treatment. However, intercanine width decreased during the postretention phase and the intermolar width increase remained stable in postretention.

### Discussion

The pretreatment irregularity index in this study was high, 7.8 mm, and larger than the pretreatment irregularity index from other stability studies.<sup>13-18</sup> Thus, this sample had as much incisor crowding at the start of treatment (T1) as the samples in other stability studies,<sup>13-18</sup> and in some cases even more.

At phase 2 evaluation (T2), the mandibular incisors demonstrated satisfactory alignment with

an irregularity index of 1.04 mm. These cases had a lingual arch in place from the start of treatment until eruption of the canines and premolars. The lingual arch was adjusted so it eventually rested at the contact points of the lower incisors, and no fixed edgewise appliances were used following lingual arch therapy. The irregularity index at T2 was comparable to other stability studies treated with fixed edgewise appliances. The lingual arch allowed for satisfactory alignment of the lower incisors at the completion of treatment (T2).

Postretention records were taken an average of 9 years after removal of all retention appliances. The irregularity index increased slightly from 1.04 mm to 2.65 mm postretention with a range of 0.5 mm to 8.5 mm. According to Little, irregularity index scores greater than 3.5 mm are considered clinically unsatisfactory. The irregularity index in this sample at the postretention stage showed satisfactory mandibular incisor align-

**Table 4**  
**Hixon-Oldfather correlation analyses**

1. H-O / IRI (T1)	$r = -.72^{**}$
2. H-O / IRI (T3)	$r = -.43^{*}$
3. H-O / A.L. (T1)	$r = .56^{**}$
4. H-O / IRI (T1 - T2)	$r = .76^{**}$
5. H-O / A.L. (T1 - T2)	$r = -.73^{**}$

$r$  = correlation coefficient,  $^{**} P < .01$ ,  $^{*} P < .05$

ment. Six of 25 patients (24%) had clinically unsatisfactory alignment of the lower incisors in the postretention stage. The Little et al.<sup>18</sup> sample was selected on the basis of treatment involving an enlargement of the mandibular arch in the mixed dentition stage by means of fixed edgewise appliances, active lingual arches, lip bumpers, or removable appliances. By contrast, this study used the passive lingual arch to preserve leeway space with no conscious effort to enlarge the mandibular arch.

Intercanine width was expanded in the treatment phase with unraveling of the crowded incisors, but most of the increase was lost in the postretention phase, similar to other stability studies.<sup>13-18</sup> Of the 25 patients, only 7 (28%) maintained the intercanine width during postretention. Although intercanine width decreased during postretention, there was a slight net overall increase of 0.62 mm from pretreatment to postretention. Stability studies have shown that intercanine width decreases with time regardless of whether the patient is treated extraction or nonextraction, or untreated. The findings of this study agree with those of other stability studies,<sup>13-18</sup> that the postretention decrease in intercanine width is not associated with an increase in incisor irregularity.

By contrast, intermolar expansion during treatment did not relapse during postretention. This finding is in contrast with other studies,<sup>13-16,18</sup> which found a decrease in intermolar width during the postretention stage. There was either no change or a slight increase in intermolar width during postretention in 15 of 25 (60%) cases. The possible explanation for stability in mandibular intermolar width may be related to maxillary arch treatment, which typically involves expansion with a 2 × 4 appliance or headgear. Perhaps establishing an intermolar width and improved occlusion in the early mixed dentition provides better stability of intermolar width treated in the early mixed dentition on a long-term basis.

Arch length was maintained or increased dur-

ing treatment. In untreated normal occlusions, arch length would normally decrease due to a loss of leeway space. All cases showed reduction of arch length during the postretention period. Seven of the 25 (28%) patients showed no loss or a slight increase in net arch length from the pretreatment to the postretention records. In other words, 18 of the 25 (72%) patients had an overall net reduction in arch length. No statistically significant associations were found between the decrease in arch length and the increase in incisor irregularity.

Early orthodontic treatment was effective in reducing overjet and overbite, and some relapse (~1.0 mm) occurred in the postretention stage. It is beyond the scope of this study to evaluate these changes further because treatment mechanics in the maxillary arch were not examined. As expected, the more negative (more crowded) cases according to the Hixon-Oldfather value were also the most crowded cases pretreatment according to the irregularity index (Table 4).

The more crowded cases with the Hixon-Oldfather analysis also showed more crowding with the irregularity index at the postretention stage ( $r = -.43$ ,  $P < .05$ ). Thus, the most crowded cases pretreatment would be the most crowded at postretention. Cases with more crowding using the Hixon-Oldfather analysis had a shorter pretreatment arch length and a greater increase in the arch length during treatment. Cases with a negative Hixon-Oldfather value at the initial records did not show a net decrease in arch length from T1 to T2, because they did not have any leeway space. By contrast, patients with a positive Hixon-Oldfather showed a decrease in arch length from T1 to T3 due to a loss of leeway following exfoliation of the second primary molars.

This study showed encouraging results with the use of a passive lingual arch in the mixed dentition. These findings are in contrast to the Little et al.<sup>18</sup> study of arch enlargement in the late mixed dentition. That study showed a severe relapse in the lower incisors in the postretention stage. Little explained that enlargement of the mandibular arch length in the mixed dentition to accommodate arch length deficiency offers no better solution for stability. In fact, that method of treatment had the poorest stability results of all the studies.

The use of the passive lingual arch in the early mixed dentition with extraction of the first primary molars did allow for good alignment of the lower incisors and satisfactory incisor alignment



in the postretention stage in the vast majority of the cases.

Comparison of the mean postretention irregularity index values in this study versus University of Washington's stability studies<sup>13-18</sup> shows the following results:

Present study:

$X = 2.65 \text{ mm} \pm 2.09 \text{ mm SD}$

Crowded first premolar extraction cases:

$X = 4.63 \text{ mm} \pm 1.91 \text{ mm SD}$

Generalized spacing cases:

$X = 3.83 \text{ mm} \pm 1.91 \text{ mm SD}$

Second premolar extraction (late extraction):

$X = 4.00 \text{ mm} \pm 1.70 \text{ mm SD}$

Serial extraction cases:

$X = 4.39 \text{ mm} \pm 1.64 \text{ mm SD}$

Mixed dentition arch length increase cases:

$X = 6.06 \text{ mm} \pm 2.79 \text{ mm SD}$

Single incisor extraction cases:

$X = 0.62 \text{ mm} \pm 0.30 \text{ mm SD}$

On the basis of the irregularity index, the present study shows acceptable alignment of mandibular incisors at the postretention stage. The single incisor extraction sample and generalized spacing cases also had an acceptable irregularity index value at T3.

There are several possibilities as to why these early treatment cases show better incisor stability in the postretention stages. Early mixed dentition treatment with a lingual arch allowed for ideal alignment of the lower incisors at a young age of approximately 9 years. The mandibular incisors were held in good alignment with the lingual arch for approximately the next 3 years, through the eruption of all the permanent teeth. Thus, the incisors were in a crowded position for a short period of time before the removal of mandibular first primary molars and alignment with a passive lingual arch.

The supracrestal fibers could reorganize at an early age around the incisors in their aligned position.<sup>20</sup> Most of these cases received supracrestal fiberotomy and interproximal enamel reduction during retention which has been reported to provide stability of rotated teeth.<sup>21,22</sup> These cases allowed for alignment of the lower incisors via utilization of leeway space. This use of leeway space to unravel lower incisor crowding may provide better mandibular incisor stability.

The limitations of this study include the irregularity index, which is not always a true indication of crowding. Individuals with a zigzag-type

crowding pattern may actually have more crowding than recorded by the irregularity index. The study would benefit from longer postretention records. It would be interesting to re-evaluate the sample with a minimum of 10-year postretention records to further test stability. Finally, a larger sample size would allow male versus female differences to be evaluated with statistical analysis.

## Conclusions

The mandibular lingual arch allowed for good alignment of the lower incisors and reduced the anterior crowding to a value close to zero. The lingual arch was as effective as fixed edgewise appliances in the reduction of anterior crowding. Intercanine and intermolar widths increased significantly during treatment, and intermolar width was held postretention. Intercanine width decreased significantly during postretention. Mandibular arch length did not decrease during the mixed dentition, but decreased during the postretention stage. The Hixon-Oldfather analysis correlated strongly with the irregularity index as an indicator for pretreatment mandibular incisor crowding, and there was a weaker correlation that it may serve as an indicator for crowding in the postretention stage. No other predictors or associations could be found to help clinicians in determining the long-term prognosis in terms of stability. The lower incisor alignment was clinically acceptable in 76% of cases in the postretention stage.

## Acknowledgments

A special thanks to Jamie Chappell for her persistence in contacting patients for the long-term records and to Rhodora Silverman for her diligent preparation of the manuscript.

## Author Address

Dr. Steven A. Dugoni  
1131 Mission Road  
South San Francisco, CA 94080

*S.A. Dugoni is an associate clinical professor at the University of the Pacific, School of Dentistry, Department of Orthodontics, San Francisco, Calif.*

*J.S. Lee is an assistant clinical professor at the University of the Pacific, School of Dentistry, Department of Orthodontics.*

*J. Varela is in private practice in Madrid, Spain.*

*A.A. Dugoni is dean and professor of orthodontics, University of the Pacific, School of Dentistry.*

## References

1. Angle EH. Treatment of malocclusions of teeth. 7th Edition, Philadelphia, 1907.
2. Wright GZ, Kennedy DB. Space control in the primary and mixed dentition. *Dent Clin N Amer* 1978; 22:579-601.
3. Eastwood AW. Lingual arch and space control. *Dent Clin N Amer* 1968;July:283-397.
4. Singer J. Effect of a passive lingual arch on the lower denture. *Angle Orthod* 1974; 44:146-155.
5. Odom WM. Mixed dentition treatment with cervical traction and lower lingual arch. *Angle Orthod* 1983;53:329-342.
6. Moorrees CA. The dentition of the growing child. Cambridge Harvard University Press, 1959.
7. Barrow DB, White JR. Developmental changes of the maxillary and mandibular dental arches. *Angle Orthod* 1952;22:41-46.
8. Sillman JH. Dimensional changes of the dental arches: Longitudinal study from birth to 25 years. *Am J Orthod* 1964;50:824-841.
9. Sinclair P, Little R. Maturation of untreated normal occlusions. *Am J Orthod* 1983;83:114-123.
10. Little R. The Irregularity Index: A quantitative score of mandibular anterior alignment. *Am J Orthod* 1975;68:554-563.
11. Gardner R. A comparison of four methods of predicting arch length. *Am J Orthod* 1979;75:387-398.
12. Hixon EH, Oldfather RE. Estimation of sizes of unerupted cuspids and bicuspid teeth. *Angle Orthod* 1958;28:236-240.
13. Little R, Wallen T, Riedel RA. Stability and relapse of mandibular anterior alignment - first premolar extraction cases treated by traditional edgewise appliances. *Am J Orthod* 1981;80:349-365, 1981.
14. Little R, Riedel RA, Årtun J. An evaluation of changes in mandibular anterior alignment from 10 to 20 years postretention. *Am J Orthod* 1988;93:423-428.
15. McReynolds DC, Little R. Mandibular second premolar extraction - postretention evaluation of stability and relapse. *Angle Orthod* 1991;61:133-144, 1991.
16. Little R, Riedel RA, Engst ED. Serial extraction of first premolars - postretention evaluation of stability and relapse. *Angle Orthod* 1990;60:255-262.
17. Riedel RA, Little R, Bui TD. Mandibular incisor extraction - postretention evaluation of stability and relapse. *Angle Orthod* 1992;62:103-116.
18. Little R, Riedel RA, Stein A. Mandibular arch length increase during mixed dentition treatment - postretention evaluation of stability and relapse. *Am J Orthod Dentofac Orthoped* 1990;97:393-404.
19. Bishara SE, Staley RN. Mixed dentition mandibular arch length analysis. A step by step approach using the revised Hixon-Oldfather prediction method. *Am J Orthod* 1984;6:130-135.
20. Edward JG. A surgical procedure to eliminate rotational relapse. *Am J Orthod* 1970;57:35-46.
21. Boese LR. Fiberotomy and reproximation without lower retention, nine years in retrospect. Part 1. *Angle Orthod* 1980;50:88-97.
22. Boese LR. Fiberotomy and reproximation without lower retention, nine years in retrospect. Part 2. *Angle Orthod* 1980;50:169-178.