

# Repair of orthodontically induced root resorption in adolescents

Py Owman-Moll, DDS, Odont Dr; Jüri Kuroi, DDS, Odont Dr; Dan Lundgren DDS, Odont Dr

**R**oot surface resorption is a common phenomenon associated with orthodontic treatment. Many investigators have attempted to elucidate factors that contribute to and/or cause root resorption. These factors include the magnitude of applied force,<sup>1,4</sup> the duration of force application,<sup>2,5-9</sup> the type of orthodontic appliance,<sup>10-12</sup> the type of applied force,<sup>13-15</sup> and individual variations.<sup>3,4,9,15-17</sup> However, few investigations of the reparative potential of root resorption have been published.<sup>8,18-21</sup>

In orthodontic patients, the healing process of a resorption cavity is believed to start when orthodontic force is discontinued or reduced to below a certain level.<sup>22-23</sup> It may be seen simulta-

neously with the resorption process.<sup>2,5,9,19</sup> Henry and Weinmann<sup>18</sup> found in an autopsy material of adults that 72% of the resorptive areas showed anatomic (full) repair. (They did not state whether orthodontic treatment had been performed.) Vardimon et al.,<sup>21</sup> in a study of 8 adolescent monkeys subjected to palatal expansion, reported that repairs were mainly partial restorations, functional or nonfunctional, depending on the rate of deposition of repair tissue (rapid/slow) and the development of extrinsic fibers (present/absent). Also, the amount of repair seemed to increase with time after maxillary expansion.<sup>20,24</sup>

Most studies concerning the healing pattern of

## Abstract

The aim of this investigation was to study the reparative potential of orthodontically induced root resorption. Sixty-four maxillary right and left first premolars in 32 patients (15 boys and 17 girls, mean age 13.7 years) were moved buccally with fixed orthodontic appliances and a continuous force of 50 cN ( $\approx$ 50 g), activated weekly for 6 weeks. The patients were divided into 4 groups of 8. Retention periods varied from 1 week to 8 weeks. Histological preparations showed that root resorption affected all the test teeth. The percentage of resorptive areas that had begun to repair ranged from 28% after 1 week of retention to 75% after 8 weeks. The healing cementum was almost exclusively of the cellular type. Partial repair, with the resorption cavity walls only partially covered with cementum, was the most frequent type of repair during the first 4 weeks of retention (17% to 31%). Functional repair, with the total surface of the resorption cavity walls covered with varying thicknesses of cementum, dominated after 5, 6, 7 and 8 weeks of retention (33% to 40%). There were no large differences in the healing potential in the cervical, middle, and apical thirds of the root. After 8 weeks, three out of four resorptive areas showed some degree of repair. Individual variations in healing potential were large.

## Key Words

Adolescence • Adverse effects • Histology • Repair • Root resorption

Submitted: September 1994

Revised and accepted: January 1995

Angle Orthod 1995;65(6):403-410.

| Group | Orthodontic tooth movement | Retention periods |                         |
|-------|----------------------------|-------------------|-------------------------|
|       |                            | 6 weeks           | Right side    Left side |
| 1     | 8 individuals              | —*—*—*—*—*—*—     | 1 week    -    5 weeks  |
| 2     | 8 individuals              | —*—*—*—*—*—*—     | 2 weeks    -    6 weeks |
| 3     | 8 individuals              | —*—*—*—*—*—*—     | 3 weeks    -    7 weeks |
| 4     | 8 individuals              | —*—*—*—*—*—*—     | 4 weeks    -    8 weeks |

\* denotes weekly reactivation of the force to 50 cN

**Figure 1**  
**Experimental design.** The maxillary first premolars were moved buccally during 6 weeks with a continuous force of 50 cN, activated weekly. Sixteen test teeth in each of 4 groups were retained for 1 or 5 weeks, 2 or 6 weeks, 3 or 7 weeks, or 4 or 8 weeks. Each group comprised 8 individuals.

orthodontically induced root resorption have been carried out after maxillary transverse expansion,<sup>6,8,19-21,24,25</sup> when applied forces are often higher than in conventional treatment with a fixed appliance. Root surface resorption has been registered in almost 7% of the root contour in a histological section after only 7 weeks of routine orthodontic tooth movement with small forces (35 to 50 cN).<sup>9</sup> The possibility of repair of such resorptive areas, the potential for full or partial repair of the cavity, and the relationship of repair and time have not been fully elucidated.

The aim of this investigation was to study the early time-related healing patterns of orthodontically induced root resorption following the cessation of a commonly used, controlled force of 50 cN

**Material and methods**

**Experimental design and orthodontic appliance**

Maxillary right and left first premolars in 32 individuals (15 boys and 17 girls, 11.3 to 17.3 years old, mean 13.7 years) constituted the test teeth. The patients had been referred for orthodontic treatment and showed bilateral maxillary crowding or maxillary protrusion. Orthodontic treatment for these patients would include bilateral first premolar extractions, with the extractions postponed for the purpose of this study. The design of this study was approved by the Ethics Committee of the Medical Faculty, Göteborg University, Sweden.

The 64 test teeth were moved buccally with a fixed orthodontic appliance and a sectional archwire (Sentalloy 0.018 inch heavy, Tomy, Tokyo, Japan). A continuous, horizontal<sup>26</sup> force of 50 cN (» 50 g), controlled and reactivated weekly, was applied for 6 weeks. Then a passive sectional archwire (Blue Elgiloy 0.017 x 0.022 inch heavy, Rocky Mountain Orthodontics, Denver, Colo) was applied for retention. The archwire was activated by bending the wire just mesial to the molar tube. The passive retentional archwire was adjusted to fit the bracket on the orthodontically moved test teeth. The experiment design is out-

lined in Figure 1. The patient material was subdivided into 4 groups of 8 individuals. Retention periods varied from 1 to 8 weeks, with 4 weeks intraindividual difference between sides.

At the end of the experimental period, the teeth were extracted with forceps. After routine histologic preparation, the teeth were step-serially sectioned longitudinally in a buccopalatal direction (3 levels, 0.3 mm apart) with the microtome set to 4 µm, then stained with hematoxylin and eosin.

**Registration of root resorption and repair**

A light microscope was used to register root resorption and repair on one randomly chosen histological section from each of three different sectional levels.<sup>9</sup> In order to describe the location of the findings, the root was divided into three parts: cervical, middle, and apical. Surface extension and depth of each resorption lacuna was measured to the nearest 1 arbitrary unit (≈1.33 µm ≈ 0.0133 mm) using a scale placed in the eyepiece of the microscope. Resorptive cavities measuring 5 arbitrary units (≈65 µm ≈ 0.07 mm) or more were registered. This corresponds roughly to the size of a multinucleated resorbing cell. Small (<5 arbitrary units), closely spaced cavities were registered as one area. No distinction was made between resorptive areas with multinucleated cells and those in which the resorption process seemed to have stopped without any cementum deposition. Repair was registered whenever a lacuna revealed any secondary cementum.

The following registrations of repair were made:

- No repair, Figure 2B.
- Partial repair. Part of the surface of the resorption cavity was covered with reparative cementum, Figure 2C-D.
- Functional repair. The total surface of the resorption cavity was covered with reparative cementum without reestablishment of the original root contour, Figure 2E.
- Anatomic repair. The total surface of the resorption cavity was covered with reparative cementum to such an extent that the original root contour was reestablished, Figure 2F.

All registrations on histological sections were performed by one of the authors (P.O.M.)

**Statistical analyses**

The correlation between the total number of resorptive areas and the number of resorptive areas showing repair independent of time was studied by means of an analysis of variance (ANOVA). Intraindividual variations of reparative potential were investigated using a paired

Downloaded from http://meridian.allenpress.com/angle-orthodontist/article-pdf/65/6/403/1373471/0003-3219(1995)065\_0403\_1rootr\_2\_0\_co\_2.pdf by guest on 25 November 2020

t-test. The statistical analysis was performed using the StatView 4.0 computer program (Abacus Concepts, Inc, Berkeley, Calif, 1992).

### Results

Resorptive areas were registered for all 64 test teeth, with great individual variation (between 2 and 35, average  $15 \pm 7$ ), in three histological sections of each experimental tooth. Resorptive areas were located primarily in the apical and cervical thirds of the root (55% and 32%, respectively).

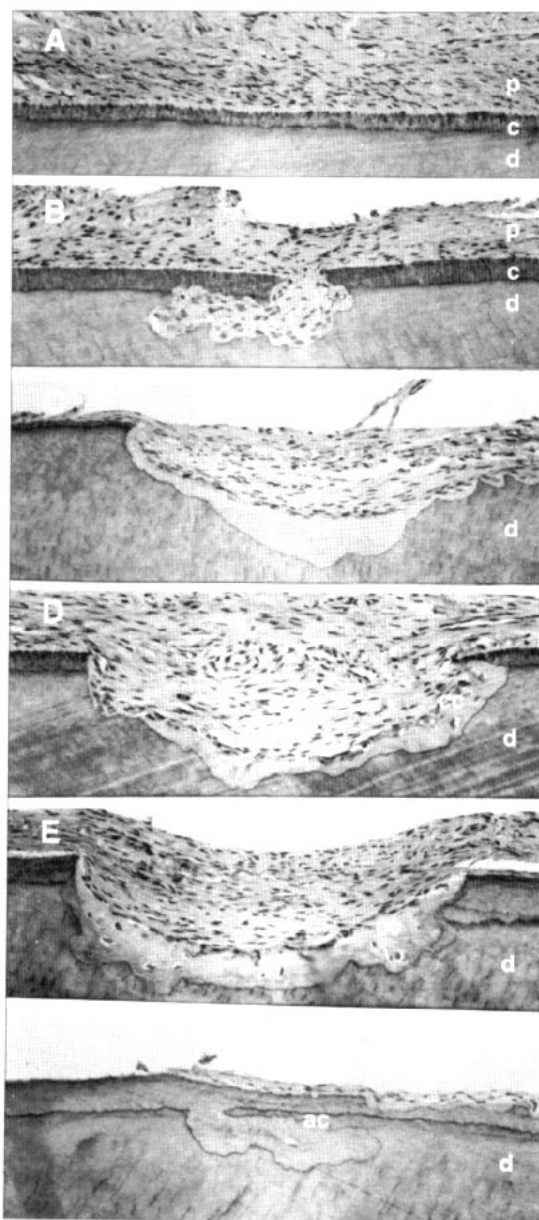
The amount of repair increased with time. After 1 week, 28% of the resorption lacunae showed some degree of repair; after 8 weeks, that number rose to 75% (Figure 3). Figure 4 illustrates the distribution of open resorption areas and the three types of repair. Partial repair was registered more often (17% to 31%) than functional or anatomic repair during the first 4 weeks of retention. After 5 to 8 weeks with a passive sectional archwire, functional repair dominated the repair process (33% to 40%). Resorptive areas with anatomic repair were registered 6 times more often after 8 weeks of retention than they were after 1 week (12% and 2%, respectively). However, after 8 weeks of retention with a passive appliance, almost half of the resorptive areas showed open dentin tubuli, i.e., unrepaired, open spots (26%) or partial repair (23%).

The distribution of resorptive areas with secondary cementum was almost the same in the cervical, middle, and apical thirds of the root (56%, 55%, and 66%, respectively). Partial repair was registered most often in the cervical part of the root while anatomic repair was found primarily in the middle and apical parts. Anatomic repair was seen nine times more often in the apical third compared with the cervical third of the root (Figure 5).

There were significantly more resorptive areas with varying degrees of repair after a retention period of 5 weeks than there were after 1 week. Similarly, more repair was evident after 6 weeks than after 2, and more after 7 weeks than after 3 ( $P < 0.001$ ). However, there was no significant difference in reparative potential after 8 weeks of retention than after 4 weeks. There were large individual variations in repair of root resorption, with no association between right and left sides in each individual (Figure 6A,B).

The healing cementum was almost exclusively of the cellular type. A tiny layer of acellular repair cementum partly covered the surfaces of less than 1% of the resorption lacunae.

An analysis of variance revealed a significant



**Figure 2**  
**Histological illustration of varying degrees of repair in orthodontically induced root resorption in maxillary premolars after 1 to 8 weeks retention.**

**A.** Root surface in the cervical third of the root with normal dentin (d), acellular root cementum (c), and periodontal ligament (p).

**B.** Undermined root resorption in the cervical third of the root. Dentin (d), cementum (c), periodontal ligament (p).

**C.** Partial repair with acellular cementum (ac) in the cervical third of the root. Dentin (d).

**D.** Partial repair with cellular cementum (cc) in the apical third of the root. Dentin (d).

**E.** Functional repair with cellular cementum (cc) in the apical third of the root. Dentin (d).

**F.** Anatomic repair with acellular cementum (ac) in the middle third of the root. Dentin (d).

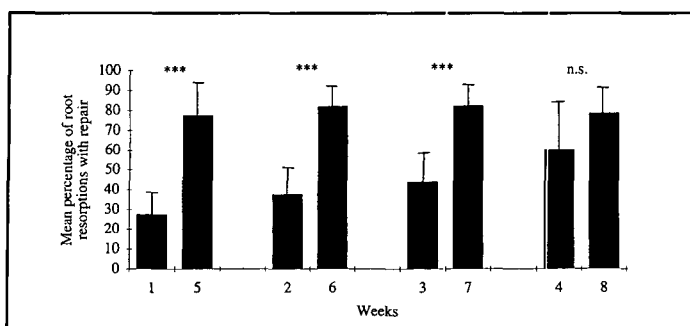


Figure 3

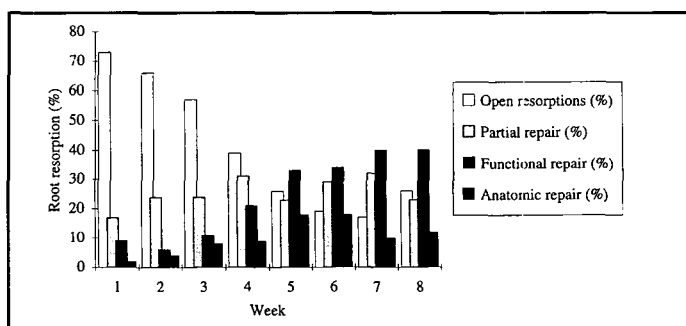


Figure 4

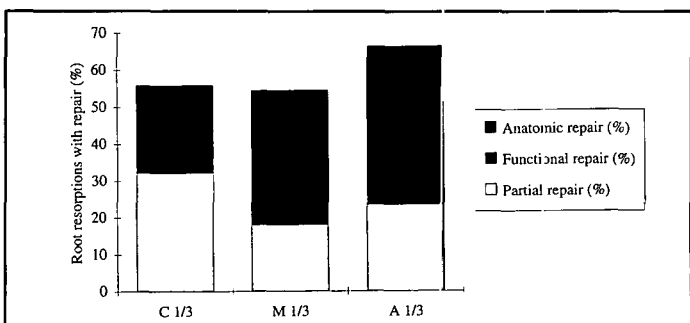


Figure 5

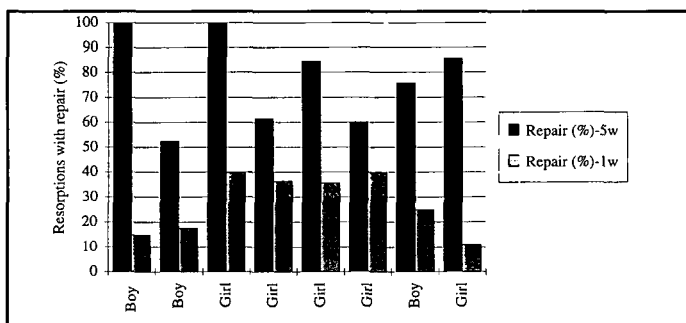


Figure 6A

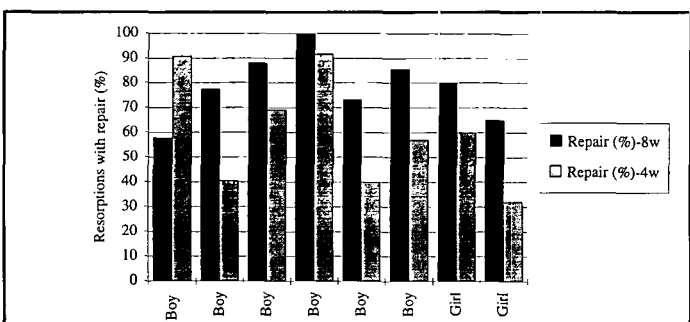


Figure 6B

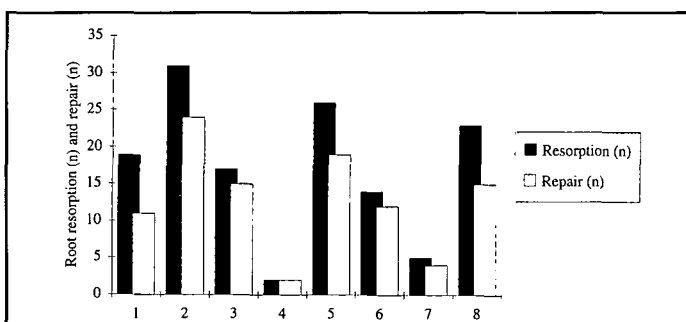


Figure 7

**Figure 3**  
Root resorptions with varying degrees of repair (mean and SD) in 64 test teeth after 6 weeks of force application followed by 1 to 8 weeks of retention with a passive sectional arch.

**Figure 4**  
Distribution of open resorptive areas and areas with partial, functional, and anatomic repair (%) in 64 maxillary premolars after 6 weeks of force application followed by 1 to 8 weeks of retention.

correlation ( $p < 0.0001$ ) between the total number of resorptive areas and the number showing various degrees of repair (Figure 7). However, there was no correlation between the number of lacunae with varying degrees of repair and age or sex.

**Discussion**

This clinical investigation showed that early repair with varying degrees of reparative cementum was frequently registered in root resorption after discontinuation of an orthodontic force of 50 cN, and that the amount of repair was related to time.

In order to study the effects of repair over a 4-week period, this investigation was outlined with 4-week intraindividual differences in periods of retention. Although the experimental premolar on the right side was extracted 4 weeks earlier than the contralateral premolar, there was probably no mechanical interference on the reparative potential in the left side tooth due to

retention with a heavy archwire. Moreover, the occlusal forces were reduced by use of an anterior acrylic bite block. Whether the repair could have been influenced by the healing process of the alveolus after extraction is open to speculation.

The orthodontically induced root resorption in young individuals in this study was repaired almost exclusively with cellular cementum (Figure 2D,E). This is in agreement with earlier investigations in patients of about the same age.<sup>6,19,20</sup> Vardimon et al.<sup>21</sup> reported similar results in an investigation using monkeys. It was hypothesized that the cells were inclusions of rapidly growing tissue. This may explain why primarily cellular cementum was registered in the present investigation in young individuals in whom regeneration processes are faster and cells more easily captured by growing repair tissue.

Resorption lacunae with secondary cementum were distributed with almost the same frequency in the cervical, middle, and apical parts of the

root. This may lead to the assumption that tooth movement was primarily bodily and the applied force was evenly distributed over the entire root length. However, in an earlier study<sup>26</sup> in this series of investigations, using the same type of appliance and the same magnitude of force, tooth movement was found to be mainly a tipping displacement when registered in a coordinate measuring machine. The even distribution of secondary cementum in a coronal-apical direction in this study may be explained by the use of a passive sectional arch during the retention period in combination with an anterior bite block. Thus, the test tooth was kept in a steady position without interference from relapse and occlusal forces, which allowed the healing process to continue evenly all over the root surface.

Partial repair was most often seen in the cervical third of the root and anatomic repair in the apical third. Since there was no difference in the frequency of deep root resorption lacunae between the cervical and apical parts of the root, the finding is somewhat surprising and we cannot find an explanation.

In this report, the healing pattern was investigated for 8 weeks. For ethical and practical reasons, observations were limited to this time period, which may seem short considering earlier reports dealing with retention periods of 16 weeks with 8 weeks of relapse in monkeys,<sup>8,21</sup> or 53 weeks in humans.<sup>19,20,25</sup> Vardimon et al.<sup>21</sup> reported that the healing process in monkeys reached a steady phase after 42 to 56 days. The present study in adolescent humans revealed a rapid healing potential during the first 7 weeks, after which a slowdown was noted (Figure 4), although there was no significant difference in the number of resorptive areas with secondary cementum after 7 and 8 weeks of retention. After 8 weeks, 49% of the resorption lacunae were still not covered with repair cementum or were only partially covered.

What happens with the healing process in the long run? It has been stated that all resorption lacunae may be repaired once the cause of the resorption ceases.<sup>11,18,22</sup> Vardimon et al.<sup>8</sup> agreed, as long as the total unresorbed surface area exceeds the total resorbed area. Two years after

rapid expansion and discontinuation of retention, evidence of recent root resorption and repair may remain.<sup>25</sup> Such information is difficult to interpret and relate to the test situation because long observation periods out of retention may influence the results, through function, habits, trauma, treatment, systemic factors, etc. (See Brezniak and Wasserstein<sup>27</sup> for a review.) In the present investigation, some possible disturbing factors that might overshadow the results were eliminated. The healing potential after orthodontic treatment was studied during active retention, i.e., relapse with reversed tooth movement, and perhaps further resorption was prevented. Moreover, occlusal forces were reduced by the anterior bite block disengaging the occlusion. Related to the findings in this study, the average number of resorption lacunae showing repair increased three-fold, from 28% after 1 week to 75% after 8 weeks. It would be tempting to assume or hope that, with time, the open lacunae would all be repaired.

#### Summary

The potential for repair in young individuals seems to be considerable. Repair could already be seen after one week of retention. After 8 weeks with a passive appliance, 3 out of 4 resorptive areas showed signs of healing. On the other hand, after 8 weeks of retention, almost 50% of the lacunae surfaces showed no repair or only partial coverage with healing cementum.

#### Author Address

Py Owman-Moll  
Department of Orthodontics  
Faculty of Odontology  
Medicinaregatan 12  
413 90 Göteborg, Sweden

*Py Owman-Moll, DDS, Odont Dr, Department of Orthodontics, Faculty of Odontology, Göteborg University, Göteborg, Sweden.*

*Jüri Kurol, DDS, Odont Dr, Department of Orthodontics, Institute for Postgraduate Dental Education, Jönköping, Sweden*

*Dan Lundgren DDS, Odont Dr, Department of Periodontology, Institute for Postgraduate Dental Education, Jönköping, Sweden*

#### Facing Page:

**Figure 5**  
Distribution of varying degrees of repair (%) in each third of the root after 1 to 8 weeks of retention: cervical third (C 1/3), 56%; middle third (M 1/3), 55%; and apical third (A 1/3), 66%.

**Figure 6**  
A. Distribution of repair cementum (%) after 6 weeks of orthodontic treatment followed by a retention period of 1 week on the right side and 5 weeks on the left side in 16 maxillary first premolars in 8 individuals.

B. Distribution of repair cementum (%) after 6 weeks of orthodontic treatment followed by a retention period of 4 weeks on the right side and 8 weeks on the left side in 16 maxillary first premolars in 8 individuals.

**Figure 7**  
Total number of resorptive areas, and number of areas with various degrees of repair with secondary cementum in the maxillary first premolars in 8 patients. The test teeth were moved with a buccally directed continuous force of 50 cN for 6 weeks, after which a passive sectional arch was applied as retention for 8 weeks.

## References

1. Reitan K. Initial tissue behavior during apical root resorption. *Angle Orthod* 1974;44:68-82.
2. Harry MR, Sims MR. Root resorptions in bicuspid intrusion. A scanning electron microscope study. *Angle Orthod* 1982;52:235-258.
3. Owman-Moll P, Kurol J, Lundgren D. Effects of a doubled orthodontic force magnitude on tooth movement and root resorptions. An interindividual study in adolescents. *Eur J Orthod*. Accepted for publication.
4. Owman-Moll P, Kurol J, Lundgren D. The effects of a four fold increased force magnitude on tooth movement and root resorptions. An intraindividual study in adolescents. *Eur J Orthod*. Accepted for publication.
5. Stenvik, A, Mjör, I. Pulp and dentine reactions to experimental tooth intrusion. A histologic study of the initial changes. *Am J Orthod* 1970;57:370-385.
6. Lilja E, Odenrick L. Root resorption following slow maxillary expansion. *Swed Dent J Suppl.* 15, 1982;123-129.
7. Dermaut LR, DeMunck A. Apical root resorption of upper incisors caused by intrusive tooth movement: A radiographic study. *Am J Orthod Dentofac Orthop* 1985;90:321-326.
8. Vardimon AD, Graber TD, Voss LR, Lenke J. Determinants: controlling iatrogenic external root resorptions and repair during and after palatal expansion. *Angle Orthod* 1991;61:113-122.
9. Kurol J, Owman-Moll P, Lundgren D. Time-related root resorptions after application of a controlled continuous force. *Am J Orthod Dentofac Orthop*. In press.
10. Malmgren O, Goldson L, Hill C, Orwin A, Petrini L, Lundgren M. Root resorption after orthodontic treatment of traumatized teeth. *Am J Orthod* 1982;82:487-491.
11. Ohm Linge B, Linge L. Apical root resorption in upper anterior teeth. *Eur J Orthod* 1983;5:173-183.
12. Linge L, Ohm Linge B. Patient characteristics and treatment variables associated with apical root resorption during orthodontic treatment. *Am J Orthod Dentofac Orthop* 1991;99:35-43.
13. Reitan K. The initial tissue reaction incident to orthodontic tooth movement. A relation to the influence of function. *Acta Odont Scand suppl.* 6, 1951.
14. Reitan K. Effects of force magnitude and direction of tooth movement on different alveolar bone types. *Angle Orthod* 1964;34:244-255.
15. Owman-Moll P, Kurol J, Lundgren D. Continuous versus interrupted continuous orthodontic force related to early orthodontic tooth movement and root resorption. *Angle Orthod* 1995;65(6):395-402.
16. Becks H. Orthodontic prognosis: Evaluation of routine dentomedical examinations to determine "good and poor risks." *Am J Orthod Oral Surg* 1939;25:610-624.
17. Zachrisson BU. Cause and prevention of injuries to teeth and supporting structures during orthodontic treatment. *Am J Orthod* 1976;69:285-300.
18. Henry JL, Weinmann JP. The pattern of resorption and repair of human cementum. *J Am Dent Assoc* 1951;42:270-289.
19. Barber AF, Sims MR. Rapid maxillary expansion and external root resorptions in man: A scanning electron microscope study. *Am J Orthod* 1981;79:630-652.
20. Langford SR, Sims MR. Root surface resorption, repair and periodontal attachment following rapid maxillary expansion in man. *Am J Orthod* 1982;81:108-115.
21. Vardimon AD, Graber TM, Pitaru S. Repair process of external root resorption subsequent to palatal expansion treatment. *Am J Orthod Dentofac Orthop* 1993;103:120-130.
22. Rygh P. Orthodontic root resorptions studied by electron microscopy. *Angle Orthod* 1977;47:1-16.
23. Reitan K. Biomechanical principles and reactions. In: Graber TM, Swain BF, editors. *Orthodontics. Current Principles and Techniques*, pp. 101-192. St. Louis: Mosby, 1985.
24. Odenrick L, Lilja Karlander E, Pierce A, Kretschmar U. Surface resorption following two forms of rapid maxillary expansion. *Eur J Orthod* 1991;13:264-270.
25. Timms DJ, Moss JP. An histological investigation into the effects of rapid maxillary expansion on the teeth and their supporting tissue. *Trans Eur Orthod Soc* 1971;263-271.
26. Lundgren D, Owman-Moll P, Kurol J. Early tooth movement pattern after application of a controlled continuous orthodontic force. A human experimental model. *Am J Orthod Dentofac Orthop*. In press.
27. Brezniak N, Wasserstein A. Root resorption after orthodontic treatment: Part 2. Literature Review. *Am J Orthod Dentofac Orthop* 1993;103:138-146.

## Commentary: Repair of orthodontically induced root resorption in adolescents

Peter Ngan, DMD

Most clinicians are aware that rapid maxillary expansion exerts forces on anchor teeth far in excess of customary orthodontic forces. Alveolar dehiscences, fenestration, and external root resorption (ERR) have been cited as possible deleterious effects resulting from indiscriminate dental arch expansion. But does ERR occur with routine orthodontic tooth movement with light forces of around 50 g? If so, what kind of repair processes do our bodies possess?

The paper by Owman-Moll et al. addresses these clinical questions. The authors are to be congratulated for the ingenious method of studying root resorption and repair following orthodontic tooth movement in young human patients. They used fixed orthodontic appliances and a continuous force of 50 g, activated weekly for 6 weeks, to move 64 maxillary right and left premolars buccally. Then they made the appliance passive for 1 to 8 weeks, using a rectangular wire to prevent relapse and a bite plane to eliminate occlusal interferences. By using the contralateral premolars as controls, the authors were able to study intraindividual differences during the retention period.

Previous animal studies have shown that the onset of ERR is related to impulse (force/time) and narrowing of the periodontal ligament.<sup>2,3</sup> For example, the turning of a jack screw in the case of treatment with RPE substantially increases the magnitude of the impulse. During tipping movement, when the center of rotation is located apical to the center of resistance, no change in periodontal ligament width is expected at the narrowest width. Conversely, substantial changes are expected in root extremities. Thus, more marginal root areas are prone to ERR assault. In the present study, the authors showed that with buccal tipping of premolars, resorption lacunae were registered in all teeth with great individual variation. Furthermore, the distribu-

tion of resorption lacunae with secondary cementum was almost the same in the cervical, middle, and apical thirds. However, the authors did not discuss the reasons for the uniformity of root resorption and repair along the root surface. Is it because the movement is more translatory than tipping?

The authors reported that repair started 1 week after the insult and that 75% of the registered resorptive areas showed signs of repair by the eighth week. They went on to describe the type of repair. Partial repairs were registered during the first 4 weeks and anatomic repair was registered with longer periods of retention. In addition, partial repair was the dominating form of healing in the cervical part of the root while anatomic repair was seen more often in the apical third of the root. Intuitively, wouldn't one expect more resorption around the apical third of the root with buccal tipping and less repair due to the ongoing process of resorption?

Clinically, the present study should alert clinicians to the presence of ERR in routine orthodontic tooth movement. On the other hand, there is a sign of relief to know that repair starts as early as 1 week after the insult. In particular, repair with cellular cementum was found in young patients in which there was rapidly growing tissue. However, it is cautioned that after 8 weeks of retention, 49% of the resorption lacunae are not covered or are only partly covered with repair cementum. Total healing times must be far greater than the 8-week period of the present study. If we do not allow enough time for repair, it is possible that, in patients who require orthodontic treatment for more than 3 or 4 years, the problems will be compounded to produce "unhealed ERR" that can be observed on posttreatment radiographs.

*Peter Ngan is chairman of the Department of Orthodontics, West Virginia University, Morgantown, West Virginia.*

References

1. Watson WG. Expansion and fenestration or dehiscence (editorial). *Am J Orthod* 1980;77:330-332.
2. Vardimon AD. Determinants controlling iatrogenic external root resorption and repair during and after palatal expansion. *Angle Orthod* 1990;61:113-124.
3. Goz G, Rakosi T. Die apikale Wurzelresorption unter kieferorthopädischer Behandlung. *Fortschr Kieferorthop* 1989;50:196-206.
4. Reitan K. Effects of force magnitude and duration of tooth movement on different alveolar bone types. *Angle Orthod* 1953;34:244-255.