

An Improved Version of the Cervical Vertebral Maturation (CVM) Method for the Assessment of Mandibular Growth

Tiziano Baccetti, DDS, PhD^a; Lorenzo Franchi, DDS, PhD^a; James A. McNamara Jr, DDS, PhD^b

Abstract: The present study aimed to provide a version of the Cervical Vertebral Maturation (CVM) method for the detection of the peak in mandibular growth based on the analysis of the second through fourth cervical vertebrae in a single cephalogram. The morphology of the bodies of the second (odontoid process, C2), third (C3), and fourth (C4) cervical vertebrae were analyzed in six consecutive cephalometric observations (T₁ through T₆) of 30 orthodontically untreated subjects. Observations for each subject consisted of two consecutive cephalograms comprising the interval of maximum mandibular growth (as assessed by means of the maximum increment in total mandibular length, Co-Gn), together with two earlier consecutive cephalograms and two later consecutive cephalograms. The analysis consisted of both visual and cephalometric appraisals of morphological characteristics of the three cervical vertebrae. The construction of the new version of the CVM method was based on the results of both ANOVA for repeated measures with post-hoc Scheffé's test ($P < .05$) and discriminant analysis. The new CVM method presents with five maturational stages (Cervical Vertebral Maturation Stage [CVMS] I through CVMS V, instead of Cvs 1 through Cvs 6 in the former CVM method). The peak in mandibular growth occurs between CVMS II and CVMS III, and it has not been reached without the attainment of both CVMS I and CVMS II. CVMS V is recorded at least two years after the peak. The advantages of the new version of the CVM method are that mandibular skeletal maturity can be appraised on a single cephalogram and through the analysis of only the second, third, and fourth cervical vertebrae, which usually are visible even when a protective radiation collar is worn. (*Angle Orthod* 2002;72:316–323.)

Key Words: Cervical vertebrae; Cephalometrics; Mandibular growth; Skeletal maturity; Maturational indices

INTRODUCTION

The issue of optimal timing for dentofacial orthopedics is linked intimately to the identification of periods of accelerated or intense growth that can contribute significantly to the correction of skeletal imbalances in the individual patient. Maturational indices^{1–11} have been proposed to evaluate skeletal maturity in the growing patient when plan-

ning orthodontic/orthopedic treatment or for clinical research purposes. Among these indices, the Cervical Vertebral Maturation (CVM) method has proved to be effective to assess the adolescent growth peak both in body height and mandibular size.^{12–14} Several clinical studies have shown that the greatest response to functional jaw orthopedics tends to occur during the circumpubertal growth period.^{15–21} Thus, the use of a reliable biologic indicator aimed to detect the pubertal spurt in mandibular growth represents a crucial diagnostic tool for a rational treatment planning in Class II subjects with mandibular deficiencies. Further, methods such as CVM can be extremely useful to detect periods of reduced growth rate in the timing of orthognathic surgery or for the long-term evaluation of treatment outcomes.

Interest in the maturational changes in both size and shape of the cervical vertebrae dates back to the first decades of the twentieth century. Todd and Pyle,²² Lanier,²³ and Taylor²⁴ measured dimensional growth modifications in the cervical vertebrae on lateral radiographs. The ossification events in the cervical vertebrae begin during fetal life and continue until adulthood.^{25,26} Therefore, maturational

^a Research Associate, Department of Orthodontics, The University of Florence, Florence, Italy; and Thomas M. Graber Visiting Scholar, Department of Orthodontics and Pediatric Dentistry, School of Dentistry, The University of Michigan, Ann Arbor, Mich.

^b Thomas M. and Doris Graber Endowed Professor of Dentistry, Department of Orthodontics and Pediatric Dentistry, School of Dentistry; Professor of Cell and Developmental Biology, School of Medicine; and Research Scientist, Center for Human Growth and Development, The University of Michigan, Ann Arbor, Mich.

Corresponding author: Tiziano Baccetti, DDS, PhD, Università degli Studi di Firenze, Via del Ponte di Mezzo, 46–48, 50127, Firenze, Italy (e-mail: condax@tin.it).

Accepted: February 2002. Submitted: September 2001.

© 2002 by The EH Angle Education and Research Foundation, Inc.

changes can be observed in the vertebrae during this entire interval, which covers the period when orthodontic/orthopedic treatment is typically performed in the growing patient.

Based on the findings of earlier investigations^{22,23,27,28} in 1972, Lamparski²⁹ created separate standards of cervical vertebral maturation for female and male subjects as related to both chronological age and skeletal maturation observed in the hand-wrist radiograph. The method analyzed size and shape changes in the bodies of five cervical vertebrae (from the second one through the sixth). Hassel and Farman³⁰ reviewed lateral cephalometric and left hand-wrist radiographs from the *Bolton-Brush Growth Study* at Case Western Reserve University to develop an index based on the lateral profiles of the second, third, and fourth cervical vertebrae. These researchers, as well as Panchez and Szyska³¹ who further evaluated Hassel and Farman's index in relation to increases in body height, stated that the cervical vertebral analysis had a comparable high reliability and validity as the hand-wrist bone analysis in the assessment of individual skeletal maturity.

As for the relationship of cervical vertebral maturation and mandibular growth changes, O'Reilly and Yanniello³² evaluated annual lateral cephalometric radiographs of 13 Caucasian girls from 9 to 15 years of age and found statistically significant increases in mandibular length, corpus length, and ramus height in association with specific maturation stages in the cervical vertebrae according to the method of Lamparski.²⁹ More recently, Franchi and coworkers^{12,13} confirmed the validity of six CVM stages as a biologic indicator for both mandibular and somatic skeletal maturity in 24 growing untreated subjects. The original method by Lamparski²⁹ was adopted with a modification allowing for the appraisal of skeletal age in both boys and girls, regardless of chronological age (Figure 1).

The main features of the CVM method as described by Franchi and coworkers^{12,13} included:

- In nearly 95% of North-American subjects, the growth interval between stage 3 and stage 4 in CVM coincides with the pubertal peak in both mandibular growth and body height.
- Reproducibility of recorded data (identification of CVM stages) is as high as 98.6%.
- The method is useful for the anticipation of the pubertal peak in mandibular growth. The peak has not been reached if either stage 1 or stage 2 in CVM is recorded in the individual patient.

However, a few improvements of the original CVM analysis were still needed to make the method easier and applicable to the vast majority of patients: (1) To use a more limited number of vertebral bodies to perform the staging (as suggested by Hassel and Farman³⁰). In particular, the method should include only those cervical vertebrae (C2, C3, and C4) that can be visualized when the patient wears

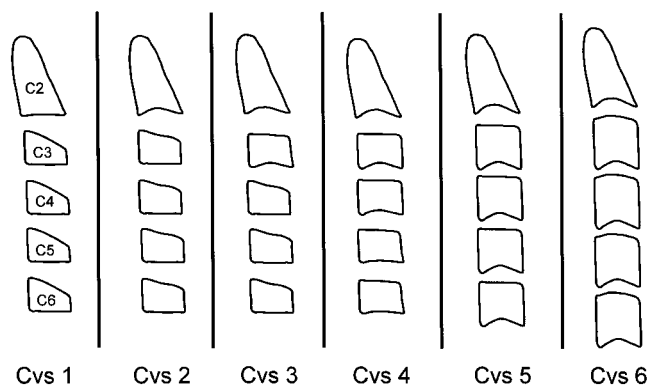


FIGURE 1. Developmental stages of cervical vertebrae. *Stage 1 (Cvs 1):* the inferior borders of the bodies of all cervical vertebrae are flat. The superior borders are tapered from posterior to anterior. *Stage 2 (Cvs 2):* a concavity develops in the inferior border of the second vertebra. The anterior vertical height of the bodies increases. *Stage 3 (Cvs 3):* a concavity develops in the inferior border of the third vertebra. *Stage 4 (Cvs 4):* a concavity develops in the inferior border of the fourth vertebra. Concavities in the lower borders of the fifth and of the sixth vertebrae are beginning to form. The bodies of all cervical vertebrae are rectangular in shape. *Stage 5 (Cvs 5):* concavities are well defined in the lower borders of the bodies of all 6 cervical vertebrae. The bodies are nearly square in shape and the spaces between the bodies are reduced. *Stage 6 (Cvs 6):* all concavities have deepened. The bodies are now higher than they are wide. (Modified from O'Reilly and Yanniello.³¹)

a protective radiation collar. (2) To avoid definitions of stages based on a comparative assessment of between-stage changes, so that stages can be identified easily in a single cephalogram.

The aim of the present work, therefore, is to present an improved version of the CVM method and its validity for the appraisal of mandibular skeletal maturity in the individual patient.

SUBJECTS AND METHODS

The total sample (706 subjects) that comprises the cephalometric files of the University of Michigan Elementary and Secondary School Growth Study³³ was evaluated. Due to the longitudinal nature and to the aim of the present investigation, subjects with less than six consecutive cephalometric observations ($n = 492$) were excluded from the study. Total mandibular length (Co-Gn) was measured on the longitudinal sets of annual lateral cephalograms for each of the 214 remaining subjects. The lateral cephalograms were analyzed by means of a digitizing tablet (Numonics, Lansdale, Penn) and digitizing software (Viewbox, ver 2.6 Kafissa, Greece). The maximum increase in Co-Gn between two consecutive cephalograms was used to define the peak in mandibular growth at puberty in the individual subjects. Two consecutive cephalograms comprising the interval of maximum mandibular growth, together with two earlier consecutive cephalograms and two later consecutive cephalograms had to be available for each subject and were

TABLE 1. Results of Qualitative Analysis of Cervical Vertebral (C2-C4) Characteristics at the Six Consecutive Observations (T₁-T₆)*

	T ₁		T ₂	
	Yes	No	Yes	No
Concavity at the lower border of C2	7 (23.3%)	23 (76.7%)	22 (73.3%)	8 (26.7%)
Concavity at the lower border of C3	0 (0%)	30 (100%)	2 (6.7%)	28 (93.3%)
Concavity at the lower border of C4	0 (0%)	30 (100%)	0 (0%)	30 (100%)
C3 Shape: trapezoid	30 (100%)	0 (0%)	29 (96.7%)	1 (3.3%)
C4 shape: trapezoid	30 (100%)	0 (0%)	26 (86.7%)	4 (13.3%)
C3 shape: rectangular horiz.	0 (0%)	30 (100%)	1 (3.3%)	29 (96.7%)
C4 shape: rectangular horiz	0 (0%)	30 (100%)	4 (13.3%)	26 (86.7%)
C3 shape: squared	0 (0%)	30 (100%)	0 (0%)	30 (100%)
C4 shape: squared	0 (0%)	30 (100%)	0 (0%)	30 (100%)
C3 shape: rectangular vert	0 (0%)	30 (100%)	0 (0%)	30 (100%)
C4 shape: rectangular vert	0 (0%)	30 (100%)	0 (0%)	30 (100%)

* Horiz indicates horizontal; and vert, vertical.

included in the study. This limited the investigation to 30 subjects (18 boys, 12 girls).

The morphology of the bodies of the second (odontoid process, C2), third (C3), and fourth (C4) cervical vertebrae were analyzed in the six consecutive observations (T₁ through T₆). The analysis consisted of both visual and cephalometric appraisals of morphological characteristics of the cervical vertebrae.

Visual analysis

The morphology of the three cervical vertebrae (C2, C3, C4) on the six consecutive cephalograms (T₁ through T₆) was evaluated by visual inspection. Two investigators (LF and TB) performed the appraisal independently. The percentage of interexaminer agreement was 96.7%. Two sets of variables were analyzed: (1) presence of a concavity at the lower border of the body of C2, C3, and C4; and (2) shape of the body of C3 and C4:

trapezoid (the superior border is tapered from posterior to anterior);

rectangular horizontal (the heights of the posterior and anterior borders are equal; the superior and inferior borders are longer than the anterior and posterior borders);

squared (the posterior, superior, anterior and inferior borders are equal);

rectangular vertical (the posterior and anterior borders are longer than the superior and inferior borders).

Cephalometric analysis

On the lateral cephalograms, the following points for the description of the morphologic characteristics of the cervical vertebral bodies were traced and digitized (Figure 2):

C2p, C2m, C2a: the most posterior, the deepest and the most anterior points on the lower border of the body of C2.

C3up, C3ua: the most superior points of the posterior and anterior borders of the body of C3.

C3lp, C3m, C3la: the most posterior, the deepest and the most anterior points on the lower border of the body of C3.

C4up, C4ua: the most superior points of the posterior and anterior borders of the body of C4.

C4lp, C4m, C4la: the most posterior, the deepest and the most anterior points on the lower border of the body of C4.

For the location of landmarks, the indications described by Hellsing³⁴ were adopted partially. With the aid of these landmarks, the following measurements were performed:

C2Conc: a measure of the concavity depth at the lower border of C2 (distance from the line connecting C2p and C2a to the deepest point on the lower border of the vertebra, C2m).

C3Conc: a measure of the concavity depth at the lower border of C3 (distance from the line connecting C3lp

Table 1. Extended

T ₃		T ₄		T ₅		T ₆	
Yes	No	Yes	No	Yes	No	Yes	No
30 (100%)	0 (0%)	30 (100%)	0 (0%)	30 (100%)	0 (0%)	30 (100%)	0 (0%)
28 (93.3%)	2 (6.7%)	28 (93.3%)	2 (6.7%)	29 (96.7%)	1 (3.3%)	30 (100%)	0 (0%)
3 (10%)	27 (90%)	26 (86.7%)	4 (13.3%)	29 (96.7%)	1 (3.3%)	30 (100%)	0 (0%)
23 (76.7%)	7 (23.3%)	0 (0%)	30 (100%)	0 (0%)	30 (100%)	0 (0%)	30 (100%)
15 (50%)	15 (50%)	0 (0%)	30 (100%)	0 (0%)	30 (100%)	0 (0%)	30 (100%)
7 (23.3%)	23 (76.7%)	30 (100%)	0 (0%)	12 (40%)	18 (60%)	0 (0%)	30 (100%)
15 (50%)	15 (50%)	30 (100%)	0 (0%)	14 (46.7%)	16 (53.3%)	0 (0%)	30 (100%)
0 (0%)	30 (100%)	0 (0%)	30 (100%)	18 (60%)	12 (40%)	15 (50%)	15 (50%)
0 (0%)	30 (100%)	0 (0%)	30 (100%)	16 (53.3%)	14 (46.7%)	16 (53.3%)	14 (46.7%)
0 (0%)	30 (100%)	0 (0%)	30 (100%)	0 (0%)	30 (100%)	15 (50%)	15 (50%)
0 (0%)	30 (100%)	0 (0%)	30 (100%)	0 (0%)	30 (100%)	14 (46.7%)	16 (53.3%)
0 (0%)	30 (100%)	0 (0%)	30 (100%)	0 (0%)	30 (100%)	14 (46.7%)	16 (53.3%)

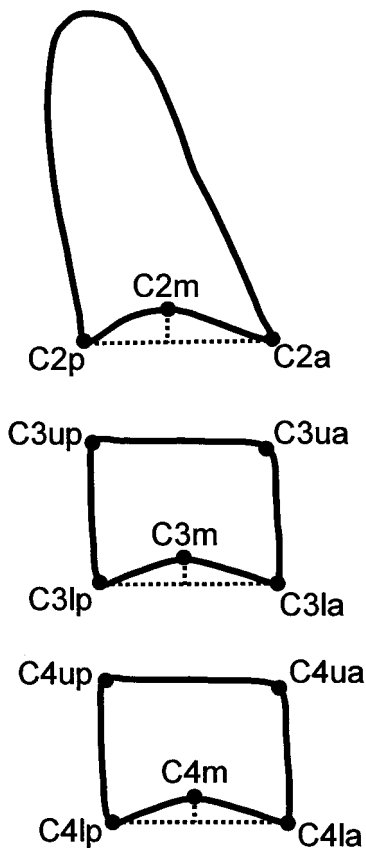


FIGURE 2. Cephalometric landmarks for the quantitative analysis of the morphologic characteristics in the bodies of C2, C3, and C4.

- and C3la to the deepest point on the lower border of the vertebra, C3m).
- C4Conc: a measure of the concavity depth at the lower border of C4 (distance from the line connecting C4lp and C4la to the deepest point on the lower border of the vertebra, C4m).
- C3BAR: ratio between the length of the base (distance C3lp-C3la) and the anterior height (distance C3ua-C3la) of the body of C3.
- C3PAR: ratio between the posterior (distance C3up-C3lp) and anterior (distance C3ua-C3la) heights of the body of C3.
- C4BAR: ratio between the length of the base (distance C4lp-C4la) and the anterior height (distance C4ua-C4la) of the body of C4.
- C4PAR: ratio between the posterior (distance C4up-C4lp) and anterior (distance C4ua-C4la) heights of the body of C4.

The method error for cephalometric measurements is reported elsewhere.¹²

Statistical analysis

The significance of the prevalence rates for the morphologic characteristics of the cervical vertebrae was evaluated at each observation time by means of Chi-square test with Yates' correction ($P < .05$). Descriptive statistics were obtained for total mandibular length and for vertebral cephalometric measures at each of the six consecutive observations (T₁ through T₆). The differences between the mean values for all the computed variables at the six consecutive

TABLE 2. Results of Quantitative Analysis: Descriptive Statistics and Statistical Comparisons (ANOVA for Repeated Measurements With post-hoc Scheffé's test) on the Measurements at the Six Consecutive Cephalometric Observations (T_1 - T_6)*

	T_1			T_2			T_3		
	Mean	SD	SEM	Mean	SD	SEM	Mean	SD	SEM
Age (months)	104.67	15.12	2.76	116.40	14.84	2.71	128.73	14.99	2.74
Co-Gn (mm)	107.85	5.33	0.97	110.32	5.68	1.04	112.63	5.78	1.06
C2Conc (mm)	0.44	0.46	0.08	0.76	0.49	0.09	1.15†	0.44	0.08
C3Conc (mm)	0.01	0.41	0.07	0.36	0.49	0.09	0.95†	0.53	0.10
C4Conc (mm)	0.03	0.31	0.06	0.12	0.29	0.05	0.31	0.39	0.07
C3PAR (ratio)	1.35	0.15	0.03	1.26	0.16	0.03	1.16†	0.12	0.02
C3BAR (ratio)	1.85	0.24	0.04	1.77	0.23	0.04	1.61†	0.15	0.03
C4PAR (ratio)	1.34	0.13	0.02	1.25	0.14	0.03	1.15†	0.17	0.03
C4BAR (ratio)	1.83	0.25	0.05	0.71	0.22	0.04	1.59	0.21	0.04

* SD indicates standard deviation; and SE, standard error of mean.

† Statistically significant with respect to preceding observation.

stages were tested for significance by means of ANOVA for repeated measurements with post-hoc Scheffé's test ($P < .05$).

The cephalometric measurements of the bodies of cervical vertebrae at each interval between consecutive cephalograms were analyzed by means of a multivariate statistical approach using a discriminant analysis to identify those vertebral morphologic variables mostly accounting for the differences between two consecutive observations. A stepwise variable selection (forward selection procedure) was performed with the goal of obtaining a model with the smallest set of significant cephalometric variables (F to enter and to remove = 4). Finally, the classifying power of selected cephalometric variables was tested. All statistical computations were performed by means of computer software (SPSS for Windows, release 10.0.0, SPSS Inc, Chicago, Ill).

RESULTS

The findings of the visual analysis of the morphologic characteristics of cervical vertebrae (C2, C3, C4) are reported in Table 1. The features of the examined vertebrae at the six consecutive observations can be summarized as follows:

- T_1 . A concavity already is evident at the lower border of C2 in 23.3% of the subjects. This percentage is significant (Chi-square = 5.82; $P = .016$). The concavity is absent at the lower borders of both C3 and C4 in 100% of the subjects. The bodies of both C3 and C4 are trapezoid in shape.
- T_2 . A concavity is present at the lower border of C2 in 73.3% of the subjects. However, the prevalence rate of subjects who do not show a concavity at the lower border of C2 is significant (Chi-square = 7.07; $P = .008$). The observation at T_2 is characterized by the absence of a concavity at the lower borders of C3 (with the nonsignificant exception of 6.7% of the subjects) and of C4. Both C3 and C4 still are trapezoid in shape,

with the nonsignificant exceptions of 3.3% and 13.3% of the subjects showing rectangular horizontal bodies for C3 and C4, respectively.

- T_3 . A concavity is present at the lower border of C2 (100% of the subjects) and of C3 (with the nonsignificant exception of 6.7% of the cases). No concavity is present at the lower border of C4 (with the nonsignificant exception of 10% of the cases). The shape of both C3 and C4 may be either trapezoid or rectangular horizontal.
- T_4 . This observation is characterized by the presence of a concavity at the lower borders of C2, C3 (with the nonsignificant exception of 6.7% of the cases), and C4 (with the nonsignificant exception of 13.3% of the cases). The bodies of both C3 and C4 now are rectangular horizontal in shape (100% of the subjects).
- T_5 . A concavity is present at the lower borders of C2, C3 (with the nonsignificant exception of 3.3% of the cases), and C4 (with the nonsignificant exception of 3.3% of the cases). The body of C3 is rectangular horizontal in 40% of the cases and squared in the remaining subjects. The body of C4 is rectangular horizontal in 46.7% of the cases and squared in the remaining subjects.
- T_6 . A concavity is present at the lower borders of all 3 examined cervical vertebrae. The body of C3 is squared in 50% of the cases and rectangular vertical in the remaining 50% of the cases. The body of C4 is squared in 53.3% of the cases and rectangular vertical in the remaining cases.

Descriptive statistics for cephalometric measurements of vertebral morphologic characteristics are reported in Table 2, together with the statistical comparisons between consecutive observations. No significant differences for any of the measurements were assessed between T_1 and T_2 . The depth of the concavities at the lower borders of both the second (C2Conc) and the third (C3Conc) cervical vertebra was significantly greater at T_3 when compared to T_2 . In the

TABLE 2. Extended

T ₄			T ₅			T ₆		
Mean	SD	SEM	Mean	SD	SEM	Mean	SD	SEM
141.17	14.42	2.63	153.30	14.41	2.63	166.00	13.83	2.53
118.05†	5.83	1.06	119.63	5.91	1.08	121.77	5.93	1.08
1.58†	0.37	0.07	1.91	0.40	0.07	2.23	0.48	0.09
1.36	0.64	0.12	1.85	0.60	0.11	2.40†	0.68	0.12
1.07†	0.53	0.10	1.77†	0.60	0.11	2.28†	0.63	0.11
0.98†	0.08	0.01	0.98	0.06	0.01	0.99	0.06	0.01
1.39†	0.14	0.02	1.20†	0.15	0.03	1.03†	0.13	0.02
1.01†	0.06	0.01	1.008	0.07	0.01	0.97	0.05	0.01
1.36†	0.12	0.02	1.19†	0.18	0.03	1.04	0.12	0.02

transition from T₂ to T₃, the height of the anterior border of both C3 and C4 increases significantly, thus leading to significant decrements in the ratio between the heights of the posterior and anterior borders of the vertebral bodies (C3PAR and C4PAR).

At T₄, the depth of the concavity at the lower border of C4 (C4Conc) becomes significantly greater than at T₃. In the transition from T₃ to T₄, the height of the anterior borders of both C3 and C4 increases significantly again, thus leading to significant decrements both in the ratio between the heights of the posterior and anterior borders of the vertebral bodies (C3PAR and C4PAR) and in the ratio between the length of the base and the anterior height of the vertebral bodies (C3BAR and C4BAR). On average, C3PAR and C4PAR now have a ratio of approximately 1:1, an indication that both C3 and C4 vertebral bodies are rectangular horizontal in shape.

T₅ and T₆ are characterized by decrements of the ratio between the length of the base and the anterior height of the vertebral bodies (C3BAR and C4BAR). The mean values for these measurements indicate that the vertebral bodies become progressively more squared in shape. At T₆, one-third of the cases show a rectangular vertical shape of one or both C3 and C4 vertebral bodies.

Discriminant analysis revealed that the forming concavity at the lower border of C3 could account only for 63% of the differences between T₁ and T₂. The depth of C3Conc becomes the discriminant variable between T₂ and T₃ with a classifying power of 75%. The difference in the postero-anterior ratio of C3 (C3PAR), together with the depth of the concavity at the lower border of C4 (C4Conc), are the discriminant factors between T₃ and T₄ (classifying power equal to 85%). C3PAR in association with both the ratio between the length of the base and the anterior height of C3 (C3BAR) and C4Conc are able to discriminate between T₄ and T₅ in 88% of the cases. The ratios for C3 (C3BAR and C3PAR), together with the depth of the concavity at the lower border of C2 (C2Conc), are the discriminant variables between T₅ and T₆ in 80% of the cases.

DISCUSSION

The modifications in size and shape of the cervical vertebrae in growing subjects have gained increasing interest in the last decades as a biological indicator of individual skeletal maturity. One of the main reasons for the rising popularity of the method is that the analysis of cervical vertebral maturation is performed on the lateral cephalogram of the patient's head, a type of film used routinely in orthodontic diagnosis. The objective of the present investigation was to improve the method for practical application in dentofacial orthopedics, and more specifically:

- A direct appraisal of the skeletal maturity of the mandible in relation to the morphological features of the cervical vertebrae. Previous studies have focused on the relations between the changes in size and shape of the cervical vertebrae and the skeletal maturation as evaluated by means of hand and wrist radiographs.²⁹⁻³¹
- An evaluation of the morphological features of the cervical vertebral bodies restricted to those that are visible on the lateral cephalogram even when a protective collar is worn, as originally proposed by Hassel and Farman.³⁰
- A definition of the cervical vertebral morphology at each developmental stage that allows the clinician to apply the method on the basis of the information derived from a single cephalogram. The assessment of individual stages in cervical vertebral maturation through the comparative analysis of between-stage changes,^{12,13,29} should, in fact, be avoided.

The anatomical features of the second (odontoid process), third, and fourth cervical vertebrae were evaluated here as visualized on lateral cephalograms in a time interval ranging on average from two years before to two years after the peak in mandibular growth. The description of the consecutive stages in vertebral development consisted of a non-comparative definition of morphological characteristics at each observation.

The findings of both the inspective and cephalometric analyses revealed that no statistically significant discrimi-

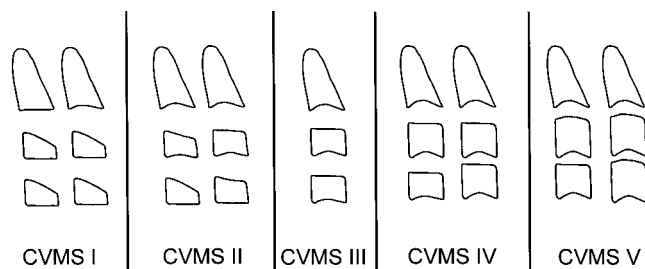


FIGURE 3. The newly improved CVM Method (five developmental stages, CVMS I through CVMS VI). Different combinations of morphological features in the bodies of C2, C3, and C4 are presented for the new method.

nation can be made between Cvs 1 and Cvs 2 as defined in the former CVM method.^{12,13} The presence of a concavity at the lower border of the second cervical vertebra is not a distinctive feature of Cvs 2 when compared to Cvs 1. The two former stages (Cvs 1 and Cvs 2) merge into one single stage. This newly described Cervical Vertebral Maturation Stage is referred to as CVMS I.

The appearance of a visible concavity at the lower border of the third cervical vertebra is the anatomic characteristic that mostly accounts for the identification of the stage immediately preceding the peak in mandibular growth (former Cvs 3, actual CVMS II). The distinction among Cvs 4, Cvs 5, and Cvs 6 as defined in the former CVM method^{12,13} is possible only by using the shape of the bodies of C3, C4, or both, as a discriminant factor.

Thus, the stages in cervical vertebral development in the version of the method presented here can be defined as follows (Figure 3):

CVMS I: the lower borders of all the three vertebrae are flat, with the possible exception of a concavity at the lower border of C2 in almost half of the cases. The bodies of both C3 and C4 are trapezoid in shape (the superior border of the vertebral body is tapered from posterior to anterior). The peak in mandibular growth will occur not earlier than one year after this stage.

CVMS II: Concavities at the lower borders of both C2 and C3 are present. The bodies of C3 and C4 may be either trapezoid or rectangular horizontal in shape. The peak in mandibular growth will occur within one year after this stage.

CVMS III: Concavities at the lower borders of C2, C3, and C4 now are present. The bodies of both C3 and C4 are rectangular horizontal in shape. The peak in mandibular growth has occurred within one or two years before this stage.

CVMS IV: The concavities at the lower borders of C2, C3, and C4 still are present. At least one of the bodies of C3 and C4 is squared in shape. If not squared, the body of the other cervical vertebra still is rectangular horizontal. The peak in mandibular growth has occurred not later than one year before this stage.

CVMS V: The concavities at the lower borders of C2, C3, and C4 still are evident. At least one of the bodies of C3 and C4 is rectangular vertical in shape. If not rectangular vertical, the body of the other cervical vertebra is squared. The peak in mandibular growth has occurred not later than two years before this stage.

The clinical application of the method to dentofacial orthopedics becomes relevant for those treatment protocols that benefit from the inclusion of the period of accelerated mandibular growth. Cervical Vertebral Maturation can be useful as a maturational index to detect the optimal time to start treatment of mandibular deficiencies by means of functional jaw orthopedics.^{20,21} It has been demonstrated that the effectiveness of functional treatment of Class II skeletal disharmony strongly depends on the biological responsiveness of the condylar cartilage, which in turn is related to the growth rate of the mandible.¹⁸

When CVMS I is diagnosed in the individual patient with mandibular deficiency, the clinician can wait at least one additional year for a radiographic re-evaluation aimed to start treatment with a functional appliance. CVMS II represents the ideal stage to begin functional jaw orthopedics, as the peak in mandibular growth will occur within one year after this observation. In the sample examined here, total mandibular length exhibited an average increase of 5.4 mm in the year following CVMS II, a significantly greater increment when compared both to the growth interval from CVMS I to CVMS II (about 2.4 mm) and to following between-stage intervals (1.6 mm and 2.1 mm for the intervals from CVMS III to CVMS IV and from CVMS IV to CVMS V, respectively).

CONCLUSION

The new CVM method is comprised of five maturational stages (CVMS I through CVMS V, instead of Cvs 1 through Cvs 6 in the former CVM method), with the peak in mandibular growth occurring between CVMS II and CVMS III. The pubertal peak has not been reached without the attainment of both CVMS I and CVMS II. The new method is particularly useful when skeletal maturity has to be appraised on a single cephalogram and only the second through fourth cervical vertebrae are visible.

REFERENCES

- Hellman M. The process of dentition and its effects on occlusion. *Dent Cosmos*. 1923;65:1329-1344.
- Nanda RS. The rates of growth of several facial components measured from serial cephalometric roentgenograms. *Am J Orthod*. 1955;41:658-673.
- Greulich WW, Pyle SI. *Radiographic Atlas of Skeletal Development of the Hand and Wrist*. Stanford, Calif: Stanford University Press; 1959.
- Lewis AB, Garn SM. The relationship between tooth formation and other maturation factors. *Angle Orthod*. 1960;30:70-77.
- Tanner JM. *Growth at Adolescence*. 2nd ed. Oxford: Blackwell Scientific Publications; 1962.

6. Hunter CJ. The correlation of facial growth with body height and skeletal maturation at adolescence. *Angle Orthod.* 1966;36:44–54.
7. Björk A, Helm S. Prediction of the age of maximum puberal growth in body height. *Angle Orthod.* 1967;37:134–143.
8. Tofani M. Mandibular growth at puberty. *Am J Orthod.* 1972;62:176–194.
9. Hägg U, Taranger J. Menarche and voice changes as indicators of the pubertal growth spurt. *Acta Odontol Scand.* 1980;38:179–186.
10. Hägg U, Taranger J. Skeletal stages of the hand and wrist as indicators of the pubertal growth spurt. *Acta Odontol Scand.* 1980;38:187–200.
11. Fishman LS. Maturation patterns and prediction during adolescence. *Angle Orthod.* 1987;57:178–193.
12. Franchi L, Baccetti T, McNamara JA Jr. Mandibular growth as related to cervical vertebral maturation and body height. *Am J Orthod Dentofacial Orthop.* 2000;118:335–340.
13. Franchi L, Baccetti T. New emphasis on the role of mandibular skeletal maturity in dentofacial orthopedics. In: McNamara JA Jr, ed. *The Enigma of the Vertical Dimension*. Craniofacial Growth Series, Vol 36. Ann Arbor, Mich: Center for Human Growth and Development, The University of Michigan; 2000:253–275.
14. McNamara JA Jr, Brudon WL. *Orthodontics and Dentofacial Orthopedics*. Ann Arbor, Mich: Needham Press Inc; 2001:78–80.
15. McNamara JA Jr, Bookstein FL, Shaughnessy TG. Skeletal and dental changes following functional regulator therapy on Class II patients. *Am J Orthod.* 1985;88:91–110.
16. Malmgren O, Ömblus J, Hägg U, Pancherz H. Treatment with an appliance system in relation to treatment intensity and growth periods. *Am J Orthod Dentofacial Orthop.* 1987;91:143–151.
17. Hägg U, Pancherz H. Dentofacial orthopaedics in relation to chronological age, growth period and skeletal development. An analysis of 72 male patients with Class II division 1 malocclusion treated with the Herbst appliance. *Eur J Orthod.* 1988;10:169–176.
18. Petrovic A, Stutzmann J, Lavergne J. Mechanism of craniofacial growth and modus operandi of functional appliances: a cell-level and cybernetic approach to orthodontic decision making. In: Carlson DS, ed. *Craniofacial Growth Theory and Orthodontic Treatment*. Craniofacial Growth Series, Vol 23. Ann Arbor, Mich: Center for Human Growth and Development, The University of Michigan; 1990.
19. Petrovic A, Stutzmann J, Lavergne J, Shaye R. Is it possible to modulate the growth of the human mandible with a functional appliance? *Inter J Orthod.* 1991;29:3–8.
20. Baccetti T, Franchi L, Toth LR, McNamara JA Jr. Treatment timing for twin block therapy. *Am J Orthod Dentofacial Orthop.* 2000;118:159–170.
21. Baccetti T, Franchi L. Maximizing esthetic and functional changes in Class II treatment by means of appropriate treatment timing. In: McNamara JA Jr, Kelly K eds. *New Frontiers in Facial Esthetics*. Craniofacial Growth Series, Vol 38. Ann Arbor, Mich: Center for Human Growth and Development, The University of Michigan; 2001.
22. Todd T, Pyle SI. Quantitative study of the vertebral column. *Am J Phys Anthropol.* 1928;12:321.
23. Lanier R. Presacral vertebrae of white and Negro males. *Am J Phys Anthropol.* 1939;25:341–417.
24. Taylor JR. Growth of human intervertebral discs and vertebral bodies. *J Anat.* 1975;120:49–68.
25. Gray H, Clemente CD. *Anatomy of the Human Body*. 30th ed. Philadelphia, Penn: Lea & Febiger; 1985.
26. Bick E, Copel J. Longitudinal growth of the human vertebrae. *J Bone Joint Surg (Am)*. 1950;32A:803–813.
27. Elsberg CA, Duke CG. The diagnosis and localization of tumors of the spinal chord by means of measurement made on the x-ray films of the vertebrae and the correlation of clinical and x-ray findings. *Bull Neuro Inst.* 1934;3:359.
28. Hinck V, Hopkins C, Savara B. Sagittal diameter of the cervical spine in children. *Radiology* 1962;70:97–101.
29. Lamparski DG. *Skeletal Age Assessment Utilizing Cervical Vertebrae* [Master's thesis]. Pittsburgh, Penn: Department of Orthodontics, The University of Pittsburgh; 1972.
30. Hassel B, Farman A. Skeletal maturation evaluation using cervical vertebrae. *Am J Orthod Dentofacial Orthop.* 1995;107:58–66.
31. Pancherz H, Szyska M. Analyse der Halswirbelkörper statt der Handknochen zur Bestimmung der skelettalen und somatischen Reife. *IOK* 2000;32:151–161.
32. O'Reilly M, Yanniello GJ. Mandibular growth changes and maturation of cervical vertebrae—a longitudinal cephalometric study. *Angle Orthod.* 1988;58:179–184.
33. Riolo ML, Moyers RE, McNamara JA Jr, Hunter WS. *An Atlas of Craniofacial Growth: Cephalometric Standards from The University School Growth Study, The University of Michigan*. Ann Arbor, Mich: Monograph 2, Craniofacial Growth Series; The Center for Human Growth and Development, The University of Michigan; 1974.
34. Hellsing E. Cervical vertebral dimensions in 8-, 11-, and 15-year-old children. *Acta Odontol Scand.* 1991;49:207–213.