

Comparison of Skeletal and Dental Morphology in Asymptomatic Volunteers and Symptomatic Patients with Bilateral Disk Displacement without Reduction

Ioanna K. Gidarakou, DDS^a; Ross H. Tallents, DDS^b; Stephanos Kyrkanides, DDS, PhD^c; Scott Stein, DMD^d; Mark E. Moss, DDS, PhD^e

Abstract: The purpose of this study was to evaluate the effect of bilateral disk displacement without reduction (BDDN) on the skeletal and dental pattern of affected individuals. There were 59 symptomatic female patients and 46 asymptomatic normal female volunteers. All study participants had bilateral high-resolution magnetic resonance imaging scans in the sagittal (closed and open) and coronal (closed) planes to evaluate the temporomandibular joints. Linear and angular cephalometric measurements were taken to evaluate the skeletal, denture base, and dental characteristics of the two groups. A smaller cranial base length (Ba-Na) was found in the symptomatic group. The facial plane angle was smaller, and the angle of convexity was larger because of the retropositioned mandible. The lower denture base was also retruded as shown by the smaller SNB angle. The BDDN group exhibited a larger overjet. The mandibular plane angle was steeper, the Y-axis was more vertical (S-Gn to FH), the posterior ramal height (Ar-Go) was shorter, and the angle between the mandibular and the palatal plane (PP to MP angle) was increased in the symptomatic group. No significant dental differences were found. This study showed that alterations in skeletal morphology might be associated with BDDN. This study suggests that subjects with BDDN may manifest altered craniofacial morphology. The clinician should be aware of that possibility, especially for the growing patients and the surgical candidates. (*Angle Orthod* 2004;74:684–690.)

Key Words: Joint; Cephalometrics; Skeletal; Nonreducing; Morphology

INTRODUCTION

Temporomandibular joint disorder (TMD) is a collective term embracing a number of clinical problems that involve

^a Resident, Department of Dentistry, Division of Orthodontics, University of Rochester School of Medicine and Dentistry, Rochester, NY.

^b Professor, Department of Dentistry, Division of Orthodontics and Prosthodontics, Program Director Temporomandibular Joint Disorders, University of Rochester School of Medicine and Dentistry, Rochester, NY.

^c Assistant Professor, Department of Dentistry, Assistant Chief of Division of Orthodontics, Craniofacial Research Core Coordinator, University of Rochester School of Medicine and Dentistry, Rochester, NY.

^d Clinical Instructor, Department of Dentistry, Division of Orthodontics, University of Rochester School of Medicine and Dentistry, Rochester, NY.

^e Assistant Professor, Department of Dentistry and Community and Preventive Medicine, University of Rochester School of Medicine and Dentistry, Rochester, NY.

Corresponding author: Ross H. Tallents, DDS, Eastman Dental Center, Orthodontics and TMJD, 625 Elmwood Avenue, Eastman Dental Center, Rochester, NY 14620 (e-mail: Ross.Tallents@urmc.rochester.edu).

Accepted: October 2003. Submitted: June 2002.

© 2004 by The EH Angle Education and Research Foundation, Inc.

the masticatory musculature, the temporomandibular joint (TMJ), and associated structures or both.¹ Disk displacement (DD) with reduction (DDR) is frequently associated with a clicking sound, and DD without reduction (DDN) is often associated with limitation of jaw opening.² Previous studies have suggested that DDN may progress to osteoarthritis in the TMJ.^{3–6}

Autopsy studies in both young and mature adults show DD in 10–32% in the general population.^{7,8} Several studies have suggested that DD occurs in asymptomatic subjects with a prevalence ranging from 10–33%.^{9–15}

A high prevalence of DD in asymptomatic volunteers (AVs) is not unique to the TMJ because magnetic resonance imaging (MRI) studies of asymptomatic subjects in the knee, cervical spine, and lumbar spine indicate similar disease prevalences in asymptomatic subjects.^{16–22} These studies demonstrate that DD can be present in patients without clinical signs and symptoms. On the other hand, it has been shown, that not all TMJ pain, clicking, and limited jaw motion can be related to DD in symptomatic patients. Pae-sani et al²³ found that 78% of their symptomatic TMD sample had unilateral or bilateral DD whereas 22% had bilaterally normal TMJs. They also concluded that the structural

difference between painful and nonpainful DD as seen on imaging studies is not yet clear.

DD has been suggested to affect skeletal morphology. Nebbe et al²⁴ have suggested that adolescent female patients presenting for orthodontic treatment with bilateral DD show numerous angular and linear cephalometric differences compared with age-matched female controls. Nebbe et al²⁵ also demonstrated that associations exist between subjects with DD and craniofacial morphology in a female adolescent sample. Turpkova et al²⁶ investigated the amount of craniofacial asymmetry in female orthodontic patients with unilateral or bilateral TMJ DD compared with female controls without DD using frontal radiographs. They concluded that a female patient with unilateral or bilateral DD may present with or develop a vertical mandibular asymmetry.²⁶ Schellhas et al²⁷ and Dibbets et al²⁸ suggested that there are morphologic changes in children with DD and symptoms, respectively. Brand et al,²⁹ Bosio et al,³⁰ and Gidarakou et al^{31,32} have also suggested that DD might be associated with skeletal changes. Patients referred for orthognathic surgery are also found to exhibit a high prevalence of DD,^{5,33} and animal studies have suggested that there are arthrotic changes associated with surgically created DD.^{34–38} This study will evaluate AVs and symptomatic bilateral DD without reduction (BDDN) subjects presenting with localized jaw joint pain for skeletal and dental morphologic changes.

MATERIALS AND METHODS

Materials

There were 46 normal female AVs and 59 symptomatic age-matched females with BDDN. The age range was 28.3 ± 6.7 for the AVs, whereas the mean age of the symptomatic subjects was 28.6 ± 10.2. All study participants read and signed an informed consent before the study initiation. The form and the study were approved by the Research Subjects Review Board of the University of Rochester.

All AVs answered a solicitation for examination and inclusion in the study. They were all examined by one investigator and were accepted in the study after completion of:

- A TMJ subjective questionnaire documenting the absence of jaw pain, joint noise, locking, and positive history of TMD.
- A clinical TMJ and dental examination for signs and symptoms commonly associated with TMD or internal derangement.

All symptomatic subjects had localized jaw joint pain and pain on movement or when eating. Vertical opening and right and left mandibular movements were measured and recorded. The masseter, anterior, middle, and posterior temporalis, and temporalis tendon area were digitally palpated. All AVs demonstrated a maximal opening of at least

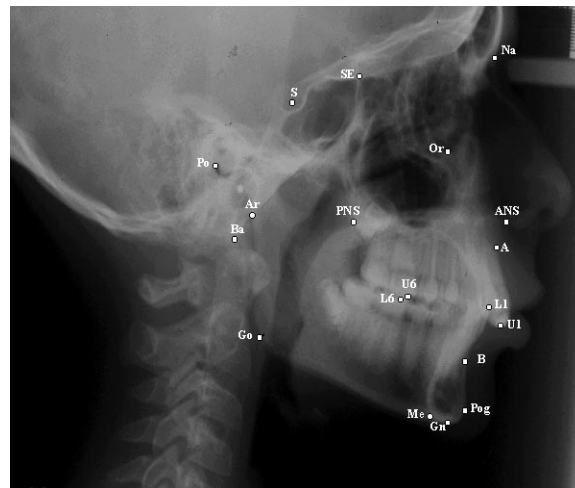


FIGURE 1. Cephalometric landmarks used.

TABLE 1. Cranial Base Measurements

Measurements	AV-N		BDDN	
	Mean	SD	Mean	SD
S-Na	73.06	3.28	71.89	3.24
Ba-Na	110.1	4.66	107.9*	4.97
Ba-S	47.18	2.54	46.08	3.4
Ba-S-Na	131.7	5.05	131.3	4.85

* P values equal to or less than .05 were considered significant.

40 mm. The asymptomatic and symptomatic subjects were not blinded to the examiner.

All study participants had bilateral high-resolution MRI scans in the sagittal (closed and open) and coronal (closed) planes to evaluate the TMJs as described by Katzberg et al³⁹ and Westesson et al.⁴⁰ Each study participant was classified as AV or symptomatic BDDN.

All study participants had lateral cephalograms with the teeth in centric occlusion position and with Frankfort horizontal parallel to the floor. All cephalograms were taken on the same radiographic machine at the Orthodontic Clinic set for standardized exposure.

Null hypothesis

There are no statistically significant differences between skeletal, denture base, and dental characteristics of symptomatic BDDN patients compared with a sample of individuals with bilateral normal asymptomatic TMJs.

Cephalometric measurements

Figure 1 shows the cephalometric points used. Tables 1–5 summarize the angular and linear cephalometric measurements used in this study. These were categorized as cranial base measurements, profile analysis, denture base, dental pattern, and vertical relationship measurements.

TABLE 2. Profile Analysis

Measurements	AV-N		BDDN	
	Mean	SD	Mean	SD
FH to Na-Pg	89.18	3.1	87.62*	3.4
FH to Na-A	90.71	2.99	90.32	3.31
Na-A-Pog	2.99	6.23	5.69*	6.85

* *P* values equal to or less than .05 were considered significant.

TABLE 3. Denture Base Measurements

Measurements	AV-N		BDDN	
	Mean	SD	Mean	SD
ANS-PNS	56.3	3.84	56.24	3.32
SNA	81.81	3.74	80.52	3.81
SNB	79.18	3.69	76.66*	3.96
ANB	2.64	2.52	3.86	2.87
A-B to FP	-4.99	3.54	-6.58	4.51

* *P* values equal to or less than .05 were considered significant.

TABLE 4. Denture Pattern

Measurements	AV-N		BDDN	
	Mean	SD	Mean	SD
FH to OP	5.14	3.67	5.53	4.03
U1 to L1	128.2	8.41	128.7	11.69
U1 to PP	109.2	6.81	107.7	7.32
U1 to FH	110.7	6.85	109.8	7.71
U1 to S-Na	101.8	6.87	99.9	8.5
U1 to A-Pog	23.3	6.7	25.59	6.84
U1 perpendicular to A-Pog	7.38	2.06	8.41	2.57
L1 to MP	5.89	7.18	4.21	7.46
L1 to OP	25.1	6.92	25.79	8.15
L1 to A-Pg	27.7	4.44	25.57	6.59
L1 perpendicular to A-Pog	4.14	1.84	4.06	2.12
Overbite (perpendicular to FH)	2.88	1.7	3.02	2.05
Overjet (parallel to FH)	3.07	1.18	4.18*	2.25

* *P* values equal to or less than .05 were considered significant.

Statistical method

The analysis of variance was used to reveal any statistically significant differences between the control group and the experimental group. All subjects were matched for age. The *P* value was calculated for each of the variables with a level of significance for each test established at .05.

Error of measurement

Errors in landmark localization during tracing were evaluated by retracing 20 cephalograms in the experimental and control group. The reliability of tracing, landmark identification, and analytical measurements had an intraclass correlation coefficient greater than .92.

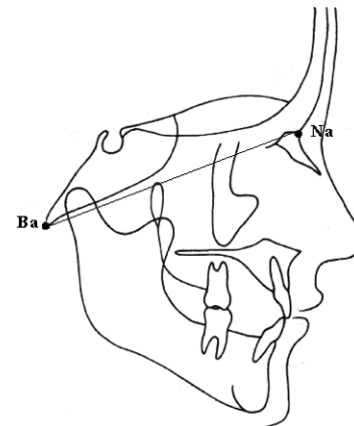
RESULTS

Tables 1–5 summarize the findings of the measurements. Table 1 demonstrates that the cranial base length (Ba-Na)

TABLE 5. Vertical Relationships

Measurements	AV-N		BDDN	
	Mean	SD	Mean	SD
MP to FH	24.36	4.91	27.02*	5.36
S-Gn to FH	58.02	2.92	59.62*	3.74
Na-ANS (UFH)	53.8	3.06	53.85	3.35
ANS-Me (LFH)	65.99	4.83	65.82	6.07
Na-Me (TFH)	119.8	5.49	119.6	7.11
UFH: TFH	44.94	2.37	45.09	2.61
SE-PNS	49.2	3.15	49.31	3.45
Ar-Go	47.86	5.11	45.66*	4.75
U6 perp PP	23.45	1.93	23.97	2.74
U1 perp PP	29.23	2.71	29.95	3.34
L6 perp MP	32.37	2.4	32.08	2.77
L1 perp MP	41.97	2.49	41.78	3.47
PP to OP	6.65	3.8	7.81	4.33
PP to MP	25.86	4.99	29.02*	5.61
PP to FH	-1.09	3.54	-1.83	3.08
Ar-Go-Gn	126.5	5.55	127.8	5.6
Antigonial notch	171.7	7.58	169.2	7.78

* *P* values equal to or less than .05 were considered significant.

**FIGURE 2.** Significant measurements of the cranial base (Ba-Na).

was smaller in the BDDN group. In the profile analysis (Table 2) the facial plane angle was smaller and the angle of convexity larger in the symptomatic group. The only significant difference found in the denture base measurements was a smaller SNB angle as seen in Table 3. The overjet was increased in the BDDN subjects and that was the only significant difference found in the denture pattern measurements (Table 4).

The measurements of the vertical relationships showed numerous differences (Table 5). There was a steeper mandibular plane angle, a more vertical (larger) Y-axis (S-Gn to FH angle), a shorter ramal height (Ar-Go), and an increased divergence of the palatal and mandibular planes (PP to MP angle) in the BDDN subjects. The significant measurements are shown in Figures 2–5.

DISCUSSION

A high prevalence of DD in AVs has been suggested. Westesson et al⁹ found 15% of their AVs to have unilateral

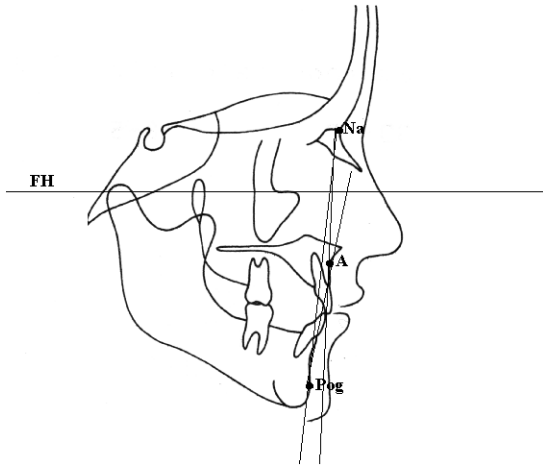


FIGURE 3. Significant measurements of profile analysis (FH to Na-Pg, Na-A-Pg).

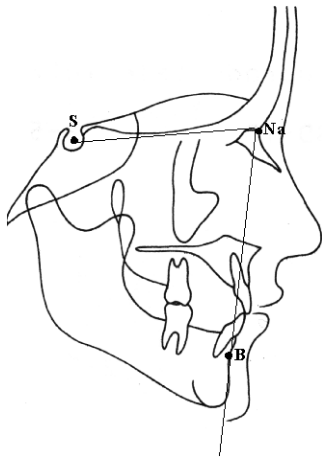


FIGURE 4. Significant measurements of the denture base (SNB).

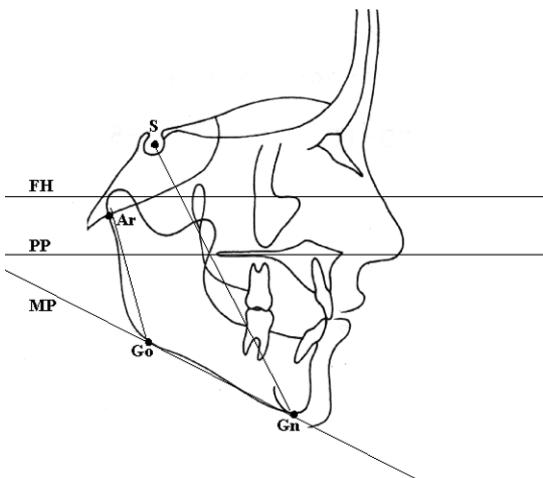


FIGURE 5. Significant measurements of the vertical relationships (MP to FH, S-Gn to FH, Ar-Go, PP to MP).

DD using TMJ arthrography. Tallents et al¹⁰ in a study of evaluation of TMJ sounds in AVs found that 24% had one or two joints with DD as diagnosed by MRI. Ribeiro et al¹¹ found the prevalence of DD in asymptomatic children and young adults to be 34%, whereas 86% of the symptomatic temporomandibular disorder patients had DD. Their results showed that 13.8% had bilateral symptomatic, but normal joints, 28% had unilateral DD, and 58% had bilateral DD. Kircos et al¹⁵ found similar results (32%) in AVs.

A high prevalence of DD in AVs is not unique to the TMJ. MRI studies of asymptomatic subjects in the knee, cervical spine, and lumbar spine indicate similar disease prevalences in asymptomatic subjects in those body parts as well.¹⁶⁻²¹ Brunner et al²² showed that half of the asymptomatic athletes included in the study had significant baseline knee MRI scan abnormalities. Oberg et al⁷ macroscopically examined the right TMJs of 155 cadavers of different ages regarding the shape, size, and appearance of the joint surfaces. They found that with increasing age the number of joints with local changes in the shape, remodeling, or arthritic changes of the articular surfaces increased. The arthritic changes were significantly more prevalent in women.

Previous studies have suggested that DDN may progress to osteoarthritis in the TMJ.³⁻⁵ Eriksson and Westesson⁴ suggested that DDR and DDN are two different entities and that DDN seems to be a more advanced condition and may in some cases be a precursor of osteoarthritis. Yamada et al⁶ have also suggested that there is a correlation between degenerative changes and DDN.

DD has been suggested to affect skeletal morphology.^{5,25-27} In this study we evaluated the effect of BDDN on the skeletal and dental pattern of the affected individuals. There was a smaller cranial base length (Ba-Na) in the BDDN group. In our study with BDDR we also found differences in the cranial base, namely shorter anterior (S-Na) and total (Ba-Na) cranial base lengths.³¹ Nebbe et al²⁵ found a shorter posterior cranial base length and also a more acute cranial base angle, which was not significantly different in our group, but they did not clarify if their subjects had DD with or without reduction.

The mandible of the symptomatic subjects was retruded in relation to the forehead as seen by the smaller facial plane angle and the larger angle of convexity. The mandibular denture base was also retruded as demonstrated by the smaller SNB angle and there was increased overjet in our BDDN sample. These findings agree with previously published studies.

In our study of patients with BDDN, the affected individuals exhibited smaller facial plane angle and SNB angle but also smaller Lande's and SNA angles.³² Bosio et al³⁰ found a smaller mean SNB angle in patients with bilateral DD compared with AVs. Schellhas et al²⁷ in their study of children 14 years of age or younger concluded that TMJ derangements may contribute to the development of retrognathia, with or without asymmetry. Ninety-three percent

of the retrognathic subjects were found to have DD, generally bilateral. Dibbets et al²⁸ suggested that TMJ dysfunction might be associated with altered growth of the mandible and may cause retrognathia in children.

There were numerous significant differences in the vertical relationships. The mandibular plane angle was steeper, the Y-axis more vertical, the posterior ramal height (Ar-Go) was shorter, and there was a divergence of the palatal and mandibular plane indicative of posterior mandibular rotation in the symptomatic group. We found similar findings (steeper mandibular plane and shortened ramal height) in our study with BDDR patients and BJD patients (steeper mandibular plane, decreased ramal height, divergence of mandibular plane to palatal plane).^{31,32} Dibbets et al²⁸ and Nebbe et al²⁵ have also reported steeper mandibular plane and shorter ramal height in children and adolescents presenting with degenerative joint disease and DD, respectively. Nebbe et al²⁵ also found an increased mandibular and palatal plane relative to sella-nasion and posterior rotation of the mandible.

Our study agrees with previous studies, which have suggested that DD can affect skeletal morphology and symmetry. The present study's findings are more severe than the findings of our previous study of BDDR patients³¹ and less severe than our findings of BJD patients,³² which can be expected because DD may progress to DJD. Bosio et al³⁰ also suggested that symptomatic TMD patients with BDD have a repositioned mandible.

Link and Nickerson⁵ and Schellhas et al²⁷ have suggested that there is a cause and effect relationship between DD and facial growth. Schellhas et al²⁷ concluded that TMJ derangements are both common in children and may contribute to the development of retrognathia, with or without asymmetry. In cases of lower face asymmetry, the chin was uniformly deviated toward the smaller or more degenerated TMJ. They proposed that in the growing facial skeleton, DD either retards or arrests condylar growth, which results in decreased vertical dimension in the proximal mandibular segment(s) with ultimately mandibular deficiency or asymmetry.²⁷ Nebbe et al²⁵ have suggested that adolescent female patients presenting for orthodontic treatment with bilateral DD show numerous angular and linear cephalometric differences compared with age-matched female controls indicative of mandibular posterior rotation and retrognathia. Dibbets et al²⁸ showed that children with symptoms of dysfunction formed a morphologically clearly recognizable group. Their profile was more Class II and had a shorter corpus and ramus with decreased posterior facial height. They concluded that TMJ dysfunction might be associated with the growth of the mandible.²⁸ Brand et al²⁹ indicated that patients with DD had significantly shorter maxillary and mandibular lengths compared with asymptomatic normal individuals with normal TMJs. That investigation did not distinguish between unilateral and bilateral DD and could not account for any asymmetries because the right

and left landmarks in the cephalometric radiograph were averaged.

Trpkova et al²⁶ investigated the amount of craniofacial asymmetry in female orthodontic patients with unilateral or bilateral TMJ DD compared with normal controls without DD using posteroanterior films. Female subjects with bilateral DD had significantly greater asymmetry in the vertical position of the antegonion. If the DD was more advanced on one side, then the ipsilateral ramus was shorter resulting in significant asymmetry of the mandible. The authors concluded that a female patient with unilateral or bilateral DD might present with or develop a vertical mandibular deficiency.²⁶

Increased prevalence of DD has been found in patients with mandibular retrognathia presenting for orthognathic surgery. Link and Nickerson⁵ studied 39 patients referred for orthognathic surgery, 38 of who were found to have DD before surgery. All their open-bite patients and 88% of the patients with Class II malocclusion had bilateral DD. They suggested that DD may be a contributing factor in the development of dentofacial deformities and that new loading of deranged joints after orthognathic surgery may be a cause of a new arthrosis and skeletal relapse suggesting a progression of TMJ pathology. They suggested that DD should be suspected in individuals with sagittal mandibular deficiency, vertical ramus deficiency, or a unilateral sagittal deficiency. The high degree of association of DD with mandibular deficiency suggests that DD may have a role in causing these deformities. That is, loss of condylar height and/or growth secondary to the DD caused or worsened the horizontal or vertical ramus mandibular deficiency.⁵ Schellhas et al³³ in their retrospective study of 100 consecutive orthognathic surgery candidates found that DD was prevalent especially in patients who exhibited change in their facial contour in the year before the evaluation. The degree of joint degeneration directly paralleled the severity of retrognathia. They concluded that TMJ DD is common in cases of mandibular retrusion and leads to the facial morphology in a high percentage of patients.

CONCLUSIONS

The results of this study show that alterations in skeletal morphology may be associated with BDDN. The skeletal differences are more pronounced in patients with BDDN than in patients with BDDR and less severe than in patients with BJD as reported by Gidakou et al^{31,32}. The present study agrees with previous studies suggesting that DD may affect the skeletal morphology and especially the mandibular position and rotation. The underlying mechanisms causing DD or the mechanisms that cause that skeletal alteration are yet to be identified. Because the present and previous studies suggest that BDDN may affect skeletal morphology and growth pattern, the clinician should be

aware of these possibilities especially for the growing patient and the orthognathic surgery candidate.

REFERENCES

- Okesson JP. *Orofacial Pain. Guidelines for Assessment, Diagnosis and Management*. Carol Stream, Ill: Quintessence Publishing Co, Inc; 1996:116.
- Katzberg RW, Westesson PL, Tallents RH, Drake CM. Orthodontics and temporomandibular joint disorders. *Am J Orthod Dentofacial Orthop*. 1996;109:515–520.
- Westesson P-L, Rohlin M. Internal derangement related to osteoarthritis in temporomandibular joint autopsy specimens. *Oral Surg*. 1984;57:17–22.
- Eriksson L, Westesson P-L. Clinical and radiologic study of patients with anterior disk displacement of the temporomandibular joint. *Swed Dent J*. 1983;7:55–64.
- Link JJ, Nickerson JW Jr. Temporomandibular joint internal derangements in an orthognathic surgery population. *Int J Adult Orthod Orthognath Surg*. 1992;7:161–169.
- Yamada K, Hiruma Y, Hanada K, Hayashi T, Koyama J, Ito J. Condylar bony change and craniofacial morphology in orthodontic patients with TMD symptoms: a pilot study using helical computed tomography and magnetic resonance imaging. *Clin Orthod Res*. 1999;2:133–142.
- Oberg T, Carlsson GE, Fajers CM. The temporomandibular joint. A morphometric study on a human autopsy material. *Acta Odontol Scand*. 1971;29:349–384.
- Solberg WK, Hansson TL, Nordstrom B. The temporomandibular joint in young adults at autopsy: a morphologic classification and evaluation. *J Oral Rehabil*. 1985;12:303–321.
- Westesson PL, Eriksson L, Kurita K. Reliability of a negative clinical temporomandibular joint examination: prevalence of disk displacement in asymptomatic temporomandibular joint. *Oral Surg Oral Med Oral Pathol*. 1989;68:551–554.
- Tallents RH, Hatala M, Katzberg RW, Westesson PL. Temporomandibular joint sounds in asymptomatic volunteers. *J Prosthet Dent*. 1993;69:298–304.
- Ribeiro RF, Tallents RH, Katzberg RW, Murphy WC, Moss ME, Magalhaes AC, Tavano O. The prevalence of disk displacement in symptomatic and asymptomatic volunteers aged 6 to 25 years. *J Orofacial Pain*. 1997;11:37–46.
- Tallents RH, Katzberg RW, Murphy W, Proskin H. Magnetic resonance imaging findings in asymptomatic volunteers and symptomatic patients with temporomandibular disorders. *J Prosthet Dent*. 1996;75:529–533.
- Katzberg RW, Westesson PL, Tallents RH, Drake CM. Orthodontics and temporomandibular joint internal derangement. *Am J Orthod Dentofacial Orthop*. 1996;109:515–520.
- Morrow D, Tallents RH, Katzberg RW, Murphy WC, Hart TC. Relationship of other joint problems and anterior disk displacement in symptomatic TMD patients and in asymptomatic volunteers. *J Orofacial Pain*. 1996;10:15–20.
- Kircos LT, Ortendhal DA, Mark A, Arakawa M. Magnetic resonance imaging of the TMJ disk in asymptomatic volunteers. *J Oral Maxillofac Surg*. 1987;45:852–854.
- Nagendak WG, Fernandez FR, Halburn LK, Teitge RA. Magnetic resonance imaging of meniscal degeneration in asymptomatic knees. *J Orthop Res*. 1990;8:311–312.
- Kornick J, Trefelner ME, McCarty S, Lang R, Lynch K, Jokl P. Meniscal abnormalities in the asymptomatic population in MR imaging. *Radiology*. 1990;177:463–465.
- Boden SD, Davis DO, Dina TS, Staller DW, Brown SD, Vailas JC, Labropoulos PA. A prospective and blinded investigation of magnetic resonance imaging of the knee: abnormal findings in asymptomatic subjects. *Clin Orthop*. 1992;282:177–185.
- Shellock FG, Morris E, Deutsch AL, Mink JH, Kerr R, Boden SD. Hematopoietic marrow hyperplasia: high prevalence on MR images of the knee in asymptomatic marathon runners. *AJR*. 1992;158:335–338.
- Boden SD, McCowin PR, Davis DO, Dina TS, Mark AS, Wiesel S. Abnormal magnetic resonance scans of the cervical spine in asymptomatic subjects. *J Bone Joint Surg (Am)*. 1990;72:1174–1184.
- Boden SD, Davis DO, Dina TS, Patronas NJ, Wiesel SW. Abnormal magnetic resonance scans of the lumbar spine in asymptomatic subjects: a prospective investigation. *J Bone Joint Surg (Am)*. 1990;72:403–408.
- Brunner MC, Flower SP, Evancho AM, Allman FL, Apple DF, Fajman WA. MRI of the athletic knee. Findings in asymptomatic professional basketball and collegiate football players. *Invest Radiol*. 1989;24:72–75.
- Paesani D, Westesson PL, Hatala M, Tallents RH, Kurita K. Prevalence of temporomandibular joint internal derangement in patients with craniomandibular disorders. *Am J Orthod Dentofacial Orthop*. 1992;101:41–47.
- Nebbe B, Major PW, Prasad NGN. Adolescent female craniofacial morphology associated with advanced bilateral TMJ disk displacement. *Eur J Orthod*. 1998;20:701–712.
- Nebbe B, Major PW, Prasad NGN. Female adolescent facial pattern associated with TMJ disk displacement and reduction in disk length: part I. *Am J Orthod Dentofacial Orthop*. 1999;116:168–176.
- Trpkova B, Major P, Nebbe B, Prasad N. Craniofacial asymmetry and temporomandibular internal derangement in female adolescents: a posteroanterior cephalometric study. *Angle Orthod*. 2000;70:81–88.
- Schellhas KP, Pollei SR, Wilkes CH. Pediatric internal derangements of the temporomandibular joint: effect on facial development. *Am J Orthod Dentofacial Orthop*. 1993;104:51–59.
- Dibbets JMH, Van Der Weele LT, Uildriks AKJ. Symptoms of TMJ dysfunction: indicators of growth patterns? *J Pedod*. 1985;9:265–284.
- Brand JW, Nielson KJ, Tallents RH, Nanda RS, Currier GFC, Owen WL. Lateral cephalometric analysis of skeletal patterns in patients with and without internal derangement of the temporomandibular joint. *Am J Orthod Dentofacial Orthop*. 1995;107:121–128.
- Bosio JA, Burch JG, Tallents RH, Wade DB, Beck FM. Lateral cephalometric analysis of asymptomatic volunteers and symptomatic patients with and without temporomandibular joint displacement. *Am J Orthod Dentofacial Orthop*. 1998;114:248–255.
- Gidarakou IK, Tallents RH, Kyrkanides S, Stein S, Moss ME. Comparison of skeletal and dental morphology in asymptomatic volunteers and symptomatic patients with bilateral disk displacement with reduction. *Angle Orthod*. 2002;72:541–546.
- Gidarakou IK, Tallents RH, Kyrkanides S, Stein S, Moss ME. Comparison of skeletal and dental morphology in asymptomatic volunteers and symptomatic patients with bilateral degenerative joint disease. *Angle Orthod*. 2003;73:71–78.
- Schellhas KP, Piper MA, Bessette RW, Wilkes CH. Mandibular retrusion, temporomandibular joint derangement and orthognathic surgery planning. *Plastic Recon Surg*. 1992;90:218–232.
- Macher DJ, Westesson PL, Brooks SL, Hicks D, Tallents RH. Temporomandibular joint surgically created disk displacement causes arthritis in the rabbit. *Oral Surg Oral Med Oral Pathol*. 1992;73:645–649.
- Qadan S, Macher DJ, Tallents RH, Kyrkanides S, Moss ME. The effect of surgically induced anterior disk displacement of the tem-

- poromandibular joint on the midface and cranial base. *Clin Orthod Res.* 1999;2:124–132.
36. Tallents RH, Macher DJ, Rivoli P, Scapino R, Puzas JE, Katzberg WR. An animal model for meniscus displacement in the rabbit. *J Craniomandib Disord Facial Oral Pain.* 1990;4:233–240.
 37. Legrell PE, Reidel J, Nylander K, Horstedt P, Isberg A. Temporomandibular joint condyle changes after surgically induced non-reducing disk displacement in rabbits: a macroscopic and microscopic study. *Acta Odontol Scand.* 1999;57:290–300.
 38. Hatala MP, Tallents RH, Spoon M, Subtelny JD, Kyrkanides S. Effect of surgically created disk displacement on mandibular asymmetry in the growing rabbit. *Oral Surg Oral Med Oral Pathol Oral Radiol Endod.* 1996;82:625–633.
 39. Katzberg RW, Westesson PL, Tallents RH, Anderson R, Kurita K, Manzione JV, Totterman S. Temporomandibular joint: magnetic resonance assessment of rotational and sideways disk displacement. *Radiology.* 1988;169:74174–74178.
 40. Westesson PL, Katzberg RW, Tallents RH, Sanchez-Woodworth RE, Svensson SA. Temporomandibular joint: comparison of MR images with creosectional anatomy. *Radiology.* 1987;164:59–64.