

Sliding Mechanics with Microscrew Implant Anchorage

Hyo-Sang Park, DDS, MSD, PhD^a; Tae-Geon Kwon, DDS, MSD, PhD^b

Abstract: Three cases are illustrated. One was treated with maxillary microscrew implants, another with mandibular microscrew implants, and the third with both maxillary and mandibular microscrew implants. With the maxillary microscrew implants, the maxillary anterior teeth were retracted bodily with a slight intrusion and all the premolar extraction space was closed without loss of anchorage. Furthermore, the maxillary posterior teeth showed distal movement. The mandibular microscrew implants controlled the vertical position of the mandibular posterior teeth and played an important role in improving the facial profile. The efficacy of sliding mechanics with microscrew implant anchorage on the treatment of skeletal Class II malocclusion is also discussed. (*Angle Orthod* 2004;74:703–710.)

Key Words: Microscrew implants; Absolute anchorage; Sliding mechanics with MIA; Skeletal Class II malocclusion

INTRODUCTION

With increased use of preadjusted appliances, various forms of sliding mechanics have replaced closing loop arches. Sliding mechanics might have great benefits, such as minimal wire-bending time and adequate space for activations.¹

The retraction of four incisors after canine retraction is accepted as a method to minimize the mesial movement of the posterior teeth segment, whereas en masse retraction of six anterior teeth may create anchorage problems. In addition, the tipping action built into anterior brackets in preadjusted appliances may produce problems of anchorage. These problems may be aided by the use of a transpalatal bar and extraoral appliances.^{1,2} However, intraoral anchorage devices may provide unacceptable anchorage, whereas extraoral appliances provide a suitable anchorage but are dependent on patient compliance.

Skeletal anchorage using dental implants,^{3,4} miniplates,⁵ miniscrews,⁶ and microscrews^{7–9} provides an absolute anchorage for tooth movement. Miniscrew or microscrew implants have many benefits such as ease of placement and removal and inexpensiveness. Most importantly, because of their small size, they can be placed in the intra-arch alveolar

bone without discernable damage to tooth roots. In addition, orthodontic force applications can begin almost immediately after placement,⁸ in contrast to dental implants. Therefore, these advantages have expanded the use of mini- or microscrew implants for various orthodontic problems.¹⁰

By using microscrew implants in the mechanics of en masse retraction of six anterior teeth, treatment time can be reduced effectively and clinicians can move teeth to satisfy the treatment goal without patient compliance for anchorage devices. To show the efficacy of the microscrew implants in anchorage control during the retraction of the maxillary anterior teeth, in vertical control of the mandibular posterior teeth and on the facial profile, three cases are presented.

CASE 1. EFFECT OF THE MAXILLARY MICROSCREW IMPLANTS IN CONTROLLING ANCHORAGE FOR RETRACTION OF ANTERIOR TEETH

A 13-year-old female patient presented with lip protrusion and proclined maxillary and mandibular incisors. Because of the protruded incisors, her lips were hardly able to close. The patient had a 5° ANB angle and a high mandibular plane angle (39°) (Table 1). Intraorally, Class II canine and Class I molar relationships were evident, and the overjet and the overbite were six and two mm, respectively. There were no arch length discrepancies in either the maxillary or mandibular arches (Figure 1). The treatment plan called for extraction of the maxillary first and mandibular second premolars and the installation of maxillary microscrew implants for anchorage control.

Treatment

During the extraction appointment, a maxillary microscrew implant (1.2 mm in diameter, six mm long, Stryker

^a Associate Professor, Department of Orthodontics, College of Dentistry, Kyungpook National University, Taegu, South Korea.

^b Assistant Professor, Department of Oral and Maxillofacial Surgery, College of Dentistry, Kyungpook National University, Taegu, South Korea.

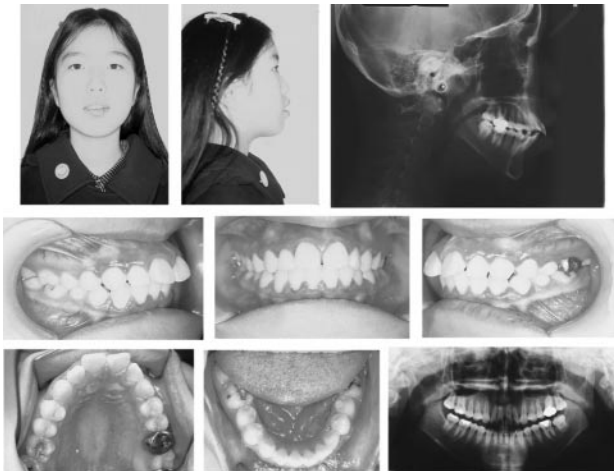
Corresponding author: Hyo-Sang Park, DDS, MSD, PhD, Department of Orthodontics, College of Dentistry, Kyungpook National University, 101, Dongin-2-Ga, Jung-Gu, Taegu 700-422, South Korea (e-mail: parkhs@knu.ac.kr).

Accepted: October 2003. Submitted: July 2003.

© 2004 by The EH Angle Education and Research Foundation, Inc.

TABLE 1. Cephalometric Measurements (case 1)

	Pretreatment	Posttreatment
SNA (°)	82.5	80
SNB (°)	77.5	79.5
ANB (°)	5	0.5
FMA (°)	39	36.5
PFH/AFH (%)	58 (42/72)	61 (44/73)
FH to Occ P (°)	9.5	2.5
Ui to FH (°)	122	119
IMPA (°)	93.5	78
Z angle (°)	55	69

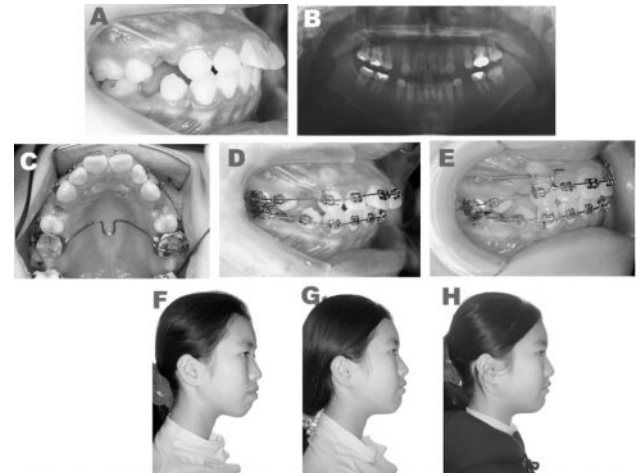
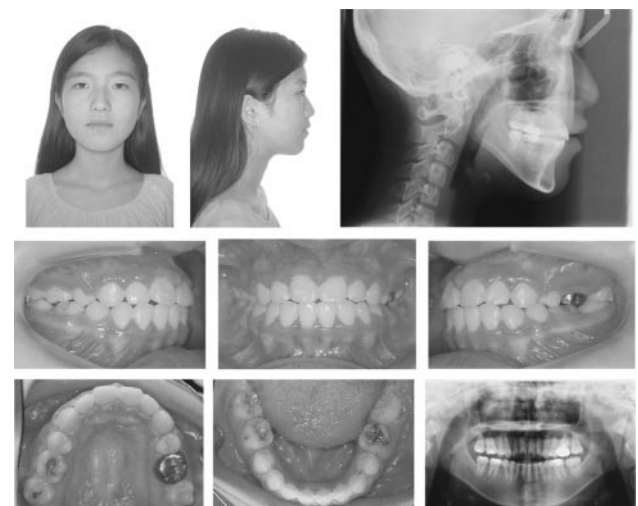**FIGURE 1.** Pretreatment cephalograph, extraoral and intraoral photographs, and panoramic radiograph (case 1).

Leibinger, Kalamazoo, Michigan) was placed bilaterally in the alveolar bone between the maxillary second premolar and first molar. The detailed surgical procedure was discussed in previous reports.⁹⁻¹¹ Two weeks after placement, leveling was initiated with a 0.014-inch Nitinol archwire using 0.022-inch preadjusted appliances. To minimize forward movement of the maxillary canines in the early stages of treatment, a force was applied with tiebacks between the canines and the maxillary microcrew implants. A 0.016- \times 0.022-inch SS archwire with anterior hooks was inserted, and a bilateral force of 150 g was applied with NiTi coil springs to retract the maxillary anterior teeth.

The sequential views of the facial profile showed early improvement. This was the result of en masse retraction of the six anterior teeth instead of the separate canine retraction followed by incisor retraction (Figure 2). After achieving a good facial profile, the retraction forces from the microcrew implants were discontinued. The microcrew implants did not show mobility and stayed firmly in place throughout treatment. They were removed simply by unscrewing them.

Treatment results

After 19 months of treatment time Class I canine and molar relationships were obtained with achievement of a

**FIGURE 2.** Placement of microcrew implants (A, B), transpalatal bar to maintain the arch form (C), tieback to prevent forward movement of canines (D), NiTi retraction force application from microcrew implants (E), and early improvement of profiles at three months (F), eight months (G), and 12 months (H) of treatment.**FIGURE 3.** Posttreatment cephalograph, extraoral and intraoral photographs, and panoramic radiograph (case 1).

harmonious facial profile. The ANB angle was reduced from 5° to 0.5°, SNA was reduced by 2.5° and SNB was increased by 2° (Figure 3). The Z angle, an angle between an FH line and a line from soft tissue menton to the most protruded point of the upper or lower lip, was increased. During the 2.5-year retention period, the facial profile and occlusal relationships showed good retention except for the midline (Figure 4).

Cephalometric superimposition shows that the maxillary anterior teeth retracted bodily seven mm, with two mm of intrusion. The patient had a large amount of mandibular growth, which resulted in forward movement of the chin and an improvement of the facial profile (Figure 5).

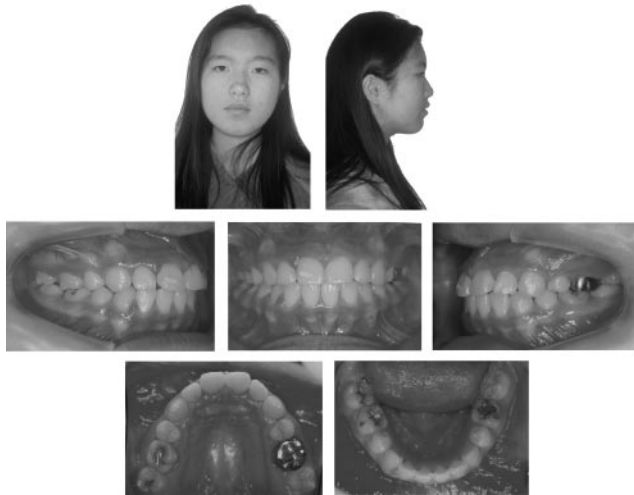


FIGURE 4. Two and a half-year retention extraoral and intraoral photographs.

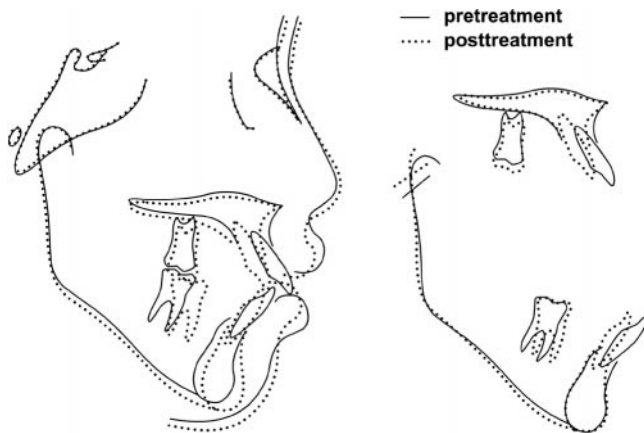


FIGURE 5. Cephalometric superimposition (case 1).

CASE 2. EFFECT OF THE MICROSREW IMPLANTS ON VERTICAL CONTROL OF THE MANDIBULAR MOLARS AND RESULTANT MANDIBULAR RESPONSE

An 11-year-old female patient presented with anterior crowding, convex profile, hyperactive mentalis muscle strain, and a long lower lip to menton length. The mandibular plane angle was 32°, and the maxillary and mandibular anterior teeth showed severe labioversion (Table 2).

Model analysis revealed Class I canine and molar relationships, a three-mm overjet, and a two-mm overbite. The arch length discrepancies in the maxillary and mandibular arches were four and two mm, respectively (Figure 6). The treatment plan called for extraction of the maxillary and mandibular first premolars and use of maximum anchorage.

Treatment

Before any implant use, treatment was begun with initial leveling and retraction of the six anterior teeth using ante-

TABLE 2. Cephalometric Measurements (case 2)

	Pretreatment	Posttreatment
SNA (°)	76.5	76
SNB (°)	74	75.5
ANB (°)	2.5	0.5
FMA (°)	32	31
PFH/AFH (%)	58 (43/74)	61 (46/75)
FH to Occ P (°)	9	6
Ui to FH (°)	123.5	120
IMPA (°)	96.5	81
Z angle (°)	56	70.5

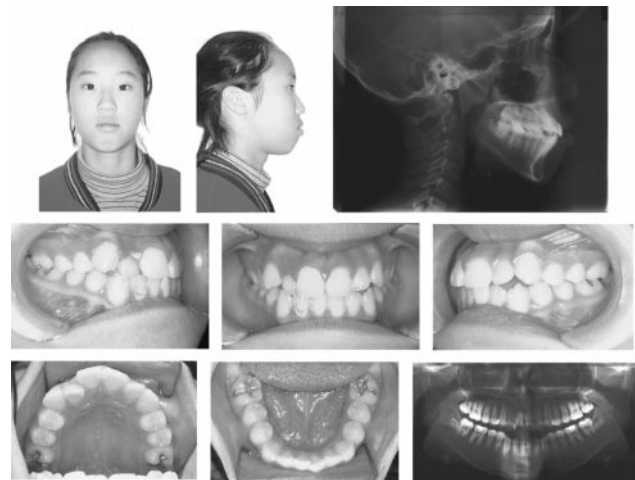

FIGURE 6. Pretreatment cephalograph, extraoral and intraoral photographs, and panoramic radiograph (case 2).

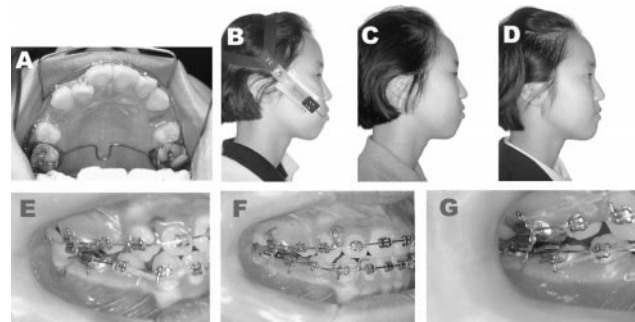


FIGURE 7. Anchorage reinforcement by transpalatal bar (A) and high-pull J hook (B), profile changes from nine months (C) to 11 months of treatment (D) after placement of the mandibular micro-screw implants (E) and application of intruding force to the mandibular archwire (F, G).

rior hooks on a 0.022-inch preadjusted appliance. Although a transpalatal bar was inserted and the patient was compliant with a high-pull J hook for anchorage control, the facial profile was less than desirable after nine months of treatment (Figure 7C).

The retropositioned chin and the long lower lip to menton distance played a role in the facial profile. In addition, the vertical control of the mandibular molars during space

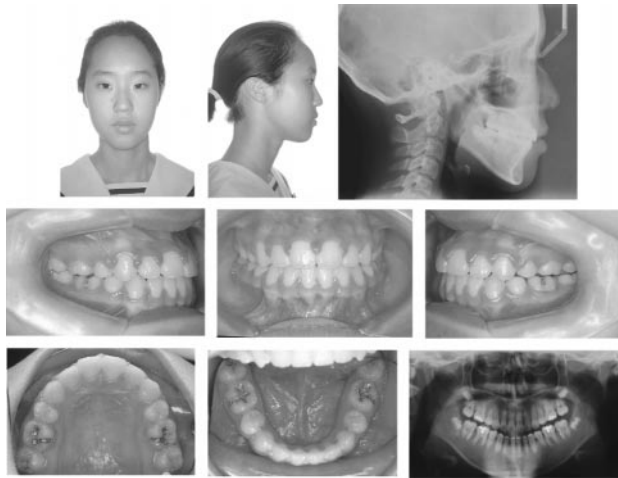

FIGURE 8. Posttreatment cephalograph, extraoral and intraoral photographs, and panoramic radiograph (case 2).

closure was considered important. In other words, the mesial movement of the molars, with uprighting, could be a contributing factor in improving the profile because of a counterclockwise rotation of the mandible as a result of moving the fulcrum forward. Therefore, mandibular microscrew implants (1.2 mm in diameter, six mm long; Osteomed Co., Addison, Tex) were placed between the mandibular first and second molars, and an intruding force was applied from the microscrew implants to a mandibular archwire distal to the first molars. The improvement in the profile after two months of intrusive force application was even evident (Figure 7).

Treatment results

The treatment was finished after 21 months of treatment time with Class I canine and molar relationships. The improvement of the facial profile was achieved by resolution of the hyperactive muscle strain in the mentalis after vertical control of the mandibular posterior teeth during space closure. The ANB angle was reduced by 2°, which was achieved by an increase in the SNB angle (Figure 8). The facial profile and occlusal relationships were maintained during the two-year retention period (Figure 9). Cephalometric superimposition revealed that the mandibular molars were uprighted and moved mesially. This was followed by closure of the mandibular plane angle and an increase in the SNB angle (Figure 10).

CASE 3. EFFECT OF THE MAXILLARY AND MANDIBULAR MICROSCREW IMPLANTS IN RETRACTION OF THE MAXILLARY ANTERIOR TEETH AND VERTICAL CONTROL OF THE MANDIBULAR MOLARS

A 15-year-old male patient presented with lip protrusion and a mandibular retrusion. The patient had dolichofacial

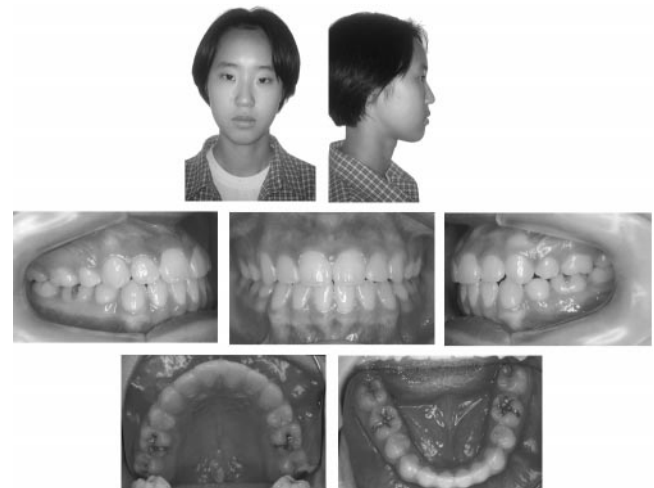


FIGURE 9. Two-year retention extraoral and intraoral photographs.

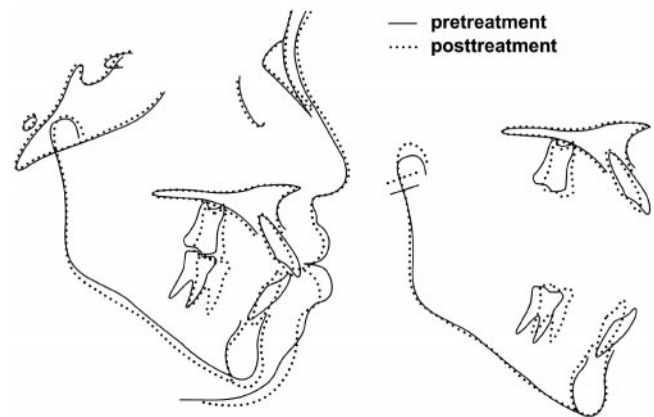


FIGURE 10. Cephalometric superimposition (case 2).

TABLE 3. Cephalometric Measurements (case 3)

	Pretreatment	Posttreatment
SNA (°)	78.5	75
SNB (°)	70.5	72
ANB (°)	8	3
FMA (°)	33.5	34
PFH/AFH (%)	60 (44/73.5)	67 (49/73)
FH to Occ P (°)	9.5	11
Ui to FH (°)	126	112.5
IMPA (°)	102	91.5
Z angle (°)	45	62.5

pattern with a 33.5° mandibular plane angle. There were severe skeletal discrepancies between the maxilla and mandible with an 8° ANB angle (Table 3) and a severe mentalis strain and retruded mandible. Intraorally, a bilateral Class II canine and molar relationship, a large overjet (13 mm) and overbite (five mm), and a bilateral posterior crossbite of both mandibular first molars were evident. The maxillary and mandibular arches showed one- and zero-mm arch length discrepancies, respectively. The patient had a deep

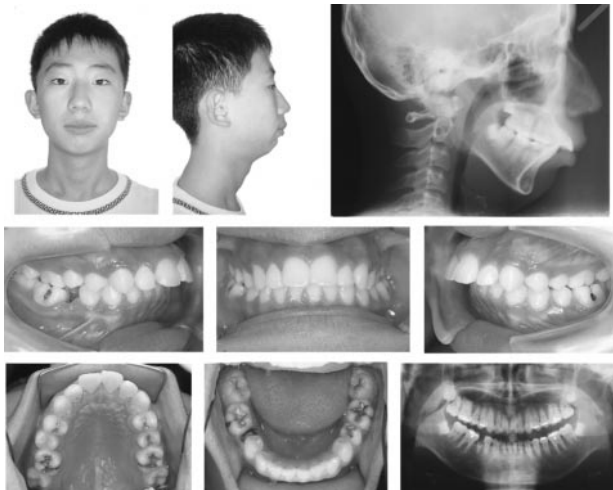

FIGURE 11. Pretreatment cephalograph, extraoral and intraoral photographs, and panoramic radiograph (case 3).

curve of Spee (three mm). The right mandibular second premolar residual root was present (Figure 11).

The first treatment option was maxillary impaction and mandibular advancement surgery, but the patient rejected this option. Another option was extraction of the maxillary first premolars and the use of microcrew implants for anchorage control. The patient and his parents requested this treatment and said they would be satisfied if the large overjet was reduced and an occlusion established. We decided to extract the maxillary first premolars and treat the patient by orthodontic treatment only, but with the aid of microcrew implants.

Treatment

During the extraction procedure, the maxillary microcrew implants (1.2 mm in diameter, six mm long, Stryker Leibinger) were placed in the same locations as in case 1. Preadjusted 0.022-inch appliances were used, and tiebacks from the microcrew implants to the canines were applied to prevent forward movement. After alignment of the anterior teeth, a 0.016- × 0.022-inch SS archwire with anterior hooks was inserted, and a 150-g force was applied on each side with NiTi coil springs. As the anterior teeth were retracted, the overjet was reduced.

The initial Class II molar relationship contraindicated lower extractions. However, because of a residual root on the right mandibular second premolar and a posterior cross-bite, we decided to extract the second premolars to correct the molar relationship. In addition, the mandibular microcrew implants (1.2 mm in diameter, six mm long, Osteomed Co.) were placed in the alveolar bone between the first and second molars for vertical control of the mandibular molars during space closure. The facial profile showed a remarkable improvement during 11 months of treatment. Closure of the remaining extraction space in the mandibular arch,

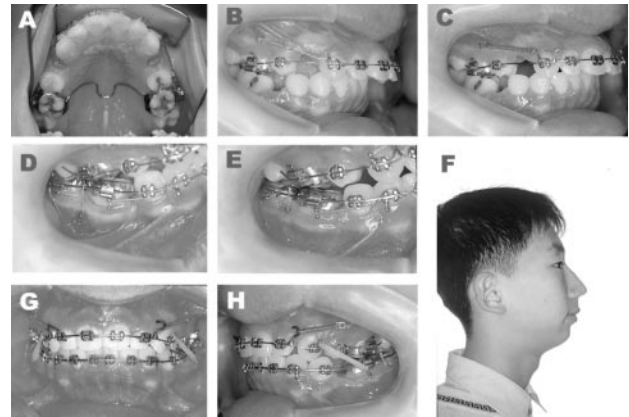


FIGURE 12. Transpalatal bar (A), tieback to prevent forward movement of a canine (B), en masse retraction of six anterior teeth against a microcrew implant (C), placement of mandibular microcrew implants and intruding force application (D, E), extraoral photographs at 11 months of treatment (F), and intraoral photographs at 18 months of treatment (G, H).

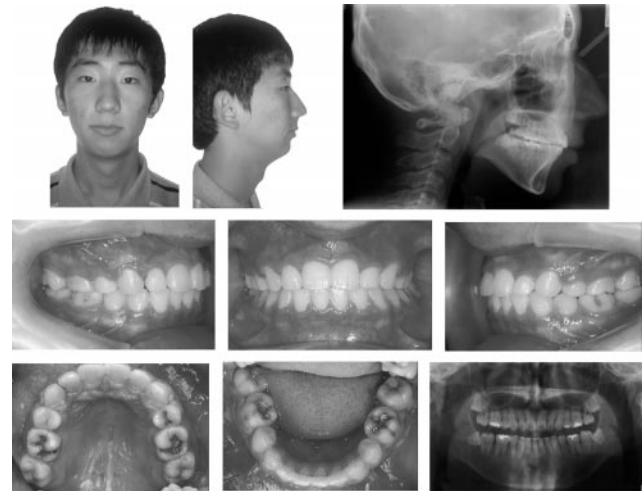


FIGURE 13. Posttreatment cephalograph, extraoral and intraoral photographs, and panoramic radiograph (case 3).

especially on the left side, required more treatment time than that needed for retraction of the maxillary anterior teeth and improvement of the profile (Figure 12).

Treatment results

After 34 months of treatment, the patient was finished with Class I canine and molar relationships and a clinically acceptable facial profile. The facial profile was improved by reduction of the ANB angle from 8° to 3°, obtained mainly by a decrease in the SNA angle (Figure 13). The cephalometric superimposition showed that the maxillary anterior teeth moved distally 13 mm, with two mm of intrusion. The maxillary posterior teeth experienced a slight distal movement with uprighting of both the mandibular posterior and anterior teeth. The patient showed a very lim-

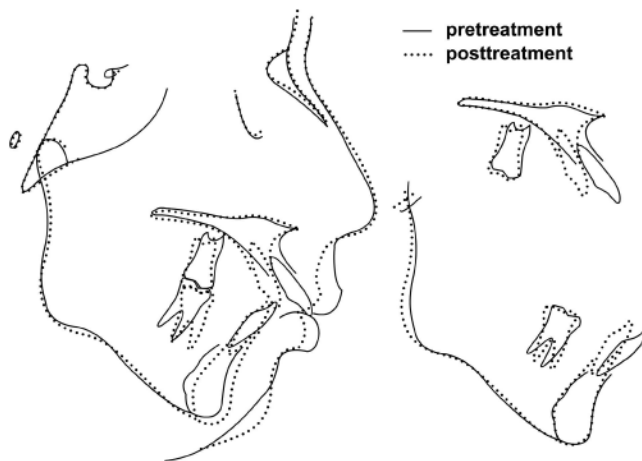


FIGURE 14. Cephalometric superimposition (case 3).

ited amount of mandibular growth, making treatment difficult (Figure 14).

DISCUSSION

Sliding mechanics for en masse retraction of the anterior teeth have become more common with increased use of preadjusted appliances. The tip built into anterior brackets tends to tip anterior teeth forward during initial leveling and jeopardize anchorage.¹ Attempts to retract the six anterior teeth simultaneously result in anchorage loss problems as shown in case 2. If there were acceptable anchorage devices, it would be more reasonable to retract the six anterior teeth simultaneously in one rather than two steps. When microscREW implants are used, clinicians can retract six anterior teeth altogether without anchorage loss even with the use of preadjusted appliances.

The maxillary anterior teeth were bodily retracted against microscREW implants in cases 1 and 3. The center of resistance of the six anterior teeth was estimated to be halfway between the center of resistance of the four incisors and canines.¹² By using an upward and backward force passing near the center of resistance, the maxillary anterior teeth showed bodily intrusion and retraction.

The occlusogingival position of microscREW implants determines the force direction so that the retraction of the anterior teeth can be controlled. A second factor capable of changing the direction of force is the vertical position of the anterior hooks. For example, the use of short anterior hooks would increase the vertical component and decrease the horizontal component of the force and vice versa. For bodily retraction of the anterior teeth with a slight intrusion, the proper position of the maxillary microscREW implants was 8–10 mm apical to the bracket slot with the anterior hooks 5–6 mm gingival to the bracket slot. With this configuration, the force will pass just under the center of resistance and induce bodily retraction with only slight linguoersion and intrusion.

The torquing curve in an archwire could be another factor in controlling anterior teeth movement. The movement of the anterior teeth could be changed by increasing or decreasing the height of the anterior hooks and the amount of torquing curve during treatment after evaluation through cephalometric superimposition (Figure 15A).

If the maxillary force passes close to the center of resistance, this could eliminate the need for applying lingual root torque to the archwire to prevent lingual tipping. In fact, no torque was applied to the anterior teeth using 0.016- × 0.022-inch archwire in 0.022-inch brackets. However, the maxillary anterior teeth in cases 1 and 3 show the well-controlled inclination to the FH plane at posttreatment. Elimination of the unnecessary requirement of applying lingual root torque on the maxillary anterior teeth makes treatment mechanics simpler. The only factors clinicians should keep in mind are the direction of the force and the response of the teeth to the force.

The maxillary anterior teeth in cases 1 and 3 were retracted enough to close all the extraction space from the anterior. Furthermore, in case 3, the maxillary posterior teeth show a slight distal movement. On the other hand, the maxillary posterior teeth show a fairly large amount of mesial movement or anchorage loss in conventional mechanics. For example, in case 2, despite the use of the transpalatal bar and high-pull J hook, anchorage loss occurred. This means that small microscREW implants can provide sufficient anchorage to retract the whole dentition distally without patient compliance and extraoral appliances.^{9,11}

Because there is a tendency for the forward and downward movement of the retracted maxillary anterior teeth during posttreatment settling, the maxillary anterior teeth should be retracted to overcorrected positions, with a shallow overjet and overbite and a super Class I relationship.

En masse retraction of the six anterior teeth, instead of step-by-step retraction of the canine and four incisors can reduce treatment time and allow an early change of the facial profile. This increases patient cooperation in treatment. The important aspect of this approach is that teeth can be moved to their exact treatment goal. The amount of maxillary retraction or teeth movement can be controlled by continuing or discontinuing the retracting force. The decision of when to discontinue the maxillary retraction force is determined after evaluating the facial profile and occlusal relationships.

Several studies have stated that the palatal cortical bone and the width of the alveolar bone could be a limiting factor for orthodontic retraction of the anterior teeth.¹³ These studies state that if the teeth are moved beyond these limits, root resorption and dehiscence could be expected to occur. Edwards¹⁴ found that the bone at the midroot level and alveolar margin but not the bone at higher levels was remodeled with tooth movement and postulated that an anatomical barrier for retraction of the teeth existed higher at the anterior palatal curvature. In cases 1 and 3, the maxil-

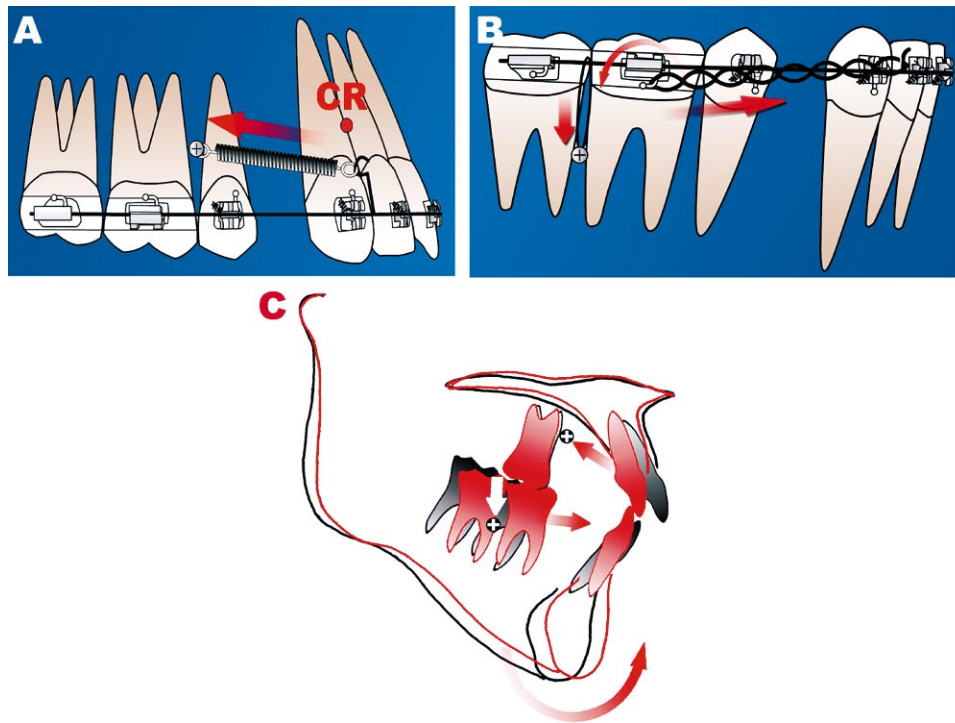


FIGURE 15. Biomechanics concerning en masse retraction of maxillary anterior teeth (A) and intruding force application on the mandibular posterior teeth area (B), and changes expected after the uprighting and mesial movement of the mandibular posterior teeth (C).

lary anterior teeth were retracted seven and 13 mm, respectively. However, although the teeth moved distally beyond theoretical limits of the orthodontic treatment,¹⁵ there was no obvious evidence of root resorption. This might be explained by young age of patients and mode of tooth movement in relation to the palatal cortical bone. The retraction accompanied with intrusion could make the maxillary anterior teeth stay in the alveolar trough at root apex level during retraction. However, when treating adult patients, the amount of anterior teeth retraction could be limited.

Vertical control of the mandibular posterior teeth has been considered an important factor for the mandibular response and improvement of the profile.^{16,17} The mandibular microscrew implants provided vertical intrusive force to the archwire distal to the first molars. This exerted uprighting forces on the first molars and an intrusive force on the second molars (Figure 15B). The mesial movement of the mandibular posterior teeth could move a fulcrum forward and as a result close the mandibular plane. An increase in the SNB angle and forward and upward movement of the chin follow (Figure 15C). This was a major factor in the improvement of the facial profile. In case 2, most of the ANB reduction was obtained by the increase in the SNB angle. However, patients who did not have growth potential or a short mandible were unlikely to present this response, as shown in case 3. This should be elucidated with a larger sample size in further studies.

Intermaxillary elastics to correct Class II canine and mo-

lar relationships cause the extrusion of the posterior teeth and opening of the mandibular plane, which results in a deleterious effect on the facial profile.¹⁸ In sliding mechanics with microscrew implant anchorage (MIA), the need for intermaxillary elastics is usually eliminated. This prevents extrusion of the posterior teeth and opening of the mandibular plane.

The small size, oblique placement against bone surface, and placement into the apical area of roots where more space is present could make the microscrew implants avoid the roots in the maxilla.¹⁹ The thick cortical bone in the mandibular posterior alveolar bone²⁰ is enough to bear the microscrew implants without damaging the roots.

The microscrew implants placed in these three cases showed no mobility throughout treatment, even though they were loaded with 150–200 g of force two weeks after placement. Early loading of the microscrew implants contributed to reduction in treatment time. The mandibular microscrew implants tended to be covered by soft tissue so that a ligature wire extension was needed to attach elastic materials (Figures 7G and 12E). The head of the maxillary microscrew implants could be exposed from the soft tissue, but the elastic materials were prone to move down into the soft tissue and cause an inflammation around the neck of the microscrew implants. Ligature hooks were used to attach elastic materials in cases 1 and 3, which were helpful in reducing soft tissue inflammation (Figures 2E and 12C,H). To avoid soft tissue impingement around the canine eminence, a ligature hook should be used above the

head of the microscrew implants and the anterior hooks on the archwire should be bent out. The microscrew implants used in these cases were surgical microscrews, which have been used to stabilize plates in facial bone fracture reduction surgery. To minimize soft tissue problems and to ease attachment of elastic materials, the authors modified the shape of the head of the microscrews and developed a new microscrew implant. This implant is characterized by a button on the head for attaching elastic materials and a smooth unthreaded neck in contact with the soft tissue.¹⁰

The characteristics of sliding mechanics with MIA are independence from patient compliance, an early improvement of the facial profile, and shortened treatment time by retracting six anterior teeth simultaneously. The use of the force passing near the center of resistance simplifies treatment mechanics. Chair time can be reduced by the decreased number of archwire changes. By using microscrew implants, clinicians can correct Class II and Class III dental relationships efficiently in a shorter treatment time by moving quadrants of the dentition distally or mesially. The midline discrepancy can also be controlled easily and consistently with microscrew implants. As previously reported, intrusion of the incisors and molars can easily be achieved.¹⁰

Microscrew implants might make changes in treatment planning. For instance, patients who have mild Class III skeletal problems but resist orthognathic surgery can be treated with microscrew implant-aided mechanics. When extraction is required, healthy sound teeth can be preserved by extracting decayed teeth, no matter where the teeth are located in the mouth. Most importantly, in most cases, teeth can be moved to satisfy a more precise treatment plan and treatment goal.

CONCLUSIONS

The maxillary anterior teeth were retracted seven and 13 mm with the aid of microscrew implants in cases 1 and 3, respectively. The mandibular forward and upward response was evident in case 2 with uprighting of the molars during space closure by intruding forces from the microscrew implants.

Sliding mechanics with maxillary microscrew implants provide anchorage for bodily retraction with a slight intrusion by making the force pass near the center of resistance. The maxillary posterior teeth and anterior teeth can both be retracted without anchorage loss. The mandibular microscrew implants control the vertical mandibular molar position and contribute to improvement of the facial profile.

REFERENCES

1. McLaughlin RP, Bennett JC. The transition from standard edge-wise to preadjusted appliance systems. *J Clin Orthod.* 1989;23:142-153.
2. McLaughlin RP, Bennett JC. Anchorage control during leveling and aligning with a preadjusted appliance system. *J Clin Orthod.* 1991;25:687-696.
3. Shapiro PA, Kokich VG. Uses of implants in orthodontics. *Dent Clin North Am.* 1988;32:539-550.
4. Roberts WE, Nelsen CL, Goodacre CJ. Rigid implant anchorage to close a mandibular first molar extraction site. *J Clin Orthod.* 1994;28:693-704.
5. Unemori M, Sugawara J, Mitani H, Nagasaka H, Kawamura H. Skeletal anchorage system for open bite correction. *Am J Orthod Dentofacial Orthop.* 1999;115:166-174.
6. Creekmore TD. The possibility of skeletal anchorage. *J Clin Orthod.* 1983;17:266-269.
7. Kanomi R. Mini-implant for orthodontic anchorage. *J Clin Orthod.* 1997;31:763-767.
8. Deguchi T, Takano-Yamamoto T, Kanomi R, Hartsfield JK Jr, Roberts WE, Garetto LP. The use of small titanium screws for orthodontic anchorage. *J Dent Res.* 2003;82:377-381.
9. Park HS. The skeletal cortical anchorage using titanium microscrew implants. *Korean J Orthod.* 1999;29:699-706.
10. Park HS. *The Use of Micro-Implant as Orthodontic Anchorage.* Seoul, South Korea: Nare Pub Co; 2001:5-124.
11. Park HS, Bae SM, Kyung HM, Sung JH. Micro-implant anchorage for treatment of skeletal Class I bialveolar protrusion. *J Clin Orthod.* 2001;35:417-422.
12. Melsen B, Fotis V, Burstone CJ. Vertical force considerations in differential space closure. *J Clin Orthod.* 1990;24:678-683.
13. Horiuchi A, Hotokezaka H, Kobayashi K. Correlation between cortical plate proximity and apical root resorption. *Am J Orthod Dentofacial Orthop.* 1998;114:311-318.
14. Edwards JG. A study of the anterior portion of the palate as it relates to orthodontic therapy. *Am J Orthod.* 1976;69:249-273.
15. Proffit WR, Ackerman JL. Diagnosis and treatment planning in orthodontics. In: Graber TM, Vanarsdall RL Jr, eds. *Current Orthodontic Concepts and Techniques*, 2nd ed. St Louis, Mo: Mosby; 1995:3-95.
16. Klontz HA. Facial balance and harmony: an attainable objective for the patient with a high mandibular plane angle. *Am J Orthod Dentofacial Orthop.* 1998;114:176-188.
17. Gebeck TR. Analysis-concepts and values, Part 1. *J Tweed Found.* 1989;17:19-48.
18. Yamaguchi K, Nanda RS. The effects of extraction and nonextraction treatment on the mandibular position. *Am J Orthod Dentofacial Orthop.* 1991;100:443-452.
19. Park, HS. An anatomical study using CT images for the implantation of micro-implants. *Korean J Orthod.* 2002;32:435-441.
20. Champy M, Pape H, Gerlach KL, Lodde JP. Mandibular fracture. In: Kruger E, Schilli W, eds. *Oral and Maxillofacial Traumatology*, Vol. 2. Chicago, Ill: Quintessence Publishing Co; 1986:19-43.