

# The Efficient Use of Midpalatal Miniscrew Implants

Jong-Suk Lee, DDS, MSD<sup>a</sup>; Doo Hyung Kim, DDS<sup>b</sup>; Young-Chel Park, DDS, PhD<sup>c</sup>;  
Seung-Hyun Kyung, DDS, PhD<sup>d</sup>; Tae-Kyung Kim, DDS, MSD<sup>e</sup>

**Abstract:** The midpalatal suture area with thin, keratinized soft tissue and sufficient cortical bone is an optimal site for miniscrew implantation. Even though the midpalatal area has its own anatomical limitations, it can be overcome by bonding extension arms to the miniscrews. This technique also enhances screw stability, thus producing a successful outcome. Among many applications, midpalatal miniscrew implants can be effectively used for intrusion of upper molars with reduced treatment time and enhanced patient comfort. (*Angle Orthod* 2004;74:711–714.)

**Key Words:** Miniscrew; Molar intrusion; Midpalate

## INTRODUCTION

Achieving absolute anchorage has been a very important topic of interest in the field of orthodontics. The rule of “action and reaction” is applied in every orthodontic treatment. Intrusion of extruded teeth and distalization of anterior teeth, all cause undesired displacement of the adjacent teeth, hindering the required tooth movement. Orthodontists have always struggled to prevent such side effects. As part of their efforts, there has been much research on endosseous implants for absolute anchorage.<sup>1–4</sup> In 1984, Roberts et al<sup>5</sup> investigated the tissue response from orthodontic force applied to endosseous implants. In the 1990s, case reports using these concepts were published.<sup>6–7</sup> The endosseous implants used in previous studies were mostly blade-type or conventional prosthodontic fixtures, which were difficult for orthodontists to use clinically because of the complex procedure involved and their high cost. Later, Kanomi<sup>8</sup> and Costa et al<sup>9</sup> introduced endosseous implants that were more

suitable for orthodontic purposes, with simplified implant procedures and lowered costs.

Miniscrews implanted in the maxilla have less stability than those implanted in the mandible because of the more porous maxillary bone structure. However, the midpalatal suture area is composed of dense cortical bone, and this site has been determined as the best anchorage site in the maxilla.<sup>10</sup>

In this case report, a simplified clinical procedure for the application of midpalatal miniscrew implants is discussed, with a presentation of a case of a patient treated using midpalatal miniscrew implants.

## APPLIANCE FABRICATION

Two miniscrews (Martin<sup>®</sup> Tuttlingen, Germany) two mm in diameter and seven mm in length are implanted on the midpalatal area seven mm apart (Figure 1a). An extension arm is fabricated with 0.9 mm stainless steel wire following the contour of the palate (Figure 1b). Hooks are soldered to the wire (Figure 1c), whereas metal mesh is welded to the extension arm (Figure 1d). The appliance is light cured to the implanted miniscrews (Transbond, 3M<sup>®</sup> Unitek Monrovia, Calif, USA) (Figure 1e), with additional resin application on the surface for enhanced patient comfort.

## CASE

A 50-year-old male patient was referred from the prosthodontic department for intrusion of the upper left first and second molars. As seen in Figure 2, the upper left first and second molars were extruded because of the loss of the lower left first and second molars. Because of the crowding existing in the upper left molar area, space was first obtained with open coil springs. Extraction of the upper left third molar was scheduled because of severe caries, but it

<sup>a</sup> Lecturer, Department of Orthodontics, Yonsei University, Seoul, South Korea.

<sup>b</sup> Resident, Department of Orthodontics, Yonsei University, Seoul, South Korea.

<sup>c</sup> Professor, Department of Orthodontics, College of Dentistry, Oral Science Research Center, Institute of Craniofacial Deformity, Yonsei University, Seoul, South Korea.

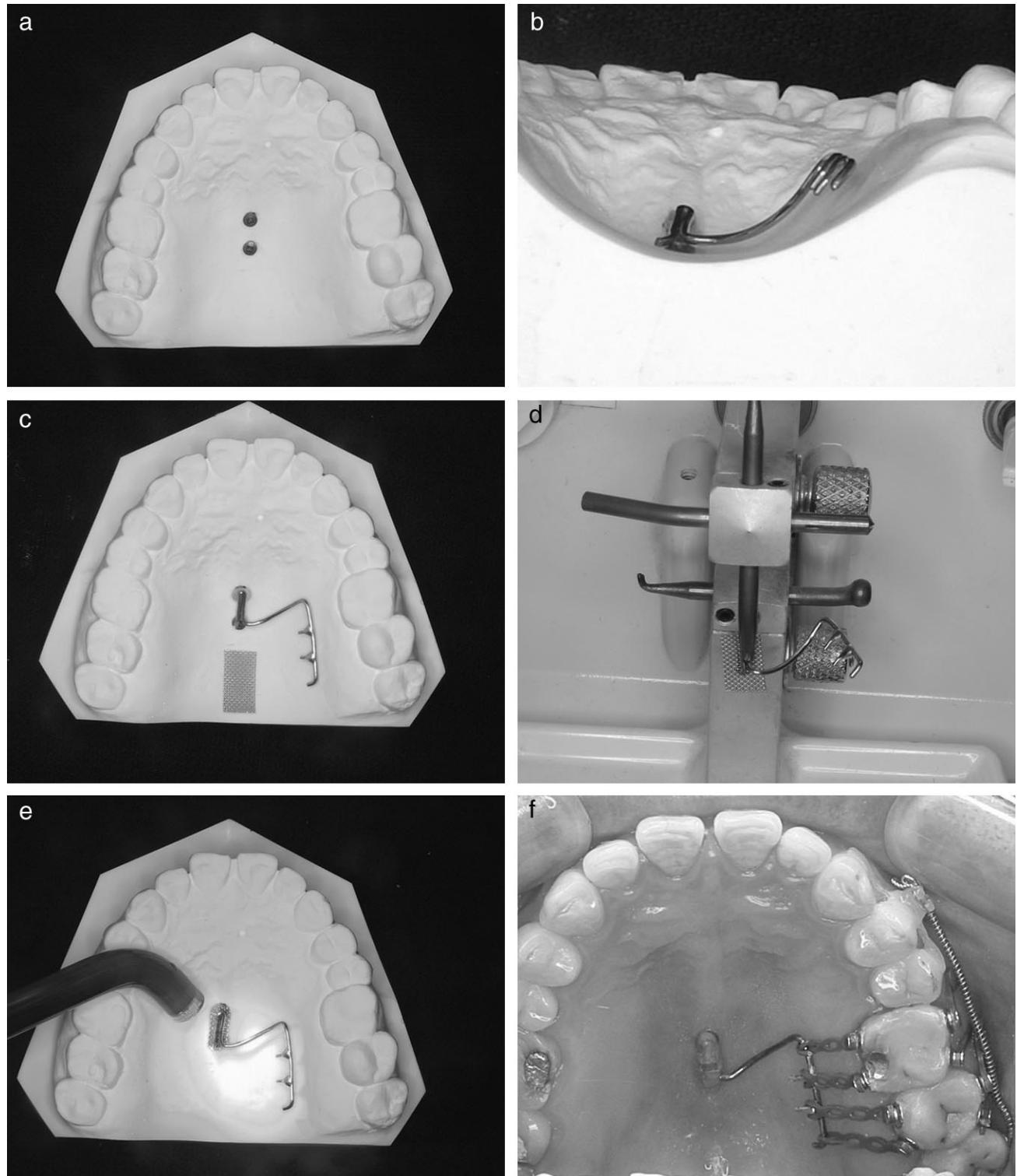
<sup>d</sup> Assistant Professor, Department of Orthodontics, Samsung Medical Center, Sungkyunkwan University School of Medicine, Seoul, South Korea.

<sup>e</sup> Clinical Assistant Professor, Department of Orthodontics, Yonsei University, Seoul, South Korea.

Corresponding author: Young-Chel Park, DDS, PhD, Department of Orthodontics, College of Dentistry, Oral Science Research Center, Institute of Craniofacial Deformity, Yonsei University, Seodaimun Gu, Shinchon Dong 134, Seoul, 120-732 South Korea (e-mail: ypark@yumc.yonsei.ac.kr).

Accepted: November 2003. Submitted: September 2003.

© 2004 by The EH Angle Education and Research Foundation, Inc.



**FIGURE 1.** The procedure for splinting two miniscrew implants. (a) Two miniscrews (Martin®) two mm in diameter and seven mm in length are implanted on the midpalatal area seven mm apart. (b) An extension arm is fabricated with 0.9 mm stainless steel wire according to the contour of the palate. (c) Hooks are soldered to the wire. (d) Metal mesh is welded to the extension arm. (e) The appliance is light cured to the implanted miniscrews (Transbond, 3M® Unitek). (f) Additional resin is applied on the surface for enhanced patient comfort.

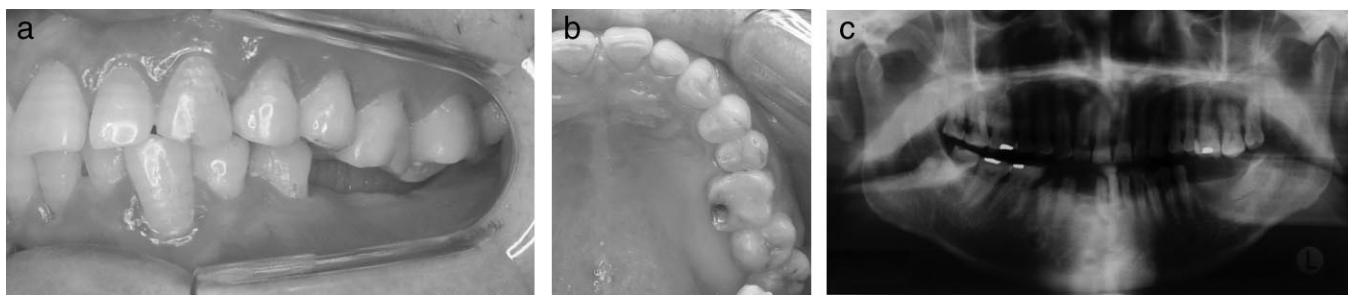


FIGURE 2. (a, b) Initial intraoral photograph. (c) Initial radiograph.

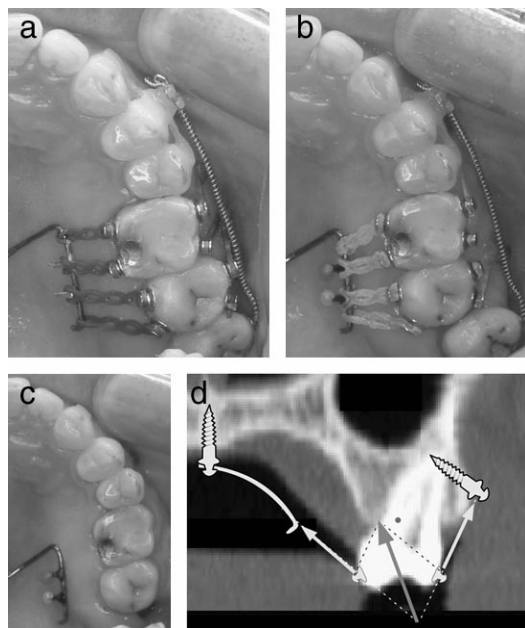


FIGURE 3. (a–c) Initial, progress, and posttreatment intraoral photographs. (d) Force system applied in this patient.

was delayed until the intrusion was complete to act as a reference point.

The upper left canine to second premolar teeth were bonded with fiber-reinforced composites<sup>11</sup> (Splint-It®, Jeneric/Pentron, Inc Wallingford, CT, USA) for stabilization. Two miniscrews (two × seven mm, Martin®) were implanted in the midpalate, and additional three miniscrews were implanted on the buccal side, mesiodistal to the extruded teeth. As described in Figure 1, the two midpalatal miniscrews were splinted together with extension arms. An intrusion force of 150–200 gm was applied to the upper left first and second molars (Figure 1f).

The treatment progress is shown in Figure 3. Note the change in the first and second molars relative to the third molar. It is not easy to obtain a vector sum that passes through the center of resistance due to the anatomy of the palatal and buccal alveolar bone (Figure 3d). Therefore, monitoring is important to verify the torque and buccopalatal position of the molars being intruded. If the molar is tilted more to the palatal side during intrusion, the activa-

tion rate on the buccal side should be increased to obtain proper intrusion.

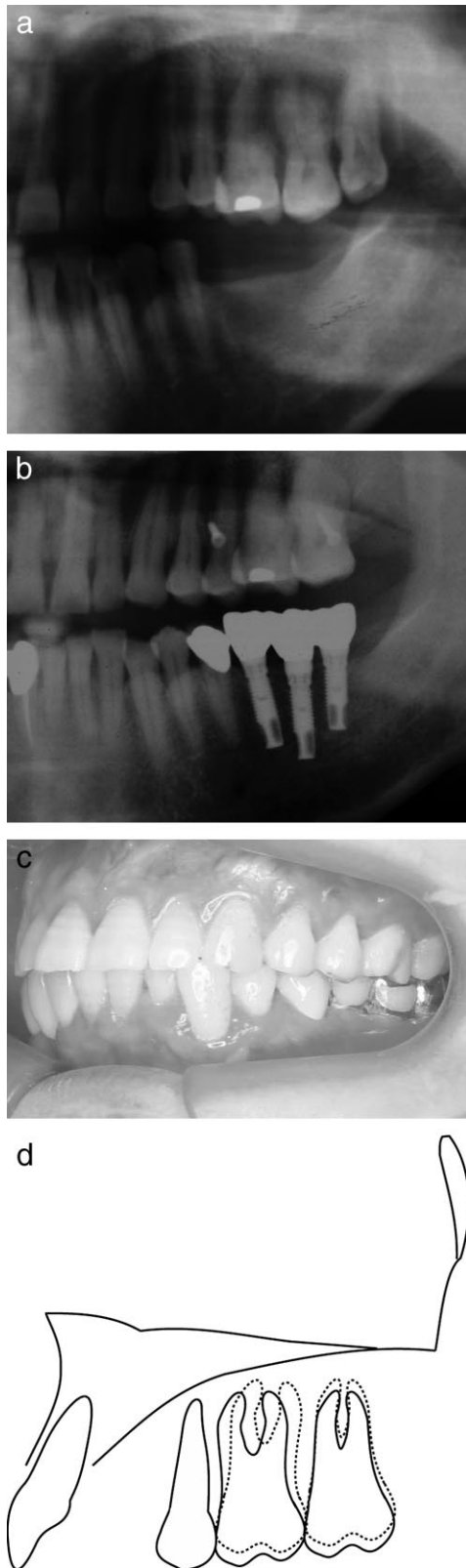
It took seven months from the first visit to the completion of the prosthodontic treatment. The comparison of the panoramic radiographs shows successful intrusion at the end of treatment (Figure 4). The total treatment time is reduced by orthodontic treatment proceeding after inserting the prosthodontic implants in the lower edentulous area. The appliance bonded to the miniscrew implants remained intact until the end of the orthodontic treatment.

## DISCUSSION

The midpalate is an excellent area in the maxilla for miniscrew implantation in terms of soft and hard tissue characteristics. Thin, keratinized soft tissue in the midpalatal area is more advantageous for screw implantation than the thick soft tissue that can be found in the palatal slope. According to Yun et al,<sup>12</sup> soft tissue in the palatal slope is two to three times thicker than it is on the buccal side. It is difficult to obtain adequate screw stability in these areas with thick soft tissue. Yun et al<sup>12</sup> also reported that a uniform soft tissue thickness of one mm is present in the midpalatal area four mm posterior to the incisive papilla. Therefore, the soft tissue in the midpalatal area is optimal for miniscrew implantation.

In terms of hard tissue, the stability of miniscrew implants depends on the quality and quantity of the cortical bone. The midpalatal area is composed of a good quality and quantity of cortical bone. According to the classification of Misch,<sup>13</sup> the maxilla is mostly composed of porous bone corresponding to D3 or D4, whereas the midpalatal area has dense cortical bone corresponding to D1 or D2. In addition, Wehrbein and coworkers<sup>14–16</sup> stated that bone around the midpalatal area is two mm thicker than its image observed on the lateral cephalometric radiograph, also supporting the concept that the adequate amount of cortical bone in the midpalatal area is suitable for screw implantation.

In spite of its soft and hard tissue advantages, the midpalatal area was thought to be inadequate for clinical use because of its distance from the teeth. The use of miniscrew implantation along with extension arms provides a solution



**FIGURE 4.** (a, b) Initial and posttreatment radiograph. (c) Final intraoral slide. (d) Superimposition of initial (solid line) and final (broken line) tracings.

for this topographic limitation. In addition, screw stability can be further enhanced by splinting two miniscrews together, producing a successful outcome.

## CONCLUSIONS

Midpalatal miniscrew implantation is a powerful tool in modern orthodontics. Among many applications, it can be effectively used for intrusion of upper molars with reduced treatment time and enhanced patient comfort.

## REFERENCES

1. Gainsforth BL, Higley LB. A study of orthodontic anchorage possibilities in basal bone. *Am J Orthod Oral Surg.* 1945;31:406–417.
2. Linkow LI. The endosseous blade implant and its use in orthodontics. *Int J Orthod.* 1969;18:149–154.
3. Linkow LI. Implanto-orthodontics. *J Clin Orthod.* 1970;4:685–705.
4. Creekmore TD, Eklund MK. Possibility of skeletal anchorage. *J Clin Orthod.* 1983;17:266–267.
5. Roberts WE, Smith RK, Zilberman Y, Mozsary PG, Smith RS. Osseous adaptation to continuous loading of rigid endosseous implants. *Am J Orthod Dentofacial Orthop.* 1984;86:95–111.
6. Roberts WE, Marshall KJ, Mozsary PL. Rigid endosseous implant utilized as anchorage to protract molars and close an atrophic extraction site. *Angle Orthod.* 1990;60:135–152.
7. Roberts WE, Arbuckle GR, Analoui M. Rate of mesial translation of mandibular molars using implant-anchored mechanics. *Angle Orthod.* 1996;66:331–337.
8. Kanomi R. Mini-implant for orthodontic anchorage. *J Clin Orthod.* 1997;11:763–767.
9. Costa A, Raffaini M, Melsen B. Miniscrews as orthodontic anchorage: a preliminary report. *Int J Adult Orthod Orthognath Surg.* 1998;13:201–209.
10. Schlegel KA, Kinner F, Schlegel KD. The anatomic basis for palatal implants in orthodontics. *Int J Adult Orthod Orthognath Surg.* 2002;17:133–139.
11. Burstone CJ, Kuhlberg AJ. Fiber-reinforced composites in orthodontics. *J Clin Orthod.* 2000;34:271–279.
12. Yun HS, Kim HJ, Park YC. *The Thickness of the Maxillary Soft Tissue and Cortical Bone Related With an Orthodontic Implantation* [master's thesis]. Seoul, South Korea: Yonsei University; 2001.
13. Misch CE. *Contemporary Implant Dentistry*, 2nd ed. St Louis, Mo: Mosby; 1999;8:110–118.
14. Wehrbein H, Merz BR, Diedrich P, Glatzmaier J. The use of palatal implants for orthodontic anchorage. Design and clinical application of the orthosystem. *Clin Oral Impl Res.* 1996;7:410–416.
15. Wehrbein H, Merz BR. Aspects of the use of endosseous palatal implants in orthodontic therapy. *J Esthet Dent.* 1998;10:315–324.
16. Wehrbein H, Merz BR, Diedrich P. Palatal bone support for orthodontic implant anchorage—a clinical and radiological study. *Eur J Orthod.* 1999;21:65–70.