

Screw-type Implants Used as Anchorage for Lingual Orthodontic Mechanics: A Case of Bimaxillary Protrusion with Second Premolar Extraction

Masayoshi Kawakami, DDS, PhD^a; Shouichi Miyawaki, DDS, PhD^b;
Haruhiro Noguchi, DDS, PhD^c; Tadaaki Kirita, DDS, DMSc^d

Abstract: We present a case of bialveolar protrusion treated with second premolar extraction. The patient did not agree to placement of a visible labial appliance or to the use of a headgear. Therefore, a lingual orthodontic appliance was used, and titanium screws were placed into the buccal alveolar bone for orthodontic absolute anchorage and support of en masse retraction of the anterior teeth. Cephalometric superimposition and panoramic radiographs showed little anchorage loss and good occlusion at the end of treatment. Our results suggest that lingual treatment combined with a screw-type implant anchorage provides reliable and comfortable results for those seeking invisible treatment. (*Angle Orthod* 2004;74:715–719.)

Key Words: Lingual orthodontics; Titanium screw; Anchorage

INTRODUCTION

Adult patients often reject the use of a headgear and placement of a visible labial appliance because of esthetic and social concerns. However, lack of such cooperation results in anchorage loss and insufficient treatment results. Lingual orthodontics is an alternative solution, but stable anchorage using an extraoral appliance is often needed.

The recent introduction of implants provides clinicians with an alternative anchorage system instead of the conventional extraoral appliance and transpalatal arch.¹ Titanium screws have been shown to provide a simple means of anchorage to obtain en masse retraction without anchorage loss.^{1–3} An anchorage system with titanium screws provides advantages in orthodontic treatment including space closure, intrusion, and distalization of posterior teeth. The screws are usually placed in the buccal alveolar bone, where the dental root will not be damaged.⁴ With the ad-

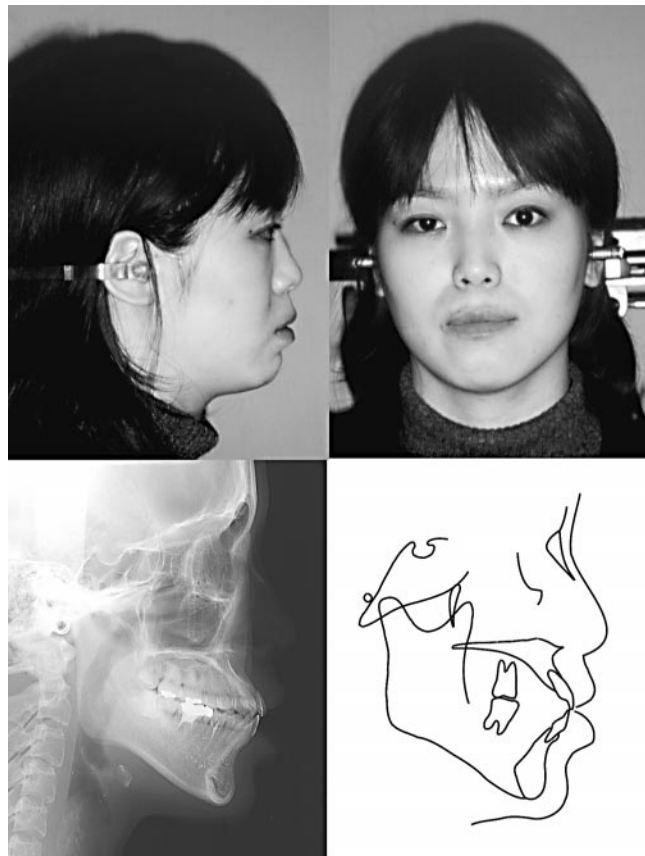

FIGURE 1. Initial facial photographs with lateral cephalogram and its tracing.

^a Assistant Professor, Department of Oral and Maxillofacial Surgery, Nara Medical University, Kashihara Nara, Japan.

^b Assistant Professor and Lecturer, Department of Orthodontics and Dentofacial Orthopedics, Okayama University Graduate School of Medicine and Dentistry, Japan.

^c Private practice, Kohriyama Nara, Japan.

^d Professor and Chair, Department of Oral and Maxillofacial Surgery, Nara Medical University, Kashihara Nara, Japan.

Corresponding author: Masayoshi Kawakami, DDS, PhD, Department of Oral and Maxillofacial Surgery, Nara Medical University, 840 Shijo-cho, Kashihara Nara 634-8522, Japan (e-mail: mkawaka@naramed-u.ac.jp).

Accepted: October 2003. Submitted: September 2003.

© 2004 by The EH Angle Education and Research Foundation, Inc.

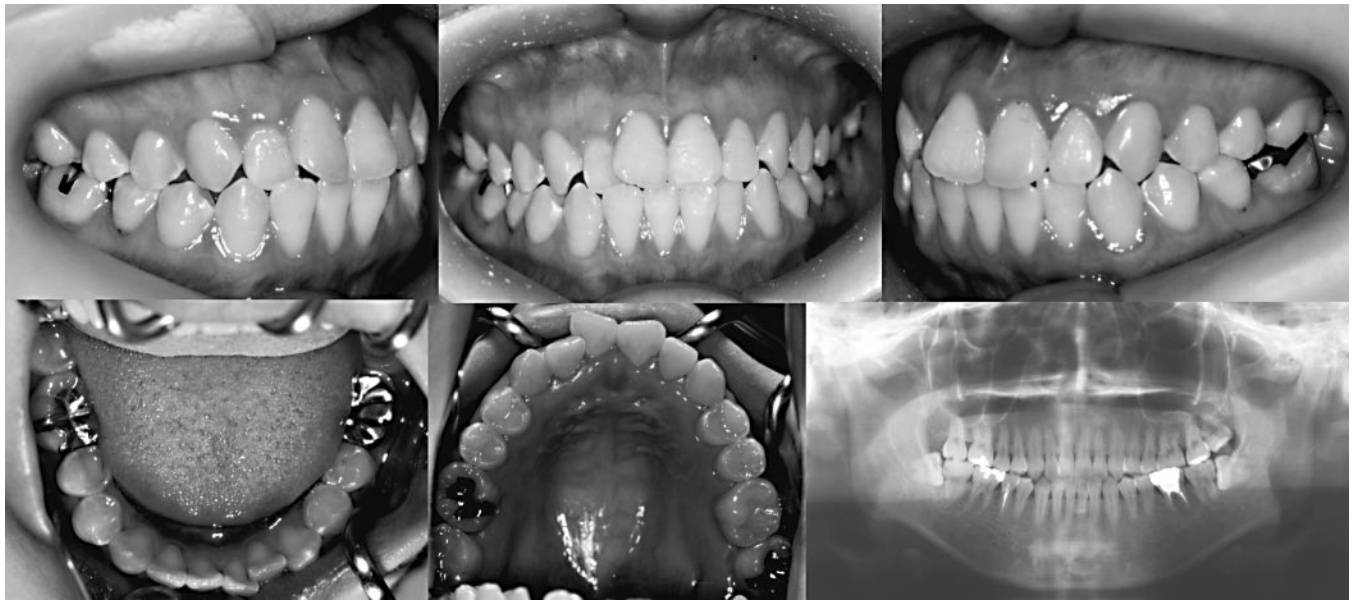


FIGURE 2. Initial intraoral photographs and panoramic radiograph. Panoramic radiograph was taken after initial treatment of dental caries and restorations.

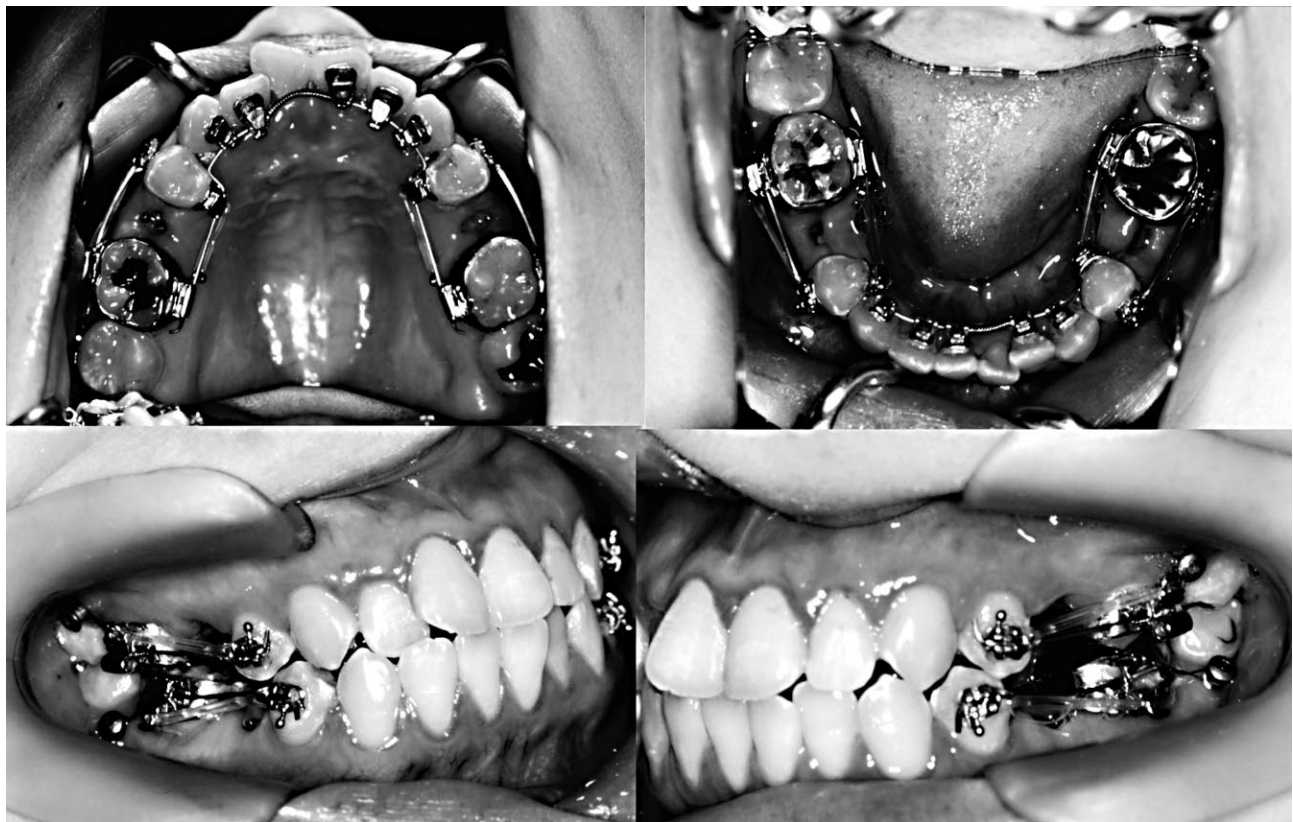


FIGURE 3. Intraoral photographs after engaging the initial wires. Anchorage reinforcement was performed with ligation of the titanium screws to the first molar hook.

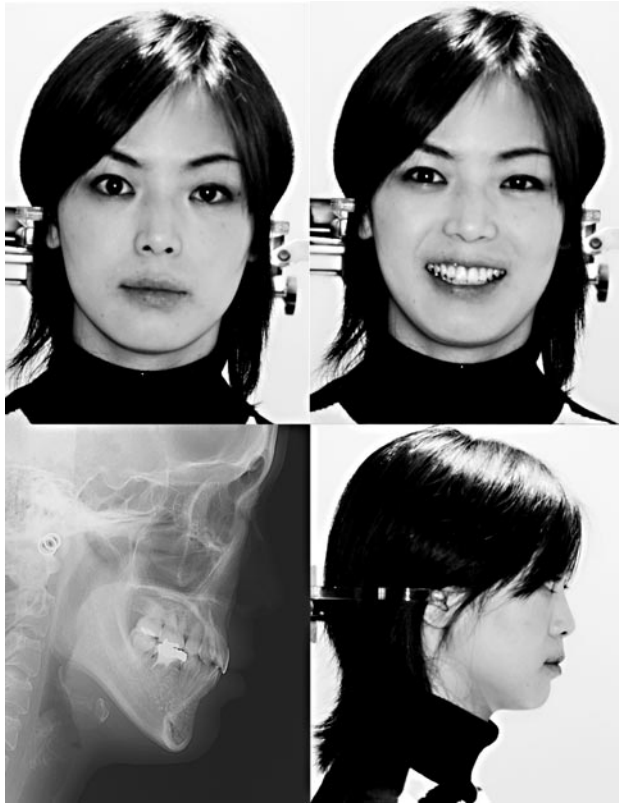

FIGURE 4. Facial photographs and the lateral cephalogram after active treatment.

vantages of easy surgical placement and osteointegration not required, only a short fixation period is needed after the screws are placed.^{5,6} However, few reports have been published regarding lingual orthodontics combined with titanium screw anchorage. The present case demonstrates a

TABLE 1. Cephalometric Analysis

	Initial (22 y and 5 mo)	Posttreatment (25 y and 10 mo)	Mean
SNA (°)	79.8	79.0	80.8
SNB (°)	78.3	78.0	77.9
ANB (°)	1.5	1.0	2.8
Mand.pl to FH (°)	33.4	33.8	30.5
Mx 1 to FH (°)	118.6	107.1	105.9
IMPA (°)	98.6	90.6	93.4
Interincisal angle (°)	106.9	130.1	123.6
Overjet (mm)	1.9	1.6	2.5
Overbite (mm)	-1.2	0.3	2.5

safe and effective method for controlling anchorage with buccally implanted titanium screws and a lingual multi-bracket appliance.

Diagnosis and treatment planning

A 22-year-old woman presented with a chief complaint of irregularly aligned and protruding anterior teeth. A review of her medical history revealed no allergies or medical problems, and no signs or symptoms of temporomandibular dysfunction were noted at the initial examination. The patient had a convex profile and bialveolar protrusion (Figure 1), and the molar relationships were Class I with moderately crowded anterior teeth. The lower dental midline was deviated two mm to the left because of mild crowding at the incisors. Further, both upper and lower anterior incisors displayed severe protrusion with a small interincisal angle (106.9°) (Figure 2).

A lateral cephalometric analysis revealed a normal skeletal relationship with an ANB angle of 1.5° and a steep mandibular plane angle (FMA) of 33.4° (Figure 1).

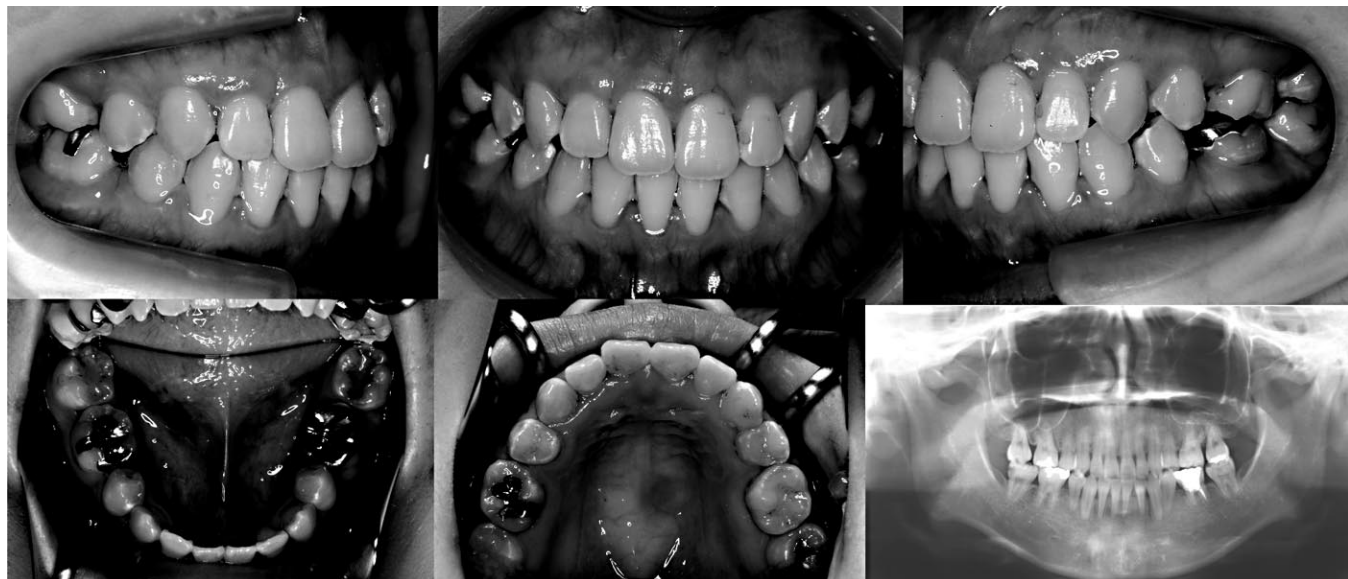

FIGURE 5. Intraoral photographs and panoramic radiographs after active treatment.

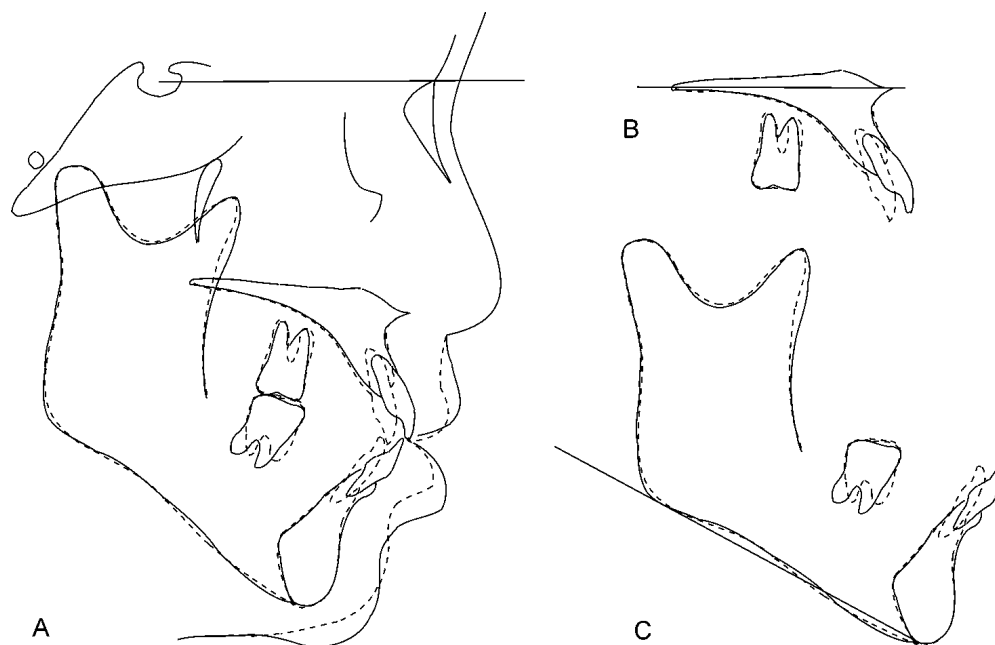


FIGURE 6. Superimposition of cephalometric tracings before (solid line) and after (dotted line) treatment. (A) Registered on the SN plane at S. (B) Registered on the palatal plane at ANS. (C) Registered on the mandibular plane at Me.

The patient expressed a desire for an invisible appliance and wanted to avoid wearing headgear because of esthetic and social concerns. She also liked the temporary spaces to be seen as little as possible after the extraction of the bicuspids. Thus, the treatment plan involved extraction of both upper and lower second premolars (lower right previously treated with a root canal filling), followed by lingual orthodontic treatment with maxillary and mandibular micro-implants for absolute anchorage.

Treatment objectives

- Retraction of both upper and lower incisors, and leveling and alignment of the dental arches.
- Establishment of ideal occlusion with Class I molar relationship.
- Reduce upper lip protrusion and improve the soft tissue profile.

Treatment progress

Titanium screws (1.5 mm in diameter, 15 mm in length, Martin Medizin-Technik Gebrüder-Martin GmbH, Tuttlingen, Germany) were implanted into the upper and lower alveolar bones between the first and second molars under local anesthesia. To avoid the root damage, the screws were placed in the interseptal areas of the molars. Two months after implantation, the upper and lower second premolars were extracted and leveling was initiated using a fixed lingual orthodontic appliance (Kurz appliance 7th generation, Ormco Co Glendora, CA, USA). Force application for retraction of the anterior teeth was performed with reinforced

anchorage using ligation of the titanium screws to the first molar hook with an elastic thread (Figure 3).

After retraction of the anterior teeth for 12 months, all implant screws were removed. The lingual orthodontic treatment was completed, and the use of upper and lower removable retainers was started when the patient was 25 years and 10 months old. The active treatment including the implant placement lasted 29 months. Profile improvement and marked retraction of the anterior teeth were achieved.

RESULTS

The patient showed good occlusion, and her facial profile was improved with retraction of the upper and lower lips (Figure 4). The dental arches were aligned and leveled, and ideal overbite and overjet were established (Figure 5). A panoramic radiograph showed no radiolucent layers or any forms of inflammation in the alveolar bone. Cephalometric superimposition showed a lingual inclination of the upper incisors, with a decrease of Mx 1 to FH from 118.6° to 107.1° . The proclined lower incisors were uprighted from 98.6° to 90.6° (IMPA), and the interincisal angle increased from 106.9° to 130.1° (Table 1). The upper molars showed little anchorage loss, whereas the mandibular molars were uprighted and slightly intruded (Figure 6).

DISCUSSION

A lingual orthodontic technique enables an esthetically pleasing appearance along with an invisible treatment; however, just as with labial treatment, the anchorage requirement is critical. En masse retraction of the six anterior teeth

requires stationary or absolute anchorage and acceptance of conventional intra- or extraoral reinforcement such as the use of a headgear. However, adult patients who require the lingual appliance often reject use of the headgear because of social and esthetic concerns,⁶ and this can result in anchorage loss and unsatisfactory treatment results. The introduction of temporary implants as an alternative to orthodontic anchorage can resolve this problem. We considered that lingual treatment combined with implant anchorage would provide reliable and comfortable results for the patients who request invisible treatment today.

Implant placement and orientation are important when attempting to establish stationary anchorage. The titanium screw implants must be placed in adequate bone in the palate or mandible and avoid tongue movement and damage to the roots, as well as damage to the major arteries and neuromuscular bundle. By carefully considering these issues during implant planning, an understanding of skeletal anatomy and muscle movement will permit placement of the implants in a few regions. In the present case, the titanium screws were implanted in the buccal alveolar bone of the maxilla and mandible where they remained invisible and sufficient bone thickness was available for stable anchorage.^{4,5} This region was easily accessible for the surgical procedure and is well tolerated by patients as compared with the palatal area. A recent study showed that failure of implanted screws is associated with a small-diameter screw, inflammation of peri-implant tissue, and a high mandibular plane angle, ie, thin cortical bone.⁵

The present treatment procedure can be criticized for necessitating surgery for a transient implant. However, the operation is simplified by elimination of the incision, flap

raising, and suture because conventional implant surgery requires a full-thickness flap. Our patient easily accepted the surgery, and the postoperative pain and discomfort symptoms were almost negligible. In addition, there was little risk in allowing the implant to heal transmucosally. During active retraction of the anterior teeth, we did not find any loosening of the implants, and peri-implant soft tissue conditions were favorable.

Current orthodontic treatment demands minimum treatment time and minimum patient cooperation while offering maximum treatment efficiency. We concluded that lingual orthodontics is an excellent system for invisible treatment in an adult patient and that implant anchorage with titanium screws can be used for efficient anchorage maintenance with anterior retraction procedures.

REFERENCES

1. Lee JS, Park HS, Kyung HM. Micro-implant anchorage for lingual treatment of a skeletal Class II malocclusion. *J Clin Orthod.* 2001;35:643–647.
2. Park HS, Bae SM, Kyung HM, Sung JH. Micro-implant anchorage for treatment of skeletal Class I bialveolar protrusion. *J Clin Orthod.* 2001;35:417–422.
3. Costa A, Raffini M, Melsen B. Micro-screws as orthodontic anchorage. *Int J Adult Orthod Orthognath Surg.* 1998;13:201–209.
4. Koyama I, Miyawaki S, Takano-Yamamoto T. Application of titanium screws in orthodontic treatment. *Orthod Waves.* 2001;60:313–318.
5. Miyawaki S, Koyama I, Inoue M, Mishima K, Sugawara T, Takano-Yamamoto T. Factors associated with the stability of titanium screws placed in the posterior region of orthodontic anchorage. *Am J Orthod Dentofacial Orthop.* 2003;124:373–378.
6. Deguchi T, Takano-Yamamoto T, Kanomi R, Hartsfield JK, Roberts WE, Garetto LP. The use of small titanium screws for orthodontic anchorage. *J Dent Res.* 2003;82:377–381.