

Lever-arm and Mini-implant System for Anterior Torque Control during Retraction in Lingual Orthodontic Treatment

Ryoon-Ki Hong, DDS, PHD^a; Jung-Min Heo, DDS^b; Young-Ki Ha, DDS^b

Abstract: Anterior torque control during retraction is difficult to achieve with lingual orthodontic treatment. This article describes the use of a lever-arm and mini-implant system as absolute anchorage for controlled retraction of the anterior teeth during lingual orthodontic treatment and evaluates 2 protrusion cases treated with this system. Various clinical situations are discussed and analyzed from a biomechanical standpoint. Mini-implants are needed to control the point of force application in the posterior area and produce en masse retraction with no anchorage loss. When the length of the lever-arm is adjusted to the position of the mini-implant, the desired line of action of the retraction force with respect to the center of resistance of the anterior segment is selected. Controlled retraction of the anterior teeth was achieved with no loss of anchorage. The mini-implant, in conjunction with the lever-arm, is useful not only for absolute anchorage but also for anterior torque control during retraction in lingual orthodontic treatment. (*Angle Orthod* 2004;75:129–141.)

Key Words: Controlled retraction, Absolute anchorage, Line of action of the retraction force, Center of resistance

INTRODUCTION

Correct positioning of the maxillary and mandibular incisors is essential for function, stability, and esthetics.¹⁻⁴ Retraction of the incisors, therefore, represents a fundamental and often critical stage in orthodontic treatment. The resultant movement of the incisors depends on the tissue reaction produced by the applied biomechanical force system.

In lingual orthodontic treatment, one of the most difficult problems to overcome has been torque control of the anterior teeth during space closure (Figure 1).^{5,6} Anterior torque control is achieved either by directly applying a moment and force to a lingual bracket or by using lever-arm mechanics to obtain the desired line of action of the force with respect to the center of resistance.⁷⁻⁹

In the lever-arm system, the desired tooth movement is attained by adjusting the length of the lever-arm and the point of force application. With labial appliances, the ex-

isting oral anatomy may prevent ideal placement of the lever-arm system, but with lingual appliances, the lever-arm system can always be ideally located because of the width and depth of the palate. Therefore, lingual lever-arm me-

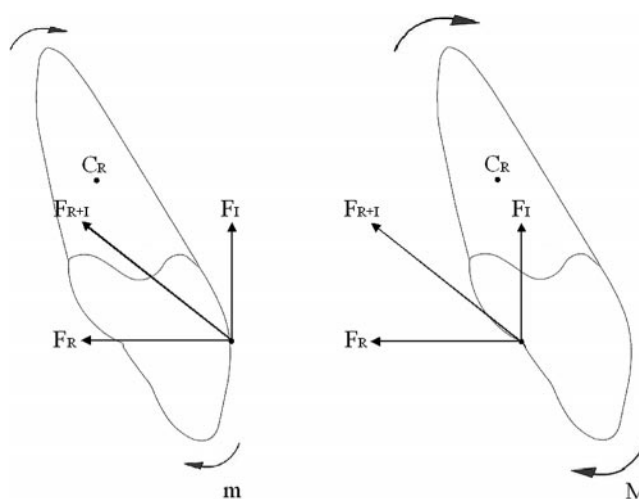


FIGURE 1. The effect of bracket position and location of the point of force application on tooth movement. When the same amount of retraction and intrusion forces is applied to the incisors in labial and lingual systems, the resultant force in the lingual system is pointed further away from the center of resistance of the incisors compared with the labial system. The net force in the lingual system will produce a larger moment to tip the incisors lingually than in the labial system. C_R indicates center of resistance; F_R , retraction force; F_I , intrusion force; F_{R+I} , resultant force; m and M , moment.

^a Chairman, Department of Orthodontics, Chong-A Dental Hospital, Seoul, South Korea.

^b Resident, Department of Orthodontics, Chong-A Dental Hospital, Seoul, South Korea.

Corresponding author: Ryoon-Ki Hong, DDS, PHD, Department of Orthodontics, Chong-A Dental Hospital, #648-22 Yoksam-Dong, Gangnam-Gu, Seoul 135-080, South Korea (e-mail: kloa@kloa.co.kr).

Accepted: February 2004. Submitted: November 2003.

© 2004 by The EH Angle Education and Research Foundation, Inc.

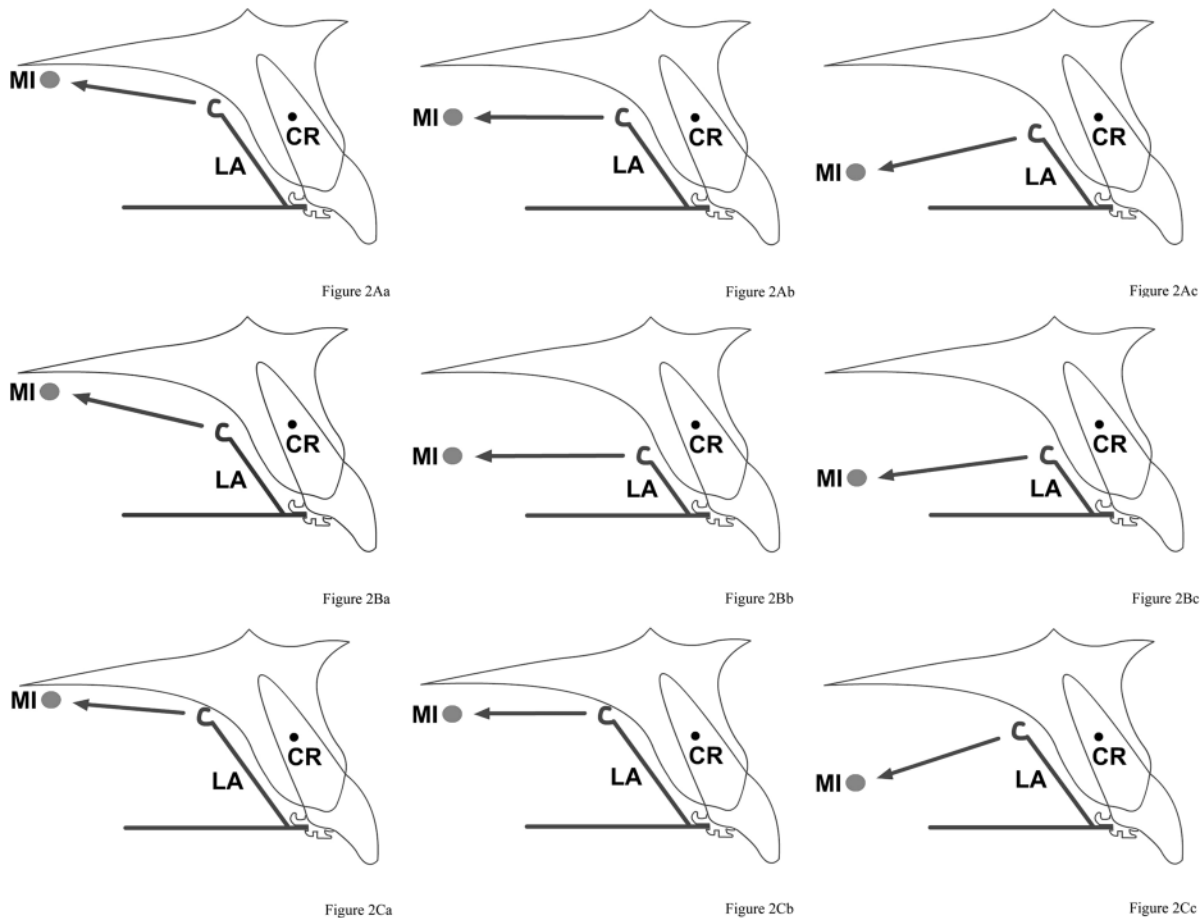


FIGURE 2. Analysis of the reaction of the anterior teeth to different applications of the line of action of the retraction force. In all cases, a 0.018 × 0.018-inch stainless steel mushroom archwire is placed from first molar to first molar in the upper arch, and 0.9 mm stainless steel lever-arms are soldered onto the mushroom archwire between the lateral incisors and canines. The desired line of action of the retraction force with respect to the center of resistance of the anterior segment is established by adjusting the length of the lever-arm and the position of the mini-implant. The tendency toward translation or tipping and simultaneous extrusion or intrusion of the anterior teeth during retraction will be determined by the direction of the retraction force. LA indicates lever-arm; MI, mini-implant; and CR, center of resistance of the anterior teeth. (A) Force system for bodily movement of the anterior teeth: a, the anterior teeth will retract bodily and intrusively; b, the anterior teeth will retract bodily; c, the anterior teeth will retract bodily and extrusively. (B) Force system for distal crown movement of the anterior teeth: a, the crown of the anterior teeth will move distally and intrusively; b, the crown of the anterior teeth will move distally and extrusively. (C) Force system for distal root movement of the anterior teeth: a, the root of the anterior teeth will move distally and intrusively; b, the root of the anterior teeth will move distally; c, the root of the anterior teeth will move distally and extrusively.

chanics can be effective in achieving any desired tooth movement.

Various types of dental implants including micro- or miniscrews,¹⁰⁻¹⁵ miniplates,^{16,17} endosseous implants,¹⁸⁻²¹ and disc-shaped onplants²² have all been tested for anchorage in orthodontics. Micro- or miniscrews have advantages over miniplates, cylindrical endosseous implants, and disc-shaped onplants because of the ease of selecting proper implant sites, ease of insertion in any desired location, ability to withstand immediate force loading, and minimal irritation of the oral tissues.

The purpose of this study is to describe the lever-arm and mini-implant system as absolute anchorage for controlled retraction of the anterior teeth in lingual orthodontic

treatment and to demonstrate the effectiveness of this system using clinical examples.

LEVER-ARM AND MINI-IMPLANT SYSTEM

Biomechanics

A number of different clinical situations may arise and should be thoroughly analyzed from a biomechanical standpoint to determine the correct force system necessary to achieve the treatment objectives.

To design the optimal lever-arm and mini-implant system for obtaining the desired force system during retraction, the point of force application and the line of action of the retraction force are planned using lateral cephalograms. By

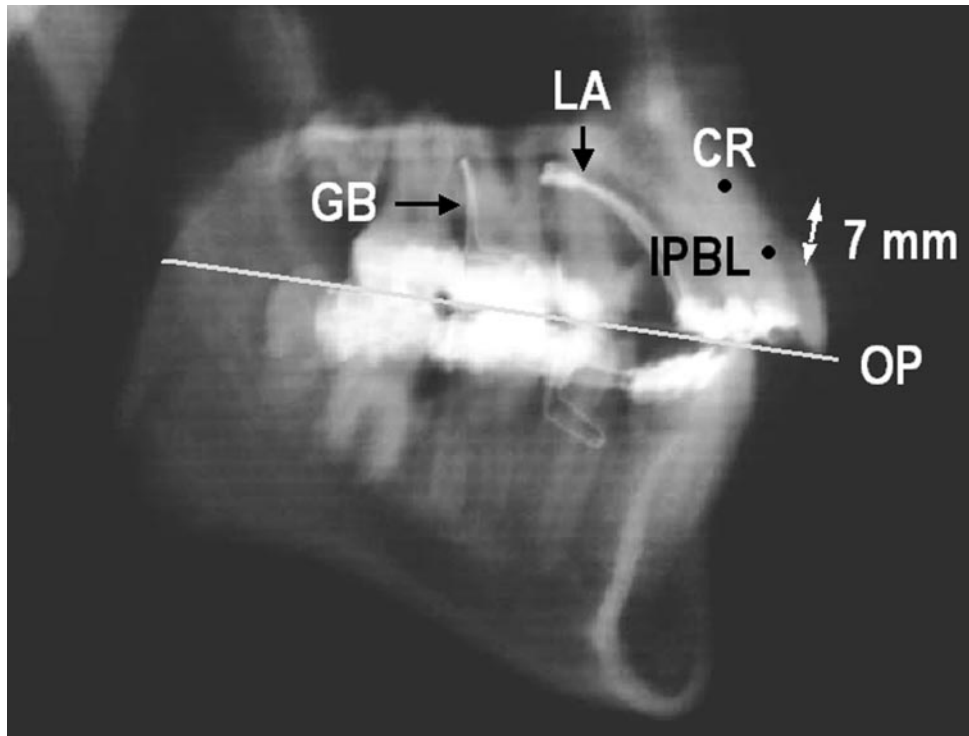


FIGURE 3. According to clinical situations, the length of the lever-arm and the position of the mini-implant are determined on the lateral cephalogram. OP indicates occlusal plane; IPBL, interproximal bone level between the central incisors; CR, center of resistance of the 6 anterior teeth; LA, lever-arm; and GB, guide bar.

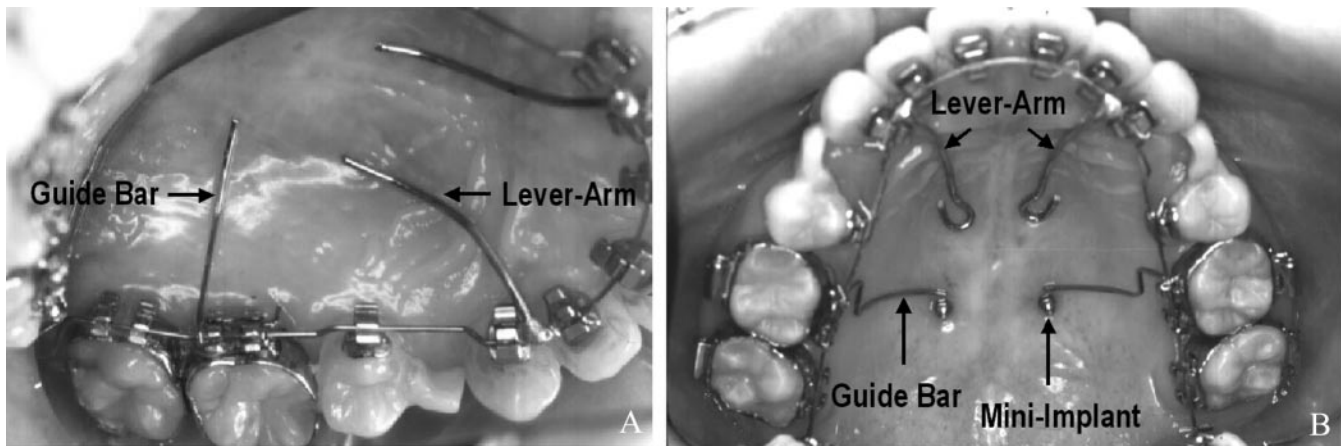


FIGURE 4. Intraoral photographs before (A) and after (B) establishing a lever-arm and mini-implant system.

adjusting the length of the lever-arm and the position of the mini-implant, the desired line of action of the retraction force with respect to the center of resistance of the anterior segment is established.

The models in Figure 2 indicate the overall reaction that can be expected in an average clinical application. A retraction force parallel to the occlusal plane and applied through the center of resistance of the anterior teeth will bodily retract the anterior segment (Figure 2Ab). In clinical situations where the retraction is to be performed by translation and simultaneous intrusion, the retraction force is re-

directed through the center of resistance of the anterior teeth as shown in Figure 2Aa. Figure 2Ac shows a configuration that will result in translation and simultaneous extrusion.

The tendency toward lingual crown or lingual root movement of the anterior teeth will be determined by the direction of the retraction force and notably by the rotational effects derived from the relation of the line of action of the retraction force relative to the center of resistance (Figure 2B,C). The correct design of the lever-arm and mini-implant system is chosen after careful analysis of the clinical situation.

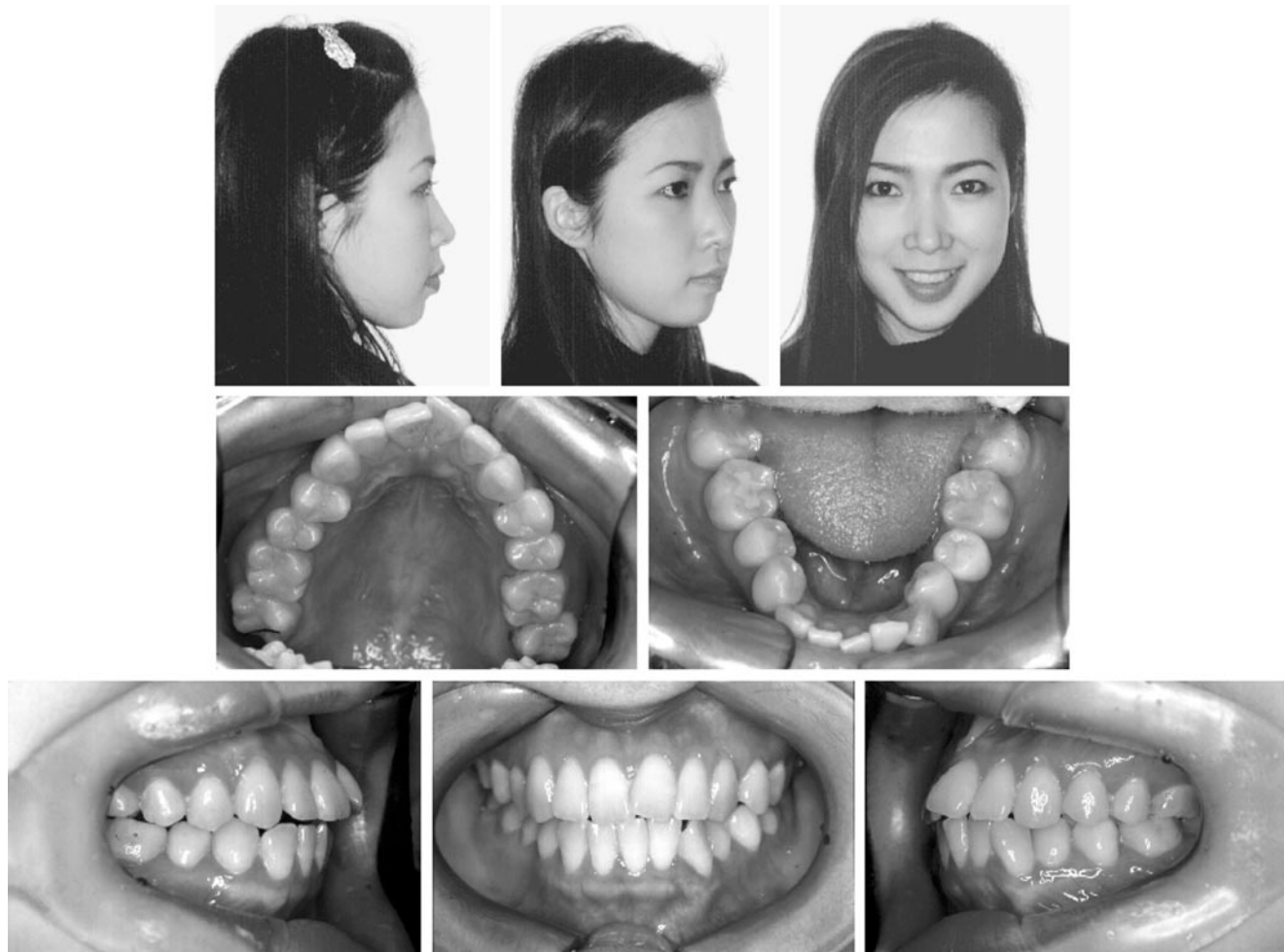

FIGURE 5. Pretreatment facial and intraoral photographs.

TABLE 1. Cephalometric Summary

Measurement	Norms	Pretreatment	Before Retraction	Posttreatment
Skeletal				
SNA (°)	82.3	88.0	88.3	88.1
SNB (°)	78.9	83.6	83.7	83.2
ANB (°)	3.4	4.4	4.6	4.8
FMA (°)	28.8	35.6	35.9	35.5
NPo-FH (°)	84.8	89.4	89.7	89.7
Dental				
Overbite (mm)	2.3	1.0	1.9	2.7
Overjet (mm)	3.2	5.0	5.0	4.5
1-FH (°)	111.3	124.3	114.0	109.2
FMIA (°)	59.8	53.5	61.7	68.0
Interincisal (°)	124.1	109.2	127.7	138.8
Is-Is' (mm) ^a	31.9	28.5	30.0	28.2
Soft tissue				
Upper lip to E-line (mm)	-0.9	4.0	4.8	2.3
Lower lip to E-line (mm)	0.6	5.5	5.2	0.1

^a Is-Is', indicates upper incisor dental height.

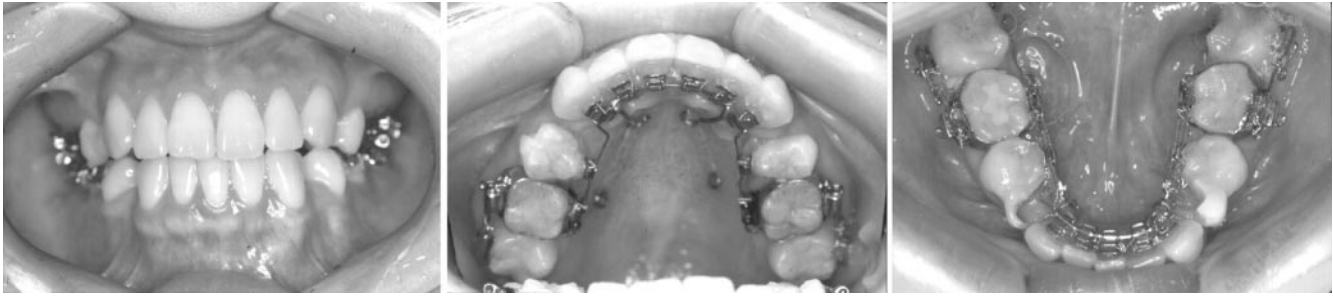

FIGURE 6. For en masse retraction, lever-arm and mini-implant system established in upper arch and 0.018 × 0.018-inch stainless steel closing-loop mushroom archwire placed in lower arch.

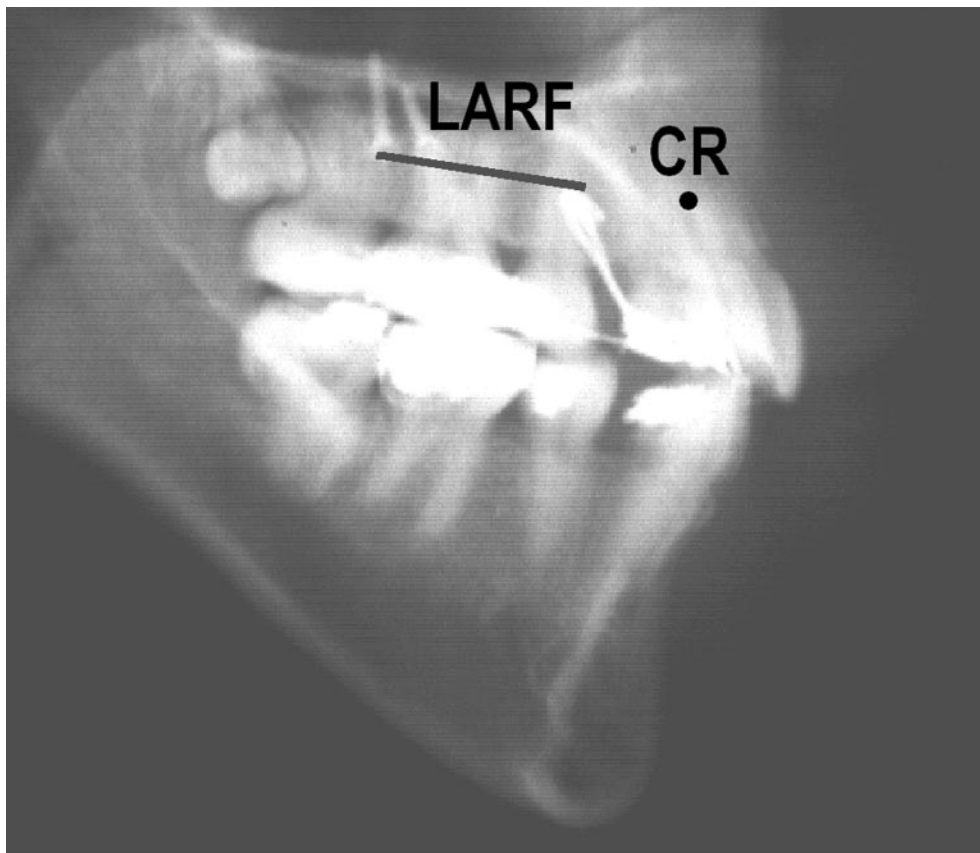


FIGURE 7. Lateral cephalogram taken after establishing a lever-arm and mini-implant system in case 1. The line of action of the retraction force (LARF) passes through the center of resistance of the 6 anterior teeth (CR) and is parallel to the occlusal plane. In this case, bodily retraction of the anterior teeth will be expected.

Determination of the length of the lever-arm and the position of the mini-implant

The center of resistance of the unit to be moved is the basic point for the arrangement of a force system. Vanden Bulcke et al²³ have concluded that the instantaneous center of resistance for the 6 anterior teeth was located at 7.0 mm apical to the interproximal bone level between the central incisors (measured perpendicular to the occlusal plane).

Using the location of the center of resistance for the 6 anterior teeth defined by Vanden Bulcke et al, the length

of the lever-arm and the position of the mini-implant are determined on the lateral cephalogram before retraction (Figure 3). A lever-arm, made of 0.9 mm stainless steel wire, is soldered onto the mushroom archwire between the lateral incisors and canines and the fitting lever-arm length is determined. The proper insertion site of the mini-implant is measured from a guide bar made of 0.018 × 0.018-inch stainless steel wire and engaged in the molar bracket. The mini-implants are inserted under local anesthesia directly through the mucosa without any flap dissection. The fitting implant length is determined by assessing the thickness of

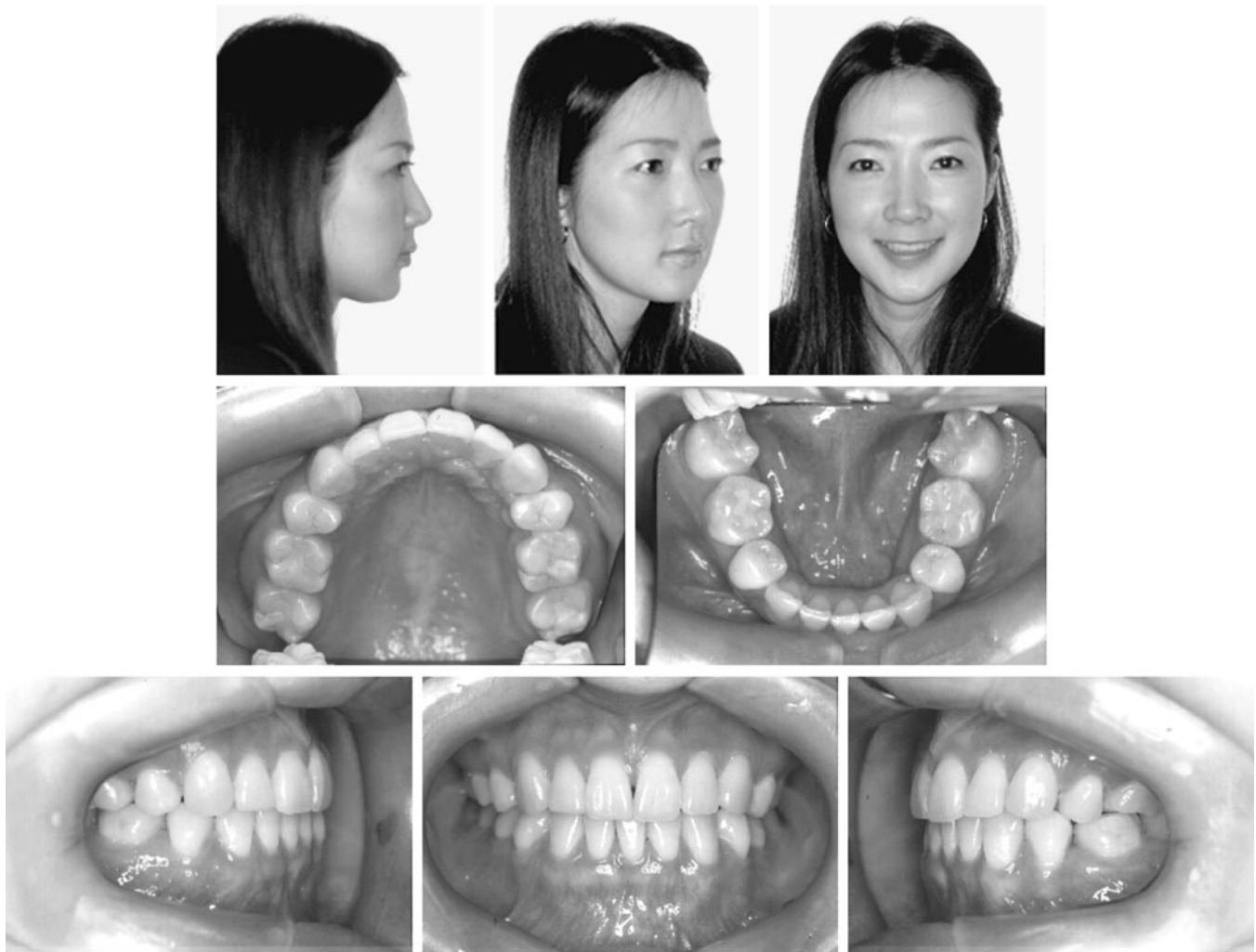

FIGURE 8. Posttreatment facial and intraoral photographs.

the palatal soft tissue and the available bone quantity at the desired implantation site. The mini-implant is inserted manually with a screwdriver. Then, the desired lever-arm and mini-implant system is completed (Figure 4).

APPLICATION OF LEVER-ARM AND MINI-IMPLANT SYSTEM

Case 1

A 25-year-old Korean female presented with the chief complaint of lip protrusion. The patient exhibited a convex profile and a super Class I molar relationship with a missing mandibular right lateral incisor (Figure 5).

Cephalometric analysis disclosed a Class I skeletal relationship and a dolichofacial pattern, as evidenced by an FMA angle of 35.6° (Table 1). The upper and lower first premolars were selected to be extracted.

Treatment progress. Except for the lower left canine, Fujita lingual brackets were placed indirectly from first molar to first molar in both arches^{24,25} and 0.018-inch slot standard

edgewise appliances were placed on the buccal of the first and second molars. A progression through mushroom archwires was initiated starting with 0.012-inch nickel titanium. Twelve months into treatment, 0.018×0.018 -inch stainless steel closing mushroom archwires were placed in the occlusal slots of both arches to begin en masse retraction (Figure 6).

At this point, a progress lateral cephalogram was exposed to evaluate the anterior tooth movement during retraction. Cephalometric evaluation revealed that the inclination of both upper and lower incisors was within normal limits (Table 1). For the upper arch, the lever-arm and mini-implant system was designed to achieve bodily retraction of the anterior teeth without anchorage loss (Figure 7), and a lingual root torque bend was placed in the anterior part of lower closing-loop mushroom archwire to achieve bodily retraction of the anterior teeth with some anchorage loss. The appliances and the mini-implants were removed 30 months after the start of treatment.

Results. The lip protrusion was improved and a favorable

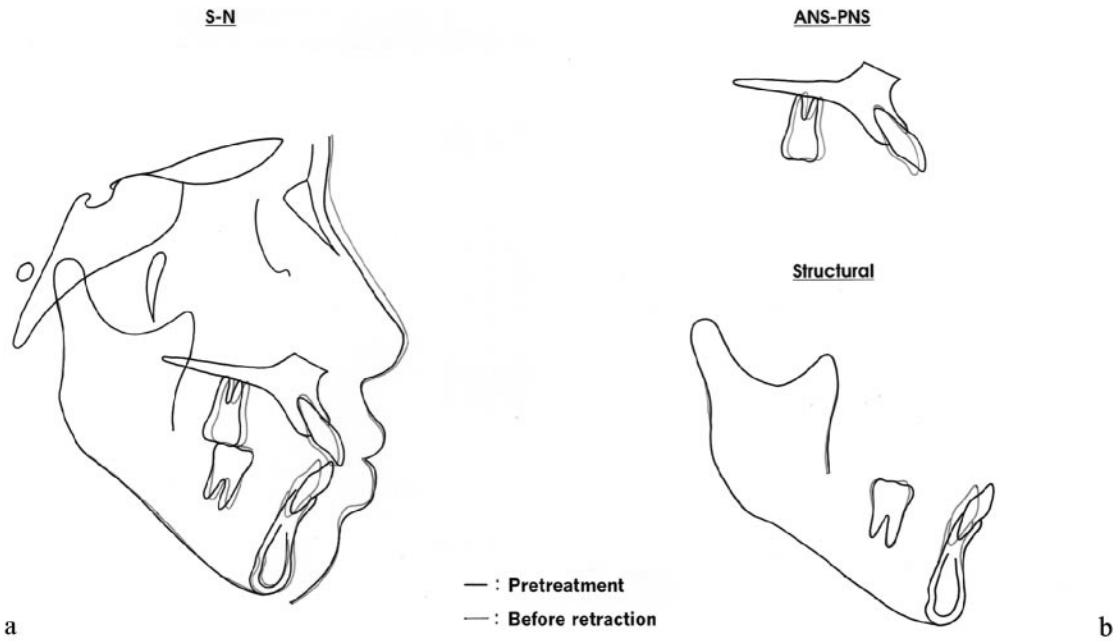


Figure 9A

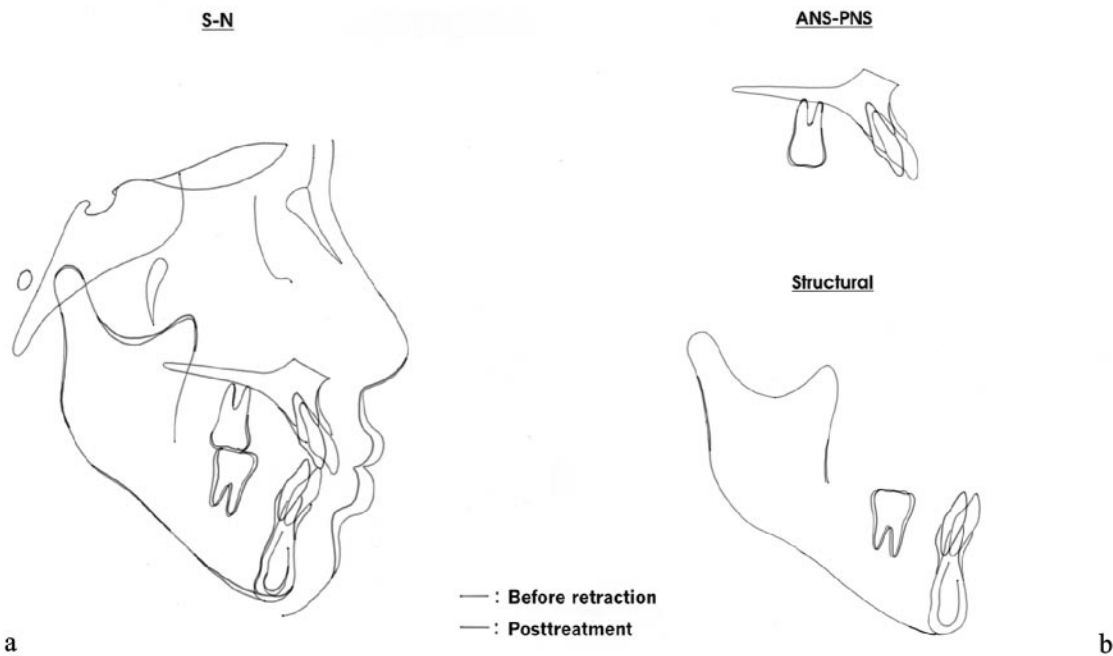


Figure 9B

FIGURE 9. (A) Superimposition of cephalometric tracings before treatment and retraction: a, overall superimposition shows no downward and backward rotation of the mandible and augmentation of the nose. It seems that augmentation rhinoplasty was performed; b, in regional superimpositions, the upper and lower incisors were uprighted. The upper molars moved mesially and the lower molars were slightly uprighted. (B) Superimposition of cephalometric tracings before and after retraction: a, overall superimposition shows an improvement in lip relations, with favorable lingual retrusion; b, in regional superimpositions, the upper incisors were retracted bodily and intrusively and the lower incisors were bodily retracted. The upper molars did not move mesially at all and the lower molars slightly moved mesially.

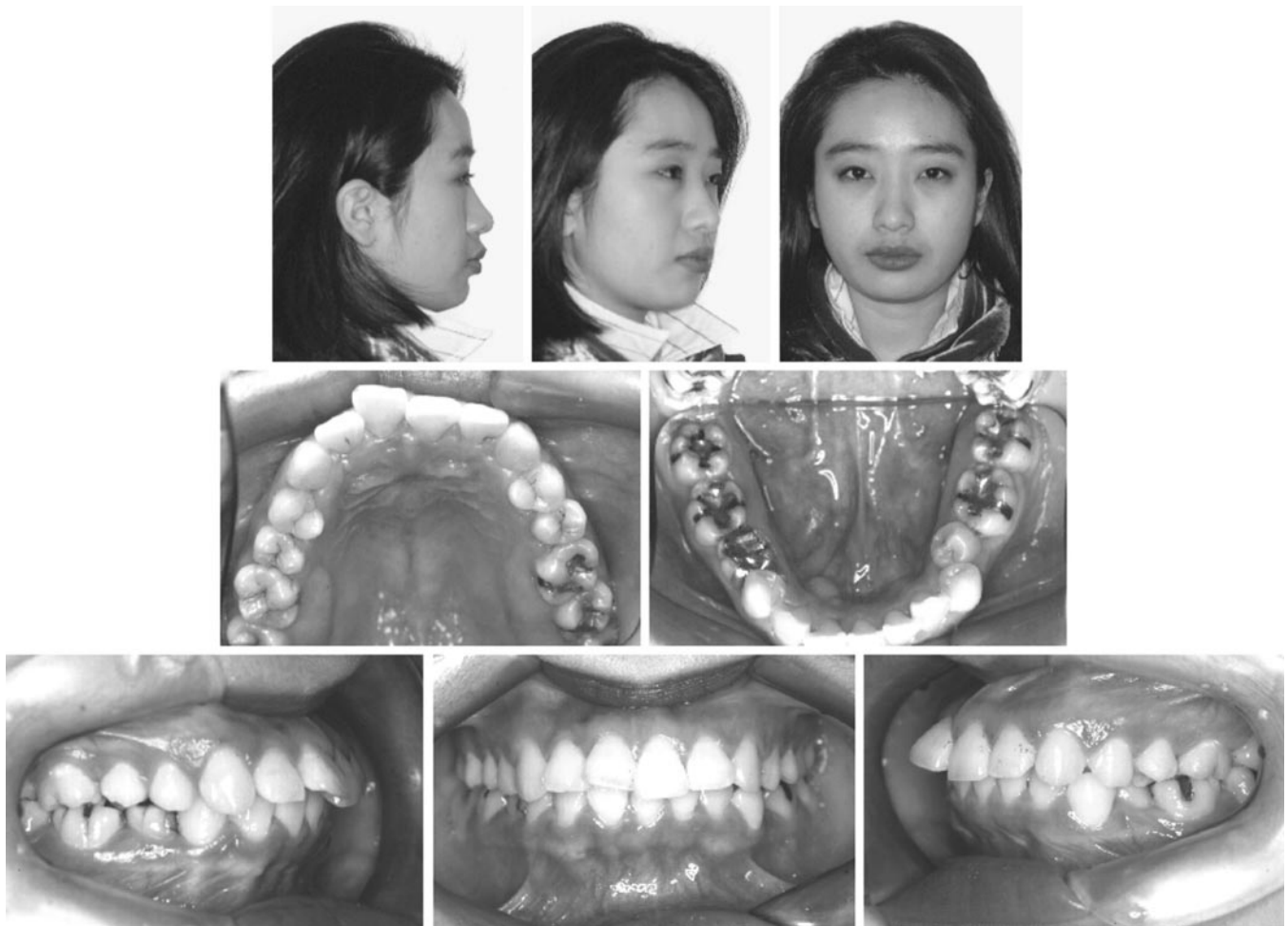

FIGURE 10. Pretreatment facial and intraoral photographs.

TABLE 2. Cephalometric Summary

Measurement	Norms	Pretreatment	Before Retraction	Posttreatment
Skeletal				
SNA (°)	82.3	80.4	80.3	79.5
SNB (°)	78.9	76.8	75.8	76.1
ANB (°)	3.4	3.6	4.5	3.4
FMA (°)	28.8	21.1	22.0	20.7
NPo-FH (°)	84.8	89.9	89.2	89.5
Dental				
Overbite (mm)	2.3	4.2	0.9	1.0
Overjet (mm)	3.2	5.7	8.6	2.4
1-FH (°)	111.3	123.6	123.3	111.4
\bar{F} MIA (°)	59.8	57.5	56.2	53.5
Interincisal (°)	124.1	113.9	112.9	122.2
Is-Is' (mm) ^a	31.9	29.8	30.6	29.3
Soft tissue				
Upper lip to E-line (mm)	-0.9	4.4	4.4	2.3
Lower lip to E-line (mm)	0.6	4.9	4.7	2.3

^a Is-Is', indicates upper incisor dental height.

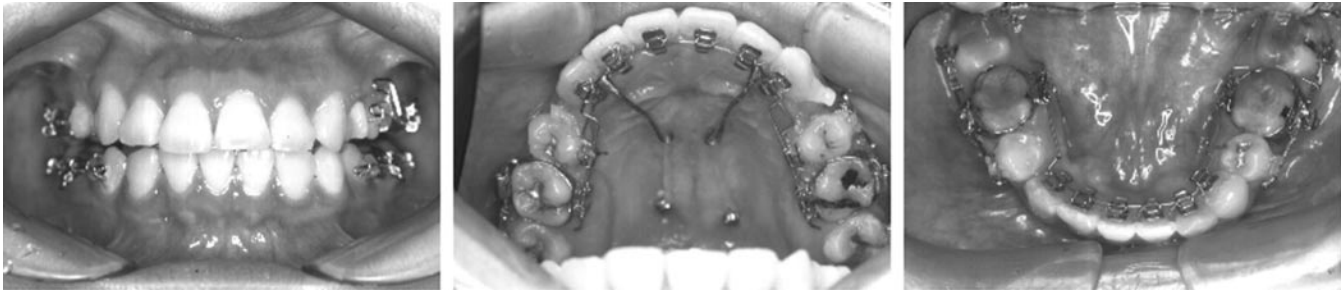

FIGURE 11. For en masse retraction, lever-arm and mini-implant system established in upper arch.

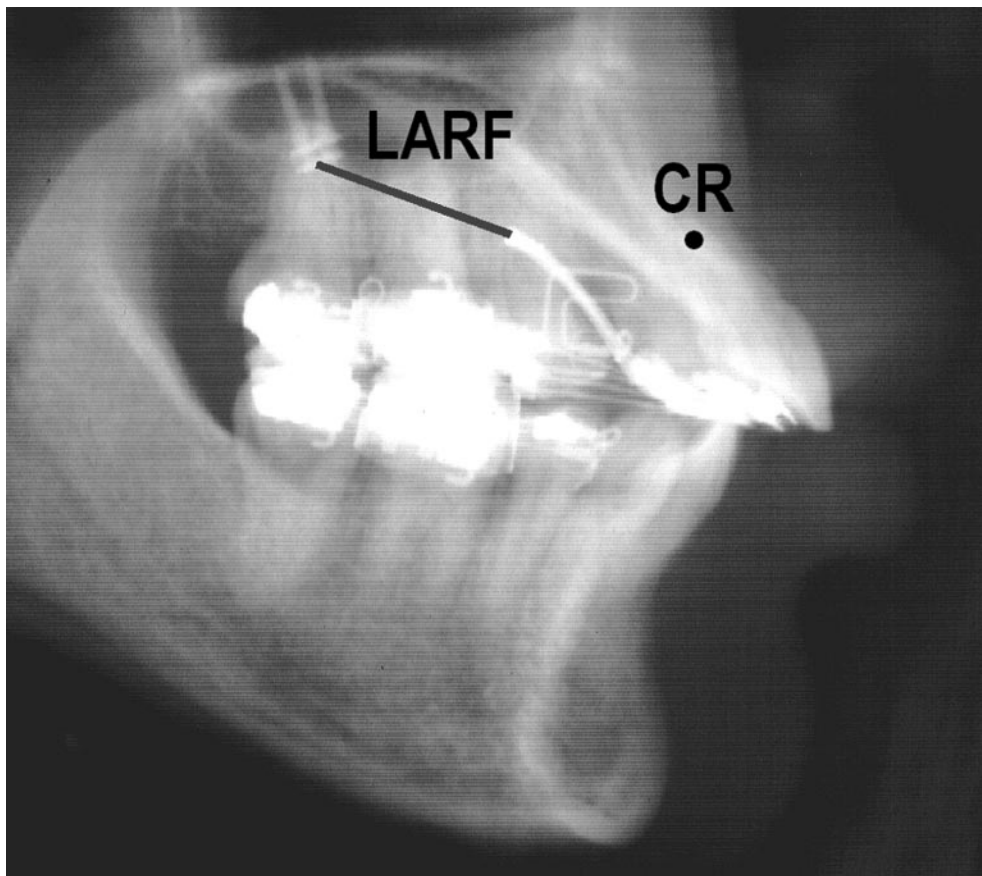


FIGURE 12. Lateral cephalogram taken after establishing a lever-arm and mini-implant system in case 2. The line of action of the retraction force (LARF) passes inferior to the center of resistance of the 6 anterior teeth (CR). Intrusive tipping retraction of the anterior teeth is expected with this configuration.

interdigitation with a super Class I molar relationship was achieved (Figure 8). Figure 9 shows superimpositions of the cephalometric tracings demonstrating the tooth movement and skeletodental changes as follows:

During alignment and leveling

- uprighting of the upper and lower incisors;
- mesial movement of the upper molars as a result of partial canine retraction;
- slight uprighting of the lower molars.

During retraction

- intrusive bodily movement of the upper incisors;
- bodily movement of the lower incisors;
- no mesial movement of the upper molars;
- slight mesial movement of the lower molars;
- favorable lingual retrusion of the upper and lower lips.

Cephalometric measurements (Table 1) indicate that during retraction, the axial inclination and the dental height of the upper incisors decreased 4.8° and 1.8 mm, respectively.

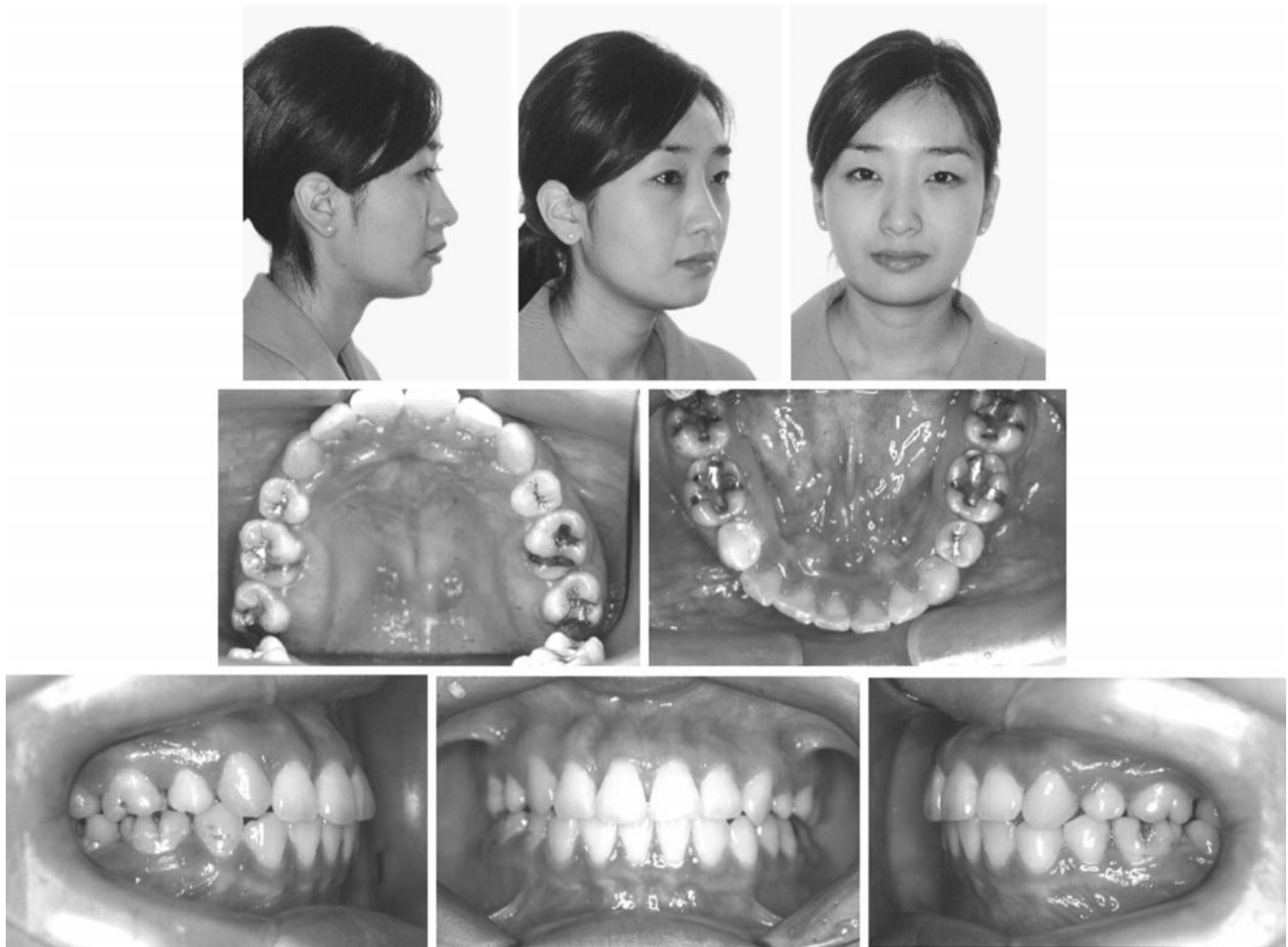

FIGURE 13. Posttreatment facial and intraoral photographs.

Case 2

Case 2 demonstrates a 22-year-old Korean female who complained of lip protrusion and crowding. The patient had a skeletal Class I malocclusion. The mandibular permanent left lateral incisor and right second premolar were missing, and the mandibular primary right second molar was retained (Figure 10).

Cephalometric analysis (Table 2) shows that the antero-posterior skeletal measurements were generally within normal limits and the facial pattern was brachyfacial. The upper first premolars and the lower prolonged retained deciduous molar were selected to be extracted.

Treatment progress. In the initial stage, upper anterior lingual brackets interfered with the lower incisors when the patient was in occlusion, causing a posterior open bite. To avoid this interference, the lower arch was indirectly bonded and banded first. Progression through mushroom archwires was initiated in the lower arch, starting with 0.012-inch nickel titanium. After bite opening by intrusion of the lower anterior teeth, Fujita lingual brackets were placed indirectly from upper right first molar to upper left first molar.

A progress lateral cephalogram was exposed 18 months into treatment to evaluate the anterior tooth movement during retraction. This revealed that the inclination of the upper incisors was protrusive (Table 2). Therefore, the lever-arm and mini-implant system for the upper arch was designed to achieve intrusive tipping retraction of the anterior teeth without anchorage loss (Figures 11 and 12). The appliances and the mini-implants were removed 33 months after the start of treatment.

Results. After lingual orthodontic treatment with lever-arm and mini-implant system, the patient's convex profile was favorably improved (Figure 13). The teeth were well aligned, and a satisfactory occlusion was achieved. Superimpositions of cephalometric tracings (Figure 14) show the tooth movement and skeletodental changes as follows:

During alignment and leveling

- slight uprighting of the upper incisors;
- significant intrusion of the lower incisors;
- slight extrusion and mesial movement of the upper and lower molars;

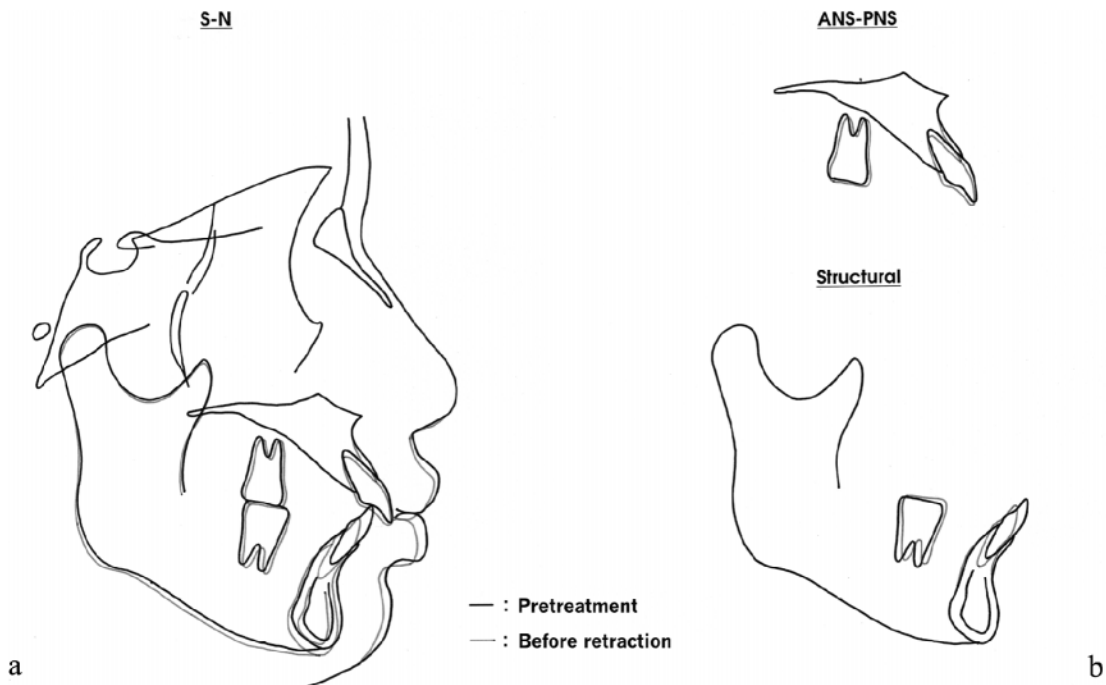


Figure 14A

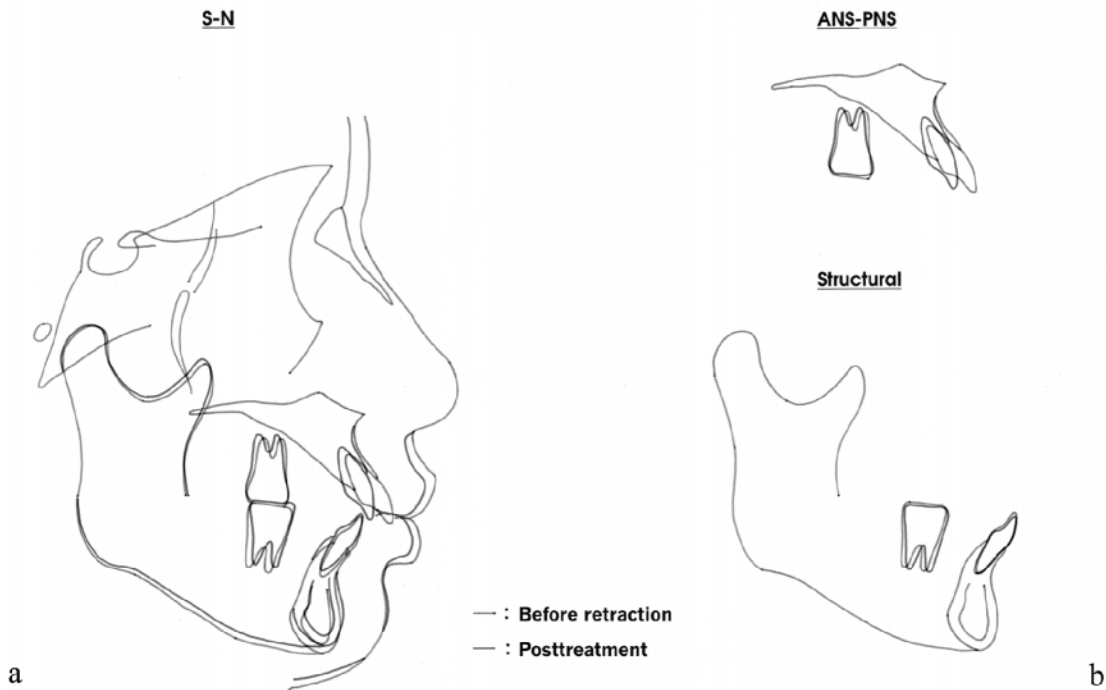


Figure 14B

FIGURE 14. (A) Superimposition of cephalometric tracings before treatment and retraction: a, overall superimposition shows clockwise rotation of the mandible and retrusion of the upper and lower lips; b, in regional superimpositions, the upper incisors were uprighted and lower incisors were significantly intruded. The upper and lower molars were slightly extruded and moved mesially. (B) Superimposition of cephalometric tracings before and after retraction: a, overall superimposition shows counterclockwise rotation of the mandible and the favorable lingual retrusion of the upper and lower lips; b, in regional superimpositions, the upper incisors were retracted with careful control of axial inclination. No mesial movement of the upper molars was noted. The upper and lower molars were slightly intruded.

- clockwise rotation of the mandible.

During retraction

- controlled intrusive tipping movement of the upper incisors;
- no mesial movement of the upper molars;
- slight intrusion of the upper and lower molars;
- counterclockwise rotation of the mandible;
- favorable lingual retrusion of the upper and lower lips.

As shown in Table 2, cephalometric measurements reveal that during retraction, the axial inclination and the dental height of the upper incisors decreased 11.9° and 1.3 mm, respectively.

DISCUSSION

The soft tissue in the palatal area is thicker than in other areas, and the thickness increases from the gingival to the apical aspect.¹⁵ In the medial posterior area of the palate, most of the soft tissue is less than 1 mm thick.²⁶ If a screw that is too short is used in the thick palatal soft tissue region, it could easily become dislodged. Therefore, it is important to measure the soft tissue thickness to determine the optimal length of screw. In case 1, screw-type implants with a diameter of 2 mm and a length of 13 mm in the right side and a diameter of 2 mm and a length of 11 mm in the left side were used in the apical region of the posterior teeth. In case 2, screw-type implants 2 mm in diameter and 8 mm in length were used in the posterior area of the midpalatal region.

In the described lever-arm and mini-implant system, we used the center of resistance of the 6 anterior teeth defined by Vanden Bulcke et al,²³ which has been reported for well-defined force systems with constant anatomic morphology. Individual variation in the bone-root anatomy and the structure of the periodontal ligament may slightly alter the location of the center of resistance in vivo.

Lever-arm mechanics can be applied using segmented archwires or continuous archwires. The advantage of using segmented archwires is that it is possible to develop a precise and predictable force system between an anterior segment and a posterior segment. However, in the cases presented in this study, lever-arm mechanics using continuous stiff archwires were used to guide the anterior teeth in their progress along the dental arch from their initial position to their final location.

In case 1, a retraction force parallel to the occlusal plane and applied through the center of resistance of the 6 anterior teeth produced bodily movement of the anterior teeth in conjunction with intrusion. Since stiff mushroom archwire (0.018 × 0.018-inch stainless steel) guided the anterior teeth parallel to the occlusal plane, unexpected intrusion of the anterior teeth occurred in the lever-arm and the mini-implant system for bodily movement of the anterior teeth during retraction. During retraction, the U1-FH angle de-

creased 4.8° in case 1, where the lever-arm and mini-implant system was designed to obtain a bodily movement of the upper incisors and decreased 11.9° in case 2, where the lever-arm and mini-implant system was designed to obtain a tipping movement of the upper incisors. The decrease in the U1-FH angulation for case 2 is 7.1° greater than that for case 1. These results support the hypothesis that the lever-arm and mini-implant system is useful for obtaining careful control of incisor axial inclination during retraction with lingual orthodontic treatment.

CONCLUSIONS

The recent introduction of micro- and mini-implants into orthodontics has provided clinicians with a reliable means of solving anchorage problems, including space closure, open-bite treatment, molar distalization, and uprighting of the posterior teeth. As shown in this study, mini-implants in conjunction with lever-arm can also be used to control the point of force application in the posterior area and produce the ideal force system during retraction in lingual orthodontic treatment.

REFERENCES

1. Steiner CC. Cephalometrics for you and me. *Am J Orthod.* 1953; 39:729–755.
2. Tweed CH. Frankfort mandibular incisor angle (FMIA) in orthodontic diagnosis, treatment planning, and prognosis. *Angle Orthod.* 1954;24:121–169.
3. Low FD, Hunter WS. Changes in nasolabial angle related to maxillary incisor retraction. *Am J Orthod.* 1982;82:384–391.
4. Sarver DM. The importance of incisor positioning in the esthetic smile: the smile arc. *Am J Orthod Dentofacial Orthop.* 2001;120: 98–111.
5. Takemoto K. Sliding mechanics versus loop mechanics during en masse retraction in extraction cases. In: Romano R, ed. *Lingual Orthodontics*. Hamilton, Ontario, Canada: BC Decker; 1998:109–115.
6. Hong RK. *Mushroom Archwire Technique and the Lingual Bracket*. Seoul, South Korea: Jeessung; 2000:58–69.
7. Burstone CJ. The segmented arch approach to space closure. *Am J Orthod.* 1982;82:361–378.
8. Bantleon HP. Modified lingual lever arm technique: biomechanical considerations. In: Nanda R, ed. *Biomechanics in Clinical Orthodontics*. Philadelphia, Penn: WB Saunders; 1997:229–245.
9. Park YC, Choy KC, Lee JS, Kim TK. Lever-arm mechanics in lingual orthodontics. *J Clin Orthod.* 2000;34:601–605.
10. Creekmore TD, Eklund MK. The possibility of skeletal anchorage. *J Clin Orthod.* 1983;17:266–269.
11. Kanomi R. Mini-implant for orthodontic anchorage. *J Clin Orthod.* 1997;31:763–767.
12. Lee JS, Park HS, Kyung HM. Micro-implant anchorage for lingual treatment of a skeletal Class II malocclusion. *J Clin Orthod.* 2001;35:643–647.
13. Karaman AI, Basciftci FA, Polat O. Unilateral distal molar movement with an implant-supported distal jet appliance. *Angle Orthod.* 2002;72:167–174.
14. Kyung SH, Hong SG, Park YC. Distalization of maxillary molars with a midpalatal miniscrew. *J Clin Orthod.* 2003;37:22–26.
15. Park YC, Lee SY, Kim DH, Jee SH. Intrusion of posterior teeth

- using mini-screw implants. *Am J Orthod Dentofacial Orthop.* 2003;123:690–694.
16. Umemori M, Sugawara J, Mitani H, Nagasaka H, Kawamura H. Skeletal anchorage system for open-bite correction. *Am J Orthod Dentofacial Orthop.* 1999;115:166–174.
 17. Chung KR, Kim YS, Lee Linton J, Lee YJ. The miniplate with tube for skeletal anchorage. *J Clin Orthod.* 2002;36:407–412.
 18. Roberts WE, Smith RK, Zilberman Y, Mozsary PG, Smith RS. Osseous adaptation to continuous loading of rigid endosseous implants. *Am J Orthod.* 1984;86:95–111.
 19. Roberts WE, Helm FR, Marshall KJ, Gongloff RK. Rigid endosseous implants for orthodontic and orthopedic anchorage. *Angle Orthod.* 1989;59:247–255.
 20. Ödman J, Lekholm U, Jemt T, Thilander B. Osseointegrated implants as orthodontic anchorage in treatment of partially edentulous adult patients. *Eur J Orthod.* 1994;16:187–201.
 21. Wehrbein H, Feifel H, Diedrich P. Palatal implant anchorage reinforcement of posterior teeth: a prospective study. *Am J Orthod Dentofacial Orthop.* 1999;116:678–686.
 22. Block MS, Hoffman DR. A new device for absolute anchorage for orthodontics. *Am J Orthod Dentofacial Orthop.* 1995;107:251–258.
 23. Vanden Bulcke MM, Burstone CJ, Sachdeva RCL, Dermaut LR. Location of the centers of resistance for anterior teeth during retraction using the laser reflection technique. *Am J Orthod Dentofacial Orthop.* 1987;91:375–384.
 24. Hong RK, Sohn HW. Update on the Fujita lingual bracket. *J Clin Orthod.* 1999;33:136–142.
 25. Hong RK, Soh BC. Customized indirect bonding method for lingual orthodontics. *J Clin Orthod.* 1996;30:650–652.
 26. Yun HS, Kim HJ, Kim KH, Park YC. *The Thickness of the Maxillary Soft Tissue and Cortical Bone Related with an Orthodontic Implantation.* Master's Thesis. Seoul, South Korea: Yonsei University; 2001.