

# Bimaxillary Dentoalveolar Protrusion: Traits and Orthodontic Correction

Daniel A. Bills<sup>a</sup>; Chester S. Handelman<sup>b</sup>; Ellen A. BeGole<sup>c</sup>

**Abstract:** A group of 48 ethnically diverse patients with bimaxillary protrusion was used to study the pretreatment cephalometric traits of this malocclusion and the effect of orthodontic correction. All patients were treated with four premolar extractions and retraction of the anterior teeth. Pre- and posttreatment lateral cephalograms were evaluated using a series of 18 linear and angular measurements, and the effect of orthodontic correction was determined using paired *t*-tests. Cephalometric standards were developed for bimaxillary protrusions, which clarify the overall presentation of this malocclusion for clinicians. Patients with bimaxillary protrusion demonstrated increased incisor proclination and protrusion, a vertical facial pattern, increased procumbency of the lips, a decreased nasolabial angle, and thin and elongated upper and lower anterior alveoli. This study also showed that the extraction of four premolars can be extremely successful in reducing the dental and soft tissue procumbency seen in patients with bimaxillary protrusion, thus providing a stronger evidence-based rationale for this treatment modality. (*Angle Orthod* 2005;75:333–339.)

**Key Words:** Bimaxillary protrusion; Dentoalveolar protrusion; Cephalometric standards

## INTRODUCTION

Bimaxillary protrusion is a condition characterized by protrusive and proclined upper and lower incisors and an increased procumbency of the lips. It is seen commonly in African-American<sup>1–4</sup> and Asian<sup>5–7</sup> populations, but it can be seen in almost every ethnic group. Because of the negative perception of protrusive dentition and lips in most cultures, many patients with bimaxillary protrusion seek orthodontic care to decrease this procumbency.

The etiology of bimaxillary protrusion is multifactorial and consists of a genetic component as well as environmental factors, such as mouth breathing, tongue and lip habits, and tongue volume.<sup>7</sup> There is a paucity of infor-

mation in the literature in terms of the overall characteristics of this malocclusion. However, in one of the few studies of its kind, Keating<sup>8</sup> used cephalometrics to determine the morphological features of bimaxillary protrusion in a strictly Caucasian population. He reported that bimaxillary protrusion was associated with a shorter posterior cranial base, a longer and more prognathic maxilla, and a mild Class II skeletal pattern. He also showed that Caucasians with this condition displayed a smaller upper and posterior face height, diverging facial planes, and a procumbent soft tissue profile with a low lip line.

The goals of orthodontic treatment of bimaxillary protrusion include the retraction and retroclination of maxillary and mandibular incisors with a resultant decrease in soft tissue procumbency and convexity. This is most commonly achieved by the extraction of four first premolars followed by the retraction of anterior teeth using maximum anchorage mechanics.

The successful orthodontic correction of bimaxillary protrusion has been reported. Tan<sup>6</sup> studied orthodontic correction of bimaxillary protrusion in 50 Chinese adult patients and found favorable soft tissue and dental changes after the extraction of four premolars. Lew<sup>5</sup> looked at profile changes after the extraction of four first premolars and orthodontic treatment of bimaxillary protrusion in 32 Asian adults. He reported significant improvement in upper and lower incisor protrusion, nasolabial angle, upper and lower lip length, and upper and lower lip protrusion. Finally, in a case report on the use of four premolar extraction and lingual appliances

<sup>a</sup> Former resident, Department of Orthodontics, College of Dentistry, University of Illinois at Chicago, Chicago, Ill; Private Practice, Washington Township and Vineland, NJ.

<sup>b</sup> Assistant Clinical Professor of Orthodontics, Department of Orthodontics, College of Dentistry, University of Illinois at Chicago, Chicago, Ill.

<sup>c</sup> Professor of Biostatistics in Orthodontics, Department of Orthodontics, College of Dentistry, University of Illinois at Chicago, Chicago, Ill.

Corresponding author: Chester S. Handelman, DMD, 25 East Washington Street, Chicago, IL 60602 (e-mail: chandel@uic.edu).

Accepted: November 2004. Submitted: May 2004.

© 2005 by The EH Angle Education and Research Foundation, Inc.

This article is based on research submitted by Dr Bills in partial fulfillment of the requirements for the degree of Master of Science in Oral Sciences, University of Illinois at Chicago, Chicago, Ill.

for the corrections of bimaxillary protrusion, Kurz<sup>9</sup> found that the upper and lower incisors became more retroclined and retrusive, resulting in a greatly improved facial profile.

Several other studies on the amount of profile improvement in patients treated with four premolar extraction have shown results that have varied greatly.<sup>10-12</sup> The efficacy of this treatment is also variable in terms of the extent of retraction, completeness of space closure, treatment time, and iatrogenic consequences.<sup>13</sup>

The most comprehensive study of the traits associated with this malocclusion was done on a sample consisting solely of Caucasian patients—a subset of the population with a low prevalence of this condition.<sup>8</sup> This study was designed to demonstrate the cephalometric characteristics of this malocclusion in a sample of ethnically diverse men and women to clarify the skeletal, dental, and soft tissue features of this relatively common orthodontic problem.

It is rather well accepted by clinicians that the extraction of four first premolars can be effective in the treatment of bimaxillary protrusion. However, given the fact that the practice of dentistry and orthodontics is now increasingly defined by an evidence-based approach to treatment, it is surprising that there is relatively little in the literature providing concrete evidence on the efficacy of this treatment approach. With that in mind, this study was designed to provide evidence of the changes that occur orthodontically by the extraction of first premolars in a large sample of patients with bimaxillary protrusion.

## MATERIALS AND METHODS

A sample of 84 patients who were clinically diagnosed with bimaxillary protrusion was chosen from the files of previously treated patients at a university orthodontic clinic. From this parent sample, 48 patients who met the following selection criteria were included in this study:

1. a minimum age of 15 for women and 18 for men at start of treatment;
2. orthodontic treatment consisting of the extraction of four premolars (at least three of which were first premolars) with subsequent retraction of anterior teeth;
3. pre- and posttreatment cephalometric radiographs of adequate diagnostic quality;
4. pretreatment Class I molar relationship;
5. pretreatment interincisal angle less than 124°;
6. pretreatment upper incisor protrusion (U1-APog) more than 7.7 mm;
7. pretreatment lower incisor protrusion (L1-APog) more than 3.0 mm.

The sample consisted of 38 women and 10 men. Twenty-two patients in the sample were African-American, 15 were Hispanic, seven were Caucasian, and four were Asian. Forty-four of the patients in the sample were treated with extraction of four first premolars. The remaining four individ-

**TABLE 1.** Age (mo) of Patients in Sample at Start of Treatment

	Male (n = 10)	Female (n = 38)	Combined (n = 48)
Mean	23.98	19.60	20.51
SD	5.95	4.67	5.22
Minimum	18.25	15.08	15.08
Maximum	38.50	30.83	38.50

uals were treated with the extraction of three first premolars and one second premolar.

Because these patients were treated in a university setting by several different practitioners, treatment modalities were quite variable. However, in all cases, an edgewise appliance was used, and the clinician reported that maximum anchorage mechanics were used with the variable use of extraoral headgear, palatal buttons, and transpalatal arches. Table 1 summarizes the sample on the basis of age and sex. The rights and privacy of all patients in the sample were protected, and approval was obtained from the Institutional Review Board of the university where the research was conducted.

The following information was recorded from each patient's clinical record: age at start of treatment, sex, ethnicity, duration of treatment in months, and extraction pattern. Pretreatment and posttreatment cephalometric radiographs were digitized, traced, and analyzed using Dolphin Imaging's "Cephalometric Tracing and Analysis" software (Dolphin Imaging System; Canoga Park, Calif).

Analysis of both the pretreatment and posttreatment radiographs included 18 linear and angular measurements. The norms for alveolar width and height (Figure 1; Table 3) were described by Handelman<sup>14</sup> (Table 4). Mixed racial norms for measurements 1 through 12 (Table 4) were developed specifically for this research by Dolphin Imaging System.

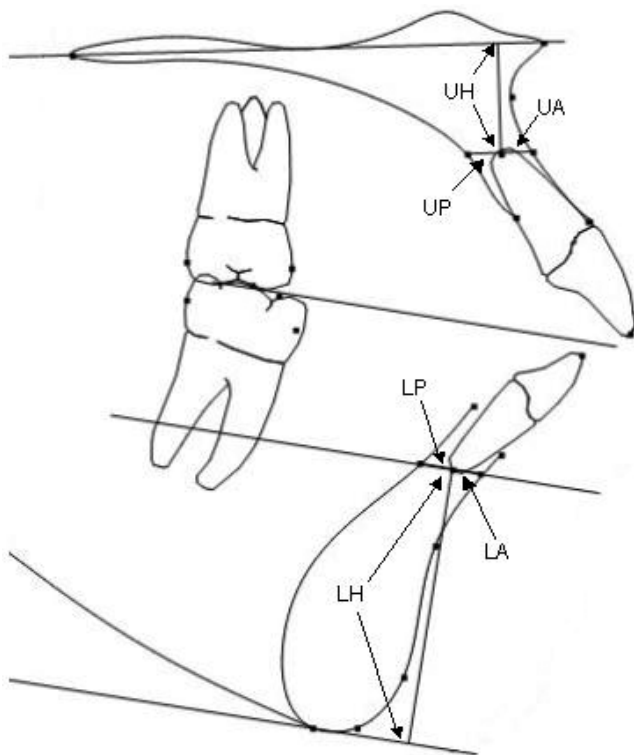
The mean, range, and standard deviation (SD) were determined for each of the pretreatment measurements. The treatment results were analyzed in the following parameters by measuring the changes between the pretreatment and posttreatment cephalograms: interincisal angle; inclination of upper incisors (U1-SN); inclination of lower incisors (L1-MP); anteroposterior position of upper incisors (U1-APo); anteroposterior position of lower incisors (L1-APo); upper lip to E-plane, change in lower lip to E-plane; nasolabial angle; lower anterior face height; and mandibular plane angle.

For the purpose of error testing, pre- and posttreatment cephalograms were traced at the same time, and all radiographs were traced by the same operator. Ten patients were selected, and pre- and posttreatment radiographs were traced and then retraced by the same operator a minimum of two weeks later. The tracings were analyzed, and the differences in measurements between the two different trac-

**TABLE 2.** Cephalometric Measurements

Measurement	Description
1. Interincisal angle	Angle between U1 axis <sup>a</sup> and L1 axis <sup>b</sup>
2. Upper incisor inclination (U1-SN)	Angle between U1 axis and SN plane <sup>c</sup>
3. Lower incisor inclination (L1-MP)	Angle between L1 axis and mandibular plane <sup>d</sup>
4. Upper incisor position (U1-APog)	Angle between U1 axis and A-Pog <sup>e</sup> line
5. Lower incisor position (L1-APog)	Angle between L1 axis and A-Pog line
6. Lower anterior face height	Distance (mm) between ANS and Menton
7. Mandibular plane angle	Angle between mandibular plane and Frankfurt horizontal <sup>f</sup>
8. Upper lip thickness	Perpendicular distance (mm) from most anterior point on upper lip to a line drawn through soft tissue A point perpendicular to Frankfurt horizontal
9. Lower lip thickness	Perpendicular distance (mm) from most anterior point on lower lip to a line drawn through soft tissue B point perpendicular to Frankfurt horizontal
10. Upper lip position (UL-E)	Distance (mm) from most anterior point on upper lip to E plane <sup>g</sup>
11. Lower lip position (LL-E)	Distance (mm) from most anterior point on lower lip to E plane
12. Nasolabial angle	Angle between a line tangent to base of nose and a line tangent to the upper lip

- <sup>a</sup> U1 axis: line through tip and root of U1.
- <sup>b</sup> L1 axis: line through tip and root of L1.
- <sup>c</sup> SN plane: plane through points Sella and Nasion.
- <sup>d</sup> Mandibular plane: plane through points Gonion and Gnathion.
- <sup>e</sup> A-Pog line: line between points A and Pogonion.
- <sup>f</sup> Frankfurt horizontal: plane through points Porion and Orbitale.
- <sup>g</sup> E plane: plane extending from tip of nose to soft tissue Pogonion.



**FIGURE 1.** Cephalometric measurements of alveolar width.<sup>14</sup>

ings of the same radiograph were calculated. Paired *t*-tests were performed to determine the significant differences between the two tracings.

The cephalometric values from the pre- and posttreatment cephalograms were evaluated by paired *t*-test. The paired *t*-test is used for assessing the effectiveness of treat-

ments by using related data from nonindependent samples. This study used the before and after measurements as the paired data with the resulting difference being the variable of interest. This difference represented the effect of treatment.

## RESULTS

### Error testing

No significant difference was found between any of the measurements on the 10 cephalograms traced at two different time points, at a minimum of two weeks apart for the purpose of error testing.

### Pretreatment characteristics

Descriptive data regarding the characteristics measured from the pretreatment cephalometric radiographs of each subject were determined and are given in Table 4. The mean, SD, minimum, and maximum for each measurement are listed. For comparison, mixed racial norms are listed in Table 4 as well as the norms for the alveolar measurements.<sup>14</sup>

Patients with bimaxillary protrusion exhibited a decreased interincisal angle ( $-17.8^\circ$ ) and much more obtuse measures of incisor inclination, ( $+10.2^\circ$  for the upper incisor and  $+10.7^\circ$  for the lower incisor) when compared with their norm. The subjects also had upper and lower incisors that were extremely protrusive in an anteroposterior direction, ( $+7.3$  mm for the upper incisor and  $+5.7$  for the lower incisor). The pretreatment mean measurement of lower anterior face height was found to be 5.6 mm lon-

**TABLE 3.** Cephalometric Measurements of Alveolar Width, From Handelman<sup>14</sup>

Measurement	Description
UP	Bone posterior (lingual) to upper incisor apex. Apex of the maxillary central incisors to the limit of the palatal cortex, along a plane parallel to the palatal plane, drawn through the apex.
UA	Bone anterior (labial) to upper incisor apex. Apex of the maxillary central incisors to the limit of the labial cortex, along a plane parallel to the palatal plane, drawn through the apex.
LP	Bone posterior (lingual) to mandibular incisor apex. Apex of the mandibular central incisor to the limit of the lingual cortex, along a plane parallel to the occlusal plane, drawn through the apex.
LA	Bone anterior (labial) to mandibular incisor apex. Apex of the mandibular central incisors to the limit of the labial cortex, along a plane parallel to the occlusal plane, drawn through the apex.
UH	Bone superior to upper incisor apex. The shortest distance from the maxillary incisor apex to the palatal plane.
LH	Bone inferior to mandibular incisor apex. The shortest distance from the apex of the mandibular incisor to the lowest point on the mandibular symphysis that is transected by a line parallel to the occlusal plane.

**TABLE 4.** Pretreatment Cephalometric Characteristics of Individuals With Bimaxillary Protrusion (N = 48)

Measurement	Mean	SD	Minimum	Maximum	Norm Mean <sup>a,b</sup>	SD
Interincisal angle	112.2	6.7	94.6	123.9	130.0	6.0
Upper incisor inclination (U1-SN)	113.5	7.3	97.4	127.9	103.0	5.5
Lower incisor inclination (L1-MP)	100.7	6.4	87.8	118.2	90.0	6.0
Upper incisor position (U1-Apo)	13.3	3.1	8.0	19.6	6.0	2.2
Lower incisor position (L1-APo)	8.4	2.8	3.8	14.2	2.7	1.7
Lower anterior face height	75.6	10.5	57.5	129.9	70.0	5.5
Mandibular plane angle	28.8	6.8	8.7	40.1	23.4	4.5
Upper lip thickness	5.6	2.9	1.4	12.5	1.0	1.0
Lower lip thickness	3.3	3.9	-6.1	11.7	1.0	1.0
Upper lip position (UL-E)	1.0	3.3	-6.3	7.3	-7.0	2.0
Lower lip position (LL-E)	4.7	3.6	-4.9	11.9	-2.0	2.0
Nasolabial angle	93.9	12.2	64.8	122.8	102.0	8.0
Width of upper anterior alveolus	4.5	2.1	2.4	16.4	4.9	1.1
Width of upper posterior alveolus	6.8	2.3	2.6	13.3	8.4	2.4
Width of lower anterior alveolus	2.5	0.8	2.6	13.3	3.7	1.2
Width of lower posterior alveolus	4.1	1.4	1.3	8.3	4.3	1.3
Upper alveolar height	10.9	2.9	4.9	17.2	6.1	2.6
Lower alveolar height	27.3	4.8	19.2	49.1	22.7	2.3

<sup>a</sup> Norms are mixed-racial norms developed by Dolphin Imaging System.

<sup>b</sup> Norms for alveolar width and height developed by Handelman.<sup>14</sup>

ger than normal. In addition, the mean mandibular plane angle was 5.4° larger as compared with the norm.

Normal values for upper and lower lip thickness, as defined in Table 2, are both 1.0 mm.<sup>16</sup> Individuals in this study had increased measures of mean upper and lower lip thicknesses at 5.6 and 3.3 mm, respectively. Both the upper and the lower lips were found to be ahead of the E-plane (1.0 and 4.7 mm, respectively), and this is in contrast to the norm where the lips are behind the E-plane (-7.0 and -2.0, respectively). The mean nasolabial angle of patients in this study was found to be decreased at 93.9° (norm = 102°).

### Effect of treatment

To determine the overall effect of the orthodontic correction of bimaxillary protrusion, the changes between pre-

treatment and posttreatment cephalometric radiographs were determined and are given in Table 5. The mean change and SD for each measurement are listed along with associated *P* values as determined by paired *t*-tests. A reduction in the measurements is represented by a negative value, whereas an increase is represented by a positive value.

The mean interincisal angle was increased 18.1° in these patients as a result of treatment. The upper incisors were retroclined a mean of 12.7°, whereas the lower incisors were retroclined a mean of 5.6°. The upper and lower incisors were retracted a mean of 5.2 and 3.2 mm, respectively. In addition, the upper lip was retracted an average of 2.4 mm, and the lower lip was retracted an average of 3.0 mm. All these changes were found to be statistically significant (*P* < .001).

**TABLE 5.** Cephalometric Changes After Orthodontic Correction of Bimaxillary Protrusion (N = 48)

Measurement	Mean Change (Post – Pre)	SD	P value
Interincisal angle	18.13	10.38	.000
Upper incisor inclination (U1-SN)	-12.71	7.51	.000
Lower incisor inclination (L1-MP)	-5.64	5.80	.000
Upper incisor position (U1-Apo)	-5.20	2.30	.000
Lower incisor position (L1-APo)	-3.22	1.99	.000
Upper lip position (UL-E)	-2.41	1.67	.000
Lower lip position (LL-E)	-3.00	2.09	.000
Nasolabial angle	3.11	9.04	.021
Lower anterior face height	-0.53	7.80	.640
Mandibular plane angle	-0.39	2.34	.250

## DISCUSSION

### Pretreatment characteristics

This study was the first to look at an ethnically diverse sample of patients with bimaxillary protrusion to determine their pretreatment cephalometric characteristics. All measurements (except for those of alveolar width and height) were compared with population (mixed racial) norms developed by Dolphin Imaging System from a collection of original research. These values were used for comparison purposes because they best represent the ethnic variability of this sample. It should be noted that because these normal values represent a combination of cephalometric norms reported for various races, they tend to fall somewhere in between the norms generally used for Caucasians and for African-Americans. Although the actual numerical value of any reported difference is in comparison to these mixed norms, all measurements reported as being increased or decreased also differ with respect to the African-American norms reported by Richardson.<sup>15</sup>

Table 4 shows the pretreatment cephalometric traits of the patients in this study and presents a good composite of the characteristics present in patients with bimaxillary protrusion. Patients with this condition demonstrated increased upper and lower incisor proclination and protrusion, generally 2 to 3 SD from the mixed racial norms. This result was not surprising because of the fact that the measures of these variables were in the selection criteria for inclusion in this study and are by definition part of this malocclusion. The cephalometric characteristics other than these dental changes, however, paint a much larger picture of the patient with bimaxillary protrusion and can give the practitioner a broader idea of what to expect from these patients.

The increased lower anterior face height, mandibular plane angle, and upper and lower alveolar heights found in this study indicate that individuals with bimaxillary protrusion tend to have vertical growth patterns. This finding is consistent with that of Keating,<sup>8</sup> who found hyperdivergent facial patterns in a Caucasian sample with bimaxillary protrusion. Although the correlation between interincisal angle and mandibular divergence was significant, it is difficult to

establish causation—does the mandibular divergence cause an increase in interincisal angle or visa-versa? However, stepwise regression analysis of factors influencing an increase in interincisal angle showed a coefficient of determination of 31.6% for mandibular divergence, which was significant at the .001 level (this data has not been reported in this paper).

Jacobson<sup>16</sup> reported that a normal distance for the incisors from both the upper and lower lip is 7.0 and 2.0 mm behind the E-plane, respectively. In this study both the upper and the lower lips in contrast were found to be ahead of the E-plane. The procumbent position of the lower lip in these patients is consistent with the work of Keating,<sup>8</sup> who found the lower lip 6.0 mm ahead of the E-plane in Caucasian patients with bimaxillary protrusion. The fact that the upper lip was 1.0 mm ahead of the E-plane suggests that the subjects in this sample had protrusive upper lips, but, this result was less than the 3.4 mm found by Keating.<sup>8</sup> Subjects in this study were found to have increased measurements of upper and lower lip thickness. Because previous studies have clearly shown that African-American individuals tend to have increased lip thickness, this result is most likely due to the large percentage of African-American patients in this sample.

The nasolabial angle in our subjects was 94°, 1 SD more acute than the mixed racial norm. An even more acute measurement of the nasolabial angle was found by Tan,<sup>6</sup> who determined the pretreatment nasolabial angle of Chinese patients with bimaxillary protrusion to be decreased at 86.6°. This result is another indication of the soft tissue procumbency seen in patients with this condition.

Handelman<sup>14</sup> described a technique for measuring upper and lower alveolar widths and heights on lateral cephalograms and determined these measurements for a sample of 107 adult Caucasian individuals before orthodontic treatment. Although he analyzed patients with various malocclusions, he classified the 18 patients with a Class I molar relationship and an average mandibular plane angle as being his normal controls. Because no other normal values are present in the literature, the pretreatment values for these measurements in this study are compared with these

norms, but it is important to keep in mind that the small sample size could limit proper interpretation.

As compared with Handelman's<sup>14</sup> normal sample, the mean values of all four measurements of alveolar width were less than bimaxillary protrusive sample. In addition, the mean values of both upper and lower alveolar heights were found to be greater in this sample, and this is consistent with the increase in anterior facial height seen in this sample. On the surface, these results may suggest that individuals with bimaxillary protrusion tend to have a thin and elongated alveolus as compared with individuals with a normal occlusion. However, as mentioned previously, the small sample size in Handelman's<sup>14</sup> study made it difficult to run any credible comparison. Patients at the minimal end of the range for width of the upper and lower posterior alveolus (2.6 and 1.3 mm, respectively) would likely be limited to uprighting of the incisors with minimal bodily retraction. An extremely thin alveolus could be a limiting factor in orthodontic correction of bimaxillary protrusion, and some of these patients may require surgical osteotomies for effective and safe treatment of their dental protrusions.<sup>14</sup>

### Effect of treatment

Patients in this study were treated with the extraction of four premolars and the retraction of anterior teeth in an attempt to correct their bimaxillary protrusion. The results of this study demonstrated a significant increase in interincisal angle, a significant decrease in upper and lower incisor inclination, and a significant decrease in the anteroposterior position of the upper and lower incisors ( $P < .001$ ). These findings suggest that this treatment modality is effective in decreasing the incisor protrusion and proclination that is characteristic of bimaxillary protrusion.

Most authors conducting this type of research have established ratios comparing dental movements to soft tissue movements—most commonly the amount of upper incisor retraction to upper lip retraction—in an attempt to establish guidelines for clinical management. In this study, this ratio for the upper lip was 2.2:1 (5.2 mm of upper incisor retraction to 2.4 mm of upper lip retraction). This result is similar to those of Chiasson<sup>12</sup> and Hershey,<sup>17</sup> who found ratios of 2.2:1 and 2:1, respectively, but it is less than the 3:1 ratio reported by Diels et al.<sup>10</sup>

These results, together with the significant increase in nasolabial angle seen in these patients ( $P < .02$ ), suggest that the extraction of four premolars can be effective in decreasing the soft tissue procumbency in patients with bimaxillary protrusion. However, the large SD, which accompany the mean changes in lip position, as well as the varying ratios of incisor retraction to lip retraction reported in the literature, suggest a great deal of variability in the soft tissue response. Factors such as interlabial gap, lip redun-

dancy, quality of the lip musculature, etc, must be evaluated in the patient with bimaxillary protrusion to gain more information on the possible consequences of incisor retraction.<sup>1,11,12,14</sup>

No significant difference was found between the pre- and posttreatment measurements of lower anterior face height and mandibular plane angle. These results suggest that the mechanics used in the treatment of individuals with bimaxillary protrusion have no significant effect on the vertical dimension.

### CONCLUSIONS

- Cephalometric standards were developed for bimaxillary protrusion in an ethnically diverse sample, clarifying the overall presentation of this malocclusion for clinicians.
- In addition to the increased incisor proclination and protrusion inherent to this malocclusion, patients with bimaxillary protrusion tend, on average, to demonstrate a vertical facial pattern, a decreased nasolabial angle, and thin and elongated upper and lower anterior alveoli.
- The results of this study also showed that the extraction of four premolars can be extremely successful in reducing the dental and soft tissue procumbency seen in patients with bimaxillary protrusion. This provides a stronger evidence-based rationale for this treatment modality.

### REFERENCES

1. Scott SH, Johnston LE. The perceived impact of extraction and nonextraction treatments on matched samples of African American patients. *Am J Orthod Dentofacial Orthop.* 1999;116:352–358.
2. Farrow AK, Zarrinnia K, Azizi K. Bimaxillary protrusion in black Americans—an esthetic evaluation and the treatment considerations. *Am J Orthod Dentofacial Orthop.* 1993;104:240–250.
3. Fonseca RJ, Klein WD. A cephalometric evaluation of American Negro women. *Am J Orthod.* 1978;73:152–160.
4. Rosa RA, Arvystas BA. An epidemiologic survey of malocclusions among American Negroes and American Hispanics. *Am J Orthod.* 1978;73:258–273.
5. Lew K. Profile changes following orthodontic treatment of bimaxillary protrusion in adults with the Begg appliance. *Eur J Orthod.* 1989;11:375–381.
6. Tan TJ. Profile changes following orthodontic correction of bimaxillary protrusion with a preadjusted edgewise appliance. *Int J Adult Orthod Orthognath Surg.* 1996;11:239–251.
7. Lambertson CM, Reichart PA, Triratanimit P. Bimaxillary protrusion as a pathologic problem in the Thai. *Am J Orthod Dentofacial Orthop.* 1980;77:320–329.
8. Keating PJ. Bimaxillary protrusion in the Caucasian: a cephalometric study of the morphological features. *Br J Orthod.* 1985; 12:193–201.
9. Kurz C. The use of lingual appliances for correction of bimaxillary protrusion. *Am J Orthod Dentofacial Orthop.* 1997;112:357–363.
10. Diels RM, Kalra V, DeLoach N, Powers M, Nelson SS. Changes

- in soft tissue profile of African-Americans following extraction treatment. *Angle Orthod.* 1995;65:285–292.
11. Talass MF, Talass L, Baker RC. Soft-tissue profile changes resulting from retraction of maxillary incisors. *Am J Orthod Dentofacial Orthop.* 1987;91:385–394.
  12. Chiasson RC. *Soft Tissue Changes in Black Orthodontic Patients* [master's thesis]. Chicago, Ill: University of Illinois at Chicago; 1996.
  13. Jacobs JD, Bell WH. Combined surgical and orthodontic treatment of bimaxillary protrusion. *Am J Orthod Dentofacial Orthop.* 1983;83:321–333.
  14. Handelman CS. The anterior alveolus: its importance in limiting orthodontic treatment and its influence on the occurrence of iatrogenic sequelae. *Angle Orthod.* 1996;66:95–110.
  15. Richardson ER. *Atlas of Craniofacial Growth in Americans of African Descent, Volume 26. Craniofacial Growth Series.* Ann Arbor, Mich: University of Michigan; 1991.
  16. Jacobson A. Ricketts analysis. In: *Radiographic Cephalometry: From Basics to Videoimaging.* Chicago, Ill: Quintessence Publishing; 1995.
  17. Hershey HG. Incisor tooth retraction and subsequent profile change in preadolescent female patients. *Am J Orthod.* 1972;61:45–54.