

# An Adult Case of Skeletal Open Bite with a Large Lower Anterior Facial Height

Eiji Tanaka<sup>a</sup>; Tatsunori Iwabe<sup>b</sup>; Nobuhiko Kawai<sup>c</sup>; Mika Nishi<sup>c</sup>; Diego Dalla-Bona<sup>c</sup>; Takuro Hasegawa<sup>c</sup>; Kazuo Tanne<sup>d</sup>

**Abstract:** Control of the height of posterior dentoalveolar regions is of great importance for the correction of skeletal open bite. Traditionally, second premolar extraction facilitates the closure of open bite by inducing a counterclockwise mandibular rotation without molar intrusion. This article reports treatment for a 24-year six-month-old female patient with an open bite and large anterior facial height. She complained of occlusal disturbances and difficulty of lip closure because of the open bite. Overjet and overbite were +3.0 mm and -3.0 mm, respectively. To correct open bite and crowding, the bilateral extraction of the maxillary and mandibular second premolars plus multibracket appliances for mesial movement of the molars was selected as the treatment plan. After a two-year treatment, an acceptable occlusion was achieved, the lower anterior facial height was decreased, and the lips showed less tension in a lip closure. An acceptable occlusion was maintained without recurrence of the open bite during a three-year retention period, indicating a long-term stability of the occlusion. The results of this treatment indicated that the correction of open bite with no or less molar intrusion or incisor extrusion is of great importance for achieving stable occlusion and avoiding the relapse of open bite. (*Angle Orthod* 2005;75:465-471.)

**Key Words:** Open bite; Second premolar extraction; Orthodontic treatment; Long-term stability

## INTRODUCTION

It is of great importance to control the height of the posterior dentoalveolar regions for the correction of skeletal open bite. Recently, a skeletal anchorage system (SAS) was developed for treatment of severe open bite, and with the use of this system, the vertical correction of posterior dentoalveolar region without unfavorable side effects became possible.<sup>1</sup> Now this system can provide a significant amount of intrusion of the lower molars.<sup>1</sup> However, tooth intrusion is one of the causative factors for root resorption during

orthodontic treatment and moderate root resorption has been reported when SAS was used.<sup>2</sup>

Traditionally, second premolar extraction facilitates the closure of anterior open bite by inducing a counterclockwise mandibular rotation without molar intrusion.<sup>3</sup> The more mesially the molars are moved, the easier these bites seem to close. The purpose of this article is to present an adult case of skeletal open bite with a long lower anterior facial height treated by means of second premolar extractions.

## CASE REPORT

The patient was a 24-year six-month-old female who had a severe anterior open bite and crowding with a Class II molar relationship (Figure 1). She complained of occlusal disturbances and difficulty of lip closure because of her open bite. Her facial profile was convex with a long anterior facial height, and no facial asymmetry was observed (Figure 1). Overjet and overbite were +3.0 mm and -3.0 mm, respectively. At the maximum intercuspation, occlusal contacts were recognized only at the molar regions. Gingival recession was found on the upper canines and the lower anterior teeth (Figure 1).

From the model analysis, the arch-length discrepancy was -5.1 mm on the upper and -6.6 mm on the lower arch. The panoramic radiograph showed the presence of the upper and lower third molars (Figure 2). All the first and

<sup>a</sup> Associate Professor, Department of Orthodontics and Craniofacial Developmental Biology, Hiroshima University Graduate School of Biomedical Sciences, Hiroshima, Japan.

<sup>b</sup> Clinical Associate, Orthodontic Clinic, Hiroshima University Medical and Dental Hospital, Hiroshima, Japan.

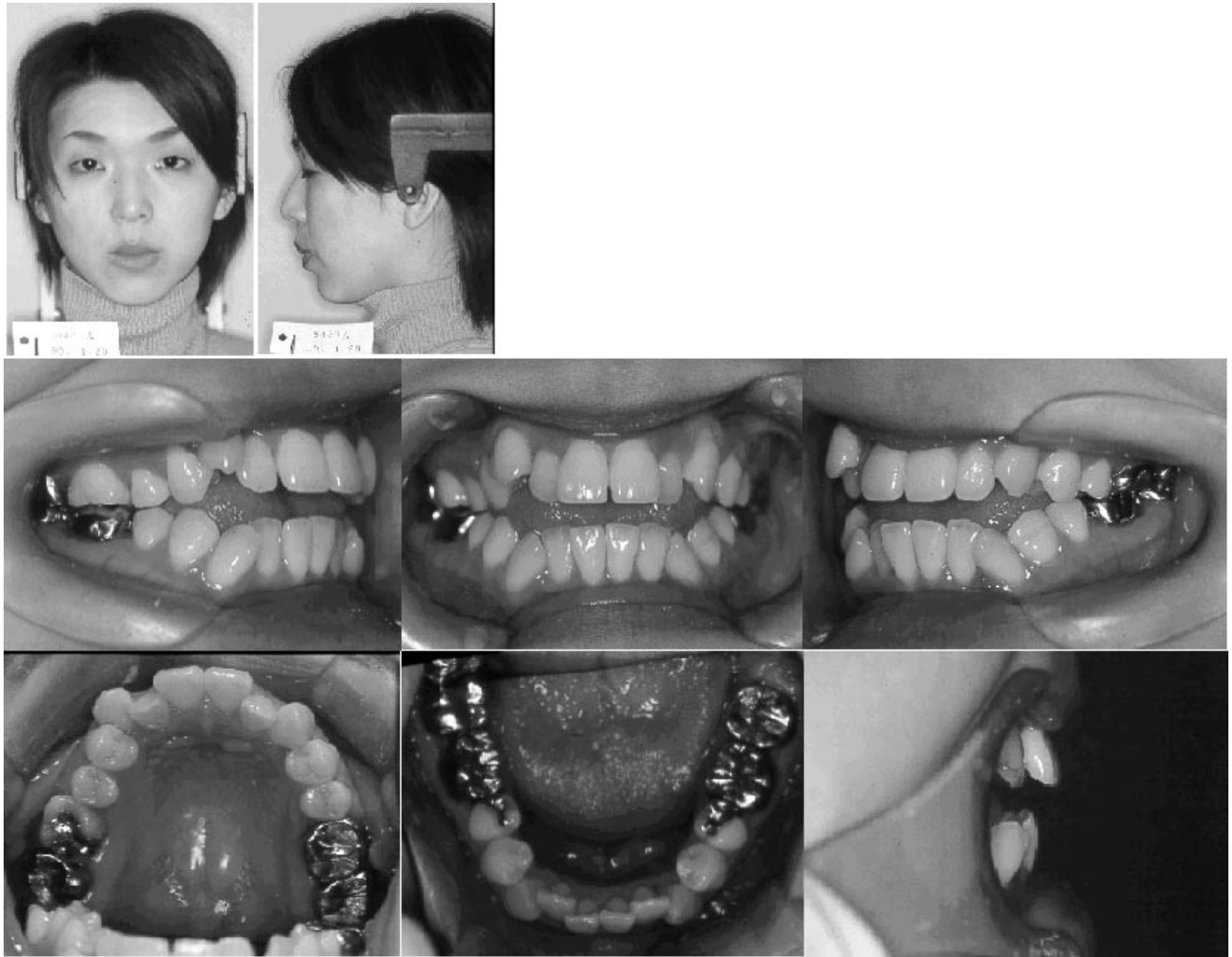
<sup>c</sup> Graduate Student, Department of Orthodontics and Craniofacial Developmental Biology, Hiroshima University Graduate School of Biomedical Sciences, Hiroshima, Japan.

<sup>d</sup> Professor and Chair, Department of Orthodontics and Craniofacial Developmental Biology, Hiroshima University Graduate School of Biomedical Sciences, Hiroshima, Japan.

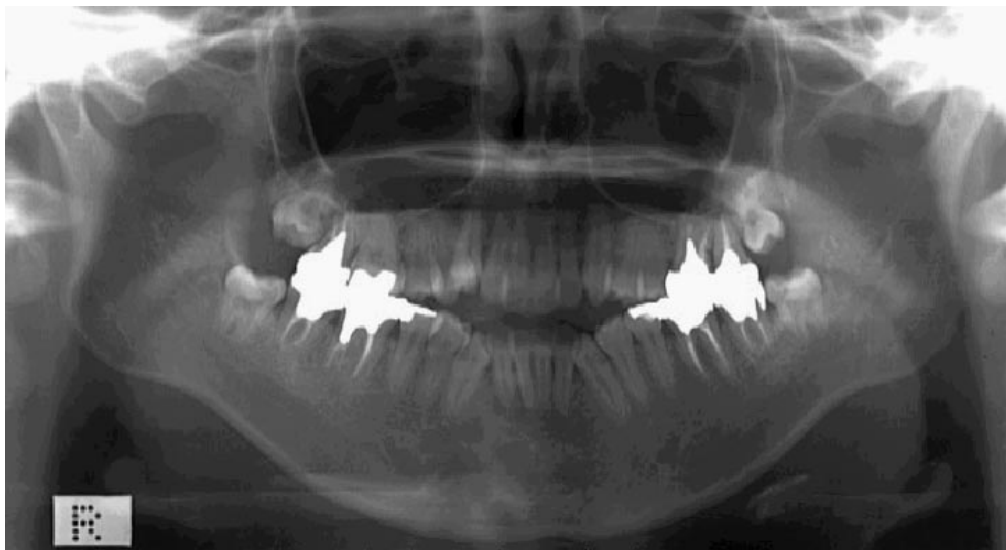Corresponding author: Eiji Tanaka, DDS, PhD, Department of Orthodontics and Craniofacial Developmental Biology, Hiroshima University Graduate School of Biomedical Sciences, 1-2-3 Kasumi, Minami-ku, Hiroshima 734-8553, Japan (e-mail: etanaka@hiroshima-u.ac.jp).

Accepted: May 2004. Submitted: April 2004.

© 2005 by The EH Angle Education and Research Foundation, Inc.



**FIGURE 1.** Facial and intra-oral photographs before treatment (24-year six-month-old).



**FIGURE 2.** Panoramic radiograph before treatment (24-year six-month-old).

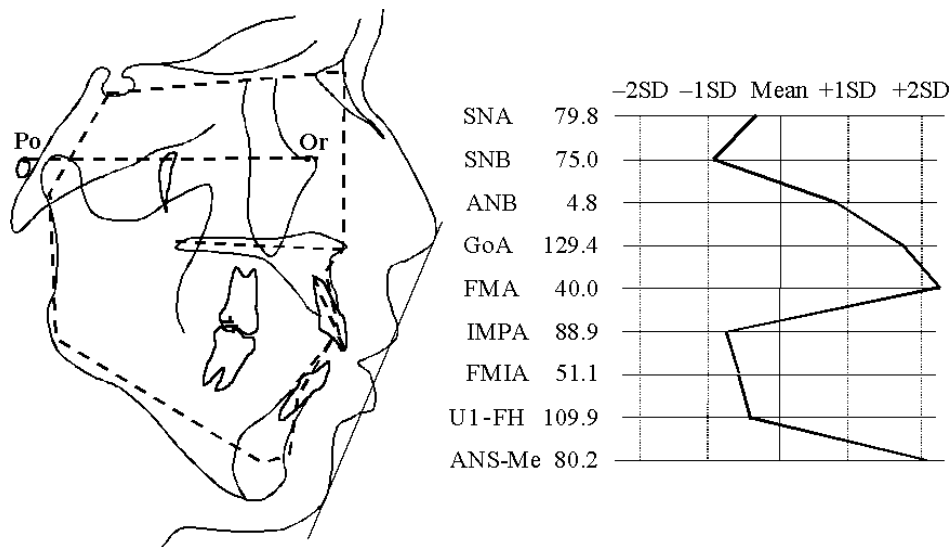


FIGURE 3. Cephalometric tracing before treatment.

second molars except the upper right first molar had undergone endodontic treatment.

The cephalometric analysis indicated the features of a skeletal open bite (Figure 3). The mandibular plane and gonial angles were larger than those of the Japanese controls.<sup>4</sup> The mandible exhibited a backward and downward rotation; consequently, the lower anterior facial height was larger than normal. The inclinations of the maxillary and mandibular incisors were within the normal range.

From these findings, this case was diagnosed as a skeletal open bite with a long lower anterior facial height. The treatment plan for this case was as follows. A transpalatal arch was to be used to avoid molar extrusion during treatment. The maxillary second and mandibular third molars and the maxillary and mandibular second premolars were extracted bilaterally. Multibracket appliances were placed on both dentitions for tooth alignment. The maxillary and mandibular molars were moved mesially to induce a counterclockwise mandibular rotation. Retention was planned using lingually bonded retainers in both dentitions.

### Treatment progress

A transpalatal arch was placed on the upper arch, and the upper second and the lower third molars were extracted. Furthermore, the upper and lower second premolars were extracted and orthodontic treatment was initiated with a multibracket appliance. The maxillary and mandibular second premolar spaces were planned so as to use half of the extraction site for the anterior crowding and the other half to move the molars mesially. A leveling of the maxillary arch preceded that of the mandibular arch. After the leveling of the maxillary arch, the first premolars were retracted with labial elastics on a plain stiff 0.016 × 0.022-inch wire (Figs. 1–4). With respect to the lower arch, the initial arch was a 0.016 × 0.016-inch wire, and the retraction of

the first premolars and the mesial movements of molars were started simultaneously with labial elastics (Figs. 1–4). After nine months, the original open bite was almost closed by the reduction of posterior height accompanied with the extraction of the upper second molars and the mesial movement of molars without the aid of vertical elastics (Figs. 2–4). The placement of brackets on the lower incisors was then performed. After two years of orthodontic treatment, a well-balanced face and an acceptable occlusion were achieved and the multibracket appliances were removed. Immediately after the removal, lingually bonded retainers were placed on both dentitions.

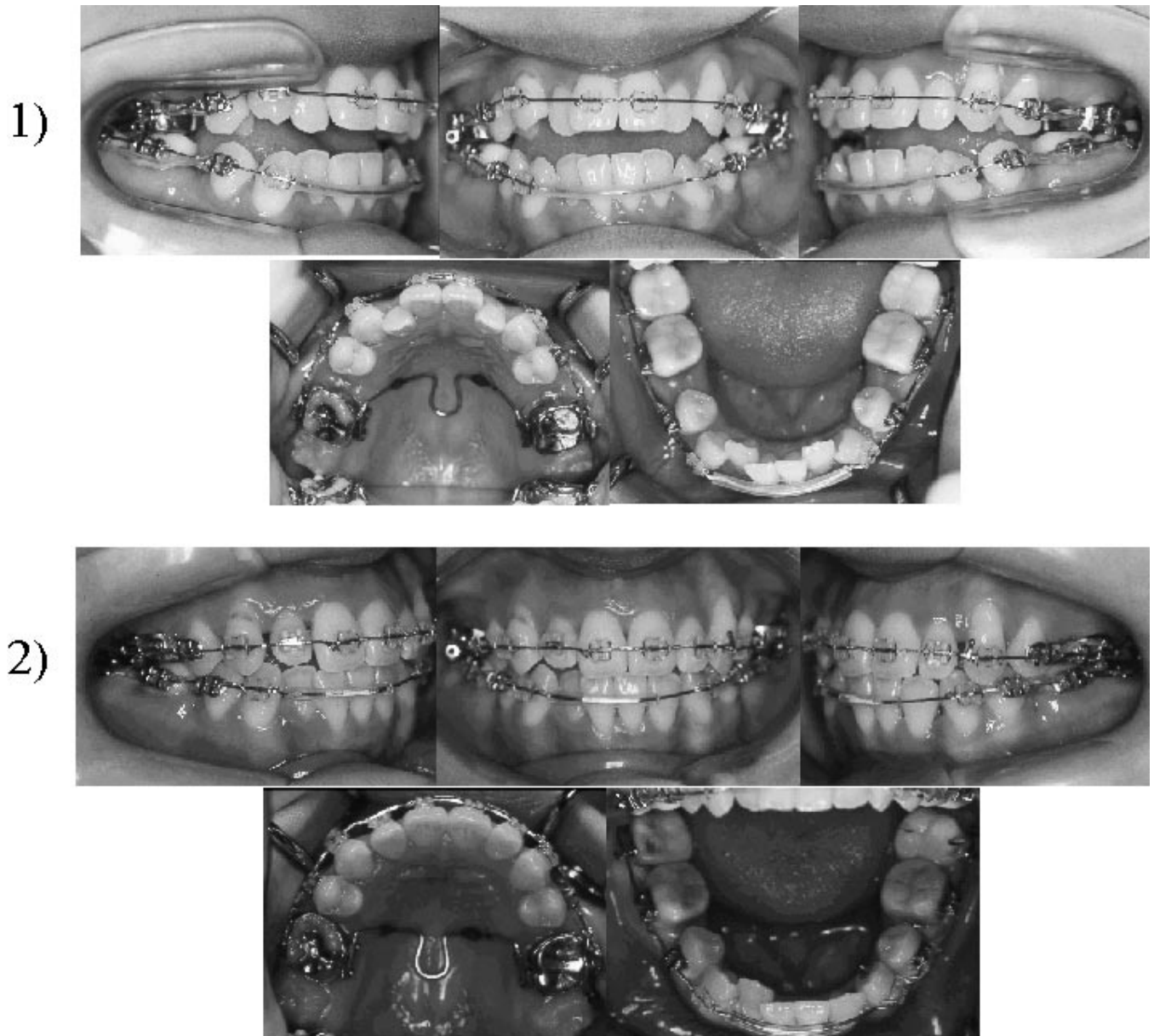
### Treatment results

Facial photographs showed that overall facial balance was improved (Figure 5). The lower anterior facial height was decreased, and the lips showed less tension in lip closure. Acceptable occlusion was achieved, and the overbite was improved to 1.2 mm and the overjet to 1.5 mm (Figure 5). The molar relationships were changed to Class I on both sides. Panoramic radiograph showed no or less root resorption (Figure 6). Cephalometric analysis indicated a counterclockwise rotation of the mandible (Figure 7). The lower anterior facial height (ANS-Me) was decreased to 77.5 mm. The inclinations of the upper and lower central incisors still remained within the normal range. From the superimposition of maxilla and mandible, the mesial movement of molars and the retraction of anterior teeth occurred with no or less molar intrusion or incisor extrusion (Figure 7).

Three years after retention, an acceptable occlusion was maintained without recurrence of the anterior open bite, indicating a long-term stability of the occlusion (Figure 8).

### DISCUSSION

Skeletal open bite is regarded as one of the complicated malocclusions, and its treatment planning depends on the



**FIGURE 4.** Intra-oral photographs during treatment. Onset of mesial movement of molars with labial elastics. Achievement of open bite correction without vertical elastics.

severity of the skeletal discrepancies, which occasionally requires surgical correction. Kim<sup>5</sup> proposed the multiloop edgewise archwire (MEAW) technique for open-bite treatment without surgery. This technique is available for the correction of open bites in terms of uprighting the posterior teeth leading to the correction of the cant of occlusal plane and the posterior discrepancy. Kim et al<sup>6</sup> evaluated the treatment effects of the MEAW therapy in open-bite correction and reported that the overbite increased by approximately four mm on average in adult patients with open bite. However, they demonstrated that the open-bite correction was achieved as much by dentoalveolar changes as by extrusion of the upper and lower incisors, slight intrusion

of the upper molars and an uprighting movement of the posterior teeth. Skeletal changes were not found. This indicates that counterclockwise mandibular rotation leading to reduction of lower facial height is not produced by a MEAW technique. Therefore, we did not use the MEAW technique and treated the patient by means of second premolar extraction to reduce the lower anterior facial height.

From the cephalometric analysis, extrusion of the upper and lower incisors and intrusion of both the molars were negligible in the present case. Nevertheless, the overbite increased by 4.2 mm. A counterclockwise rotation of the mandible occurred during treatment, and the mandibular plane angle (FMA) varied from 40.0° to 37.1°. These

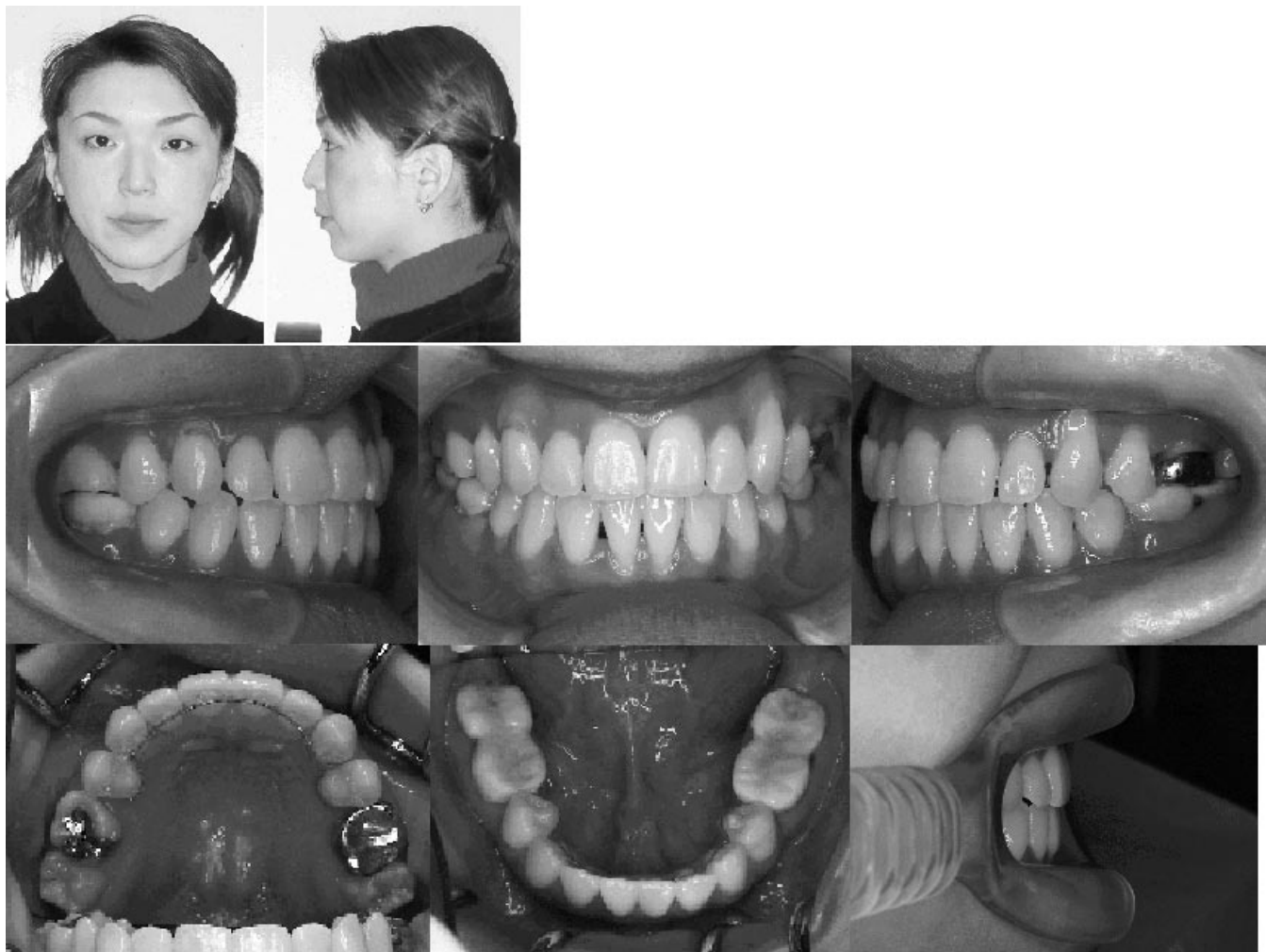

FIGURE 5. Facial and intra-oral photographs after treatment (26-year eight-month-old).

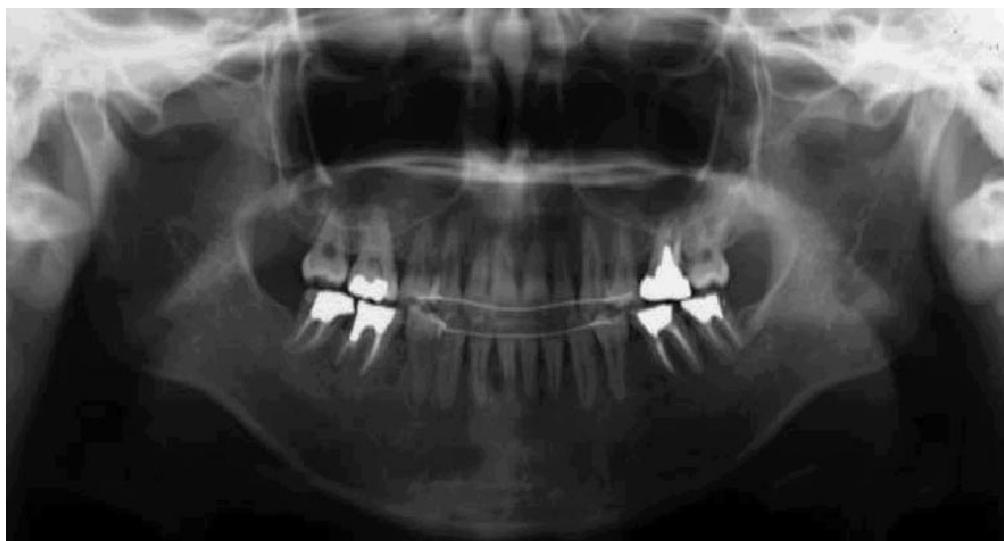


FIGURE 6. Panoramic radiograph after treatment (26-year eight-month-old).

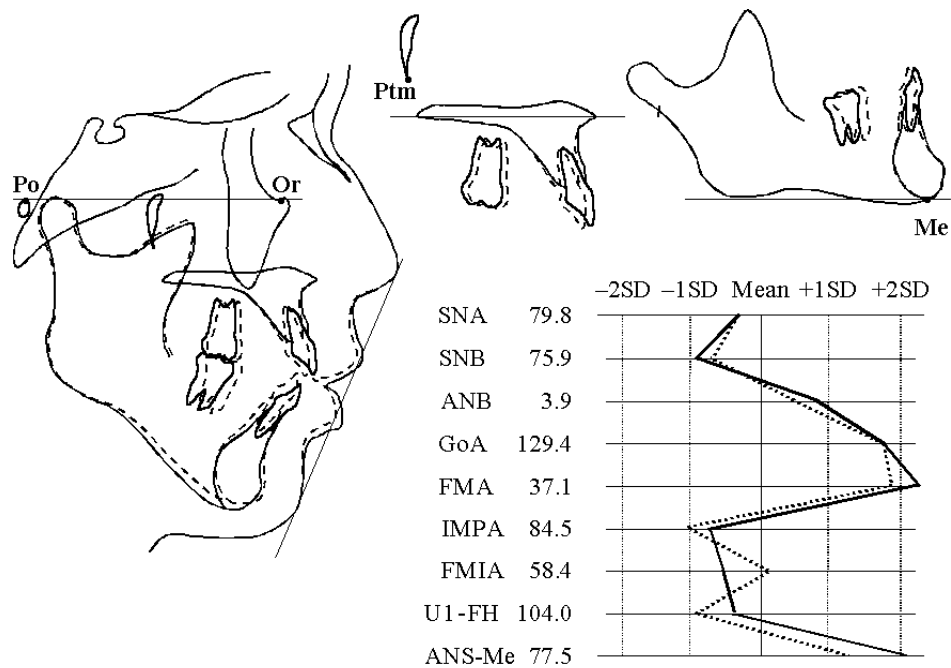


FIGURE 7. Superimposition of cephalometric tracings before (solid line) and after (dotted line) treatment.

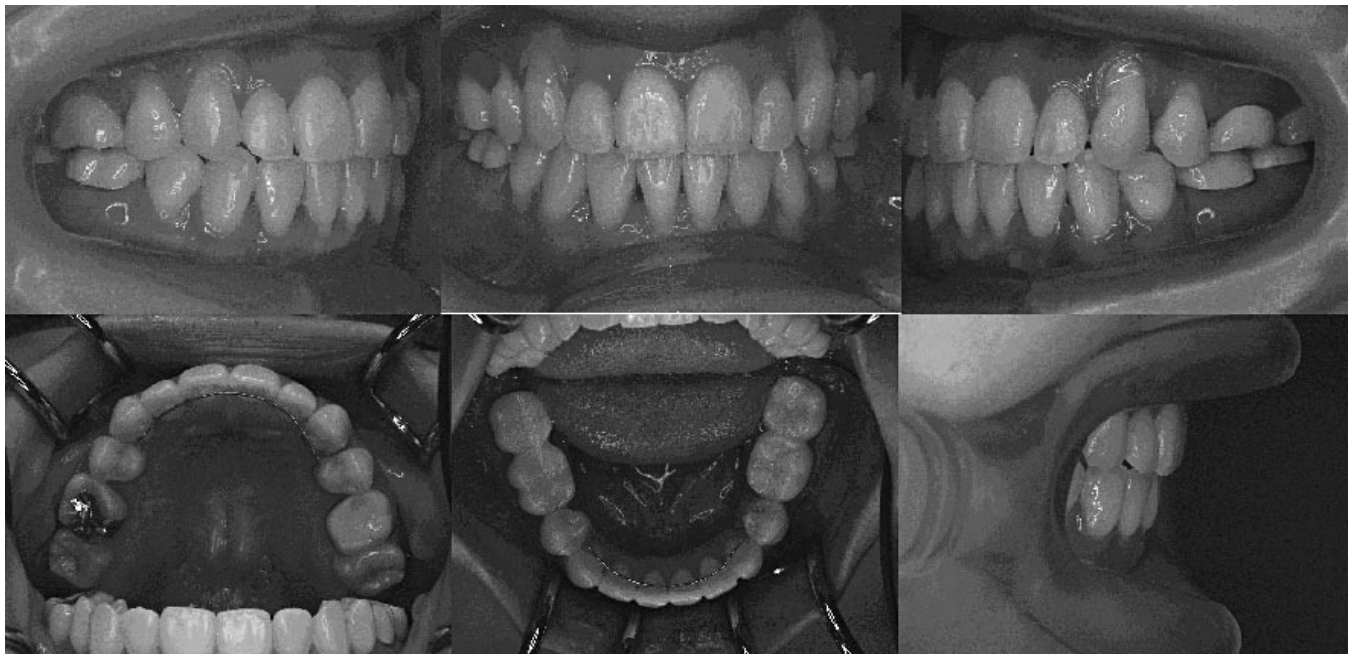


FIGURE 8. Intra-oral photographs three years after treatment.

changes were due to the extraction of the second premolars and the mesial movements of molars. In addition, the extraction of the upper second molars could help reducing vertical dimension during treatment. In the cases using the SAS for open-bite correction, the average amounts of intrusion were 1.7 mm in the lower first molar and 2.8 mm in the lower second molar<sup>8</sup> and the mandibular plane angle decreased to 3–5°.<sup>1</sup> The change of the mandibular plane

angle in the present case was almost similar to that with the use of SAS. Furthermore, the present case showed a stable occlusion without relapse of the open bite even three years after retention. Meanwhile, with SAS, the average relapse rates of intrusion were approximately 27–30% at the lower molars.<sup>7</sup> Kim et al<sup>6</sup> also reported that the average relapse in the overbite during two-year retention was 0.35 mm for adult patients with open bite treated with the MEAW

technique. Therefore, the amount of molar intrusion and incisor extrusion during treatment may be an important factor for prediction of relapse.

External apical root resorption is a multifactorial problem encountered in all disciplines of dentistry and one of the most common complications of orthodontic treatment. Force magnitude and direction have been suggested as an important factor and intrusion with continuous forces is most likely to exacerbate external apical root resorption.<sup>8,9</sup> In the present case, apical root resorption was not found throughout the treatment period because molar intrusion was not necessary to correct skeletal open bite.

Meanwhile, Costopoulos and Nanda<sup>10</sup> indicated that intrusion with low forces can be effective for correction of open bite whereas causing only a negligible amount of apical root resorption. This assumption has, therefore, been controversial. Actually, mandibular molar intrusion is most effective for correction of skeletal open bite and further information about the association between root resorption and tooth intrusion will be absolutely necessary.

In conclusion, an adult patient with a skeletal open bite and a large lower anterior facial height was treated by means of second premolar extraction to achieve stable occlusion with a well-balanced face. During treatment, the overbite increased by counterclockwise rotation of the mandible with no or less molar intrusion or incisor extrusion. Furthermore, the long-term stability of the occlusion was obtained. During treatment in patients with skeletal open bite, it is prudent for orthodontists to obtain stable occlusion without the relapse of open bite. The present case provides an insight into an assumption that the amount of molar intrusion and incisor extrusion during treatment may be an important factor for prediction of relapse.

## REFERENCES

1. Umemori M, Sugawara J, Mitani H, Nagasaka H, Kawamura H. Skeletal anchorage system for open-bite correction. *Am J Orthod Dentofacial Orthop.* 1999;115:166–174.
2. Daimaruya T, Takahashi I, Nagasaka H, Umemori M, Sugawara J, Mitani H. Effects of maxillary molar intrusion of the nasal floor and tooth root using the skeletal anchorage system in dogs. *Angle Orthod.* 2003;73:158–166.
3. Logan LR. Second premolar extraction in Class I and Class II. *Am J Orthod Dentofacial Orthop.* 1973;63:115–146.
4. Wada K, Otani S, Sakuda M. Morphometric analysis in maxillary protrusion [in Japanese]. In: Yamauchi K, Sakuda M, eds. *Maxillary Protrusion*. Tokyo: Ishiyaku; 1989:95–130.
5. Kim YH. Overbite depth indicator and its treatment with multiloop edgewise archwire. *Angle Orthod.* 1987;57:290–321.
6. Kim YH, Han UK, Lim DD, Serranon ML. Stability of anterior openbite correction with multiloop edgewise archwire therapy: a cephalometric follow-up study. *Am J Orthod Dentofacial Orthop.* 2000;118:43–54.
7. Sugawara J, Baik UB, Umemori M, Takahashi I, Nagasaka H, Kawamura H, Mitani H. Treatment and posttreatment dentoalveolar changes following intrusion of mandibular molars with application of a skeletal anchorage system (SAS) for open bite correction. *Int J Adult Orthod Orthognath Surg.* 2002;17:243–253.
8. Faltin RM, Arana-Chavez VE, Faltin K, Sander FG, Wichelhaus A. Root resorptions in upper first premolars after application of continuous intrusive forces. Intra-individual study. *J Orofac Orthop.* 1998;59:208–219.
9. Parker RJ, Harris EF. Directions of orthodontic tooth movements associated with external apical root resorption of the maxillary central incisor. *Am J Orthod Dentofacial Orthop.* 1998;114:677–683.
10. Costopoulos G, Nanda R. An evaluation of root resorption incident to orthodontic intrusion. *Am J Orthod Dentofacial Orthop.* 1996;109:543–548.