

Nonextraction Treatment of Upper Canine–Premolar Transposition in an Adult Patient

Shingo Kuroda^a; Yasuko Kuroda^b

Abstract: This article reports the successful treatment of a unilateral maxillary canine and first premolar transposition without the extraction of the premolar in an adult patient. A female patient, 21 years and three months of age, had moderate crowding in the upper arch with complete transposition of the canine and first premolar. After distal movement of the upper molars with a lingual arch and headgear appliance, the upper left first premolar and canine were transposed. Thirty-eight months after the placement of preadjusted appliances, the transposed canine and premolar were reordered in the proper positions. The total active treatment period was 49 months. After two years of retention, the occlusion is generally stable. (*Angle Orthod* 2005;75:472–477.)

Key Words: Nonextraction; Canine; Adult patient; Transposition

INTRODUCTION

Transposition of maxillary teeth is a disturbance of tooth order and eruptive position occurring in one of 300 orthodontic patients, and canine-premolar transposition is observed with the most frequency.^{1–3} In nonextract treatment, especially in adult patients, canine-premolar transpositions are usually best managed by keeping the transposed order. Attempts at restoring the natural tooth order usually lead to a prolonged treatment period with less than adequate results due to the difficulties in root movement.^{1,2,4} However, the lingual cusp of the premolar sometimes creates a functional interference if the transposed order of two teeth is maintained. A few attempts to move the transposed canine and premolar into their proper position have been tried.^{2,5–7} However, there are few reports of correcting canine-premolar transposition into ideal order using multibracket appliances without extraction of the premolar in adult patients. This case report demonstrates the successful treatment of a unilateral upper canine and first premolar transposition, without extraction of the premolar in an adult patient.

Case histories

A female patient, 21 years and three months of age, came to the clinic (Figure 1). The patient's chief complaint was a high canine. She strongly desired nonextraction treatment except for the third molars. She showed a straight profile and a symmetrical frontal view. Severe crowding was present in the upper arch because of the mesial displacement of the left molars and labial dislocation of the canine. Slight gingival recession was found around the upper left canine. With respect to the facial midline, the upper dental midline deviated 1.5 mm to the left and the lower midline deviated 3.0 mm, also to the left.

When compared with the Japanese norm,⁸ the cephalometric analysis showed a skeletal Class II relationship (Figure 2; Table 1). The molar relationships were Angle Class I on the right side and Class II on the left side. There were no symptoms of temporomandibular disorder on examination using a jaw movement recording system (Sirognathograph analyzing system, Tokyo Shika Industry, Tokyo, Japan).

Diagnosis and treatment objectives

The patient was diagnosed as having Angle Class II malocclusion, with a skeletal Class II jaw base relationship with moderate crowding in the upper arch. The treatment objectives were (1) to correct the Class II molar relationships, crowding, and midline deviation while maintaining an ideal overjet and overbite; (2) to achieve acceptable occlusion with a good functional Class I occlusion; and (3) to maintain the straight facial profile.

Because the molar Class II relationship suggested a prior mesial movement of the upper left molars, we planned dis-

^a Assistant Professor, Department of Orthodontics and Dentofacial Orthopedics, Graduate School of Medicine and Dentistry, Okayama University, Okayama, Japan.

^b Private Practice, Osaka, Japan.

Corresponding author: Shingo Kuroda, DDS, PhD, Department of Orthodontics and Dentofacial Orthopedics, Okayama University Graduate School of Medicine and Dentistry 2-5-1, Shikata-Cho, Okayama, Okayama 700-8525, Japan
(e-mail: shinkrd@md.okayama-u.ac.jp)

Accepted: June 2004. Submitted: May 2004.

© 2005 by The EH Angle Education and Research Foundation, Inc.

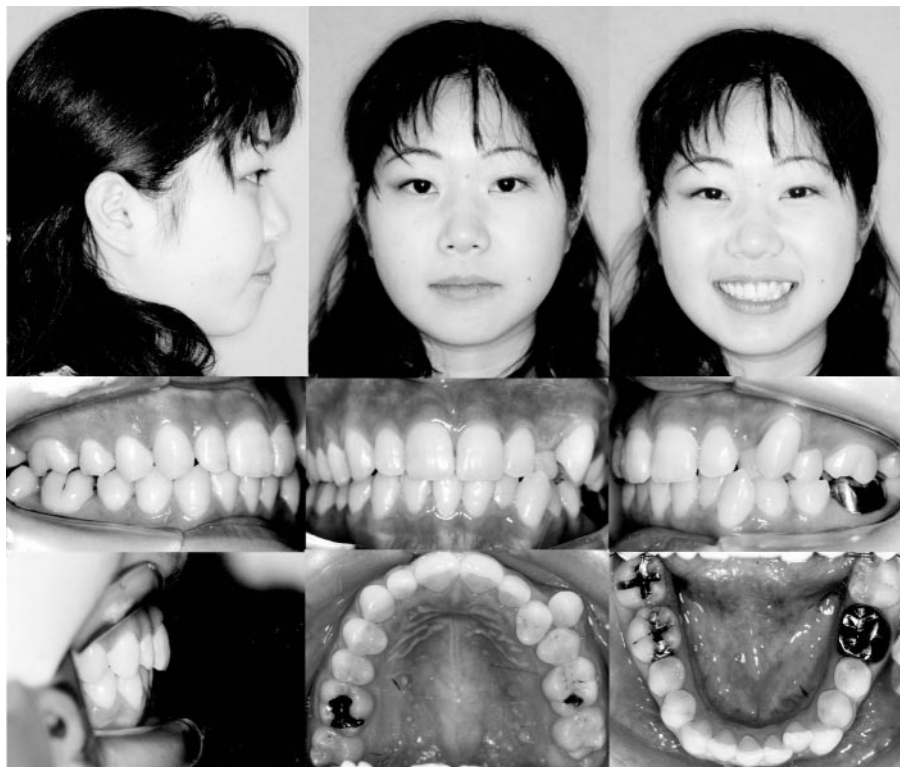

FIGURE 1. Pretreatment photographs (age, 21 years three months).

tal movement of the upper molars after extraction of the third molars. The gained spaces would be used to correct the crowding, including the canine-premolar transposition and midline deviation.

Treatment progress

Before the start of treatment, the upper and lower third molars were extracted. A distal extension lingual arch appliance and a face-bow type headgear appliance were placed between the first molars to distalize the upper molars. A 0.018-inch slot preadjusted edgewise appliance was placed in both arches.

The upper left first premolar was retracted palatally and distally using the lingual arch appliance and elastic chains (Figure 3A,B). The upper left canine was moved palatally and mesially with the edgewise appliance and a Nickel-Titanium open coil spring (Figure 3C). After the palatal movement of the premolar, a 0.017 × 0.025-inch sectional archwire was overlaid between the upper left central incisor and the first molar to control the torque of the first premolar and to avoid the root interference (Figure 3D).

Twenty-eight months after the placement of the preadjusted appliances, the transposed canine and premolar were corrected in the proper order (Figure 3E). After removal of the edgewise appliances, a wraparound retainer and a 3 × 3 lingual bonded retainer were placed to retain both arches. The total active treatment period was 49 months. Improved root coverage with mucogingival surgery was recommend-

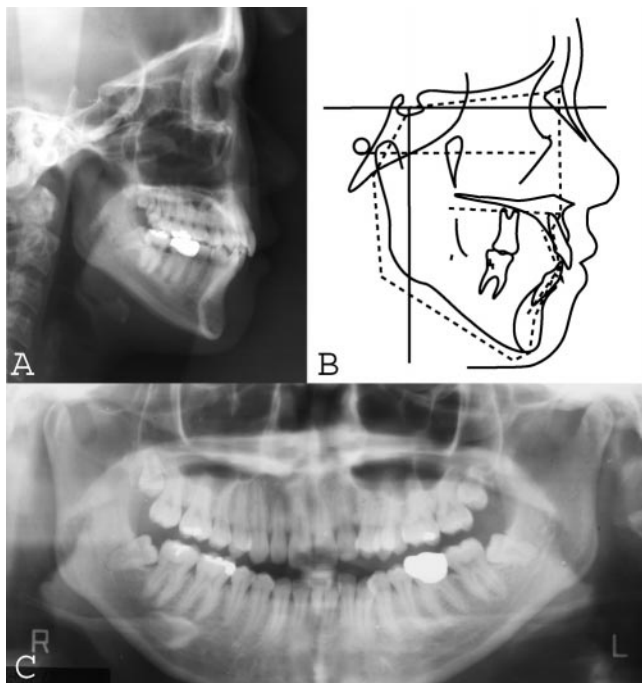
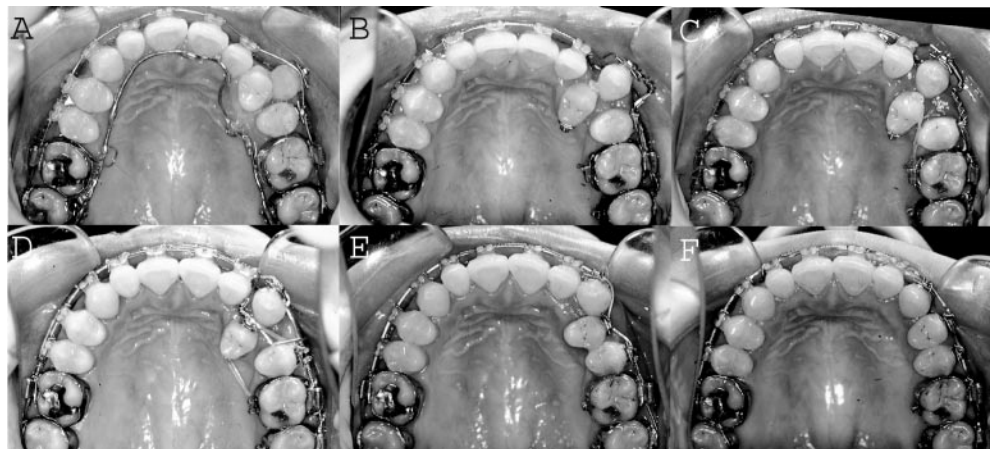


FIGURE 2. (A) Pretreatment cephalograph. (B) Tracing. (C) Panoramic radiograph. Tracing (solid lines) was superimposed with the mean profilogram (dotted line).

TABLE 1. Cephalometric Summary

Variables	Mean	SD	Pretreatment	Postactive Treatment	Two-year Postretention
Angle (°)					
ANB	2.8	2.44	5.5	6.0	6.0
SNA	80.8	3.61	82.5	82.5	82.5
SNB	77.9	4.54	77.0	76.5	76.5
Mp-FH	30.5	3.60	35.0	36.5	36.5
Gonial.A	122.1	5.29	130.0	130.0	130.0
U1-NF	115.0	6.99	113.5	112.0	112.5
L1-Mp	93.4	6.77	92.0	94.5	94.5
IIA	123.6	10.64	126.0	125.0	124.5
Occlusal.P	16.9	4.40	23.5	27.0	27.0
Liner (mm)					
S-N	67.9	3.65	69.5	69.5	69.5
N-Me	125.8	5.04	122.0	121.5	121.5
Me/NF	68.6	3.71	68.5	68.5	68.5
Go-Me	71.4	4.14	70.0	70.0	70.0
Ar-Me	106.6	5.74	107.0	106.5	106.5
OJ	3.1	1.07	4.0	3.0	3.0
OB	3.3	1.89	3.0	3.0	3.0
U1/NF	31.0	2.34	30.0	32.0	32.0
U6/NF	24.6	2.00	25.0	24.0	24.0
L1/Mp	44.2	2.68	44.0	23.5	23.5
L6/Mp	32.9	2.50	33.0	35.0	35.0

**FIGURE 3.** Photographs taken during the treatment progress. (A) Starting of the transposition. (B) Six months later. (C) Twelve months later. (D) Twenty-four months later. (E) Twenty-eight months later. (F) Thirty-eight months later.

ed to the patient during the retention phase, but she declined this treatment.

Results achieved

The posttreatment facial photograph with smile showed an esthetic improvement compared with the pretreatment photograph (Figure 4). Because of good patient cooperation, an acceptable facial profile was maintained.

Posttreatment cephalometric evaluation did not show a significant change in skeletal relationships. An Angle Class I molar relationship was achieved on both sides. Upper and lower incisors were maintained in their anterior-posterior

positions (Figure 5; Table 1), the occlusion was generally stable, and an ideal intercuspation of the teeth was achieved. The gingival recession around the upper right canine was not increased. The roots of the transposed canine and first premolar were corrected completely to their proper positions (Figure 5). Slight root resorption was observed in the upper right lateral incisor, the upper left central incisor, lateral incisor, and canine (Figure 5). After active orthodontic treatment, Class I canine relationships were achieved on both sides, and no functional problems were observed in the jaw movement examination.

After two years of retention, the occlusion is stable and

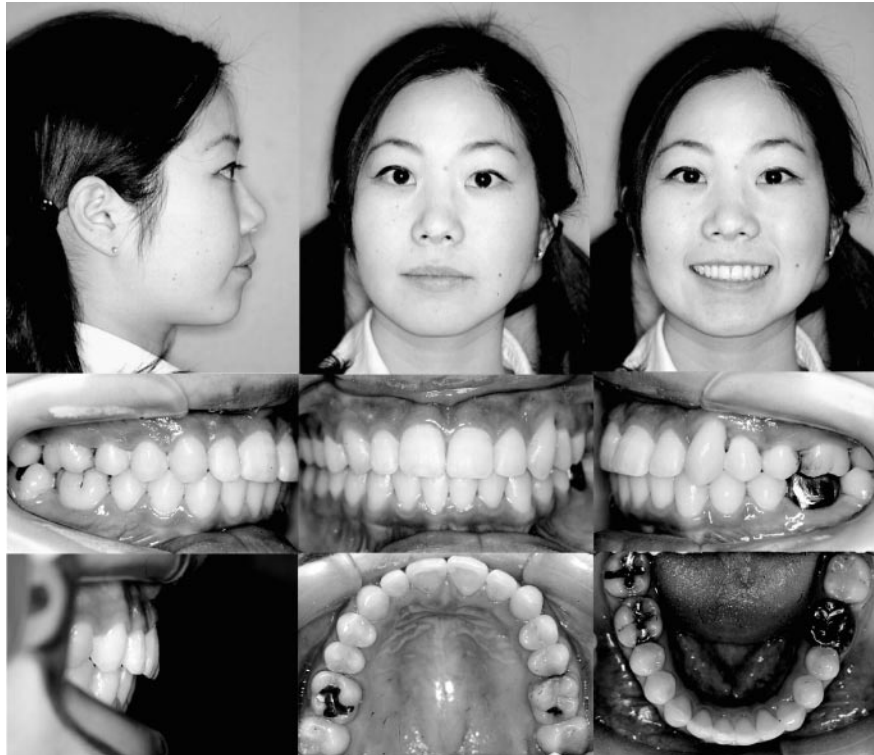


FIGURE 4. Postactive treatment photographs (age, 25 years eight months).

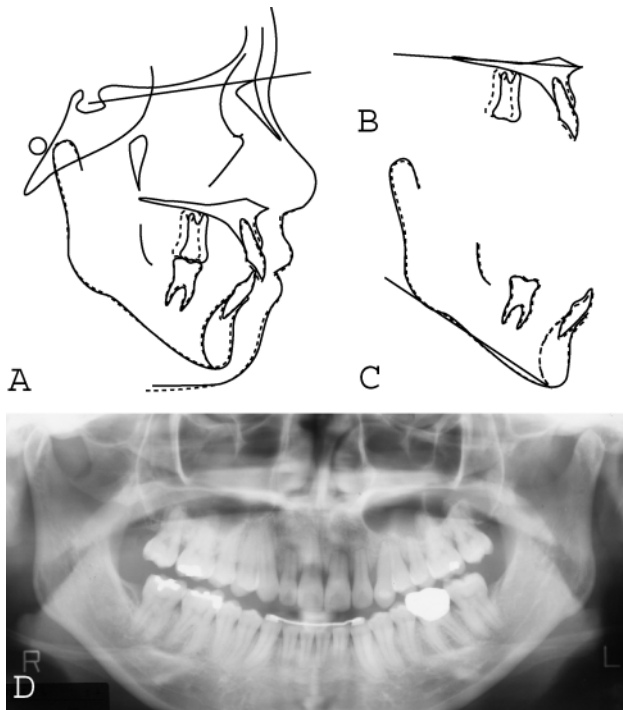


FIGURE 5. (A)–(C) Superimposition of cephalometric tracings made before (solid line) and after (dotted line) treatment. (A) Superimposition on the sella-nasion plane at sella. (B) Superimposition on the palatal plane at ANS. (C) Superimposition on the mandibular plane at Menton. (D) Panoramic radiograph at postactive treatment.

a good facial profile has also been retained (Figure 6). The cephalometric analysis showed few changes (Table 1).

DISCUSSION

Upper canine-premolar transposition in adult patients allows consideration of several treatment options, with or without extraction of the premolar. In nonextraction treatment, it is generally preferable to maintain the transposed teeth in their original order because attempts at restoring the natural tooth position usually lead to a prolonged treatment.^{1,2,4} However, the upper canine-premolar transposed order provides esthetic and functional considerations. The differences in the size, shape, and tooth color between canine and premolar sometimes cause anterior esthetic problems. The gingival counter of the premolar is lower relative to the canine, and this may require a periodontal gingival recontouring procedure. These esthetic problems may be compromised, however, the palatal cusp of the transposed premolar might be a functional interference despite control of its angulations, torques, and reshaping. Prosthetic restoration after pulpectomy will be necessary if the size and shape of premolar are completely recontoured to resemble a canine.

Treatment with premolar extraction is considered one of the alternatives.¹ Extraction of the upper left first premolar in this case would shorten the treatment period without esthetic and functional considerations mentioned above. However, in this case, the patient strongly desired a nonex-

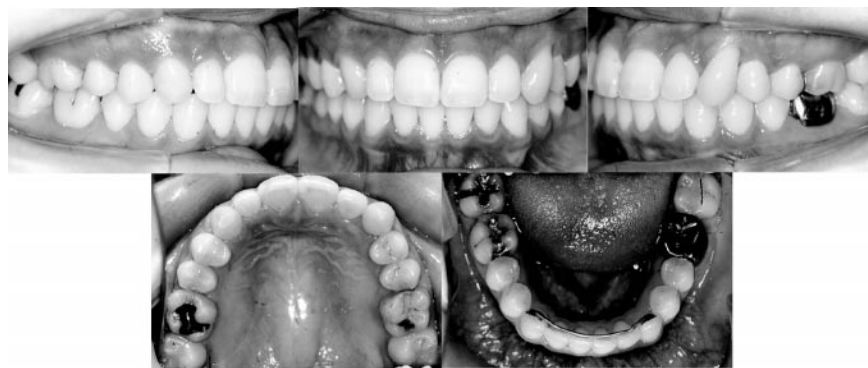

FIGURE 6. Two-year postretention photographs (age, 27 years eight months).

traction treatment. Therefore, we planned distalization of the upper molars and correction of tooth order despite the need for long-term treatment. The patient's cooperation was quite good with the headgear and intraoral elastics. Therefore, we could make the space required for correcting the tooth order without extraction of a premolar.

Several attempts to move transposed teeth into their proper positions have previously been reported.^{1,2,5-7,9,10} In adult patients with complete lateral-canine transposition, 45 or 49 months were required to restore transposed teeth to the natural order.^{9,10} Root interference during tooth movement to correct tooth order tends to occur more frequently in canine-premolar transposition than in lateral-canine transposition. This probably occurs because the labiolingual width of a premolar is much wider than that of the lateral incisor. We had to retract the first premolar palatally with bodily movement to avoid root interferences. In addition, we also had to consider gingival recession around the labial displaced canine. Alignment spaces had to be made before starting to correct the tooth order, and the canine was carefully moved in a palatal and mesial direction to prevent bone loss at the cortical plate and to increase the gingival recession. Therefore, the treatment period of 49 months may have been appropriate in this case without premolar extraction.

It is necessary to consider a risk of root resorption if the transposed teeth are moved to their proper position. The risk is entailed not only to the transposed teeth but also to the adjacent teeth because they are used as anchorage teeth for correcting the tooth order with complicated mechanics. In addition, previous studies suggest that duration of treatment was the factor highly correlated with root resorption.¹¹⁻¹³ In this case, slight root resorption was observed in both the transposed canine and the upper incisors. The position of upper incisors were not changed in comparison with cephalometric tracings, however, the incisors might have been loaded with excessive force during the tooth transposition phase.

Recently, to obtain absolute anchorage, dental implants, titanium screws, and miniplates have been used, and these can achieve various tooth movements.¹⁴⁻¹⁶ The teeth would

have been able to move easily with simple mechanics if these absolute anchorages had been used in this case, ie, a palatal screw implant would have facilitated movement of the transposed premolar palatally with bodily movement or to move the left molars distally with en masse movement. Consequently, the treatment period would be shortened, and it might also reduce the risk of root resorption. The common reasons for hesitating in the decision to restore transposed teeth into their proper positions is consideration for the prolonged treatment period and need for complicated mechanics.^{1,2,4} Therefore, treatment to move the transposed teeth to their original order might be increased by using absolute anchorages.

REFERENCES

1. Shapira Y, Kufnec MM. Tooth transpositions—a review of the literature and treatment considerations. *Angle Orthod.* 1989;59:271–276.
2. Peck S, Peck L. Classification of maxillary tooth transpositions. *Am J Orthod Dentofacial Orthop.* 1995;107:505–517.
3. Shapira Y, Kufnec MM. Maxillary tooth transpositions: characteristic features and accompanying dental anomalies. *Am J Orthod Dentofacial Orthop.* 2001;119:127–134.
4. Sato K, Yokozeki M, Takagi T, Moriyama K. An orthodontic case of transposition of the upper right canine and first premolar. *Angle Orthod.* 2002;72:275–278.
5. Bocchieri A, Braga G. Correction of a bilateral maxillary canine-first premolar transposition in the late mixed dentition. *Am J Orthod Dentofacial Orthop.* 2002;121:120–128.
6. DeMarius U, DeNuccio C. Transposition: therapeutic considerations. Part II. *Mondo Orthod.* 1985;10:51–57.
7. Mollin AD. Transposition of teeth. *Quintessence Int.* 1977;12:45–51.
8. Wada K, Matsushita K, Shimazaki S, Miwa Y, Hasuike Y, Susami R. An evaluation of a new case analysis of a lateral cephalometric roentgenogram. *J Kanazawa Med Univ.* 1981;6:60–70.
9. Shapira Y, Kufnec MM. A unique treatment approach for maxillary canine-lateral incisor transposition. *Am J Orthod Dentofacial Orthop.* 2001;119:540–545.
10. Maia FA. Orthodontic correction of a transposed maxillary canine and lateral incisor. *Angle Orthod.* 2000;70:339–348.
11. Taithongchai R, Sookkorn K, Killiany DM. Facial and dentoalveolar structure and the prediction of apical root shortening. *Am J Orthod Dentofacial Orthop.* 1996;110:296–302.
12. Vlaskalic V, Boyd RL, Baumrind S. Etiology and sequelae of root resorption. *Semin Orthod.* 1998;4:124–131.

13. Sameshima GT, Sinclair PM. Predicting and preventing root resorption: part II. Treatment factors. *Am J Orthod Dentofacial Orthop.* 2001;119:511-515.
14. Roberts WE, Helm FR, Marshall KJ, Gongloff RK. Rigid endosseous implants for orthodontic and orthopedic anchorage. *Angle Orthod.* 1989;59:247-256.
15. Umemori M, Sugawara J, Mitani H, Nagasaka H, Kawamura H. Skeletal anchorage system for open-bite correction. *Am J Orthod Dentofacial Orthop.* 1999;115:166-174.
16. Kuroda S, Katayama A, Takano-Yamamoto T. Severe anterior open-bite case treated using titanium screw anchorage. *Angle Orthod.* 2004;74:558-567.