

# Surgically Assisted Rapid Maxillary Expansion Compared with Orthopedic Rapid Maxillary Expansion

Ayşe T. Altug Atac<sup>a</sup>; Hakan A. Karasu<sup>b</sup>; Duygu Aytac<sup>c</sup>

**Abstract:** The objective of this study is to evaluate and compare the dental and skeletal changes occurring during orthopedic rapid maxillary expansion (RME) and surgically assisted RME during the active phase of treatment. The study was divided into two groups. The first group of 10 patients (six males, four females; mean age, 15.51 years) received orthopedic RME. The second group of 10 patients (seven males, three females; average age: 19.01 years) received surgically assisted RME (SARME). All patients underwent maxillary expansion with occlusal-coverage Hyrax-type expanders activated two turns a day (0.25 mm per turn). Preexpansion and postexpansion lateral and posteroanterior cephalograms were obtained for each patient. Statistically significant differences between the SARME and RME groups were found in the N-ANS, SN/PP ( $P < .01$ ) and SNA, SNB, mandibular dentoalveolar, and maxillary bony base ( $P < .05$ ) measurements. Clinically, there is no difference in patient response between the RME and SARME groups. The only difference between the groups was their indication for RME or SARME, which is based on the age and skeletal maturation of the patient. (*Angle Orthod* 2006;76:353–359.)

**Key Words:** Transverse deficiency; Surgically assisted rapid maxillary expansion; Rapid maxillary expansion

## INTRODUCTION

Rapid maxillary expansion (RME) is a common treatment modality for younger patients in the correction of a maxillary transverse deficiency. RME was proposed for nasal problems in the 19th century by Angell.<sup>1</sup> The concept was reintroduced by Haas<sup>2</sup> in 1961.

In children and adolescents, conventional orthodontic RME has been successful when used before sutural closure. On the other hand, in skeletally mature patients, the possibility of successful maxillary expansion decreases as sutures close and the resistance to mechanical forces increases. Transverse maxillary

growth significantly slows, and the maxillary sutures close around 14 to 15 years of age in females and 15 to 16 years of age in males.<sup>3</sup>

After sutural closure or completion of transverse growth, orthopedic transverse maxillary expansion is largely unsuccessful because the expansion is primarily composed of alveolar or dental tipping with little or no basal skeletal movement.<sup>4</sup> In mature patients, RME also causes severe pain, periodontal complications, and gingival recession of the maxillary posterior teeth.<sup>5,6</sup> Surgically assisted RME (SARME) has been proposed to produce better treatment results in adults and to prevent complications by surgically releasing the closed sutures resisting the expansion forces.<sup>4</sup> Brown first described SARME in 1938, performing only a midpalatal split.<sup>7</sup> After a number of years, surgically assisted maxillary expansion with lateral osteotomies only, appeared to be a simpler and more effective procedure.<sup>8–10</sup>

At the present, few reports are available comparing RME and SARME.<sup>11,12</sup> Berger et al<sup>11,12</sup> compared the two treatment modalities, but in their first study, the two groups had different age ranges because of skeletal maturity and only photographic evaluation was performed in their second study. Thus, there is still a need for a determination of the similarities and differences between RME and SARME groups that are at the same skeletal maturity.

<sup>a</sup> Assistant Professor, Department of Orthodontics, School of Dentistry, Ankara University, Ankara, Turkey.

<sup>b</sup> Associate Professor, Department of Oral and Maxillofacial Surgery, School of Dentistry, Ankara University, Ankara, Turkey.

<sup>c</sup> Resident, Department of Oral and Maxillofacial Surgery, School of Dentistry, Ankara University, Ankara, Turkey.

Corresponding author: Dr. Ayşe T. Altug Atac, Ankara University School of Dentistry Orthodontics, Ankara Universitesi, Dis Hekimligi Fakultesi, Ortodonti Anabilim Dalı, Besevler Ankara 06500, Turkey (e-mail: aysealtug@yahoo.com)

Accepted: June 2005. Submitted: April 2005.

© 2006 by The EH Angle Education and Research Foundation, Inc.

The purpose of this study was to evaluate and compare the dental and skeletal changes during the active phase of treatment for both RME and SARME.

## MATERIALS AND METHODS

### Subjects

This study was conducted on 13 male and seven female patients. The subjects were patients from Ankara University, School of Dentistry. The same orthodontic technique and surgical procedure was used for all cases.

The treatment of patients older than 17 years of age ( $n = 6$ ) was started with SARME from the beginning. The treatment of patients who were younger than 17 years of age started with RME initially ( $n = 14$ ). The subjects who had discomfort, pain, and resistance to expansion were then continued with surgical assistance and included in the SARME group ( $n = 4$ ). As a result, the patients were divided into two groups. The first group (SARME group) included 10 patients (seven males and three females) with a mean age of 19.01 years (range, 16.25 to 25.58 years). The second group (RME group) included 10 patients (six males and four females) with a mean age of 15.51 years (range, 13.33 to 17.58 years). The patients in the SARME group have completed 99.51% (minimum: 99.1%, maximum: 100%) of their growth potential, and the patients in the RME group have completed 99.2% (minimum: 98.61%, maximum: 99.8%) of their growth potential.<sup>13</sup> The minimum skeletal age of the patients in the SARME and RME groups was 17 and 15 years, respectively, according to the standards of Greulich and Pyle.<sup>13</sup>

The criteria for selection of both groups for rapid palatal expansion treatment were the presence of a posterior crossbite with skeletal involvement and having no need for future orthognathic surgeries. When the midpalatal suture was still visible in the occlusal radiograph, the expansion was started orthopedically, without surgery. If the nonsurgical RME failed or was associated with significant pain, the expansion continued with surgery without removing the appliance, and those patients were included in the SARME group.

### Orthopedic RME

In this study, RME is used to maximize skeletal expansion over dental expansion.<sup>4</sup> An occlusal-coverage Hyrax-type palatal expander was used to eliminate the premature contacts during expansion. The occlusal coverage was trimmed thin enough to keep the bite opening within 1–1.5 mm. After bonding the appliances, the patients and their parents were instructed to activate the screws one-quarter turn in the morning and another one-quarter turn in the evening.

### Surgically assisted RME

Occlusal-coverage Hyrax palatal expanders, using the same design as the ones in the RME group, were cemented in place before all surgeries.

The surgical interventions were carried out under local anesthesia. The incisions were bilaterally performed at the depth of the vestibule from the first molar area to the distal aspect of the lateral incisor. The mucoperiosteum was elevated, and the maxillary bone exposed from the piriform aperture anteriorly to the pterygomaxillary fissure posteriorly. After identifying the infraorbital nerve, an osteotomy was performed horizontally well above the apices of the teeth from the piriform aperture to the pterygomaxillary fissure. The pterygoid plates were not separated from the maxilla. Anteriorly, the maxilla was separated by malleting a thin osteotome between the central incisors at a level below the anterior nasal spine. The surgical sites were irrigated and sutured. An anterior nasal package and pressure-causing bandage was applied to patients for a day. Antibiotics, analgesic drugs, and oroantral regimen were prescribed for the patients.<sup>4,14</sup>

The screws were activated immediately after surgery in the SARME group and after the bonding in the RME group. The activations were scheduled as two turns per day<sup>15</sup> for two to three weeks, until the necessary amount of expansion was achieved. Upon completion of the expansion, the appliances were left in place for 12 weeks and then removed and replaced by transpalatal arches for the rest of the conventional orthodontic treatment. The expansion progress of a patient in the SARME group is presented in Figure 1.

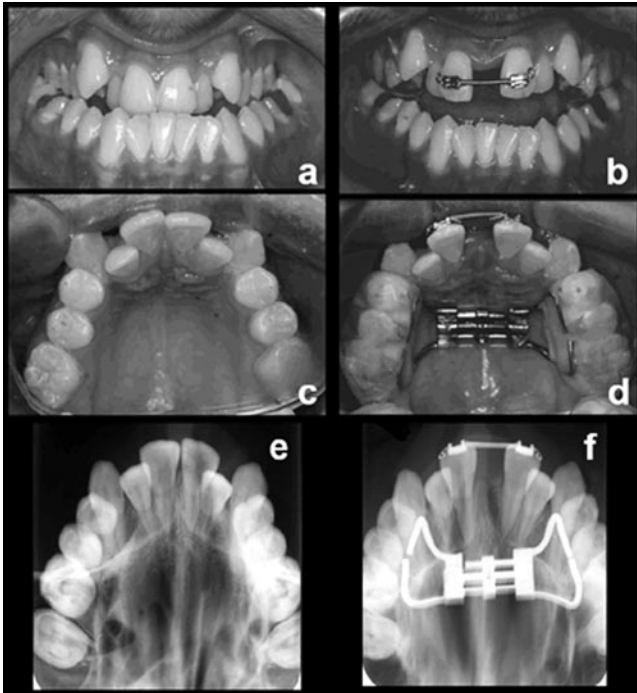
### Cephalometric evaluation

Preexpansion ( $T_1$ ) and postexpansion ( $T_2$ ) lateral, posteroanterior cephalograms and hand-wrist and occlusal films were obtained for each patient. The hand-wrist and occlusal films were used as supporting materials to place the patients into the groups. No fixed appliances were inserted until the postexpansion radiographs were taken, so as not to affect the dentoalveolar measurements.

Measurements were done on lateral (Figure 2) and posteroanterior cephalograms (Figure 3) at  $T_1$  and  $T_2$  for each patient.

### Statistics

The mean values and standard error of means were examined to compare the linear changes both within and between the groups. A paired *t*-test was performed to determine the changes from  $T_1$  to  $T_2$  within each group, and a Student's *t*-test was performed to compare the changes from  $T_1$  to  $T_2$  between SARME and RME groups.



**FIGURE 1.** The medical photograph series of a patient treated with SARME procedure; (a) intraoral frontal photograph before expansion, (b) intraoral frontal photograph after expansion, (c) occlusal photograph before expansion, (d) occlusal photograph after expansion, (e) occlusal radiograph before expansion, and (f) occlusal radiograph after expansion.

### Reliability

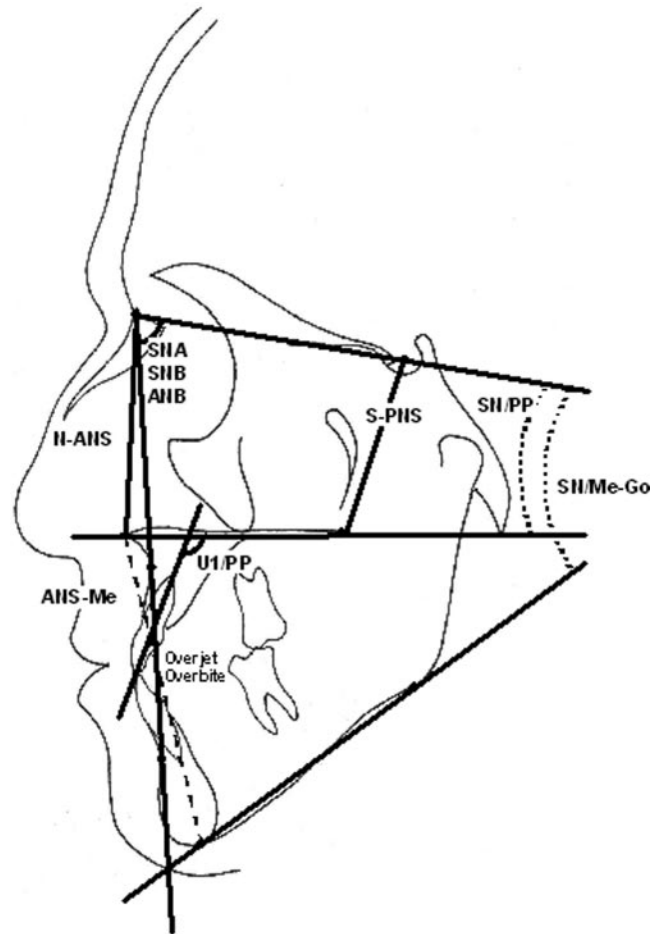
All cephalograms included in the study were retraced 1 month later. No significant mean differences between the two series of records were found, and the reliability coefficients ( $r$ ) ranged between 0.93 and 0.98.

### RESULTS

#### SARME group

**Lateral cephalometric analysis.** A significant decrease was observed in SNB, in a possible relation with the significant increase that occurred in SN/MeGo. The anterior lower face height also increased significantly. The maxillary plane showed a posterior rotation, and anterior upper face height accompanied this rotation with a significant increase. The maxillary incisors were retroclined significantly (Table 1).

**Posteroanterior cephalometric analysis.** The maxillary width increased significantly, and the maxillary posterior segment tilted to the sides ( $MxR/cg/MxL = 3.28^\circ \pm 0.75^\circ$ ). The maxillary molar width also increased significantly, with a significant tipping ( $UmolR/cg/UmolL = 5.54^\circ \pm 0.75^\circ$ ). In addition, the width between the apices of the maxillary incisors also in-



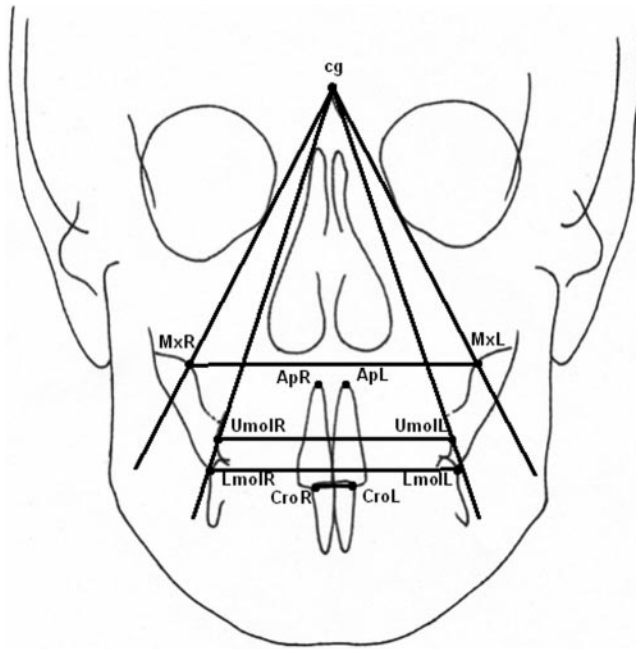
**FIGURE 2.** Lateral cephalometric measurements: SNA, SNB, ANB, N-ANS, SN/maxillary plane, SN/mandibular plane, U1/PP (in degrees), S-PNS, ANS-Me, overjet, and overbite (in mm).

creased, representing a significant expansion of the midpalatal suture (Table 1).

#### Orthopedic maxillary expansion (RME) group

**Lateral cephalometric analysis.** Significant increases were observed in the SNA and ANB ( $P < .05$ ). S-PNS increased significantly, and because of this increase, the maxillary plane showed a significant anterior rotation. ANS-Me also increased significantly without a posterior rotation of the mandible. The overjet, which was negative initially ( $-2.98^\circ \pm 1.30^\circ$ ) increased significantly (Table 2).

**Posteroanterior cephalometric analysis.** The maxillary width increased significantly, and the maxillary posterior segment tilted to the sides ( $MxR/cg/MxL = 1.08^\circ \pm 0.20^\circ$ ). The maxillary molar width also increased significantly, with a significant tipping ( $UmolR/cg/UmolL = 3.91^\circ \pm 0.40^\circ$ ). The width between the apices of the maxillary incisors also increased. Compared with the SARME group, a significant increase in



**FIGURE 3.** Posteroanterior cephalometric measurements: Basal maxillary width (MxR-MxL), the linear distances between the right and left apices of maxillary central incisors (ApR-ApL), incisal midpoints of the crowns of maxillary central incisors (CroR-CroL), maxillary dentoalveolar width (UmoIR-UmoLL), in millimeters; and mandibular dentoalveolar width (LmoIR-LmoLL), the angles between crista galli and maxillary base points (MxR/cg/MxL), maxillary molar points (UmoIR/cg/UmoLL) and maxillary incisors (CroR/cg/CroL), in degrees.

the mandibular molar width was observed in the RME group ( $P < .01$ ) (Table 2).

### Comparison of SARME and RME groups

*Lateral cephalometric analysis.* RME was more effective in the forward displacement of the maxilla, which was represented by an increase in SNA ( $P < .05$ ). SNB increased more in the SARME group than in the RME group ( $P < .05$ ). Another significant difference between the groups was observed in the maxillary plane angulations. In the RME group, a significant anterior rotation of the maxilla was noted, whereas in the SARME group, this rotation was in the posterior direction ( $P < .01$ ). The anterior upper face height accompanied these rotations with a significant increase in the SARME group and a decrease in the RME group ( $P < .01$ ) (Table 3).

*Posteroanterior cephalometric analysis.* The main difference between the two approaches was in the mandibular molar width and in the tipping of the maxillary base. The mandibular molar width increased significantly more in the RME group ( $0.27 \pm 0.43$  mm in SARME,  $1.61 \pm 0.37$  mm in RME) ( $P < .05$ ), whereas the maxillary base was tipped slightly more in the SARME group ( $3.28^\circ \pm 0.75^\circ$  in SARME,  $1.08^\circ \pm 0.20^\circ$  in RME) ( $P < .05$ ). Similarly, the maxillary molars tipped slightly more in the SARME group, but the amount of maxillary molar expansion was very similar between the groups ( $7.81 \pm 1.01$  mm in SARME,  $7.38 \pm 1.01$  mm in RME) (Table 3).

**TABLE 1.** Lateral and Posteroanterior Cephalometric Measurements for SARME Group (Paired *t*-test; \* $P < .05$ , \*\* $P < .01$ )

Parameters	Pre-SARME		Post-SARME		Difference		<i>P</i>
	X	$\pm$ SX	X	$\pm$ SX	D	$\pm$ SD	
<b>Lateral Cephalometric Measurements</b>							
SNA ( $^\circ$ )	75.28	0.94	75.46	0.69	0.18	0.36	
SNB ( $^\circ$ )	75.20	1.32	74.27	1.23	-0.93	0.34	*
ANB ( $^\circ$ )	0.08	0.67	1.19	0.58	1.11	0.59	
N-ANS (mm)	57.50	0.97	58.71	0.81	1.21	0.28	**
S-PNS (mm)	47.04	1.59	47.83	1.24	0.79	0.48	
ANS-Me (mm)	80.11	0.94	81.53	0.90	1.42	0.40	*
SN/PP ( $^\circ$ )	10.99	0.94	11.64	0.87	0.65	0.33	
SN/Me-Go ( $^\circ$ )	44.09	1.91	44.98	1.84	0.90	0.34	*
U1/PP ( $^\circ$ )	113.45	2.72	109.53	3.85	-3.92	1.40	*
Overbite (mm)	-1.61	1.48	-0.10	1.50	1.51	1.07	
Overjet (mm)	1.92	0.82	2.19	0.85	0.26	0.423	
<b>Posteroanterior Cephalometric Measurements</b>							
MxR-MxL (mm)	66.79	2.16	69.23	2.02	2.45	0.52	**
ApR-ApL (mm)	7.79	0.33	11.21	0.76	3.42	0.91	**
UmoIR-UmoLL (mm)	54.88	2.38	62.70	2.32	7.81	1.01	**
LmoIR-LmoLL (mm)	61.60	1.46	61.88	1.47	0.27	0.43	
CroR-CroL (mm)	8.82	0.27	9.28	0.23	0.46	0.38	
MxR/cg/MxL ( $^\circ$ )	50.61	1.24	53.88	1.66	3.28	0.75	**
UmoIR/cg/UmoLL ( $^\circ$ )	34.13	1.50	39.67	1.71	5.54	0.75	**
CroR/cg/CroL ( $^\circ$ )	5.14	0.22	5.43	0.10	0.29	0.28	

**TABLE 2.** Lateral and Posteroanterior Cephalometric Measurements for RME Group (Paired *t*-test; \**P* < .05, \*\**P* < .01)

Parameters	Pre-RME		Post-RME		Difference		<i>P</i>
	X	±SX	X	±SX	D	±SD	
<b>Lateral Cephalometric Measurements</b>							
SNA (°)	74.57	0.96	76.76	0.80	2.18	0.67	*
SNB (°)	77.56	1.07	78.08	0.87	0.52	0.34	
ANB (°)	-2.98	1.30	-1.33	1.31	1.66	0.50	*
N-ANS (mm)	60.08	1.94	59.86	2.07	-0.22	0.31	
S-PNS (mm)	49.28	1.16	50.97	1.53	1.70	0.64	*
ANS-Me (mm)	73.39	1.49	75.52	1.42	2.14	0.34	**
SN/PP (°)	11.83	1.11	10.74	1.27	-1.09	0.44	*
SN/Me-Go (°)	43.77	1.14	43.93	1.00	0.15	0.60	
U1/PP (°)	111.57	1.79	110.18	2.04	-1.40	0.82	
Overbite (mm)	1.15	0.52	1.57	0.30	0.42	0.60	
Overjet (mm)	-1.82	1.67	-0.18	1.50	1.64	0.56	*
<b>Posteroanterior Cephalometric Measurements</b>							
MxR-MxL (mm)	62.80	0.56	65.02	0.64	2.22	0.51	**
ApR-ApL (mm)	6.76	0.44	9.09	0.45	2.33	0.45	**
UmolR-UmolL (mm)	55.04	0.93	62.42	1.82	7.38	1.01	**
LmolR-LmolL (mm)	58.62	1.46	60.24	1.75	1.61	0.37	**
CroR-CroL (mm)	9.04	0.20	11.61	1.29	2.57	1.25	
MxR/cg/MxL (°)	48.93	1.41	50.01	1.28	1.08	0.20	**
UmolR/cg/UmolL (°)	36.30	0.80	40.21	1.12	3.91	0.40	**
CroR/cg/CroL (°)	5.28	0.10	6.76	0.71	1.48	0.70	

## DISCUSSION

The objective of this study was to evaluate and compare the dental and skeletal changes for orthopedic expansion and surgically assisted maxillary expansion modalities during the active phase of treatment. It is important to note that we are not inquiring whether SARME could be an alternative to RME. We, and the earlier authors,<sup>4,7-12,14</sup> all agree that surgically assisted maxillary expansion is unavoidable where the expansion of the maxilla is not possible orthopedically because of the patient's skeletal maturity.

The initial measurements between the two groups were similar in terms of skeletal age of the individuals (Tables 1 and 2). Comparing the groups in general, there appears to be no big difference between the behavior of the two expansion methods (Table 3). When the results are examined in detail, we can observe small and sometimes statistically significant differences between the groups. As a result, we could conclude that both approaches are effective in expanding a narrow maxilla.

In the RME group, SNA increased significantly more than in the SARME group.<sup>16,17</sup> The initial values for SNA were similar, but the initial ANB values were significantly different, presenting a negative value in RME group. In this study, a statistically significant forward displacement of the maxilla was observed only in the RME group. This forward displacement could be explained by the occlusal coverage of the expanders, which helped to unlock the occlusion and set the max-

illa free in the RME patients who had a negative ANB value initially.

A forward displacement of the mandible was observed in the RME group, whereas SNB was significantly decreased in the SARME group. Lima Filho et al<sup>18</sup> supported the finding that the mandible carried forward to its normal position, resulting in a spontaneous correction of the Class II malocclusion. In our study, the SARME group had skeletal Class III malocclusion (ANB = -2.98°), and the RME group had a tendency toward a skeletal Class III malocclusion (ANB = 0.08°). Other studies pointing the effects of maxillary expansion on the mandibular skeletal structures are still not available. The difference in SNB change between the groups was statistically significant (*P* < .01), but this result is not strong enough for supporting the hypothesis that maxillary expansion induces the mandibular growth.

Another significant difference between the groups was observed in the rotation of the maxilla. A significant difference between groups in the anterior upper face height values was also observed. Most previous studies<sup>19-23</sup> have reported that the maxillary plane shows a significant posterior rotation after RME. Our data showed that the maxillary plane displaced a slight posterior rotation in the SARME group, whereas a significant anterior rotation in the RME group. The posterior rotation in the SARME group is expected, but the unexpected anterior rotation of the RME group could be explained by the resistance of the sutures to

**TABLE 3.** Lateral and Posteroanterior Cephalometric Comparison for SARME and RME Groups (Student's *t*-test; \**P* < .05, \*\**P* < .01)

Parameters	SARME		RME		<i>P</i>
	D	±SD	D	±SD	
<b>Lateral Cephalometric Measurements</b>					
SNA (°)	0.18	0.36	2.18*	0.67	*
SNB (°)	-0.93*	0.34	0.52	0.34	*
ANB (°)	1.11	0.59	1.66*	0.50	
N-ANS (mm)	1.21**	0.28	-0.22	0.31	**
S-PNS (mm)	0.79	0.48	1.70*	0.64	
ANS-Me (mm)	1.42*	0.40	2.14**	0.34	
SN/PP (°)	0.65	0.33	-1.09*	0.44	**
SN/Me-Go (°)	0.90*	0.34	0.15	0.60	
U1/PP (°)	-3.92*	1.40	-1.40	0.82	
Overbite (mm)	1.51	1.07	0.42	0.60	
Overjet (mm)	0.26	0.423	1.64*	0.56	
<b>Posteroanterior Cephalometric Measurements</b>					
MxR-MxL (mm)	2.45**	0.52	2.22**	0.51	
ApR-ApL (mm)	3.42**	0.91	2.33**	0.45	
UmolR-UmolL (mm)	7.81**	1.01	7.38**	1.01	
LmolR-LmolL (mm)	0.27	0.43	1.61**	0.37	*
CroR-CroL (mm)	0.46	0.38	2.57	1.25	
MxR/cg/MxL (°)	3.28**	0.75	1.08**	0.20	*
UmolR/cg/UmolL (°)	5.54**	0.75	3.91**	0.40	
CroR/cg/CroL (°)	0.29	0.28	1.48	0.70	

the expansion forces. Because the sutural resistance to the expansion forces was released in the SARME group, the maxillary plane does not show a significant rotation. However, in the RME group, this resistance still remains, resulting in a statistically significant anterior rotation of the maxillary plane.

In various studies on both SARME and RME, retrusion of the maxillary incisors was reported as a common finding.<sup>14,24,25</sup> This study's finding regarding the retrusion of the incisors (U1/PP) is compatible with the previous studies. If the prevention of the retrusion of the maxillary incisors is required, stopped-arch wires should be placed when the expansion is completed.

The SARME group produced 7.81 mm of expansion of the maxillary molar width, which is similar to the 7.38-mm expansion obtained by RME. Consequently, we observed an increase in mandibular intermolar width (LmolR-LmolL) in both groups, with more in the RME group. Gryson<sup>26</sup> showed that by using bonded expansion appliances with occlusal coverage, uprighting of the mandibular posterior teeth during the active expansion and retention phases is possible.

In our study, MxR/cg/MxL increased significantly in both groups. The similarity of the increase in this variable, measured by the effect of the expansion of the maxillary basis, shows that there is no difference between the two treatment modalities. The buccal flaring of the maxillary molar teeth was measured with UmolR/cg/UmolL. In the SARME group, this angle was increased 5.54° and in the RME group 3.91°. Wertz<sup>21</sup> mentioned that flaring or tipping of the maxillary molars

was a demonstrable and expected response to expansion, whereas Northway and Meade<sup>27</sup> stated that they had not observed any buccal flaring in their studies, which compared different approaches in maxillary expansion.

## CONCLUSIONS

- Clinically, there is no difference in patient response between the RME and SARME groups.
- The only difference between the groups is their indication, for RME or SARME which is based on the age and skeletal maturation of the patient.
- Cephalometrically, the most important difference could be summarized as the rotational behavior of the maxilla between groups.
- SARME is a successful treatment modality for the adult patients requiring palatal expansion. It is well tolerated by the patients under local anesthesia.
- Some overexpansion is suggested to eliminate the risk of relapse in both approaches.
- Long-term observation of the maxillary arch width after retention is of a great importance for the maintenance of the treatment outcome in both SARME and RME patients.

## REFERENCES

1. Angell EC. Treatment of irregularities of the permanent adult teeth. *Dent Cosmos*. 1860;1:540–545.
2. Haas AJ. Rapid expansion of the maxillary dental arch and nasal cavity by opening the mid maxillary suture. *Angle Orthod*. 1961;31:73–90.

3. Baumrind S, Korn EL. Transverse development of human jaws between the ages of 8.5 and 15.5 years, studied longitudinally with the use of implant. *J Dent Res*. 1990;69:1298–1306.
4. Betts NJ, Vanarsdall RL, Barber HD, Higgins-Barber K, Fonseca RJ. Diagnosis and treatment of transverse maxillary deficiency. *Int J Adult Orthod Orthognath Surg*. 1995;10:75–96.
5. Graber TM, Swain BF. *Current Orthodontic Concepts and Techniques*. Philadelphia, Pa: Saunders; 1975.
6. Vanarsdall RL. Periodontal/orthodontic interrelationships. In: Graber TM, Vanarsdall RL, eds. *Orthodontics: Current Principles and Techniques*, 2nd ed. St Louis, Mo: CV Mosby; 1994;712–749.
7. Brown GVI. The surgery of oral and facial diseases and malformations, 4th ed. London: Kimpton, 1938:507. In: Betts NJ, Vanarsdall RL, Barber HD, Higgins-Barber K, Fonseca RJ. Diagnosis and treatment of transverse maxillary deficiency. *Int J Adult Orthod Orthognath Surg*. 1995;10:75–96.
8. Glassman AS, Nahigian SJ, Medway JM, Aronowitz HI. Conservative surgical orthodontic adult rapid palatal expansion: sixteen cases. *Am J Orthod*. 1984;86:207–213.
9. Mossaz CF, Byloff FK, Richter M. Unilateral and bilateral corticotomies for correction of maxillary transverse discrepancies. *Eur J Orthod*. 1992;14:110–116.
10. Kennedy JW, Bell WH, Kimbrough OL, et al. Osteotomy as an adjunct to rapid maxillary expansion. *Am J Orthod*. 1976;70:123–137.
11. Berger JL, Pangrazio-Kulbersh V, Borgula T, Kaczynski R. Stability of orthopedic and surgically assisted rapid maxillary expansion over time. *Am J Orthod Dentofacial Orthop*. 1998;114:638–645.
12. Berger JL, Pangrazio-Kulbersh V, Thomas BW, Kaczynski R. Photographic analysis of facial changes associated with maxillary expansion. *Am J Orthod Dentofacial Orthop*. 1999;116:563–571.
13. Greulich WW, Pyle SI. *Radiographic Atlas of Skeletal Development of Hand and Wrist*, 2nd ed. Stanford, Calif: Stanford University Press; 1959.
14. Cureton S, Cuenin M. Surgically assisted rapid maxillary expansion: orthodontic preparation for clinical success. *Am J Orthod Dentofacial Orthop*. 1999;116:46–59.
15. Memikoglu TUT, Iseri H. Effects of a bonded rapid maxillary expansion appliance during orthodontic treatment. *Angle Orthod*. 1999;69:251–256.
16. Chung CH, Font B. Skeletal and dental changes in the sagittal, vertical, and transverse dimensions after rapid maxillary expansion. *Am J Orthod Dentofacial Orthop*. 2004;126:569–575.
17. Chung C, Woo A, Zagarinsky J, Vanarsdall R, Fonseca R. Maxillary sagittal and vertical displacement induced by surgically assisted rapid maxillary expansion. *Am J Orthod Dentofacial Orthop*. 2001;120:144–148.
18. Lima Filho RMA, Lima AC, Ruellas ACO. Spontaneous correction of Class II malocclusion after rapid maxillary expansion. *Angle Orthod*. 2003;73:745–752.
19. Davis WM, Kronman JH. Anatomical changes induced by splitting of the midmaxillary suture. *Angle Orthod*. 1969;39:126–132.
20. Haas AJ. Maxillary expansion: just the beginning of dentofacial orthopedics. *Am J Orthod*. 1970;57:219–55.
21. Wertz RA. Skeletal and dental changes accompanying rapid midmaxillary suture opening. *Am J Orthod*. 1970;58:41–66.
22. Haas AJ. Long-term posttreatment evaluation of rapid maxillary expansion. *Angle Orthod*. 1980;50:189–217.
23. da Silva Filho OG, Montes LA, Torelly LF. Rapid maxillary expansion in the deciduous and mixed dentition evaluated through posteroanterior cephalometric analysis. *Am J Orthod Dentofacial Orthop*. 1995;107:268–275.
24. Lines PA. Adult rapid maxillary expansion with corticotomy. *Am J Orthod*. 1975;67:44–56.
25. Strömberg C, Holm J. Surgically assisted rapid maxillary expansion in adults. A retrospective long-term follow-up study. *J Cranio Maxillofac Surg*. 1995;23:222–227.
26. Gryson JA. Changes in mandibular interdental distance concurrent with rapid maxillary expansion. *Angle Orthod*. 1977;47:186–192.
27. Northway WM, Meade JB. Surgically assisted rapid maxillary expansion: A comparison of technique, response and stability. *Angle Orthod*. 1997;67:309–320.