

# Microscopic Evaluation of Mandibular Symphyseal Distraction Osteogenesis

İsmet Duran<sup>a</sup>; Siddık Malkoç<sup>b</sup>; Haluk İşeri<sup>c</sup>; Mustafa Tunalı<sup>d</sup>; Murat Tosun<sup>e</sup>; Hasan Küçükolbaşı<sup>f</sup>

**Abstract:** The purpose of this study was to evaluate microscopically the newly formed hard tissue after a consolidation period of mandibular symphyseal distraction osteogenesis (MSDO). Sixteen patients underwent MSDO treatment. After a latency period of seven days, the distraction device was activated by the patient once in the morning and once in the evening, for a total of one mm per day for a mean  $10.1 \pm 2.8$  days, and the mean opening of the device was  $8.1 \pm 1.7$  mm. The device was usually maintained in position approximately 90 days after surgery. After the completion of the distraction period, the lower anterior teeth were bonded and tooth movement into the distraction site was initiated. After a consolidation period, second surgery was performed to remove the distraction devices. During the second surgery, hard tissue biopsies were taken on the apical region of the two central incisors and the left canine. The samples were fixed in 10% buffered formalin and decalcified in 3% HNO<sub>3</sub> solutions. New bone formation was present within the distraction gap immediately after the consolidation period. The cellular construction was more irregular in the distraction sections than in the normal bone sections. The newly distracted area was not complete immediately after the consolidation period. Furthermore, the newly formed bone had a membranous structure, which indicates continual maturation. Bone exposed to stretching forces undergoes new bone formation, and the newly formed bone is of a membranous type also named as a woven type. (*Angle Orthod* 2006;76:369–374.)

**Key Words:** Microscopic evaluation; Symphyseal distraction; Tooth movement

## INTRODUCTION

Distraction osteogenesis (DO), initially reported in 1905 by Codivilla,<sup>1</sup> is a process of growing new bone by mechanical stretching of the preexisting bone tissue. DO controls these dynamic forces and leads to new bone formation in the direction of the distraction vectors.<sup>1</sup>

There is a large amount of literature on the use of DO to treat a wide variety of dentofacial problems.<sup>1</sup> The method is currently being developed for orthodontic application such as canine retraction,<sup>2</sup> alveolar distraction osteogenesis<sup>3</sup> (ADO) before oral implant reconstruction, mandibular widening,<sup>4-7</sup> recovery of ankylosed teeth,<sup>8</sup> segmental translation,<sup>9,10</sup> and interdental distraction.<sup>11</sup> To improve the distraction protocol, some microscopic, morphologic, and human clinical studies have been performed on the type and quality of bone obtained especially by ADO.<sup>3,11</sup> The results are encouraging in that they suggest that reliable tissues can be obtained for implant treatment. In clinical orthodontics, reconstruction of the occlusion after DO is at the forefront of research. This topic is of particular interest, especially when applied in the tooth-bearing area, because a dental gap is created between the distracted bony segments.

Mandibular symphyseal distraction osteogenesis (MSDO), initially reported by Guerrero in 1990,<sup>4</sup> has since been used sparingly by others. Despite early reports<sup>4-7</sup> of success, important questions remained unanswered. What is the biologic foundation of DO to widen the symphysis and what is the response of al-

<sup>a</sup> Associate Professor, Periodontology Department, Faculty of Dentistry, Selçuk University, Konya, Turkey.

<sup>b</sup> Assistant Professor, Orthodontic Department, Selçuk University, Konya, Kampüs, Turkey.

<sup>c</sup> Professor and Department Chair, Orthodontic Department, Ankara University, Ankara, Turkey.

<sup>d</sup> Research Fellow, Periodontology Department, Faculty of Dentistry, Gülhane Military Medicine Academy, Ankara, Turkey.


<sup>e</sup> Assistant Professor, Embryology and Histology Department, University of Afyon Kocatepe, Afyon, Turkey.

<sup>f</sup> Assistant Professor, Oral and Maxillofacial Surgery Department, Faculty of Dentistry, Selçuk University, Konya, Turkey.

Corresponding author: İsmet Duran, Periodontology, Faculty of Dentistry, Selçuk University, Kampüs, Konya 42079, Turkey (e-mail: iduran@selcuk.edu.tr)

Accepted: April 2005. Submitted: March 2005.

© 2006 by The EH Angle Education and Research Foundation, Inc.



**FIGURE 1.** The custom-made, intraoral, rigid tooth- and bone-borne distractor.

veolar bone during mandibular widening? The purpose of this study was to evaluate microscopically the newly formed bone after the consolidation period of MSDO and to verify the influence of tooth movement into immature, fibrous, and less mineralized bone.

## MATERIALS AND METHODS

### Patient population

The sample comprised 16 patients (nine male and seven female) with a mean age of  $20.4 \pm 1.2$  years (range, 16.4–23.8 years) at the time of surgery. Clinical indications<sup>7</sup> for MSDO were severe mandibular anterior dental crowding, V-shaped mandible, unilateral or bilateral scissor bite, and a maxillomandibular transverse deficiency. None of the patients had any systemic problems.

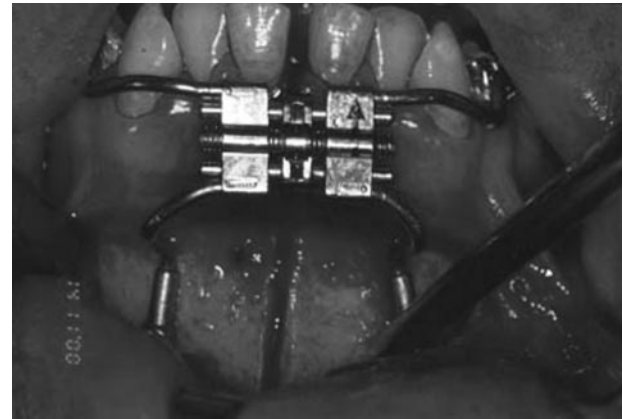
Patients and their parents were informed about the proposed treatment plan involving the surgical phase as well as the conventional alternative option, and their consent was obtained. A detailed study design was explained to patients and their parents, and only volunteers were included in this study. The research project was approved by the Ethics Committee of the School of Dentistry, University of Selçuk.

### Appliance design

A custom-made, intraoral, rigid bone- and tooth-borne distraction device was used. The device consisted of a HYRAX (GAC, New York, NY) screw and two footplates (Strike-Liebinger, Freiburg, Germany) (Figure 1). The distractor was positioned in front of the lower incisors at the gingival level, and opening holes of the screw was placed on the mandibular symphysis. The upper arms of the screw were bent in accordance with the lower anterior archform and fitted into the first mandibular premolar braces, which were welded to the band in a horizontal position. The footplates were fixed to the tip of the lower arms and adjusted according to the symphysis formation.

### Surgical technique

The surgical procedure was performed under local anesthesia and intravenous sedation. An incision to a



**FIGURE 2.** Mandibular symphyseal distraction osteogenesis surgery.

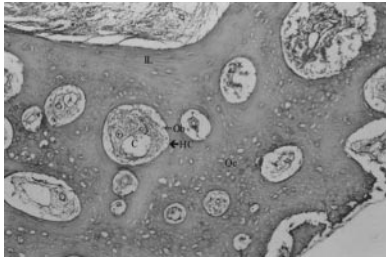
depth of four to six cm was made in the mandibular vestibule, through the orbicularis oris muscle. The upper arms of the device were fitted to the first premolars, the lower arms and footplates were adjusted to the bone, and guidance screw holes were drilled with a Lindeman bur. A vertical osteotomy was made through the symphyseal area with an oscillating saw blade, starting at the inferior border of the mandible and extending to the interdental space between the apices of the mandibular central incisors. Then, with a straight handpiece, the cut was continued on the labial cortical plate of the mandible until the alveolar crest was reached. The final sectioning was done manually with a mallet and spatula osteotome. Once the vertical osteotomy and sectioning of the mandible had been completed, the distraction device was fixed to the bone and teeth and then activated three mm (Figure 2). After confirming the complete osteotomy, the distraction device reactivated to its initial position. Care was taken to ensure that the wounds were sutured in the proper tissue planes.

### Distraction protocol

After a latency period of seven days, the distraction device was activated by the patient once in the morning and once in the evening, for a total amount of one mm per day for  $10.1 \pm 2.8$  days (distraction period), and the mean opening of the device was  $8.1 \pm 1.7$  mm. The device remained in position  $94.9 \pm 5.8$  days (consolidation period) after surgery for maturation of the newly developed bone.

### Orthodontic movement

After the completion of the distraction period, the lower anterior teeth were bonded and tooth movement was initiated into the distraction site with the new alveolar bone using light orthodontic forces (25–30 g)



**FIGURE 3.** The biopsy samples of distracted mandible stained with Hematoxylin (Cole) and Eosin. Hc indicates haversian canaliculi; IL, interstitial lamellas; Oc, osteocysts; and Ob, osteoblasts, 33 $\times$ .

commencing after distraction surgery. Dental crowding was resolved by movement of the anterior teeth into the distraction gap with fixed appliance orthodontic treatment. This orthodontic tooth movement began after the completion of the distraction process.

### Microscopic analysis

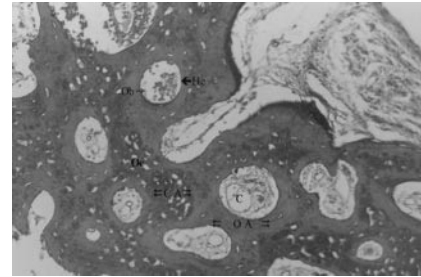
After the consolidation period, second surgery was performed to remove the distraction devices. During the second surgery, hard tissue biopsies were taken on the apical region of two central incisors (distracted bone tissue) and on the left-side canine (control bone tissue). Dimensions of the control and distracted biopsy samples were approximately 0.5  $\times$  0.5  $\times$  0.5 cm.

The histological samples were fixed in 10% buffered formalin (Sigma Chemical, St Louis, Mo) and decalcified in HNO<sub>3</sub> solutions (Sigma Chemical), which were diluted before use. To get fast but effective and safe results, this solution was refreshed each 12 hours during the decalcification process. At the end of the decalcification process, the samples were processed with classical tissue-processing techniques and embedded in 60–62°C paraffin. Then, five- $\mu$ m-thick sections were taken from these blocks and stained with Hematoxylin (Cole) and Eosin (Sigma Chemical). Cole Hematoxylin is generally used for distinguishing calcified and osteoid bone tissues under light microscopy.<sup>12</sup> In addition, mallory aniline blue collagen stain (Sigma Chemical) was used for determining developing collagen structures in different tissues.<sup>13</sup> All slides were comparatively evaluated under an Olympus BH2 (Osaka, Japan) light microscope at 33 $\times$  magnification.

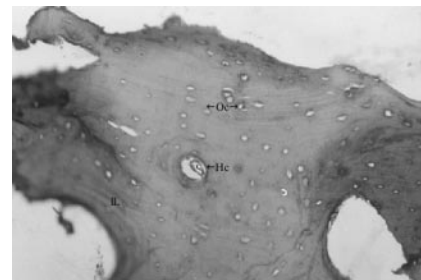
## RESULTS

### Distracted bone biopsy samples

The distracted bone biopsy samples stained with Hematoxylin (Cole) and Eosin (Figure 3) showed that although there was no mature osteon construction, there were many irregular interstitial lamellas and Haversian canaliculi. There were many osteocytes and osteoblasts in the irregular lamellar structure. There were



**FIGURE 4.** The biopsy samples of distracted mandible stained with mallory aniline blue. Hc indicates haversian canaliculi; IL, interstitial lamellas; Oc, osteocysts; and Ob, osteoblasts, 33 $\times$ .



**FIGURE 5.** The normal mandible biopsy samples stained with Hematoxylin (Cole) and Eosin. Hc indicates haversian canaliculi; IL, interstitial lamellas; C, capillar; Oc, osteocysts; Ob, osteoblasts; CA, calcified area; and OA, ossified area, 33 $\times$ .

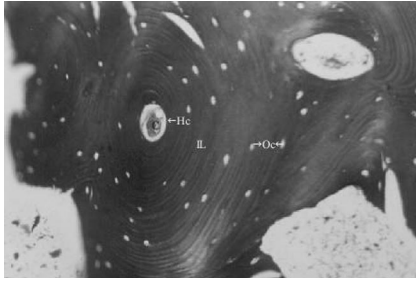
also some developing osteoblasts but no osteoclasts in the Haversian canaliculi. Fine and course vessels had invaded the entire matrix.

The tissue samples of distracted mandible stained with mallory aniline blue (Figure 4) showed that there were many irregular connective tissue fibrils and massive collagen accumulations in the distraction area. In addition, there were osteocytes scattered among the collagen fibrils. However, many osteoid structures, especially those evident around the Haversian canaliculi and in the matrix, were immature. The chondroid tissue had completely disappeared, and no evidence of soft tissue scarring was present in any of the sections.

### Control bone biopsy samples

The control bone biopsy samples stained with Hematoxylin (Cole) and Eosin (Figure 5) had regular lamellar constructions, well-developed interstitial lamellas and Haversian canaliculi, and, in some places, organized osteon structures. In the bone matrix, there were many osteocytes but few osteoblasts and almost all the matrix was ossified. Neither osteoclasts nor developing osteoblasts was found in the Haversian canaliculi. Some medium-sized vessels were also observed in the matrix.

The control bone biopsy samples stained with mallory aniline blue (Figure 6) collagen stain had regular



**FIGURE 6.** The normal mandible biopsy samples stained with malory aniline blue. Hc indicates Haversian canaliculi; IL, interstitial lamellas; C, capillar; Oc, osteocysts; Ob, osteoblasts; CA, calcified area; and OA, ossified area, 33 $\times$ .

osteon structures. The centrally located Haversian canaliculi and the regularly distributed interstitial lamellas appeared clearly. The matrix of the bone was stained dark blue indicating that it contained mature collagen. There was no chondroid structure in these samples.

## DISCUSSION

Regenerate tissue mineralization and remodeling has been investigated experimentally by several authors, mainly by radiography, ultrasound, computed tomography, light microscopy, and electron microscopy.<sup>14-18</sup> Although microscopic evaluation is limited to human biopsy material or to tissues harvested at the end point of animal experiments, it is the only method by which to directly observe all tissue components as well as their spatial relationships to one another. Moreover, direct quantification of cell and matrix types and bone formation rates are possible.<sup>19</sup> This study analyzed the processing of bone formation and remodeling during MSDO using a tooth- and bone-borne distraction device. In our clinical study, the lower incisors and canines were moved into the new distracted bone area immediately after the distraction period, and the quality of new bone formation was evaluated.

The progressive maturation of bone regeneration has been evaluated in different histological studies.<sup>19-21</sup> Cope and Samchukov<sup>19</sup> documented the histomorphometric changes of bone regeneration during an eight-week consolidation period after mandibular osteodistraction. According to their results, bone regeneration was believed to be still in the remodeling phase at the end of the consolidation period. Also, their results indicate that membranous ossification was the predominant mechanism of new bone formation in the DO process. In addition, they found that although some areas of cartilage were present within the regenerated tissue, possibly indicating enchondreal bone formation, no cartilage was seen within the distraction gap after the fourth week of consolidation. Similarly, in this study, we determined

that the cellular construction was more irregular in the distraction sections than in the control bone sections. However, the number of the cells located in the distraction area was more than in the control area.

Although control bone biopsies have a calcified structure, the distracted bone biopsies had an osteoid structure. The distraction gap when exposed to stretching forces undergoes new bone formation, and the newly formed bone is of a membranous, also named as woven, type. The chondroid tissue had also completely disappeared, and no evidence of soft tissue scarring or infection was present in any of the sections. These data suggest that maturation of the newly distracted area was not complete immediately after the consolidation period, but the newly formed bone has a membranous structure indicating the continual development and maturation of new bone. Although the size of the biopsies was small and they were not from the entire distraction region, we suggest that this study will be beneficial for future studies.

Zaffe et al<sup>22</sup> treated 10 patients with ridge deformities to obtain the required ridge augmentation by ADO. Clinical and radiological (orthopantomography and computerized tomography with densitometric assay) evaluations were carried out during the subsequent 12 weeks, before implant insertion(). Biopsies at 40, 60, and 88 days were studied after general, specific, and histochemical staining of slides; microradiographs were analyzed to evaluate the Trabecular Bone Volume (TBV). Forty days after the end of distraction, soft callus indicated the start of ossification. Sixty days after the end of distraction, the soft callus was largely converted into a network of trabecular woven bone; osteogenic activity was high and TBV was approximately 50%. Eighty-eight days after the end of distraction, the amount of bone appeared reduced, with a more ordered structure. Bone formation activity and TBV were also diminished, whereas osteoclast erosion was active. The densitometry assay shows values increasing from the end of distraction, particularly after implant insertion. Histological results of this study show a regression in bone deposition processes 88 days after the end of distraction, culminating in a virtual steady-state after a certain time.

In our study, the biopsies performed approximately 90 days from the end of distraction showed several bony trabeculae displaying a more ordered structure. The osteoblasts formed parallel-fibered or lamellar bone in apposition to the preexisting woven bone. Our results agree with those obtained by Zaffe et al<sup>22</sup> who used a different type of distraction device and vector. Therefore, their clinical pilot study, similar to our study, depended mainly on the clinical observation and included some histological analyses.

Movement of teeth through regenerate bone is a

topic of current interest. Some authors<sup>4,7</sup> advise that tooth movement should not begin until radiologic evidence of consolidation is observed after the distraction period. They report that closure of the interdental space should be delayed until the bone is observed, and to prevent mesial migration, an acrylic denture can be placed in the distraction space. They assume that allowing the teeth to move into the gap early can lead to periodontal defects, bony defects, and potential loss of teeth.<sup>4,7</sup>

However, some clinical reports have demonstrated that a tooth can be moved into the regenerated bone after the distraction period.<sup>16,23,24</sup> Moderate to severe alveolar bone loss was noted in the fourth premolars moved simultaneously with distraction.<sup>23</sup> Initiating orthodontics at the end of the distraction period preserved periodontal support and produced a tooth movement rate of 1.2 mm per week. Liou et al<sup>24</sup> demonstrated that orthodontic tooth movement into the newly distracted bone two weeks after the cessation of the distraction period accelerates the maturation process of this bone. They suggested that orthodontic tooth movement into the newly distracted bone is possible and that the new alveolar bone created through orthodontic tooth movement is a mature, compact bone indistinguishable from the original mandibular bone. Their study results indicate that orthodontic tooth movement also increased the volume of bone at the distraction site by alveolar bone formation.

Cope et al<sup>16</sup> demonstrated that teeth can be orthodontically moved into regenerated bone tissue, but the influence of tooth movement into immature or regenerated mature bone on the periodontal ligament and tooth roots remains unknown. Nakamoto et al<sup>25</sup> evaluated that the influence of tooth movement on tooth roots and periodontal tissues when teeth were moved into mature, well-organized, and mineralized regenerate bone created after DO compared with immature, fibrous, and less mineralized bone. They indicated that heavy force (80–100 g) and early orthodontic tooth movement are not recommended when teeth are moved through regenerated bone created by DO, to avoid tipping and severe root resorption.<sup>25</sup> This study demonstrated that early tooth movement into the newly distracted area has no adverse effects on bone maturation. Waiting 12 weeks after distraction to initiate tooth movement resulted in a lower rate of tooth movement with less root resorption.<sup>25</sup>

In accordance with our clinical experiences, no periodontal bone loss, periapical pathology, or soft tissue recession was evident, and tooth vitality was maintained in all patients. There are no reports that address the production and retention of attached gingiva when teeth are moved regenerated bone. Although DO offers considerable promise for orthodontics and den-

tofacial orthopedics, more research is needed to develop reliable clinical techniques.

## CONCLUSIONS

- Bone exposed to stretching undergoes new bone formation and the newly formed bone is of a membranous, also known as woven type.
- This formation is generally parallel to the axis of the stretching force. Consequently, it is possible to make the newly formed bone into the required shape.
- Early tooth movement into the newly distracted area did not affect bone maturation and regeneration.

## REFERENCES

1. McCarthy JG, Stelnicki EJ, Grayson BH. Distraction osteogenesis of the mandible: a ten year experience. *Semin Orthod.* 1999;5:3–8.
2. Kişnişçi R, İşeri H, Tüz HH, Altuğ AT. Dentoalveolar distraction osteogenesis for rapid orthodontic canine retraction. *J Oral Maxillofac Surg.* 2002;60:389–394.
3. McAllister BS, Gaffanet TE. Distraction osteogenesis for vertical bone augmentation prior to oral implant reconstruction. *Periodontol 2000.* 2003;33:54–66.
4. Guerero CA. Rapid mandibular expansion. *Rev Venez Orthod.* 1990;48:1–9.
5. Malkoç S. *Effects of Mandibular Midline Distraction Osteogenesis on the Dentofacial Structures* [PhD thesis]. Konya, Turkey: Selçuk University; 2002.
6. Mommaerts MY. Bone anchored intraoral device for transmandibular distraction. *Br J Oral Maxillofac Surg.* 2001;39:8–12.
7. Contasti G, Guerrero CA, Rodriguez AM, Legan HL. Mandibular widening by distraction osteogenesis. *J Clin Orthod.* 2001;35:165–173.
8. Isaacson RJ, Strauss RA, Bridges-Poquis A. Moving and ankylosed central incisor using orthodontics, surgery and distraction osteogenesis. *Angle Orthod.* 2001;71:411–418.
9. Kondoh T, Hamada Y, Kamei K. Transport distraction osteogenesis following marginal resection of mandible. *Int J Oral Maxillofac Surg.* 2002;31:675–676.
10. Dolanmaz D, Karaman AI, Durmus E, Malkoç S. Management of alveolar cleft by using dento-osseous transport distraction osteogenesis. *Angle Orthod.* 2003;73:723–729.
11. Block MS, Almerico B, Crawford C, Gardiner D, Chang A. Bone response to functioning implants in dog mandibular alveolar ridges augmented with distraction osteogenesis. *Int J Oral Maxillofac. Implants.* 1998;13:342–531.
12. Bancroft JD, Stevens A. Bone. In: Stevens A, Lowe J, Bancroft JD, eds. *Theory and Practice of Histological Techniques.* 3rd ed. Edinburgh, UK: Churchill-Livingstone Company; 1992:309–341.
13. Clark G. Animal histotechnic methods for connective tissue. In: Clark G, ed. *Staining Procedures.* 4th ed. Baltimore, Md. Williams and Wilkins Company; 1981:113–129.
14. Gantous A, Phillips JH, Catton P, Holmberg D. Distraction osteogenesis in the irradiated canine mandible. *Plast Reconstr Surg.* 1994;93:164–168.
15. Eyres KS, Bell MJ, Kanis JA. Methods of assessing new bone formation during limb lengthening. Ultrasonography, dual energy X-ray absorptiometry, and radiography compared. *J Bone Joint Surg Br.* 1993;75:358–364.
16. Cope JB, Harper RP, Samchukov ML. Experimental tooth

- movement through regenerate alveolar bone: a pilot study. *Am J Orthod Dentofacial Orthop.* 1999;116:501–505.
17. Karaharju-Suvanto T, Peltonen J, Kahri A, Karaharju EO. Distraction osteogenesis of the mandible. An experimental study on sheep. *Int J Oral Maxillofac Surg.* 1992;21:118–121.
  18. Karaharju EO, Aalto K, Kahri A, Lindberg LA, Kallio T, Karaharju-Suvanto T, Vauhkonen M, Peltonen J. Distraction bone healing. *Clin Orthop.* 1993;297:38–43.
  19. Cope JB, Samchukov ML. Regenerate bone formation and remodeling during mandibular osteodistraction. *Angle Orthod.* 2000;70:99–111.
  20. Cope JB, Samchukov ML, Muirhead DE. Distraction osteogenesis and histogenesis in beagle dogs: the effect of gradual mandibular osteodistraction on bone and gingiva. *J Periodontol.* 2002;73:271–282.
  21. Rowe NM, Mehrara BJ, Dudziak ME, Steinbreck DS, Mac-  
kool RJ, Gittes GK. Rat mandibular distraction osteogenesis: part I. Histologic and radiographic analysis. *Plast Reconstr Surg.* 1998;102:2022–2032.
  22. Zaffe D, Bertoldi C, Palumbo C, Consolo U. Morphofunctional and clinical study on mandibular alveolar distraction osteogenesis. *Clin Oral Implants Res.* 2002;13:550–557.
  23. Liou EJ, Figueroa AA, Polley JW. Rapid orthodontic tooth movement into newly distracted bone after mandibular distraction osteogenesis in a canine model. *Am J Orthod Dentofacial Orthop.* 2000;117:391–398.
  24. Liou EJW, Polley JW, Figueroa AA. Distraction osteogenesis, the effects of orthodontic tooth movement on distracted bone. *J Craniofac Surg.* 1998;9:564–571.
  25. Nakamoto N, Nagasaka H, Daimaruya T, Takahashi I, Sugawara J, Mitani H. Experimental tooth movement through mature and immature bone regenerates after distraction osteogenesis in dogs. *Am J Orthod Dentofacial Orthop.* 2002;121:385–395.

## Erratum

***The Angle Orthodontist* 2006;76(3):369–374.**

### **Microscopic Evaluation of Mandibular Symphyseal Distraction Osteogenesis**

Ismet Duran; Siddik Malkoç; Haluk İşeri; Mustafa Tunalı; Murat Tosun; Hasan Küçükolbaşı

Please make the following changes:

1. The second paragraph of the “Patient Population” section should read, with the addition of the italicized text:

Patients and their parents were informed about the proposed treatment plan involving the surgical phase as well as the conventional alternative option, and their consent was obtained. A detailed study design was explained to patients and their parents, and only volunteers were included in this study. The *surgical expansion of the mandible with distraction osteogenesis was approved by the Ethics Committee of the School of Dentistry, University of Selçuk. The study design was declared to patients orally and only volunteers were included in the study group.*

2. In the first sentence of the first paragraph of the “Microscopic Evaluation” section, the biopsy dimension is given as “*cm*”; it should be “*mm*.”
3. In the first sentence of the first paragraph of the “Surgical Technique” section, “*intravenous* sedation” should be changed to “*intramuscular* sedation.”

***The Angle Orthodontist* 2006;76(3):400–405.**

### **Initial Effects of the Tongue Crib on Tongue Movements During Deglutition: A Cine-Magnetic Resonance Imaging Study**

M. Özgür Sayın; Erol Akın; Şeniz Karaçay; Nail Bulakbaşı

The May 2006 issue carried this article and incorrectly listed the matrix size. Please note the change below. In the “Materials and Methods” section, please replace the incorrect matrix size.

Correct sentence:

The B-TFE images (shortest TR/TE: 2.1/1.09 ms) were obtained in the midsagittal plane by using 50° flip angle, 10-mm slice thickness, autoshim, 350 × 350 mm field of view, and 96 × 96 matrix size during swallowing of water.