

# Interexaminer Reliability of Two Cephalometric Methods to Determine Proximal Segment Position after Bilateral Sagittal Split Ramus Osteotomy

Hyun-Sil Choi<sup>a</sup>; Joe Rebellato<sup>b</sup>; Hyun-Joong Yoon<sup>c</sup>

**Abstract:** The objective of this study was to evaluate the interexaminer reliability of two cephalometric methods for determining positional change of the proximal segment after a bilateral sagittal split ramus osteotomy (BSSRO) for mandibular advancement. The records of 25 patients were used in a double-blind trial. Two nontrained investigators (having read the articles describing the two cephalometric methods, but with no other special training) independently traced posterior-anterior (PA) and lateral cephalometric radiographs taken at three time intervals: (T1) before surgery, (T2) immediately after surgery, and (T3) after orthodontic treatment was completed. The level of agreement between the two investigators (interexaminer reliability) on all 25 patients was estimated by calculating the intraclass correlation coefficient (ICC). The ICC was found to have a high value, indicating “substantial” to “almost perfect agreement” between the two examiners. Thus the results validate the use of these two methods to determine proximal segment positional changes in the frontal and sagittal planes of space after a BSSRO. (*Angle Orthod* 2006;76:375–381.)

**Key Words:** Cephalometric; Proximal segment; Reliability; BSSRO; BSSO; Relapse

## INTRODUCTION

Ever since the bilateral sagittal split ramus osteotomy (BSSRO) was introduced, the specific factors that may affect the stability of the procedure have been a topic of interest.<sup>1</sup> Schendel and Epker<sup>2</sup> concluded that one of these factors, the control of the proximal segment, was the most important factor in the prevention of relapse and ultimate stability of the planned post-surgical position.

Many studies have shown condylar positional change after a BSSRO procedure. Some authors have reported the positional change of the proximal seg-

ment using submentovertex radiography and computed tomography.<sup>3–7</sup> Several investigators have reported condylar positional changes using computed tomography (CT) for three-dimensional (3-D) evaluation.<sup>8,9</sup> However, these radiographic images are not routinely obtained on patients who are having a BSSRO and, if they were, they would both expose the patient to additional ionizing radiation and constitute an added expense to the patient or third-party provider.

Rebellato et al<sup>10</sup> reported sagittal condylar positional changes using lateral cephalometric radiographs of patients who underwent a BSSRO advancement of the mandible with rigid fixation. This technique involved superimposing tracings of the radiographs on clearly identifiable cephalometric landmarks (ie, mandibular symphysis and rigid fixation screws). The condylar portion of the proximal segments could then be indirectly extrapolated without actually having to directly image the temporomandibular joints.<sup>10</sup>

Becktor et al<sup>11</sup> presented a method to measure the transverse displacement of the proximal segments, using PA cephalometric radiographs in patients after a BSSRO for mandibular advancement surgery. Theoretically, both techniques could be used for mandibular advancement surgery, mandibular setback surgery, and in double-jaw surgery.

<sup>a</sup> Visiting Clinician, Division of Orthodontics, Department of Dental Specialties, Mayo Clinic, Rochester, Minn.

<sup>b</sup> Associate Professor, Division of Orthodontics, Department of Dental Specialties, Mayo Clinic, Rochester, Minn.

<sup>c</sup> Visiting Clinician, Division of Oral and Maxillofacial Surgery, Department of Surgery, Mayo Clinic, Rochester, Minn; Assistant Professor, Department of Oral and Maxillofacial Surgery, St Mary's Hospital, Catholic University of Korea, Seoul, South Korea.

Corresponding author: Joe Rebellato, Orthodontics, Mayo Clinic, 200 First Street SW, Rochester, MN 55905 (e-mail: rebellato.giuseppe@mayo.edu)

Accepted: June 2005. Submitted: April 2005.

© 2006 by The EH Angle Education and Research Foundation, Inc.

In determining the positional change of the proximal segment after a BSSRO, it is important to know the reliability of the measurement method. Research carried out on conventional cephalometrics has proved landmark identification to be the main source of error.<sup>12–15</sup> Among the factors contributing to the identification error are observer experience, landmark definition, and the density and sharpness of the image.<sup>16</sup> Various investigators have evaluated the validity of landmark identification in cephalometrics.<sup>17–21</sup>

This study was designed to evaluate the interexaminer reliability of the methods presented by:

- Rebellato et al<sup>10</sup> to determine the sagittal proximal segment changes after BSSRO using lateral cephalometric radiographs and
- Becktor et al<sup>11</sup> to determine the transverse proximal segment changes after BSSRO using PA cephalometric radiographs.

## MATERIALS AND METHODS

The records used in this investigation were obtained from a consecutive series of patients treated at the Mayo Clinic and were retrospectively analyzed. The patients all had double-jaw surgery that included a BSSRO. All patients had rigid internal fixation after a mandibular advancement with or without an advancement genioplasty or reduction genioplasty.

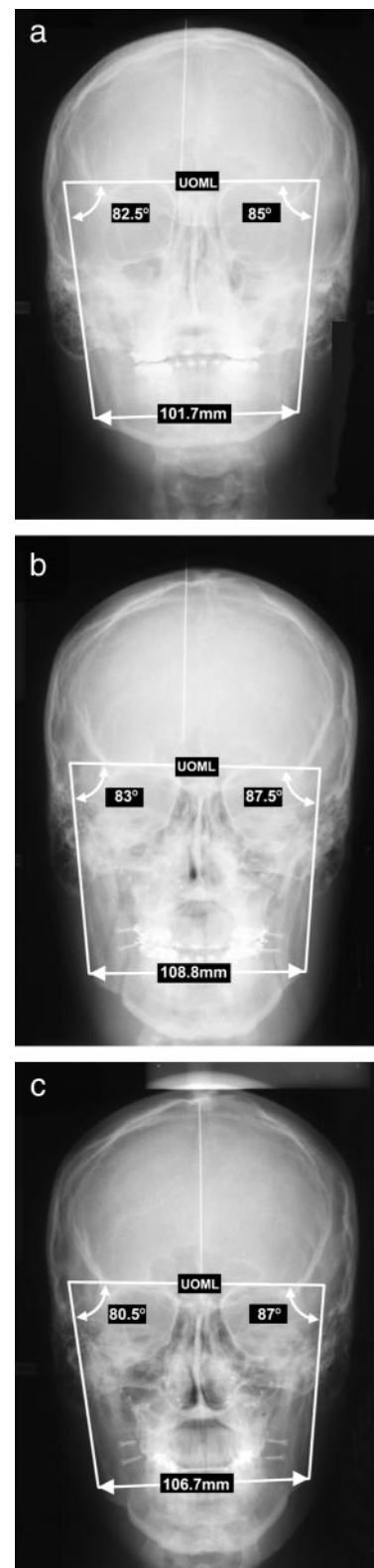
The radiographic material for this study consisted of three lateral cephalometric radiographs and three posterior-anterior (PA) cephalometric radiographs for each patient (total of 25 patients) taken at three time periods: T1 (before surgery), T2 (immediate postoperatively), and T3 (late postoperatively).

### P-A cephalometric radiographs

The P-A cephalometric radiographs were used to measure mandibular widths and the angulation of the mandibular proximal segments, according to the method described by Becktor et al.<sup>11</sup> The reference points and lines as drawn on the T1, T2, and T3 tracings are shown in Figure 1a–c, respectively, and are as follows.

- Upper orbital margin line (UOML): A tangent line to the most superior visible margins of the orbits.
- Gonion (Go): The most lateral portion of the mandible and the most inferior portion of the ramus.
- Ramus point (RP): The most lateral and superior visible portion of the mandible, where the outline of the mastoid process crosses the lateral border of the ramus; identified only on the T1 tracing.

Points Go and RP were transferred from the T1 to the T2 and to the T3 tracings by a best-fit superimposition of the proximal segment cortical outline. A reference line was drawn through Go and RP on both



**FIGURE 1.** (a–c) Tracings and PA radiographs from time points T1, T2, and T3.

sides up to the UOML, which was used as a reference plane. The following variables were measured.

1. Intergonion width (IGW): The distance between the left Go and the right Go (millimeters). This width was measured using a digital caliper (Fred Fowler Co, Newton, Mass) to the nearest 10th of a millimeter.
2. Left (LRA) and right (RRA) ramus angles: The right and left inferior-medial angles between the UOML and Go-RP lines (degrees). These angles were measured using a protractor to the closest degree.

### Lateral cephalometric radiographs

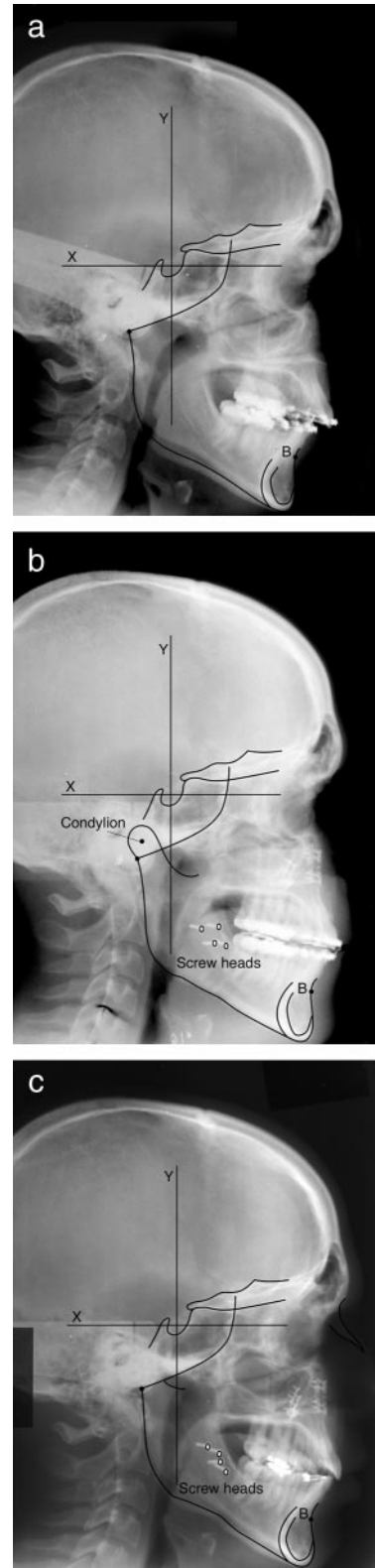
The lateral cephalometric radiographs were used to measure the horizontal and vertical changes in condylion and B point according to the method described by Rebellato et al.<sup>10</sup> In addition to the anterior cranial base outline, the reference points and lines drawn on the T1, T2, and T3 tracings are shown in Figure 2a–c, respectively, and are as follows.

- B point: The most posterior point on the anterior surface of the symphysis.
- X-axis: A plane parallel to the Frankfort horizontal plane; the x-axis was transferred from the T1 to the T2 and T3 tracings by superimposition on the anterior cranial base.
- Y-axis: An axis perpendicular to the x-axis.
- Screw heads: Outlines of the fixation screw heads were drawn on the T2 and T3 tracings.
- Condylion: Approximate geometric center of the condylar head of the mandible, determined by visual inspection (only performed on the T2 tracing).

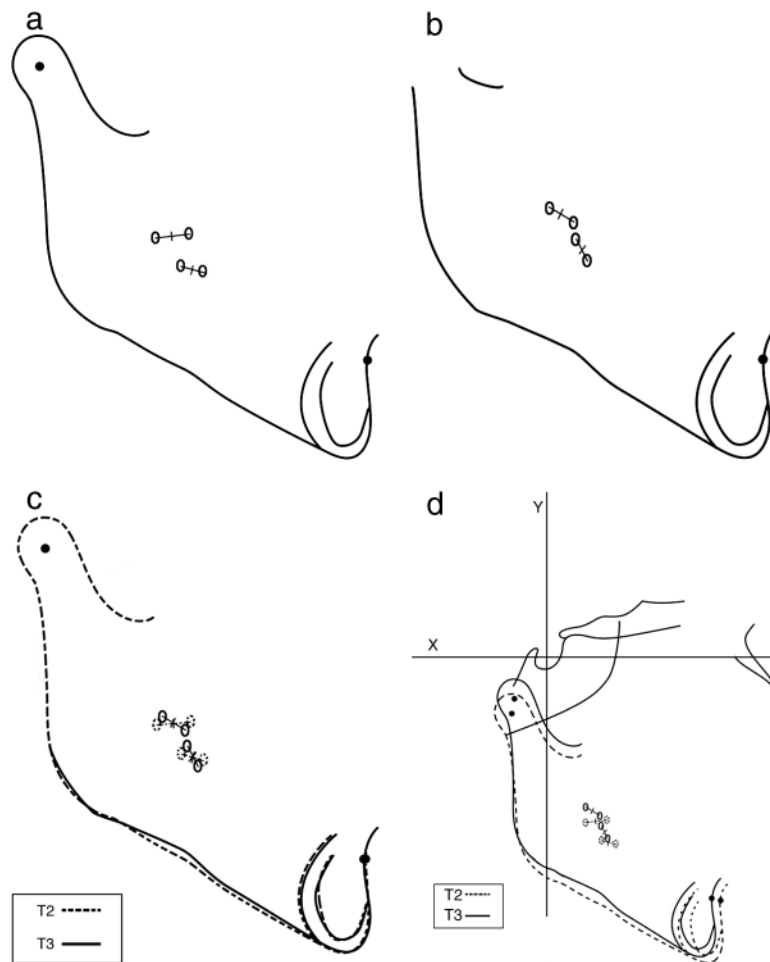
To determine any changes for B point in the horizontal and vertical dimensions, the T1 tracings were compared with the T2 and T3 tracings by superimposing on the anterior cranial base outline. Location of B point on the T1, T2, and T3 tracings was recorded each time as x, y coordinates.

To determine the sagittal changes for the condylar part of the proximal segment, the pairs of bilateral screws were connected with lines and the bisecting center of each line was marked as in Figure 3a. The same identical pairs of bilateral screws as were used on the T2 tracing were identified on the T3 tracing, and a line connecting the same screw pairs was drawn and the lines bisected as on the T2 tracing (Figure 3b).

Condylion was then transferred forward to the T3 tracing by superimposing the T2 and T3 tracings on B point and the points bisecting the lines connecting the screw pairs (Figure 3c). T2 and T3 were then superimposed back on the anterior cranial base to compare the movement of condylion (Figure 3d). Location of condylion on the T2 and T3 tracings was recorded



**FIGURE 2.** (a–c) Tracings and lateral cephalometric radiographs from time points T1, T2, and T3.



**FIGURE 3.** (a) Tracing of mandible from T2 lateral cephalogram with condyion identified and lines connecting bilateral pairs of screws bisected in the center. (b) Tracing of mandible from T3 lateral cephalogram with lines connecting bilateral pairs of screws bisected in the center. (c) Condyion transferred from T2 to T3 tracing by superimposing on B point and the points bisecting the lines connecting pairs of screw heads. (d) T2 and T3 superimposed on anterior cranial base to compare movement of B point and Condyion.

each time as x, y coordinates. All coordinate measurements (relative to the x- and y- axes) were measured using a digital caliper (Fred Fowler Co) to the nearest 10th of a millimeter.

### Interexaminer reliability

Two separate investigators independently traced and measured all 25 patients. The investigators had received no special training except for reading the articles by Rebellato et al<sup>10</sup> and Becktor et al.<sup>11</sup> The interexaminer reliability (ie, level of agreement) between the two investigators was estimated by calculating the intraclass correlation coefficient (ICC).<sup>22</sup> The ICC assesses the correlation between repeated measurements on the same patient, and its interpretation is similar to that of a correlation coefficient. The values range from  $-1$  to  $1$ . Values in the range of  $0-0.2$  indicate slight agreement,  $0.2-0.4$  fair,  $0.4-0.6$  moderate,  $0.6-0.8$  substantial, and  $0.8-1.0$  almost perfect

agreement. The 95% confidence interval for the ICC estimates was also calculated.

### RESULTS

The results of the statistical analyses are shown in Table 1. For the IGW, the ICC was found to be very high, with a value of  $0.98$ , indicating "almost perfect agreement." Regarding the variables that represented angular measures (ie, LRA and RRA), the ICC for these variables was also found to be high, indicating almost perfect agreement, ranging from  $0.93$  to  $0.97$ .

B point is a landmark that has been extensively used and has been well documented as a reliable reference point. The ICC in this study was found to have a high value, ranging from  $0.92$  to  $0.93$ , indicating almost perfect agreement.

Condyion was located on the T2 and T3 tracings as an x, y coordinate in millimeters relative to the x- and y-axes. The ICC, ranging from  $0.74$  to  $0.81$ , dem-



**TABLE 1.** Interexaminer Reliability Scores

Variables <sup>a</sup>	Agreement (Interexaminer Reliability) Based on N = 25 Patients	
	ICC <sup>b</sup>	95% CI <sup>c</sup>
IGW		
T1	0.98	0.95–0.99
T2	0.98	0.96–0.99
T3	0.98	0.90–0.99
LRA		
T1	0.96	0.92–0.98
T2	0.97	0.93–0.99
T3	0.93	0.76–0.98
RRA		
T1	0.93	0.83–0.97
T2	0.93	0.84–0.97
T3	0.94	0.86–0.97
B point (x coordinate)		
T1	0.93	0.84–0.97
T2	0.92	0.83–0.96
T3	0.93	0.84–0.97
B point (y coordinate)		
T1	0.93	0.76–0.97
T2	0.94	0.86–0.98
T3	0.94	0.86–0.97
Condylion (x coordinate)		
T2	0.74	0.49–0.88
T3	0.77	0.55–0.89
Condylion (y coordinate)		
T2	0.76	0.53–0.89
T3	0.81	0.62–0.91

<sup>a</sup> IGW indicates intergonial width; LRA, left ramus angle; and RRA, right ramus angle.

<sup>b</sup> ICC indicates intraclass correlation coefficient.

<sup>c</sup> 95% CI, 95% confidence interval for the ICC estimates.

onstrated “substantial” agreement between examiners, but not an almost perfect agreement as with B point.

## DISCUSSION

The inherent errors in cephalometric technique have been extensively studied.<sup>23–25</sup> For example, one such source of error is that, although the radiographs were taken by experienced technicians, some degree of up and down tilting of the head is inevitable. However, a change of up to 10° of up and down movement or right and left rotation of the head has been shown to be less than the method error and therefore a negligible factor in breadth measurements on PA cephalograms.<sup>26</sup>

Identification error, reported to be the main source of error, arises largely through uncertainty in the visual identification of radiographic landmarks.<sup>12–15</sup> The reproducibility of the measurements varies according to the quality of the records, the conditions under which

they are measured, and the care and skill of the measurer. It is for this reason that every study should include an assessment of the method error, although standard measurements are used.<sup>14</sup> The method error can be assessed by double determination. Each measurement is repeated on two occasions and the differences are noted. Dahlberg's formula<sup>27</sup> can be applied to calculate the standard error, ie, method error.

Richardson<sup>28,29</sup> found that interobserver variability was slightly higher than intraobserver variability in locating cephalometric landmarks. Other investigators have also reported interobserver variability as higher than the intraobserver variability.<sup>30</sup> Stabrum and Danielsen<sup>31</sup> had two observers make dual determinations of various landmarks on 100 cephalograms. Disagreement in interoperator determinations was found despite the standardization training exercise. In our study, both investigators received the same level of instructions and training. The level of agreement varied depending on the landmark under investigation as demonstrated by the ICC, ranging from 0.98 (“almost perfect” agreement) to 0.74 (substantial agreement) depending on the variable measured.

Lau et al<sup>32</sup> concluded that the amount of interexaminer error did not depend on training or experience but probably on individual conception of landmark definition and perception of landmark location. Savage et al<sup>17</sup> reported that the level of observer experience and quality of radiograph were statistically unrelated to landmark variability on replicate examination.

Kragstov et al<sup>19</sup> compared the reliability of anatomic cephalometric points from conventional cephalograms and 3-D CT. They concluded that although 3-D CT may be more beneficial in craniofacial syndrome patients, there is no evidence that 3-D CT is more reliable than the conventional cephalometric method in normal skull patients.

## PA cephalometrics

Major et al<sup>20</sup> concluded that there was a considerable range in the magnitude of error with horizontal and vertical values, and interexaminer landmark identification error was significantly larger than intraexaminer error for many PA cephalometric landmarks. Their study reported an intraexaminer error of 0.31 mm for Go (x coordinate). Becktor et al<sup>11</sup> reported their method error for IGW (linear distance connecting both Go points) as 0.21 mm.

Becktor et al<sup>11</sup> reported their method error for determining the ramus angles as 0.45° (left) and 0.47° (right). Other than Becktor et al,<sup>11</sup> it appears that the only other authors to have reported a method error for measurements of the ramus angle relative to the UOML are Astrand and Ericson.<sup>33</sup> They reported a

method error range of  $0.3^\circ$  to  $0.7^\circ$ , although they were measuring the angle of the condylar fragment to the UOML (they studied patients who underwent oblique sliding osteotomy of the mandibular rami).

### Lateral cephalometrics

Baumrind and Frantz<sup>12,13</sup> showed that each lateral cephalometric point has a characteristic pattern of recording error, some points being more reliable in either vertical or horizontal planes. Tng et al<sup>34</sup> showed that many landmarks were invalid along one or both of the x- or y-axes, with each landmark having its own characteristic envelope of error. The mean difference for B point was small, but the standard deviation along the y-axis was large. B point gives a high degree of reliability in anteroposterior plane but much less in the vertical plane.<sup>35</sup>

Van Sickels et al<sup>36</sup> studied condylar positional changes after Bilateral Sagittal Split Ramus Osteotomy (BSSRO) using lateral cephalometric radiographs. In their study, condylar position was traced on a preoperative radiograph and transferred from one radiograph to another by superimposing on a template of the ramus. However, orthognathic surgery often alters the skeletal landmarks and bony configurations that are commonly used for cephalometric analysis.

Recent studies with titanium markers have demonstrated positional stability between proximal and distal segments after BSSRO of the mandible with rigid internal fixation.<sup>37–39</sup> Therefore, the postsurgical mandible can be considered a single rigid body. Rebellato et al<sup>39</sup> described a method to determine postoperative condylar movements without actually having to directly image the temporomandibular joints. B point was used as the anterior marker and the RIF screws as the posterior markers, enabling a planar, two-dimensional description of mandibular motion to be derived. A change in the position of the condyles can be indirectly obtained by measuring the change in the position of condylion from one postsurgical tracing to the next (in this study, T2 vs T3). This approach also compensates for any head positioning error between radiographic exposures.<sup>40</sup>

Rebellato et al reported a method error for condylion movement (T3-T2) of 0.79 mm (vertical movement) and 0.80 mm (horizontal movement). Identification of the exact location of condylion is not critical for the Rebellato et al method, however, because condylion is transferred forward from one postsurgical radiograph to the next (in this case, T2 to T3). Condylion is transferred forward by superimposing on B point and the posterior markers (ie, points bisecting the lines connecting contralateral screw head pairs). The movement of condylion from T2 to T3 is what is important,

and all points in the general vicinity of condylion would move in a similar magnitude and direction.<sup>41</sup> The results of this study demonstrated substantial agreement between examiners in locating condylion movements but not almost perfect agreement as that with B point.

### CONCLUSIONS

- Interexaminer reliability was found to be high, ranging from substantial to “almost perfect” agreement between two independent examiners.
- These results support the use of these two methods to determine proximal segment changes after BSSRO in the frontal and sagittal planes of space, whether for research or clinical purposes.

### ACKNOWLEDGMENTS

We thank Laurie Furr, CDA, RDA, for creating a computerized surgical database, and Amy Weaver, MS, for statistical assistance.

### REFERENCES

1. Proffit WR, Phillips C, Dann C 4th, Turvey TA. Stability after surgical-orthodontic correction of skeletal Class III malocclusion. I. Mandibular setback. *Int J Adult Orthod Orthognath Surg.* 1991;6:7–18.
2. Schendel SA, Epker BN. Results after mandibular advancement surgery: an analysis of 87 cases. *J Oral Surg.* 1980;38:265–281.
3. Stroster TG, Pangragio-Kulbersh V. Assessment of condylar position following bilateral sagittal split ramus osteotomy with wire fixation or rigid fixation. *Int J Adult Orthod Orthognath Surg.* 1994;9:55–63.
4. Will LA, Joondeph DR, Hohl TH, West RA. Condylar position following mandibular advancement: its relationship to relapse. *J Oral Maxillofac Surg.* 1984;42:578–588.
5. Hackney FL, Van Sickle JE, Nummikoski PV. Condylar displacement and temporomandibular joint dysfunction following bilateral sagittal split osteotomy and rigid fixation. *J Oral Maxillofac Surg.* 1989;47:223–227.
6. Alder ME, Deahl ST, Matteson SR, Van Sickels JE, Tiner BD, Rugh JD. Short-term changes of condylar position after sagittal split osteotomy for mandibular advancement. *Oral Surg Oral Med Oral Pathol Oral Radiol Endod.* 1999;87:159–165.
7. Harris MD, Van Sickle JE, Alder M. Factors influencing condylar position after the bilateral sagittal split osteotomy fixed with bicortical screws. *J Oral Maxillofac Surg.* 1999;57:650–654.
8. Lee W, Park JU. Three-dimensional evaluation of positional change of the condyle after mandibular setback by means of bilateral sagittal split ramus osteotomy. *Oral Surg Oral Med Oral Pathol Oral Radiol Endod.* 2002;94:305–309.
9. Kawamata A, Fujishita M, Nagahara K, Kanematu N, Niwa K, Langlais RP. Three-dimensional computed tomography evaluation of postsurgical condylar displacement after mandibular osteotomy. *Oral Surg Oral Med Oral Pathol Oral Radiol Endod.* 1998;85:371–376.
10. Rebellato J, Lindauer SJ, Sheats RD, Isaacson RJ. Condylar positional changes after mandibular advancement surgery with rigid fixation. *Am J Orthod Dentofacial Orthop.* 1999;116:93–100.

11. Becktor JP, Rebellato J, Becktor KB, Isaksson S, Vickers PD, Keller EE. Transverse displacement of the proximal segment after bilateral sagittal osteotomy. *J Oral Maxillofac Surg.* 2002;60:395–403.
12. Baumrind S, Frantz RC. The reliability of cephalometric radiograph measurements. 1. Landmark identification. *Am J Orthod Dentofacial Orthop.* 1971;60:111–127.
13. Baumrind S, Frantz RC. The reliability of head film measurements. 2. Conventional angular and linear measures. *Am J Orthod Dentofacial Orthop.* 1971;60:505–517.
14. Houston WJB. The analysis of errors in orthodontic measurements. *Am J Orthod Dentofacial Orthop.* 1983;83:382–390.
15. Houston WJ, Maher RE, McElroy D, Sherriff M. Sources of error in measurements from cephalometric measurements from cephalometric radiographs. *Eur J Orthod.* 1986;8:149–151.
16. Bjork A, Solow B. Measurements on radiographs. *J Dent Res.* 1961;41:672–683.
17. Savage AW, Showfety KJ, Yancey J. Repeated measures analysis of geometrically constructed and directly determined cephalometric points. *Am J Orthod Dentofacial Orthop.* 1987;91:295–299.
18. Sandler PJ. Reproducibility of cephalometric measurements. *Br J Orthod.* 1988;15:105–110.
19. Kragstov J, Bosch C, Gydensed C. Comparison of the reliability of craniofacial anatomic landmarks based on cephalometric radiographs and three dimensional CT scans. *Cleft Palate Craniofac J.* 1997;34:111–116.
20. Major PW, Johnson DE, Hesse KL. Landmark identification error in posterior anterior cephalometrics. *Angle Orthod.* 1994;64:447–454.
21. Ongkosuwito EM, Katsaros C, van't Hof MA. The reproducibility of cephalometric measurements: a comparison of analogue and digital methods. *Eur J Orthod.* 2002;24:655–665.
22. Shrout PE, Fleiss JL. Intraclass correlations: uses in assessing rater reliability. *Psych Bull.* 1979;86:420–428.
23. Adams JW. Correction of error in cephalometric roentgenograms. *Angle Orthod.* 1940;10:3–13.
24. Ahlqvist J, Eliasson S, Welander U. The cephalometric projection. Part II. *Dentomaxillofac Radiol.* 1983;12:101–108.
25. Ahlqvist J, Eliasson S, Welander U. The effect of projection errors on angular measurements in cephalometry. *Eur J Orthod.* 1988;10:353–361.
26. Ishiguro K, Krogman WM, Mazaheri M, Harding RL. A longitudinal study of morphological craniofacial patterns via PA x-ray headfilms in cleft patients from birth to six years of age. *Cleft Palate J.* 1976;13:104–126.
27. Dahlberg G. *Statistical Methods for Medical and Biological Students.* New York, NY: Interscience; 1940;81–89.
28. Richardson A. A comparison of traditional and computerized methods of cephalometric analysis. *Eur J Orthod.* 1981;3:15–20.
29. Richardson A. An investigation into the reproducibility of some points, planes and lines used in cephalometric analysis. *Am J Orthod Dentofacial Orthop.* 1966;52:637–651.
30. Broadway ES, Healy MJ, Poyton HG. The accuracy of tracings from cephalometric lateral skull radiographs. *Dent Pract.* 1966;12:455–458.
31. Stabrum AE, Danielsen K. Precision in cephalometric landmark identification. *Eur J Orthod.* 1982;4:185–196.
32. Lau PY, Cooke MS, Hägg U. Effect of training and experience on cephalometric measurement errors on surgical patients. *Int J Adult Orthod Orthognath Surg.* 1997;12:204–213.
33. Astrand P, Ericson S. Relation between fragments after oblique sliding osteotomy of the mandibular rami and its influence on postoperative conditions. *Int J Oral Surg.* 1974;3:49–59.
34. Tng TT, Chan TC, Hägg U. Validity of cephalometric landmarks. An experimental study on human skulls. *Eur Orthod Soc.* 1994;16:110–120.
35. Cohen AM. Uncertainty in cephalometrics. *Br J Orthod.* 1984;11:44–48.
36. Van Sickels JE, Tiner BD, Keeling SD, Clark GM, Bays R, Rugh J. Condylar position with rigid fixation versus wire osteogenesis of a sagittal split advancement. *J Oral Maxillofac Surg.* 1999;57:31–34.
37. Tiner BD, Keeling SD, Rubenstein LK, Strauss RA, Lindauer SJ, Davidovitch M, Isaacson RJ. Tantalum implants as markers for evaluating postoperative orthognathic surgical changes. *Int J Adult Orthod Orthognath Surg.* 1993;8:203–209.
38. Strauss RA, Rubenstein LK. A technique for accurate long-term follow-up of segment positional changes following sagittal split osteotomies. *J Oral Maxillofac Surg.* 1993;51:815–816.
39. Rebellato J, Lindauer SJ, Isaacson RJ, Davidovitch M. Relapse of BSSRO with rigid fixation: an implant study. *J Dent Res.* 1994;73(suppl):28.
40. Spolyar JL. Head positioning error in cephalometric radiology: an implant study. *Angle Orthod.* 1987;57:77–88.
41. Panjabi MM. Centers and angles of rotation of body joints: a study of errors and optimization. *J Biomech.* 1979;12:911–920.