

# Mesiodistal Root Angulation Using Panoramic and Cone Beam CT

James L. Peck<sup>a</sup>; Glenn T. Sameshima<sup>b</sup>; Arthur Miller<sup>c</sup>; Peter Worth<sup>d</sup>; D.C. Hatcher<sup>e</sup>

## ABSTRACT

**Objective:** To determine if the panoramic projection can accurately determine mesiodistal root angulations.

**Materials and Methods:** A plaster study model of the dentition of each of five patients was prepared. A radiographic stent containing radiopaque markers was fabricated for each of the models. Panoramic and cone beam computed tomography (CBCT) scans were taken on each patient with the radiographic stent seated on the dentition. Root angulations for each of the radiographic images were measured and compared.

**Results:** Root angulation was measured by three independent individuals and good reliability between measurements was demonstrated. Compared to plaster model measurements (the gold standard), the CBCT scan produced very accurate measurements of root angulation. Compared to CBCT images, panoramic projections did not provide reliable data on root angulation.

**Conclusion:** Panoramic images did not accurately represent the mesiodistal root angulations on clinical patients.

**KEY WORDS:** Root angulation; Cone beam CT; Panoramic projection

## INTRODUCTION

Visualization of craniofacial anatomy is integral to understanding biomechanical relationships in the face and jaws. The current orthodontic patient record generally consists of intraoral and extraoral photographs; periapical, panoramic, and cephalometric radiographs; and study models. These records serve key roles in diagnosis, treatment planning, communication, treatment progress, and outcome evaluation. However, these records are static and are limited in providing two-dimensional representation of three-dimensional anatomy. They provide limited spatial representation and contain distortions and information voids.

A major objective of orthodontic treatment is to correct tooth positions in three planes of space so that

they approach predetermined cephalometric and occlusal standards.<sup>1</sup> One of the keys to ideally positioned teeth is proper mesiodistal axial inclination (tip).<sup>2</sup> The relative angulation of the roots of the maxillary and mandibular teeth is a factor in the American Board of Orthodontics examination.<sup>3</sup>

Panoramic projections are routinely used by the orthodontic profession to meet the following imaging goals: identify present and missing teeth, identify supernumerary teeth, assess root length and root alignment, and identify deviations in mandibular and temporomandibular joint (TMJ) form. The panoramic projection is often used to assess the quality of midtreatment root alignment. If the ideal root alignment is not met, the teeth may be rebracketed to change the root alignment based upon observations obtained from the panoramic projection.

Xie et al<sup>4</sup> stated that a panoramic radiograph provides a distorted and two-dimensional representation of a three-dimensional object. In principle, radiographic images are best suited for interpretation and measurements when the object and the film are parallel to one another and at right angles to some ray in the beam.<sup>5</sup> Panoramic images are no exception to this rule. It is apparent that there are large discrepancies between the optimal and the actual beam directions, especially in the premolar area.<sup>6</sup> Overlapping of teeth

<sup>a</sup> Private practice, Lincoln, Calif.

<sup>b</sup> Associate Professor, Department of Orthodontics, School of Dentistry, University of Southern California, Los Angeles, Calif.

<sup>c</sup> Professor, Department of Growth and Development, University of California San Francisco, San Francisco, Calif.

<sup>d</sup> Private practice, Roseville, Calif.

<sup>e</sup> Private practice, Sacramento, Calif.

Corresponding author: Dr James L. Peck, 113 Lasso Lake Court, Lincoln, CA 95648 (e-mail: ajpeck4057@aol.com)

Accepted: April 2006. Submitted: January 2006.

© 2006 by The EH Angle Education and Research Foundation, Inc.

is particularly prominent in the premolar area. Scarfe et al<sup>6</sup> concluded that the ideal beam projection angle required to provide open contacts between teeth changed along the arch. Large discrepancies exist in the projection angles of many panoramic units when compared with the interproximal contact angulations.

Commonly used panoramic projections typically magnify and distort the resulting image. The magnification in the horizontal and vertical dimensions varies with respect to position along the object and object depth.<sup>7</sup> The average vertical and horizontal magnification at the focal trough on a panoramic image obtained using an OP100 panoramic unit (Instrumentarium Dental, PO Box 20, FL-04301 Tuusula, Finland) is 1.29%.<sup>8</sup> Head positioning, geometry of the patient, and rotational parameters of the machine can all produce effects that do not accurately represent the patient.<sup>9</sup> It is expected that an x-ray beam that is not horizontally perpendicular to the jaw surface when imaging adjacent teeth that possess differences in buccolingual angulations (torque) would create a false perception that the root misalignment was in a mesiodistal direction (tip). Any change in inclination of the teeth in the buccolingual plane is recorded as a change in the mesiodistal angulation of the teeth concerned, with the canine and premolar region being the most susceptible.<sup>10</sup> Therefore, the use of the panoramic radiograph to assess postextraction root angulations in these areas may be of dubious value.<sup>11</sup>

Most of today's cephalometric standards have been based on two-dimensional radiological records of three-dimensional objects. Limitations of the panoramic image may have led to the use of a conglomeration of geometrically unrelated and inaccurate two-dimensional images that are used for diagnosis and treatment planning. True mesiodistal angulations compared to their panoramic representations need to be assessed. McKee et al<sup>12</sup> used a test phantom patient to compare the true mesiodistal angulations of teeth to those produced by four different types of panoramic units. They concluded that panoramic projections altered the perception of mesiodistal root angulations on their test phantom. These findings were not confirmed in a patient population. The goal of this study was to determine whether panoramic projections provide a true assessment of mesiodistal root angulations in clinical patients.

Computer-assisted imaging is now creating the opportunity for the orthodontic profession to better visualize and study the craniofacial anatomy. A new computer-assisted imaging device, the NewTom (9000, Verona, Italy), creates a three-dimensional replication of the patient in the form of a "digital image volume." The digital image volume can be used to assess the craniofacial and dental anatomy. Data from these im-

ages is stored on a disk and sent to a computer for review by orthodontists, prosthodontists, oral surgeons, radiologists, or other treating personnel.

Software tools allow the orthodontic practitioner to interactively manipulate the digital image volume and visualize and measure the anatomy from any desired point of view. The NewTom 9000<sup>13</sup> is manufactured in Italy and received FDA approval in April 2001. It is designed specifically to image the maxillofacial region. The patient exposure effective dose is 50  $\mu$ Sv, significantly less than that of a high-resolution CT scan and similar to that of a dental periapical full-mouth series.<sup>13,14</sup> The spatial resolution is significantly higher than that generated from a CT scan and the cost per study is comparable to other forms of dental imaging. The voxel size for the NewTom is 0.28 mm in the x, y, and z planes, allowing very good image resolution in all of the reformatted viewing planes. Applying the Nyquist sampling frequency, a voxel size of 0.28 mm will allow the detection of all features that are at least 0.56 mm in size. The NewTom software allows for reformatting the data into multiplaner slices, curved plane slices, and three-dimensional viewing. Taking into consideration the criteria for evaluating imaging input devices, including a balance between high diagnostic yield, low cost, and low risk, the NewTom may prove to be favorable.

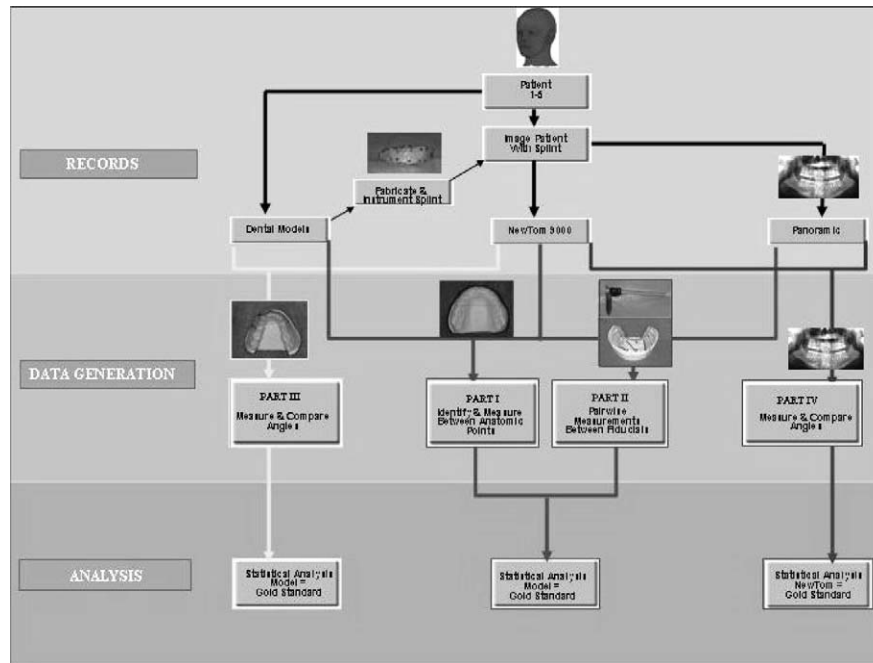
## MATERIALS AND METHODS

Figure 1 illustrates the research strategy and methods. Two male and three female Caucasian subjects, ranging in age between 11 and 55, were selected for this study prior to orthodontic treatment. The following records were obtained on all subjects:

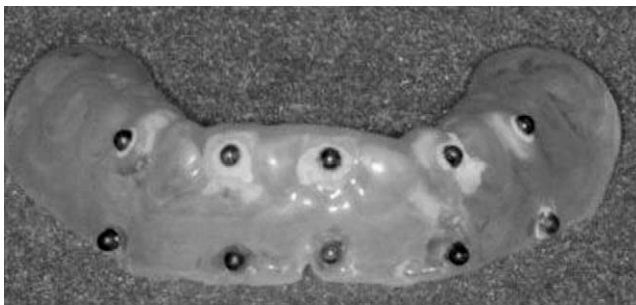
- Plaster study models of the dentition.
- Panoramic radiographic images with the Instrumentarium OP100.
- CBCT scans with the NewTom 9000.

The panoramic and CBCT scans were acquired with a radiographic stent containing radiopaque markers (Figure 2). The splint was fabricated using 2-mm-thick soft Biostar mouth guard material (Great Lakes Orthodontics Item #270, Great Lakes Orthodontics, Ltd, Tonawanda, NY) vacuum fitted with a Biostar apparatus.


The study was divided into four parts (Figure 1). Parts I, II, and III used the measurements from the models as the gold standard. These measurements were compared with measurements obtained from the panoramic and/or CBCT image sets. Part IV used the angle measurements obtained from the CBCT as the gold standard. These measurements were compared to similar measurements obtained from panoramic



**Figure 1.** This block diagram illustrates the research strategy and methods.



**Figure 2.** The radiographic stent is shown with ball bearings located near the occlusal plane and approximating the root surface.



**Figure 3.** The anatomic landmarks were identified and marked with small dots on the maxillary cast. Five pairwise measurements were made between the selected anatomic landmarks, as indicated in the figure with lines.

projections. Parts I, II, and III were performed to validate CBCT images so that they could be used as the gold standard to evaluate the panoramic measurements (Part IV).

Part I of this study was to identify and measure the distance between selected anatomic features on the study models and compare them to the same measurements from panoramic and CBCT images (Figure 3). Part II of this study consisted of pairwise measurements between the centroids of selected ball bearings contained in the radiographic stent. The measurements were made with the radiographic stent seated on the study model and compared to the same measurements made on the panoramic and the NewTom images (Figure 4). Millimeter measurements to the nearest hundredth were made on the study model and the panoramic projections using an electronic digital caliper (Figure 5), and the NewTom software was used

to take these same measurements on the CBCT image.

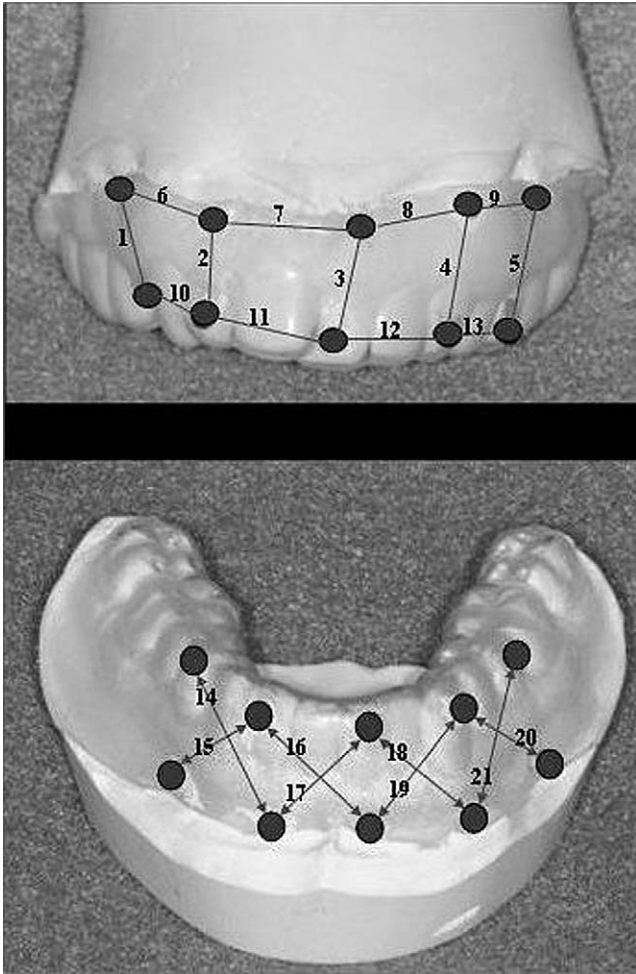
In part III, angle measurements between selected markers on the radiographic stent were compared with the same angle measurement on the CBCT images (Figure 6).

Part IV of this study compared the mesiodistal root inclination angle revealed on the panoramic projection to the same measurements on the reconstructed panoramic image from the CBCT volume (Figure 7).


### Interrater Reliability

The ball bearing measurements on both the maxillary and mandibular were compared among the three judges to measure their reliability. The data was evaluated by both a correlation matrix and a single factorial



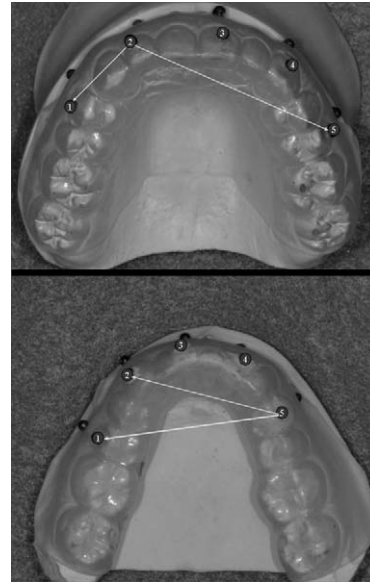


**Figure 4.** Twenty-one pairwise measurements were made between the ball bearings using electronic digital calipers for each arch, measuring the illustrated combination of bearings.

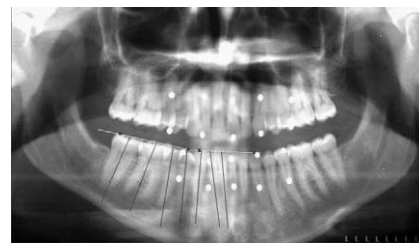


**Figure 5.** Electronic digital caliper used to make physical measurements to the nearest 0.01 mm.

ANOVA with the level of significance set at  $P < .05$ . The correlation matrix indicated a high correlation among the three judges. The ANOVA indicated no statistical difference in the judges' measurements for both the maxilla and the mandible.



**Figure 6.** Three angle measurements were made for each arch. The ball bearings were numbered 1 through 5, and the measurements were as follows: maxillary arch, 1-2-5, 1-3-5, and 1-4-5; mandibular arch, 1-5-4, 2-1-5, and 2-1-3. The images above show the 1-2-5 angle measurement for the maxilla and the 1-5-2 measurement for the mandible.



**Figure 7.** This figure illustrates the panoramic angle measurements for the mandibular right quadrant. The cusp tips, posterior and anterior portions of the occlusal plane, and long axes of the teeth were marked. The measured angle was formed between the long axis of the teeth and the occlusal plane.

**RESULTS**

**Part I. Identifying and Measuring the Distance Between Selected Anatomic Features**

The mean and standard deviation values obtained from the panoramic projections and the NewTom digital images of the models are provided in Table 1. A comparison of the same measurements obtained from the panoramic and CBCT images revealed that the NewTom measurements were more similar to the measurements obtained from the models in all 10 data sets. A repeated analysis of variance (ANOVA) indicated that the NewTom was statistically significantly more accurate in 7 out of the 10 measurements.

**Table 1.** Part I. Maxillary Measurements Are 1–5 and Mandibular Measurements are 6–10<sup>a</sup>

Location	Pan/Mod Difference		New/Mod Difference		P	Significance
	Mean	SD	Mean	SD		
1	4.21	3.00	0.18	0.41	.007	**
2	2.45	2.82	-0.44	0.51	.059	ns
3	1.72	1.00	0.07	0.39	.012	*
4	0.81	1.21	0.02	1.05	.316	ns
5	3.88	2.91	-0.27	1.30	.009	**
6	6.21	1.36	-0.14	0.61	.000	***
7	3.98	2.31	0.44	0.31	.004	**
8	1.50	1.38	-0.06	0.48	.020	*
9	1.02	1.33	-0.32	1.71	.233	ns
10	2.08	2.15	0.28	0.54	.043	*

<sup>a</sup> Pan indicates panoramic projections; Mod, models; New, NewTom 9000; and ns, not significant.

\*  $P \leq .05$ ; \*\*  $P \leq .01$ ; \*\*\*  $P \leq .001$ .

## Part II. Pairwise Measurements Between the Centroids of Selected Ball Bearings Contained in the Radiographic Stent Compared to the Same Measurements on the Panoramic and NewTom Images

The mean and standard deviation values for the model, the panoramic projection, and the NewTom digital image are shown in Tables 2 and 3. The NewTom was statistically closer to the model in 15 out of 21 measurements in the maxilla and 12 out of 21 measurements in the mandible. The NewTom linear measurements were significantly closer in 27 of the 42 measurements.

## Part III. Comparing the Accuracy of Angles Measured on the Study Model to the Same Angles on the CBCT Image

The means and standard deviations for these angles are found in Table 4. It was found that there was no significant difference in five of the six angles.

## Part IV. Using the CBCT as the Gold Standard, a Comparison Was Made From the Mesial and Distal Tooth Angulations in the Anterior and Posterior of Each Arch on the Panoramic Projection vs the NewTom Digital Panoramic Image

The mean and standard deviation values for the CBCT (gold standard) and the panoramic projection are found in Table 5. There were significant differences in 75% of the measurements.

Figures 8 and 9 showed the overestimation and underestimation of the tooth angulations derived from the standard panoramic images. The maxillary anterior roots were overinclined in a mesial direction and the posterior roots were overinclined in a distal direction on the panoramic projections. The largest deviation from the gold standard was between the maxillary canines and the first premolars, where the average an-

gular difference was 10°. This creates an illusion that there is exaggerated root divergence between these teeth. The inclination for the mandibular anterior roots was not bilaterally symmetrical, whereas the trend for the mandibular posterior roots was for mesial inclination. The first premolars show the largest mesial inclinations of the mandibular teeth.

## DISCUSSION

The purpose of this study was to determine whether a panoramic projection could accurately determine the mesiodistal root angulations on clinical patients. Fulfilling the goal of this study required determining the true in vivo mesiodistal root angulations and comparing them to the panoramic measurements. The first three of the four parts of the study were designed to calibrate the CBCT as a gold standard root angulation measurement tool. Part 4 compared the CBCT gold standard root angulation results with those obtained on a standard panoramic projection. Because accurate root angle measurements are dependent on the accurate identification and determination of the three-dimensional locations of anatomic features representing the root and crown tips, both panoramic and CBCT images were tested and compared for this portion of the calibration process.

Part I of the CBCT calibration process was designed to determine how accurately anatomy could be identified and measured using both CBCT and panoramic images. Distances between selected anatomic study model features were compared to the same measurements made on panoramic and CBCT images. The results of this study showed that anatomic features could be identified and measured with accuracy and precision using the CBCT but not with the panoramic projection. This is consistent with the findings of Tronje et al<sup>7</sup> that measurements on panoramic images in the horizontal dimension are unreliable because of the marked variation in the horizontal magnification factor

**Table 2.** Part II—Maxilla

Location	Pan/Mod Difference		New/Mod Difference		P	Significance
	Mean	SD	Mean	SD		
1	3.19	0.55	0.24	0.25	.001	***
2	3.83	0.45	0.55	0.16	.000	***
3	3.70	0.43	0.41	0.37	.000	***
4	3.83	0.78	0.20	0.49	.001	***
5	3.52	0.79	0.16	0.41	.003	**
6	-0.16	0.54	-0.36	0.72	.499	ns
7	-1.14	1.16	0.06	0.41	.143	ns
8	-1.08	0.57	0.33	0.69	.015	*
9	-0.75	0.71	-0.07	0.49	.109	ns
10	-1.79	1.43	0.46	0.96	.090	ns
11	-1.57	0.96	0.30	0.47	.009	ns
12	-1.59	0.63	-0.21	0.47	.001	***
13	-0.73	0.55	0.49	0.48	.013	**
14	2.16	0.40	0.40	0.42	.005	**
15	1.40	1.19	-0.45	1.01	.115	**
16	2.11	0.69	0.58	0.69	.030	*
17	0.92	0.83	0.33	0.58	.193	ns
18	1.32	0.42	-0.16	0.35	.001	***
19	2.02	1.07	0.09	0.34	.015	*
20	2.26	1.33	0.73	0.33	.032	*
21	2.54	1.23	0.36	0.70	.023	*

<sup>a</sup> Pan indicates panoramic projections; Mod, plaster study models; New, NewTom 9000; and ns, not significant.  
 \*  $P \leq .05$ ; \*\*  $P \leq .01$ ; \*\*\*  $P \leq .001$ .

**Table 3.** Part II—Mandible

Location	Pan/Mod Difference		New/Mod Difference		P	Significance
	Mean	SD	Mean	SD		
1	3.28	0.65	0.15	0.33	.006	**
2	2.62	0.72	0.07	0.45	.002	**
3	2.38	0.55	0.12	0.41	.000	***
4	3.26	0.58	0.17	0.35	.002	**
5	3.14	0.66	0.15	0.21	.001	***
6	-0.23	1.00	0.53	0.14	.249	ns
7	-0.70	0.57	0.05	0.48	.164	ns
8	-0.19	0.57	0.91	0.57	.001	***
9	-2.13	3.81	0.72	0.70	.141	ns
10	1.59	1.10	0.37	0.50	.078	ns
11	0.04	0.80	0.34	0.29	.275	ns
12	0.27	0.84	0.46	0.70	.685	ns
13	0.19	0.71	0.03	0.37	.737	ns
14	3.60	0.24	0.81	0.44	.002	**
15	1.14	0.72	0.22	0.24	.019	*
16	1.87	0.55	0.32	0.38	.009	**
17	1.25	0.44	-0.32	0.32	.007	**
18	1.55	0.34	0.76	0.61	.071	ns
19	2.34	0.72	0.32	0.40	.000	***
20	1.45	1.16	0.38	0.43	.064	ns
21	2.64	0.09	0.41	0.24	.000	***

<sup>a</sup> Pan indicates panoramic projections; Mod, plaster study models; New, NewTom 9000; and ns, not significant.  
 \*  $P \leq .05$ ; \*\*  $P \leq .01$ ; \*\*\*  $P \leq .001$ .

with object depth and between different parts of the image.

Part II of this study was designed to benchmark the measurement accuracy of CBCT and the panoramic projection when anatomy identification was not a fac-

tor. The centroids of the ball bearings placed in the radiographic stent were used as measurement targets. The ball bearings were located in a stent to match the general locations of the root and cusp tips of the adjacent teeth. The results again showed that the pair-

**Table 4.** Part III. Angles—Models vs Newtom<sup>a</sup>

Angle	Models		NewTom		P	Significance
	Mean	SD	Mean	SD		
1	100.8	8.84	99.16	9.31	.011	*
2	102.5	5.2	102.82	6.3	.559	ns
3	96.8	2.41	96.14	3.42	.409	ns
4	18.8	4.33	18.7	4.35	.374	ns
5	20.1	0.22	19.78	0.61	.237	ns
6	20.1	3.36	18.66	4.95	.189	ns

<sup>a</sup> NewTom indicates NewTom 9000; ns, not significant.

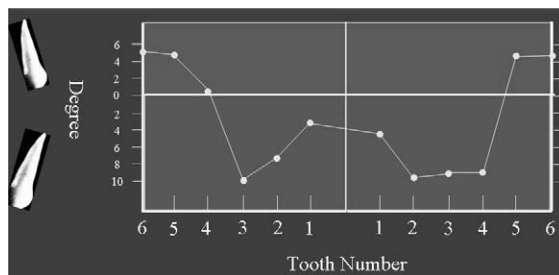
\*  $P \leq .05$ .

**Table 5.** Part IV. Angular Measurements by Arch<sup>a</sup>

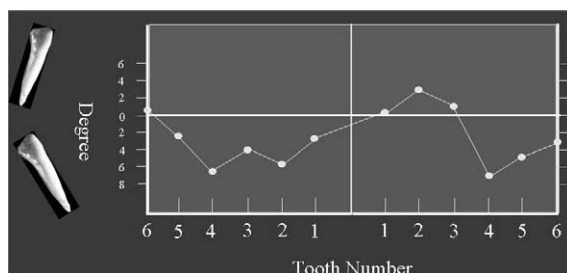
Tooth	Pan		NewTom		P	Significance
	Mean	SD	Mean	SD		
Mx post	101.81	7.36	98.58	7.44	.000	***
Md post	93.41	7.08	97.00	4.95	.000	***
Mx ant	89.32	5.17	96.16	6.92	.000	***
Md ant	90.69	7.08	91.62	5.92	.360	ns

<sup>a</sup> Mx indicates maxilla; post, posterior; Md, mandible; ant, anterior; and ns, not significant.

\*  $P \leq .05$ ; \*\*  $P \leq .01$ ; \*\*\*  $P \leq .001$ .



**Figure 8.** This figure displays the calculated maxillary root angle differences between the panoramic projection and the CBCT. The teeth are numbered in order on the horizontal axis, and the degree of root angle difference is on the vertical axis. The teeth with a mesial tip of the root apex are shown on the lower half of the figure, and the teeth with a distal tip of the root apex are shown on the upper half of the figure.



**Figure 9.** This figure displays the calculated mandibular root angle differences between the panoramic projection and the CBCT. The teeth are numbered in order on the horizontal axis, and the degree of root angle difference is on the vertical axis. The teeth with a mesial tip of the root apex are shown on the lower half of the figure, and the teeth with a distal tip of the root apex are shown on the upper half of the figure.

wise measurements between the radiographic markers were accurate and precise when using the CBCT, but not with the panoramic projection.

Part III of the study was designed to determine whether the CBCT could accurately determine angular measurements. No significant differences were detected between six angular measurements physically made with a protractor on models and the same measurements made with a digital protractor on the CBCT volume. The panoramic projection was not included in this portion of the study because the reference orientation of the point cloud used for the CBCT and model measurements could not be matched with the panoramic projection.

Analysis of Parts I, II, and III indicated that there were no statistically significant differences in the linear and angular measurements produced from the gold standard method of physical model measurements and the corresponding measurements produced using the digital tools on a CBCT volume. Parts I, II, and III of this study validated the use of a CBCT as a gold standard tool for Part IV.

Part IV measured mesiodistal root angulation as displayed on a CBCT reconstructed panoramic image and compared these measurements with the same measurements made on a standard panoramic projection.

The mean differences between those angles produced by the panoramic image and the true mesiodistal angulations were then tabulated. The results show that in the maxilla, the largest angular distance be-



tween adjacent teeth occurred between the canine and the first premolar. This means that the canines and premolars will tend to show a greater divergence of the roots on the panoramic image than actually exists. Therefore, tipping the teeth until the roots appeared parallel on the panoramic image would actually create excessive convergence of the canine and the first premolar roots.

The standard panoramic projection created the false impression that all of the maxillary anterior teeth were mesially tilted whereas all of the maxillary posterior teeth were distally tilted. In the mandible, the results were not bilaterally symmetrical, with the majority of the teeth showing excessive mesial angulation on the panoramic projection. McKee's<sup>12</sup> results on a fabricated model imaged with four different panoramic units were similar to the results of this study, which used five different patients and one panoramic unit. McDavid et al,<sup>5</sup> Samawi and Burke,<sup>10</sup> and Phillip and Hurst<sup>15</sup> also found the largest amounts of angle distortion in the canine and premolar regions.

This study showed that a panoramic projection is not a reliable imaging tool for assessing mesiodistal root angulation, particularly in the premolar and canine regions of the mouth. The CBCT is an accurate alternative to panoramic projections. The CBCT produces an accurate anatomic volume of the patient's anatomy. Visualization and analysis software tools allow the clinician to extract the relevant information from the CT volume.

## CONCLUSIONS

- Panoramic projection is a good screening projection tool, but does not provide precise reliable information related to root angulation, particularly in the canine and premolar regions of the jaws.
- The introduction of CBCT creates the opportunity for clinicians to acquire the highest-quality diagnostic images with an absorbed dose that is comparable to that of other dental surveys and less than that of a conventional CT.<sup>13,14</sup>
- The large field of view and three-dimensional image set offered by CBCT creates the opportunity for the clinician to adequately assess the jaws, teeth, occlusion, TMJs, and other factors that may be associated

with the total success of orthodontic rehabilitation of the patient's occlusion.

## REFERENCES

1. McNamara JA Jr. A method of cephalometric evaluation. *Am J Orthod.* 1984;86:449–469.
2. Andrews LF. The six keys to normal occlusion. *Am J Orthod.* 1972;62:296–309.
3. American Board of Orthodontics. *Information for Candidates.* St. Louis, MO: American Board of Orthodontics; 2001; 13.
4. Xie Q, Soikkonen K, Wolf J, Mattila K, Gong M, Ainamo A. Effect of head positioning in panoramic radiography on vertical measurements: an in vitro study. *Dentomaxillofac Radiol.* 1996;25:61–66.
5. McDavid WP, Tronje G, Welander U, Morris CR, Nummikoski P. Imaging characteristics of seven panoramic x-ray units: projection angle. *Dentomaxillofac Radiol.* 1985; 8(suppl):21–28.
6. Scarfe WC, Nummikoski P, McDavid WD, Welander U, Tronje G. Radiographic interproximal angulations: implications for rotational panoramic radiography. *Oral Surg Oral Med Oral Pathol.* 1993;76:664–672.
7. Tronje G, Welander U, McDavid WD, Morris CR. Imaging characteristics of seven panoramic x-ray units: horizontal and vertical magnification. *Dentomaxillofac Radiol.* 1985; 8(suppl):29–34.
8. Scarfe WC, Eraso FE, Farman AG. Characteristics of the orthopantomograph OP100. *Dentomaxillofac Radiol.* 1998; 27:51–57.
9. Harrell WE, Hatcher DC, Bolt RL. In search of anatomic truth: 3-dimensional digital modeling and the future of orthodontics. *Technobytes.* 2002;325–330.
10. Samawi SSB, Burke PH. Angular distortion in the orthopantomogram. *Br J Study Orthod.* 1984;11:100–107.
11. Lucchesi MV, Wood RE, Nortje CJ. Suitability of the panoramic radiograph for assessment of mesiodistal angulation of teeth in the buccal segments of the mandible. *Am J Orthod Dentofacial Orthop.* 1988;94:303–310.
12. McKee IW, Williamson PC, Lam EW, Heo G, Glover KE, Major PW. The accuracy of 4 panoramic units in the projection of mesiodistal tooth angulations. *Am J Orthod Dentofacial Orthop.* 2002;121:166–175.
13. Mozzo P, Procacci C, Tacconi A, Tinazzi Martini P, Bergamo Andreis A. A new volumetric CT machine for dental imaging based on the cone-beam technique: preliminary results. *Eur Radiol.* 1998;8:1558–1564.
14. Mah J, Danforth R, Bumann, Hatcher D. Radiation absorbed in maxillofacial imaging with a new dental computed tomography device. *Oral Surg Oral Med Oral Pathol.* 2003;96: 508–513.
15. Phillip RG, Hurst RV. The cant of the occlusal plane and distortion in the panoramic radiograph. *Angle Orthod.* 1978; 48:317–323.