

Maxillary Incisor Angulation and Its Effect on Molar Relationships

Yasinee Sangcharearn^a; Christopher Ho^b

ABSTRACT

Objectives: To determine the variation in molar relationships when upper incisor angulations are altered in a Class I occlusion with normal overjet and overbite.

Materials and Methods: Typodonts were set up to simulate a Class I occlusion on a normal skeletal base. The lower incisors were positioned normally at 92° to the mandibular plane and the upper incisor angulations were altered from 90° to 130° by 2° increments to the palatal plane. The changes in molar relationships were measured with every 2° of upper incisor angulation change. A regression analysis was performed on the experimental data, and the regression coefficients, slope, and intercept were estimated.

Results: A negative linear relationship between upper incisor angulations and change in molar relationship was observed. On average, a change of 20° in upper incisor angulation will alter the molar relationship by 1.8 mm.

Conclusions: Changes in upper incisor angulations are significantly related to change in the molar relationship. Upper incisor angulations that deviate significantly from normal values are likely to result in less than ideal buccal segment relationships.

KEY WORDS: Incisor angulations; Root torque; Overjet; Molar relationship

INTRODUCTION

The attainment of a Class I occlusion may not always be achievable for every treated malocclusion. One of the variables that may affect the final occlusion is the labiolingual angulation of the upper and lower incisor teeth, which is an important consideration during orthodontic diagnosis and treatment planning.

Andrews¹ stated that the degree of labiolingual crown angulation of the upper and lower incisor teeth influences both posterior occlusion and anterior esthetics. Correctly angulated anterior crowns contribute to normal overbite and posterior occlusion. When the crowns are too vertical, they lose their functional harmony, and overeruption may result. Improperly angulated incisors may result in all upper contact points being located either too mesially or too distally, thus

leading to an improper occlusion. This has been falsely blamed on a tooth size discrepancy when there may not be one.¹

Arch length is also influenced by the angulation of the incisor teeth. When a deficiency in the dental arch length becomes apparent, the angulation of the upper anterior teeth should be examined. If they are too upright, upper anterior arch length may be gained by increasing the amount of palatal root torque. O'Higgins et al² constructed an in vitro model of bracketed acrylic maxillary teeth to investigate Andrews' hypothesis that there is a space implication when incisors are torqued inadequately. They found that for average-shaped incisors, a space requirement of 1 mm can be expected if all four maxillary incisors are torqued by 5°.

In an occlusion with a good Class I buccal segment relationship, the lack of an adequate overbite and overjet of the anterior teeth can be associated with improperly angulated upper anterior teeth, a tooth size discrepancy, or a combination of the two. The anterior teeth may be occluding on or close to an edge-to-edge anterior relation, resulting in reduced anterior function.³ Not only can inadequate angulation of the upper anterior teeth and/or a tooth size discrepancy have an effect on the anterior occlusion, they can also affect the buccal segment relationship.

^a Private practice, Lampang, Thailand.

^b Associate Professor and Department Chair, The University of Queensland, Discipline of Orthodontics, Queensland, Australia.

Corresponding author: Dr Christopher Ho, The University of Queensland, Discipline of Orthodontics, 200 Turbot Street, Brisbane, Queensland 4000, Australia (e-mail: c.ho@uq.edu.au)

Accepted: May 2006. Submitted: March 2006.

© 2007 by The EH Angle Education and Research Foundation, Inc.

It has not been investigated to what extent the variation of upper incisor angulation could have on the buccal segment relationship if a normal overjet and overbite are present. Previous studies⁴⁻⁷ investigated the relationship between overbite, overjet, crown angulations, and crown inclination, but none have investigated the variation of incisor angulations and its effect on posterior occlusion. The question is, how much of an effect does variation of the upper incisor angulation have on the molar relationship? This study aims to investigate the variation of incisor angulations (torque) and its effects on arch length and molar relationship in Class I occlusions.

MATERIALS AND METHODS

This study involved the use of typodonts with custom-made barium acrylic teeth set up to a normal Class I occlusion with normal overjet and overbite. A straight length of stainless steel wire buried along the long axis of the tooth was used. The wire was positioned from the midincisal point to the apex of the incisor tooth. An estimate of the sizes for the typodont teeth was predetermined from Ash and Nelson.⁸ The tooth widths were altered to reduce any mismatch in tooth sizes between the upper and lower teeth by using a tooth size discrepancy analysis.^{9,10}

The typodont was set up to simulate a skeletal Class I pattern. The horizontal part of the metallic upper base of the typodont was used to represent the palatal plane from which upper incisor angulations were measured. A removable custom-made triangular metallic plate was screwed onto the lower part of the typodont. The base of the triangle coincided with the base of the typodont, and the hypotenuse represented the mandibular plane from which the lower incisor angulations were measured. The palatal plane to mandibular plane measurement was set at 23°, compared to the normal value of $23.1 \pm 1.7^\circ$.¹¹ The lower incisors were positioned normally at 92° to the mandibular plane. The upper incisor angulations were altered from 90 to 130° to the palatal plane in 2° increments.

Lateral cephalometric radiographs, using mammogram film, were used to radiograph the typodont to confirm the accuracy of each incremental 2° change of incisor angulation (Figure 1). The overjet and overbite was kept constant. Deviation of the upper molar from the normal Class I molar relationship was measured with digital calipers for every 2° of upper incisor angular change.

Standardization of Records

A radiographic stand was made to hold the typodont in the same position when it was mounted beside the radiographic film. Errors caused by rotation and mag-

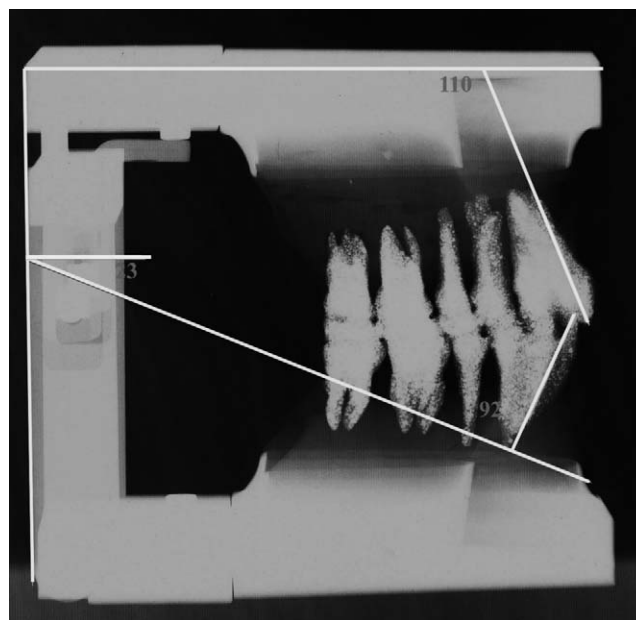


Figure 1. Radiograph of the typodont. The triangular metallic plate was removed and is not shown here.

nification were therefore reduced. The same cephalometric machine was used for the duration of the study, and each cephalogram was traced by the same investigator, who therefore was not blinded.

Tooth Morphology

The crown-root angulation of the upper incisor teeth used in this study is 0°, which is within the normal range for Class I occlusions. The normal crown-root angulation for the upper central incisor is $-0.69 \pm 4.88^\circ$.¹²

The amount of tooth thickness was controlled to not more than 2.75 mm, which could affect the anterior maxillary ratio, as suggested by Rudolph et al.¹³ The arch form used in this study to set up the teeth in Class I occlusion is the Ortho Form III (3M Unitek, Monrovia, Calif) arch form.

Measurement Error

To standardize the experiment and reduce measurement error, the experiment was replicated three times using the same mold. The mold was used to set up all teeth into a Class I occlusion with the upper incisor angulation set to 110° before changing the upper incisor angulation to a new value. A Mitutoyo digital caliper (M.T.I. Qualos, Wetherill Park, NSW, Australia) was used to measure the linear change in molar relationships following every 2° of upper incisor angulation change. The change in molar relationships was measured on both sides of the arch and when a

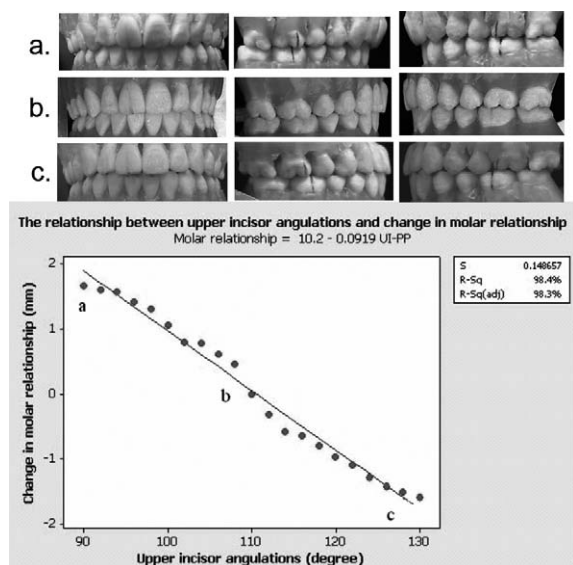


Figure 2. Scatterplot of upper incisor angulation vs change in molar relationship. The lower incisor angulation was set at 92°. (a) Upper incisor angulation is at 90° and molar relationship is near-half unit Class II. (b) Upper incisor angulation is at 110° and molar relationship is Class I. (c) Upper incisor angulation is at 130° and molar relationship is near half-unit Class III.

difference in measurements existed, the average value was used.

Statistical Methods

Linear regression analysis (Minitab Student Release 14, Minitab Inc, San Marcos, Calif) was used to find the relationship between upper incisor angulation and molar relationship. Significance was predetermined at $P < .05$. The regression equation $y = a + bx$ was formulated to predict the change in molar relationship when the angulation of the upper incisors to the palatal plane changed ($y =$ change in molar relationship; $x =$ degree of upper incisor angulation; $a =$ y intercept; $b =$ slope).

RESULTS

Changes in the upper first molar position relative to the lower first molar position was found for every 2° change in the upper incisor to palatal plane (UI-PP) angulation (Figure 2). A negative change in molar relationship indicates that the molar relationship is tending towards half-unit Class III, and similarly, a positive change in molar relationship indicates that the molar relationship is tending toward half-unit Class II.

A negative linear relationship between UI-PP angulation and change in molar relationship was observed. The data were analyzed using a simple linear regression analysis. The regression coefficients, slope, and intercept were estimated. The results

showed that there is a strong negative linear relationship between UI-PP angulation and change in molar relationship, with $R^2 = 0.9840$.

The results from the regression analysis showed a significant linear relationship between UI-PP angulation and change in molar relationship ($P < .05$). The regression equation, $y = a + bx$, is $y = 10.2 - 0.0919x$. The y intercept $a = 10.2$ mm ($SE_a = 0.2964$ mm, $df = 19$). The slope $b = -0.092$ mm/° ($SE_b = 0.0026$ mm/°, $df = 19$).

The reproducibility of the change in molar relationship with every 2° increase or decrease in UI-PP angulation showed a very high degree of accuracy. The estimated experimental error was 0.022 mm, with each observation being close to the corresponding mean.

The assumption of regression was checked by using the residual plot and residual analysis. The normal probability plot of the residuals revealed that the normality of data may be safely assumed. The residuals vs order and the residuals vs fitted data formed certain patterns, which may be explained by a lack of randomization in measurements. However, these patterns would not influence the estimates, because the experimental error is very small.

Each experimental model tended towards a similar result for all experiments. From the regression equations, a change of 20° in UI-PP angulation will alter the molar relationship by an average of 1.838 mm.

DISCUSSION

The effect of inadequate upper incisor angulation on molar relationships may not be fully appreciated until the later stages of orthodontic treatment. This is an important consideration, as difficulties with finishing to a normal Class I occlusion could arise from deficient labiolingual angulation of the upper incisors. Angle¹⁴ was the first to describe the importance of such relationships, and based his classification of malocclusion on these occlusal characteristics.

Andrews¹ explained the importance of various occlusal components and described the six keys required for normal occlusion. He further highlighted and quantified the interrelationship which exists between the various keys of normal occlusion. This emphasized that although each key is integral to achieving a normal occlusion, a deficiency in one of the keys of occlusion can adversely affect the overall occlusal scheme. That is, the anterior and posterior occlusion cannot be considered to be mutually exclusive.

A normal upper incisor angulation of 110° to the palatal plane facilitates a Class I buccal segment relationship when the lower incisor to mandibular plane angulation is 92°. However, as the upper incisor an-

gulation deviates further from this mean value of 110°, the result is a less than an ideal buccal segment relationship when the overjet and overbite remain similar. Changes to the angulation of the upper incisors alter the arch length, which in turn has an effect on the buccal segment relationship, the overjet, or a combination of the two. Tuverson³ demonstrated, through the use of a diagnostic setup, that arch length is clearly influenced by the degree of angulation of the upper incisors. He showed that dental arch length decreased as the upper incisors became more upright, and conversely that dental arch length could be increased through increasing the lingual axial inclination of the upper incisors.

An association between upper incisor angulation and change in molar relationship was found by the use of successive experimental occlusal models in this study. It was possible to quantify this described relationship, and a highly significant relationship between upper incisor angulation and molar relationship ($R^2 = 98.4$) was found.

One of the requirements of this investigation was that the anteroposterior position of the upper incisor crowns be held constant throughout the experiment. Therefore, any change in the UI-PP angulation was attributed to root movement or torque, as opposed to simple crown tipping. It is important to specify this condition, as it is clear that root torque and crown tipping have the potential to produce different changes in the overall anterior and posterior dental relationships. For every 5° of upper incisor angulation change, the molar relationship changed by 0.46 mm per side. Therefore, a 5° increase in incisor angulation resulted in a 0.92-mm increase in arch length bilaterally. It can be predicted that the molar relationship will tend towards Class III at a rate of 0.09 mm per degree of increase of UI-PP angulation change. In agreement with these findings, O'Higgins et al² also reported that increasing the angulation of the upper incisors by 5° resulted in an increase in arch length of approximately 1 mm.

Clinicians should be aware of the reasons why the buccal segments do not always interdigitate satisfactorily despite the attainment of a normal overjet and overbite. It is apparent that when the upper incisor angulation is increased, the molar relationship will tend towards a Class III molar relationship (Figure 2c), assuming that a normal overjet and overbite are maintained. Conversely, a decrease in upper incisor angulation will result in a tendency towards a Class II molar relationship (Figure 2a). In this situation, increased palatal root torque will be necessary to gain arch length and thus improve the posterior buccal segment relationship. This is particularly important in extraction cases, when loss of torque control could arise during space closure. It is also important to recognize

that overjet and overbite must be maintained within the normal range to ensure that the increase in arch length occurs in the posterior segment rather than being reflected as an increase in overjet in the anterior segment.

Although this study investigated upper incisor angulation as a contributing factor to changes in arch length and molar relationship, upper incisor angulation is not the only factor that needs to be considered in the attainment of a normal Class I occlusion. There are other occlusal variables that are essential for the establishment of an ideal occlusal scheme. If these variables deviate significantly from the mean values, a less than ideal Class I occlusion will be the likely end result. One such variable is the presence of a significant tooth size discrepancy, which has the potential to contribute to the poor interdigitation of teeth at the end of a course of orthodontic treatment.

It is common to suggest that a tooth size discrepancy is responsible for poor buccal segment interdigitation in cases in which the overjet and overbite have been reduced to normal values. This investigation highlights that incorrect incisor angulation may also be a significant, and perhaps a more frequent, contributor to the presence of a poor buccal segment relationship. Despite this, it is not uncommon to overlook the importance of cephalometric radiographs, and to underestimate the value of measuring tooth sizes and performing a tooth size analysis. Although it may not be necessary to request a comprehensive range of radiographs and perform such analyses for every orthodontic patient, it is important to appreciate the value of such information in the assessment of problem cases. Evaluation of incisor angulations and performance of a tooth size analysis should be considered in patients when the anterior and/or posterior occlusion does not interdigitate satisfactorily. Ideally, this should have been performed earlier as an integral part of diagnosis and treatment planning.

Not much has been said about the angulation of the lower incisor teeth. Proclination of the lower incisors is a common finding in many completed cases. Again, lower incisor angulations that deviate away from normal limits may create problems during the latter stages of treatment. How much can the lower incisors be proclined before they significantly affect the overall occlusal scheme? Tweed¹⁵ reported that 12° of proclination or retroclination of the lower incisors could result in arch length changes of up to 10 mm. Sadowsky¹⁶ stated that advancing or retracting the lower incisor by 1 mm will result in a 2-mm gain or a 2-mm reduction in the mandibular dental arch length, respectively. It is apparent that an association between lower incisor angulation, arch length, and molar rela-

tionship also exists, but this will be subject to a separate study.

The crown-root angulation may also affect the degree of upper incisor angulation. Delivanis and Kuftinec¹⁷ found that the incisor crowns of Class II division 2 malocclusion patients appeared to be more palatally placed in relation to their respective roots compared to the incisors of Class II division 1 patients. Again, this has to be considered during diagnosis and treatment planning. With all cases, early planning with a vision towards providing or maintaining adequate incisor root torque will enhance the results of completed cases.

Limitations of This Study

This experimental model has several limitations. It has not investigated the effects of tooth size discrepancy, tooth shape, crown root angulations, incisor edge thickness, or arch form on the molar relationship. All of these occlusal variables were controlled in this typodont investigation. Although each of these variables individually and/or collectively has the potential to affect the overall occlusion, the extent of such effect(s) was not examined in this study. The regression equation from this experiment is valid only when the upper incisor angulation ranges between 100 and 130° to the palatal plane and for the tooth sizes that correspond to the study. Beyond this range of angulation and for significantly larger or smaller tooth sizes, the predictive value of this equation could be incorrect. Information derived from this regression equation is also invalid when the lower incisor to mandibular plane angulation varies significantly from 92°.

CONCLUSIONS

- Variation in the angulation of the upper incisors from normal limits can significantly alter the molar relationship and is likely to result in less than ideal buccal segment relationships.
- Positioning the upper and lower incisor angulations within normal limits is an important consideration during orthodontic diagnosis and treatment planning and should be monitored during treatment, and this objective should be achieved in the finishing stages of treatment.

ACKNOWLEDGMENTS

This study was supported by the Australian Society of Orthodontists' Foundation for Research and Education. The authors would like to thank Mr Paul Chapman for his technical expertise in setting up the typodont and Dr Olena Kravchuk for her statistical advice.

REFERENCES

1. Andrews LF. The six keys to normal occlusion. *Am J Orthod.* 1972;62:296–309.
2. O'Higgins EA, Kirschen RH, Lee RT. The influence of maxillary incisor inclination on arch length. *Br J Orthod.* 1999; 26:97–102.
3. Tuverson DL. Anterior interocclusal relations. Part I. *Am J Orthod.* 1980;78:361–370.
4. Steadman S. Predetermining overbite and overjet. *Angle Orthod.* 1949;19:101–105.
5. Hussels W, Nanda RS. Effect of maxillary incisor angulation and inclination on arch length. *Am J Orthod Dentofacial Orthop.* 1987;91:233–239.
6. Cordato MA. A simple mathematical study of anterior dental relations. Part III: incisor and canine overbite. *Aust Orthod J.* 1998;15:75–84.
7. Heusdens M, Dermaut L, Verbeeck R. The effect of tooth size discrepancy on occlusion: an experimental study. *Am J Orthod Dentofacial Orthop.* 2000;117:184–191.
8. Ash MM, Nelson SJ. *Wheeler's Dental Anatomy, Physiology, and Occlusion.* 8th ed. St Louis, Mo: Saunders; 2003: 18.
9. Bolton WA. Disharmony in tooth size and its relation to the analysis and treatment of malocclusion. *Angle Orthod.* 1958;28:13–30.
10. Ho CT, Freer TJ. The graphical analysis of tooth width discrepancy. *Aust Orthod J.* 1994;13:64–70.
11. Anthanasiou AE. *Orthodontic Cephalometry.* London: Mosby-Wolfe; 1995:254.
12. Williams A, Woodhouse C. The crown to root angle of maxillary central incisors in different incisal classes. *Br J Orthod.* 1983;10:159–161.
13. Rudolph DJ, Dominguez PD, Ahn K, Think T. The use of tooth thickness in predicting intermaxillary tooth-size discrepancies. *Angle Orthod.* 1998;68:133–138. discussion 139–140.
14. Angle EH. *Treatment of Malocclusion of the Teeth: Angle's System.* 7th ed. Philadelphia, Pa: The SS White Dental Manufacturing Co; 1907:7–27.
15. Tweed CH. The Frankfort-Mandibular Incisor Angle (FMIA) in orthodontic diagnosis, treatment planning and prognosis. *Angle Orthod.* 1954;24:121–169.
16. Sadowsky PL. The Geometry of Cephalometry. In: Jacobson A, ed. *Radiographic Cephalometry: From Basics to Videoimaging.* Chicago, Ill: Quintessence Publishing Co; 1995:134.
17. Delivanis HP, Kuftinec MM. Variation in morphology of the maxillary central incisors found in Class II, division 2 malocclusions. *Am J Orthod.* 1980;78:438–443.