

Long-term Stability of Unilateral Posterior Crossbite Correction

Theodosia Bartzela^a; Irmtrud Jonas^b

ABSTRACT

Objective: To evaluate the stability of orthodontically corrected unilateral posterior crossbite in patients treated either by rapid maxillary expansion or with slow expansion devices in the early (mean age 7.2 years, n = 50) or late mixed dentition (mean age 9.9 years, n = 50).

Materials and Methods: The observation periods were approximately 8 years for the early treatment groups and 6.5 years for the late treatment groups. The measurements were made on plaster casts at the following time points: before treatment (T1), after crossbite correction (T2), at the end of active orthodontic treatment (T3), and about 2 years after the end of active treatment (T4). Midline deviation and the skeletal classification of the malocclusion were also evaluated.

Results: Almost 80% of the treated patients showed long-term stability of the corrected unilateral posterior crossbite. More than 70% of the patients were treated for the mandibular midline deviation. At the end of active treatment, 50% of the patients showed a skeletal Class III craniofacial morphology.

Conclusions: The results emphasize that determination of the correct treatment approach for the individual patient is the basic principle underlying the therapeutic success in unilateral crossbite cases. In patients where a broad lower arch is a cofactor in the etiology of the lateral crossbite, the treatment approach should be focused on both arches and not be limited to the constricted upper arch.

KEY WORDS: Unilateral crossbite; Early treatment; Stability

INTRODUCTION

According to epidemiological data,¹⁻⁵ the prevalence of unilateral posterior crossbite in the early mixed dentition varies between 8% and 23%. Unilateral crossbite is characterized by an arch deficiency, and sometimes asymmetries in the upper or lower arch are present.⁶ In crossbite cases, early treatment has been recommended because spontaneous correction is unusual.^{7,8} However, early orthodontic treatment is controversial with respect to its cost-to-benefit ratio. Studies have reported that 50% of the crossbite cases treated

in the primary dentition had to be retreated in the early or late mixed dentition.^{3,9}

According to the current literature, there is no clear consensus if a structural adaptation of the condyle-fossa caused by asymmetric growth of an untreated crossbite is an etiological factor for temporomandibular disorders.¹⁰

The aim of this retrospective study was to evaluate the stability of corrected unilateral crossbites. Long-term therapeutic results of rapid maxillary expansion (RME) and slow palatal expansion devices were compared in patients in the early and late mixed dentitions.

MATERIALS AND METHODS

Patients

One hundred orthodontic patients treated for unilateral crossbite were randomly selected from the records of the Department of Orthodontics, University of Freiburg. All patients had undergone maxillary expansion treatment for correction of posterior crossbite. Patients with cleft palate, anterior crossbite, extractions, or breathing problems were excluded from the study.

^a Assistant Professor, Department of Orthodontics and Oral Biology, Radboud University Nijmegen Medical Centre, Nijmegen, The Netherlands.

^b Professor and Department Chair, Department of Orthodontics, University Clinic of Freiburg, Freiburg, Germany.

Corresponding author: Dr Theodosia Bartzela, Department of Orthodontics and Oral Biology, Radboud University Nijmegen Medical Centre, 309 Dentistry, PO Box 9101, 6500 HB Nijmegen, The Netherlands (e-mail: t.bartzela@dent.umcn.nl)

Accepted: June 2006. Submitted: January 2006.

© 2007 by The EH Angle Education and Research Foundation, Inc.

TABLE 1. Mean Ages and Standard Deviations at First Registration (T1) and Overall Observation Period (T1–T3, T3–T4)

	Group 1	Group 2	Group 3	Group 4
Device used	Slow expansion	RME	Slow expansion	RME
Treatment time	Early treatment	Early treatment	Late treatment	Late treatment
No. of patients	25	25	25	25
Mean age, y (T1)	6.97 ± 1.3	7.29 ± 1.0	9.78 ± 0.9	10.0 ± 1.8
Treatment period, y (T1–T3)	5.5 ± 2.6	4.6 ± 1.6	4.2 ± 1.4	4.3 ± 1.8
Posttreatment period, y (T3–T4)	3.3 ± 2.0	2.3 ± 1.5	2.2 ± 1.1	2.0 ± 0.9

Patients had been treated in the early (mean age 7.2 years, $n = 50$) or late mixed dentition (mean age 9.9 years, $n = 50$). The expansion had been performed either by a slow palatal expansion procedure or by RME technique, depending on the severity of the malocclusion. RME was the approach selected for patients whose expansion-treatment needs were more than 4–5 mm.

The slow palatal expansion procedure was performed with a removable plate ($n = 50$) and the RME technique was performed with a tissue-borne split fixed acrylic appliance ($n = 50$). Each of the above groups contained 25 early treatment patients and 25 late treatment patients (Table 1).

The slow palatal expansion appliance was activated 0.2 mm (90° rotation of the screw) once a week, and the RME was activated 0.4 mm per day. After crossbite correction, a retention period of at least 3 months was observed in all patients.

After the first phase of treatment, active orthodontic therapy was completed by fixed appliance therapy. The fixed phase of treatment consisted of preadjusted fixed appliances, and a standard archwire sequence was used. Hawley appliances were used for retention after the fixed appliances therapy. The patients were instructed to wear their retainers full time for a period of 6 months and only at nights for additional 6 months.

The treatment results were evaluated by means of measurements on dental casts at the following time points: before treatment (T1), immediately after posterior crossbite correction (T2), after active orthodontic treatment (T3), and about 2 years after active treatment (T4).

METHODS

All measurements were made by the same examiner and recorded to the nearest 0.1 mm with a Boley gauge. The transversal widths of the upper and lower dental arches were measured at the reference points as indicated in Figures 1 and 2:

- Tips of the canines (in the maxilla and mandible)
- Maxillary premolars at the central fossa or maxillary first primary molars at the posterior groove of the transverse fissure (anterior maxillary arch width)

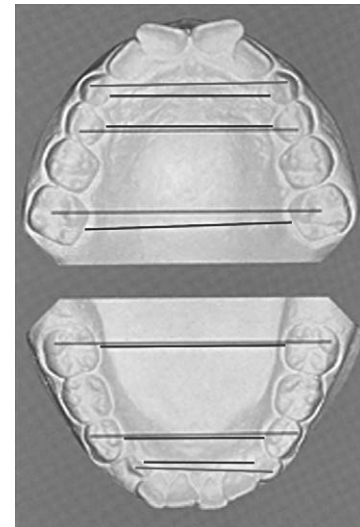


Figure 1. Transverse distance of Pont's Index reference points in the mixed dentition.

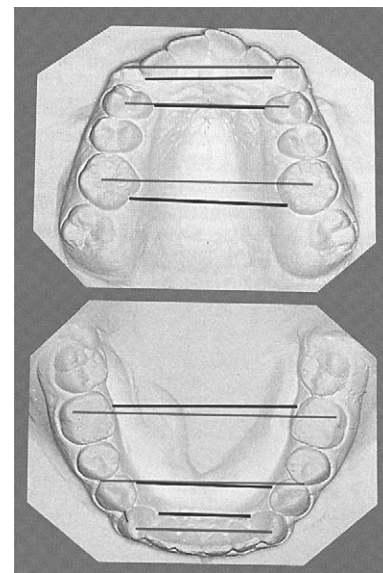


Figure 2. Transverse distance of Pont's Index reference points in the permanent dentition.

- Maxillary first permanent molar at the point of intersection of the transverse fissure with the buccal fissure (posterior maxillary arch width)
- Contact point between the first and the second pre-

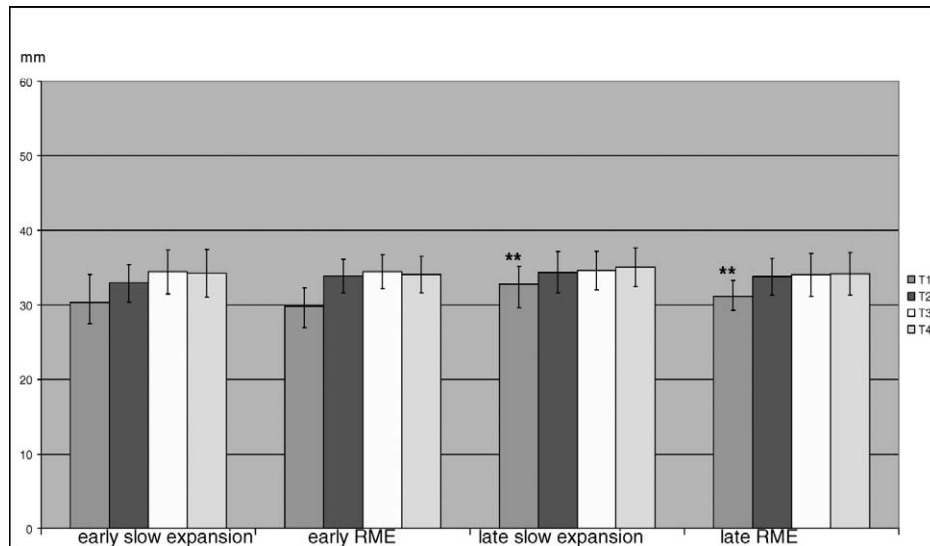


Figure 3. Intercanine arch width in the four groups at the four registrations (** $P < .01$).

molars or at the distal buccal cusp of the first primary molars (anterior mandibular arch width)
 e. Mesio Buccal cusp of the mandibular first molars (posterior mandibular arch width)

The gingival crests measurements were also assessed (Figures 1 and 2).

The “ideal” anterior and posterior arch width values were evaluated according to Pont’s Index.¹¹ The modification of Pont’s Index was used, introduced by Linder¹² and Harth¹³ for the German population.

The mandibular midline deviation was evaluated at first and last registrations (T1, T4) to the nearest 0.1 mm.

Cephalometric Analysis

Three lateral head films taken before treatment (T1) and after active orthodontic treatment (T3) were available for each patient. The cephalometric parameters SNA, SNB, and ANB were registered. The measured ANB angle was compared with the individualized ANB angle¹⁴ in relation to SN-MeGo angle. These measurements were taken to classify the patients according to their skeletal pattern.

Statistical Methods

The data were statistically analyzed at the Institute of Medical Biometry and Medical Informatics, University of Freiburg, by using SAS 6.12 statistical software (Statistic Analysis System Institute, Cary, NC).

Student’s *t*-test was carried out to evaluate the success rate of the crossbite correction. A two-way analysis of variance (ANOVA) was applied for the evaluation of arch width at the four registrations (T1, T2, T3, T4) in the four different treatment groups.

A three-way ANOVA was applied to test the incidence of relapse after crossbite correction and to compare the treatment relapse rates between the early treatment groups and the late treatment groups, as well as between the two different treatment approaches. The Wilcoxon test was chosen to evaluate mandibular midline deviation.

Error of the Method

The measurements were repeated twice on the dental casts at time point T1. The Dahlberg form¹⁵ was selected to assess the reliability of our measurements. The greatest random method error observed was in posterior mandibular arch width (0.349 mm) and the lowest at gingival crest of the posterior maxillary arch width (0.162 mm). The normal distribution of each variable was verified by kurtosis and skewness statistics.

RESULTS

The early treatment RME group had the highest relapse rate at 24%. The relapse rate recorded in the other three groups at the final registration was 20%.

The mean ages at T1 were 7.2 years for the early treatment groups and 9.9 years for the late treatment groups. The total observation period (T1–T4) was approximately 8 years for the early treatment groups and 6.5 years for the late treatment groups (Figure 1). The intercanine arch widths in the late treatment groups were significantly increased ($P < .01$) in comparison with the early treatment groups (Figure 3). The early treatment groups never reached the ideal arch width values specified by the modified Pont’s Index.^{12,13} The widest dental arches were registered in the late treatment groups (Figures 4 and 5).

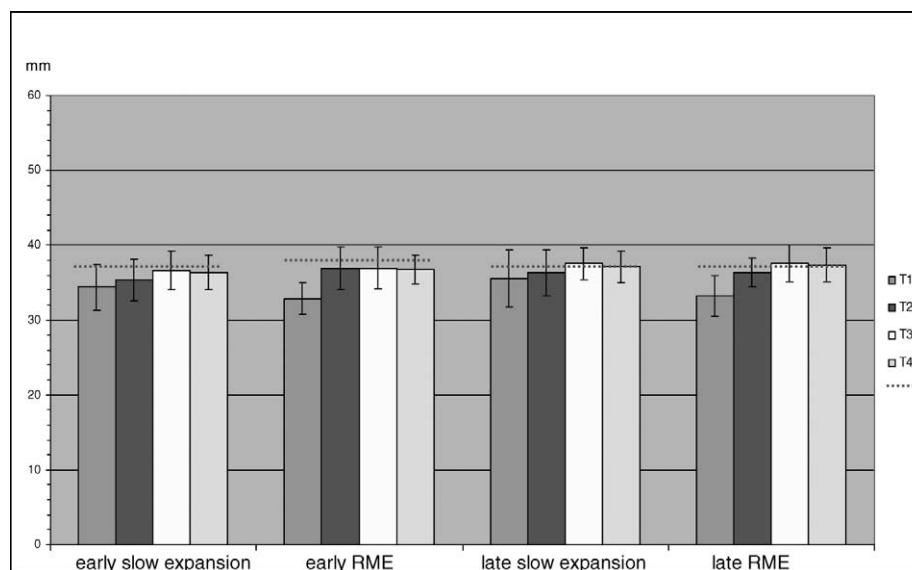


Figure 4. Mean values and standard deviations of interpremolar arch width in the four groups at the four registrations and ideal anterior arch width value in each group (dotted line).

The expansion increases achieved in the maxillary posterior arch width in the RME groups at T3 was statistically significant ($P < .01$) in comparison with the slow expansion groups (Figure 5). The same observations were made for our measurements on gingival crests. The slow expansion samples had reached the ideal posterior arch width values^{12,13} by T3. This finding persisted at T4 in the late slow expansion group only (Figure 5).

From T1 to T2, all mandibular widths showed minor alterations. At T4, there was a significance comparing the mandibular widths between the relapsed and the nonrelapsed cases in the intercanine dental ($P < .01$) and skeletal measurements ($P < .001$) (Figure 6).

The midline deviation had significantly improved ($P < .01$) in the late slow expansion group at T4 as compared with the T1 group (19 of 25 patients in T1 and only 1 of 25 patients in T4 had midline deviation) (Table 2). The late treatment groups as well as the early RME cases showed an increase in the number of skeletal Class III patients at T3 (Figure 7).

DISCUSSION

The debate for early or late unilateral crossbite correction focuses on the stable results of the treatment during the still-following physiological adolescent growth processes. According to the results of a systematic review by Harrison and Ashby,⁵ a palatal expansion for the correction of crossbite in the primary dentition will decrease the risk of the perpetuation of the problem.

In an epidemiological study by Helm,¹⁶ crossbite prevalence was significantly higher in girls than in

boys. In an investigation by Athanasiou et al,¹⁷ all frontal cephalometric variables revealed lack of differences between sexes. In agreement with the above findings is the study by Boysen and La Cour,¹⁸ who compared odontometric and cephalometric variables. Sexual differences in frontal cephalometric variables are noticed only after puberty.¹⁹ In our data, the sex distribution was not elaborated.

We compared the “ideal values” according to the modified Pont’s Index^{12,13} with the measured values of the dental arches and interpreted our findings as broadness or narrowness of the upper in comparison with the lower dental arches. We took into account that ideal arch values are only a guide and not a goal per se.

Many authors have critically viewed the validity of Pont’s Index.^{20–24} In this study, Pont’s Index has been used only as a tool for the comparison between the upper and lower dental arches.

In different studies the intercanine arch width remained stable after an increase of 3–4 mm, with RME treatment associated with an increase in the intermolar width of up to 6 mm.^{25–28} Our findings are in agreement with the above-mentioned values.

Hicks²⁹ treated 10- to 15-year-old patients with slow maxillary expansion and found an increase in dental arch width ranging from 3.8 to 8.7 mm. In our late slow expansion group the dental arch width changes roughly exceed 3.1 ± 2.3 mm.

In the Michigan study, Spillane and McNamara³⁰ examined the records of 7- to 15-year-old untreated patients who presented with narrow arch forms and compared them with the average arch forms of the sample.

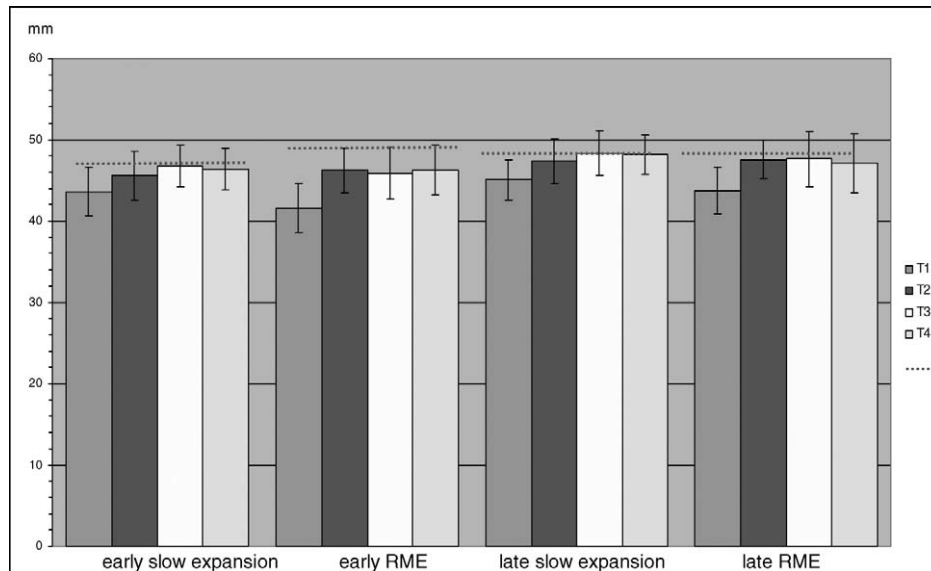


Figure 5. Mean values and standard deviations of intermolar arch width for the four groups at the four treatment registrations and ideal posterior arch width value for each treatment group (dotted line) (** $P < .01$).

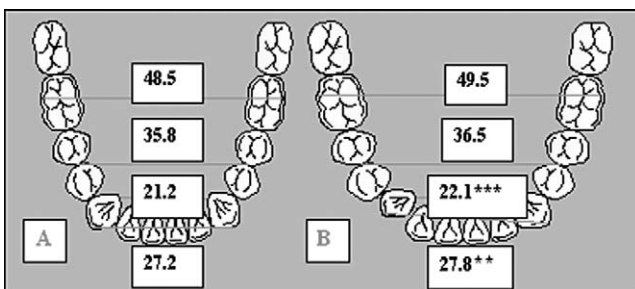


Figure 6. (A) Mean lower arch widths (mm) of the 79 successfully treated crossbite patients. (B) Mean lower arch widths (mm) of the 21 relapsed crossbite cases (** $P < .01$) (** $P < .001$).

TABLE 2. Mandibular Midline Deviation—Number of Patients in First (T1) and Last (T4) Registration

	T1	T4
Early slow expansion	10/25	7/25
Early RME ^a	24/25	13/25
Late slow expansion	19/25	1/25*
Late RME ^a	23/25	7/25

^a RME indicates rapid maxillary expansion.

* Significant improvement ($P < .01$).

The patients with initial narrow arch width tended to become more average after appliance therapy. According to Lee,³¹ there is no evidence that appliances can stimulate growth beyond the normally expected amount.

A meta-analysis published by Schiffman and Tunçay³² critically evaluated the maxillary expansion treatment because there was lack of scientific data for long-term therapeutic results. The role of growth in changes during the postretention period is controver-

sial. Some authors reported less relapse when treatment was performed during the period of greatest growth increments.³³ Others reported growth as a cofactor for relapse, considering the amount and the direction of facial growth during the postretention period to be at least partially responsible for the occlusal changes.^{34–36}

In the present study, we observed an increased lower posterior arch width in comparison with the upper posterior arch width in all treatment periods and in all treatment groups. The mandibular posterior arch widths were even greater than the ideal values^{12,13} in all groups (with the exception of the early RME group). The above finding indicates an overdeveloped mandible in combination with a normal or underdeveloped maxilla in the late slow expansion group or the late RME group, respectively.

These findings show that an early correction of the crossbite has a positive influence on the further development of the maxilla and may prevent an abnormal transverse growth of the lower arch in the intermolar region (Figure 5).

We also observed that the mean lower arch width values in the relapsed cases were increased compared with the nonrelapsed treated cases. The significant difference recorded in the mandibular intercanine width corresponded well with the findings of Thilander and Lennartsson⁶ (Figure 3).

In the present study, we noted skeletal classification changes during the treatment period resulting from the orthodontic treatment and the normal growth processes. According to Nanda and Nanda³⁷ and Thilander,³⁸ posttreatment relapse is related to late growth changes, especially in Class III patients.

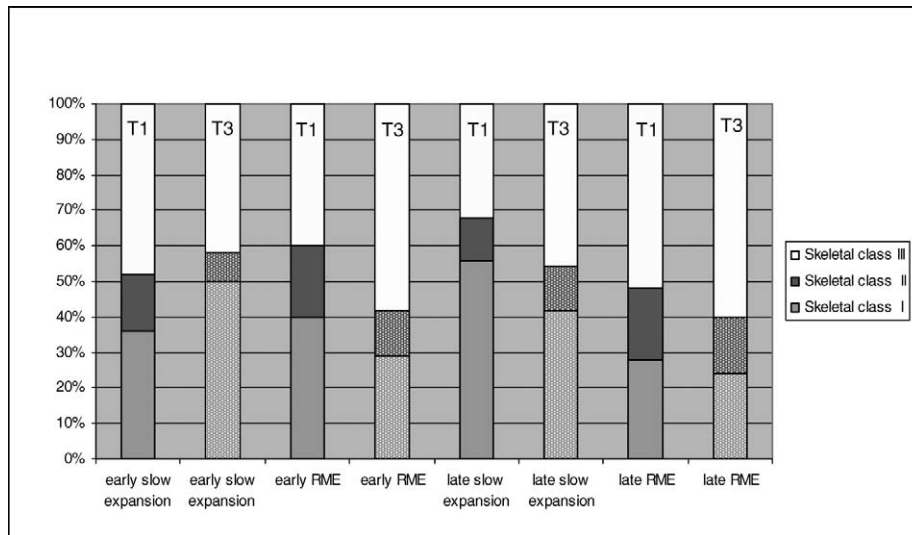


Figure 7. Percentage of skeletal classification of each group of patients at first and third registrations.

Baccetti et al³⁹ showed that RME treatment during early developmental stages gives more skeletal and more stable long-term results. Wertz and Dreskin⁴⁰ showed that maxillary skeletal expansion underwent no relapse in younger patients, whereas the older patients lost most of the width increase that had been achieved through palatal expansion. Our study revealed no significant differences in relapse between the age groups and that the relapse was mainly due to the skeletal growth pattern of the mandible and to a lesser extent to the stability of the expanded maxilla.

The late treatment group was the only group showing a significant improvement in midline deviation at the final registration (Table 1). This might well be attributed to the differentiated treatment indication for this group of patients. Transverse discrepancies treated late with slow expansion devices should have been of minimal transverse deficiency. These results are in accordance with the findings of Hesse et al.⁴¹

Considering occlusion to be a dynamic developmental process subject to genetic and environmental influences, we should expect continuous changes throughout life.³⁸ In cases where a broad lower arch is a cofactor in the etiology of the lateral crossbite, the treatment approach should be focused on both arches and not only on the constricted upper arch.

The results underline that determination of the correct treatment approach for the individual patient is the basic principle for therapeutic success in unilateral crossbite cases.

According to our measurements, we recommend an early crossbite correction, which may prevent an abnormal transverse growth of the maxilla and the mandible. A late relapse may be expected mainly because of late mandibular growth.

CONCLUSIONS

- Long-term stability of the corrected unilateral posterior crossbite was seen in 79% of the treated patients. All groups were equal in terms of relapse.
- The maxillary anterior arch width revealed the greatest transverse expansion, which was still recorded at the final registration.
- The mean lower arch width values in the relapsed cases were increased compared with the nonrelapsed treated cases.
- The net effect of the increase in the dental and skeletal transverse dimension was not significantly different in the four treatment groups.
- The mandibular midline deviation was corrected in 72% of the patients. The midline correction was significantly greater in the late slow expansion group.

ACKNOWLEDGMENTS

We wish to express our sincere thanks to Professor Katsaros (Radboud University Nijmegen Medical Centre, Department of Orthodontics and Oral Biology) for his advice and comments on the manuscript.

REFERENCES

- Ingervall B, Seeman L, Thilander B. Frequency of malocclusion and need of orthodontic treatment in 10-year old children in Gothenburg. *Sven Tandlak Tidskr.* 1972;65:7-21.
- Magnusson TE. An epidemiologic study of occlusal anomalies in relation to development of the dentition in Icelandic children. *Community Dent Oral Epidemiol.* 1976;4:121-128.
- Kurol J, Berglund L. Longitudinal study and cost-benefit analysis of the effect of early treatment of posterior crossbites in the primary dentition. *Eur J Orthod.* 1992;14:173-179.
- Jämsä T, Kirveskari P, Alenen P. Malocclusion and its as-

- sociation with clinical sign of craniomandibular disorders in 5-, 10- and 15-year old children in Finland. *Proc Finn Dent Soc.* 1988;84:235–240.
5. Harrison JE, Ashby D. Orthodontic treatment for posterior crossbites. *Cochrane Database Syst Rev.* 2006;2:CD000879.
 6. Thilander B, Lennartsson B. A study of children with unilateral posterior crossbite, treated and untreated, in the deciduous dentition—occlusal and skeletal characteristics of significance in predicting the long-term outcome. *J Orofac Orthop.* 2002;63:371–383.
 7. Thilander B, Wahlund S, Lennartsson B. The effect of early interceptive treatment in children with posterior cross-bite. *Eur J Orthod.* 1984;6:25–34.
 8. Lindner A, Henrikson CO, Odenrick L, Modeer T. Maxillary expansion of unilateral cross-bite in preschool children. *Scand J Dent Res.* 1986;94:411–418.
 9. Lindner A. Longitudinal study on the effect of early interceptive treatment in 4-year-old children with unilateral cross-bite. *Scand J Dent Res.* 1989;97:432–438.
 10. Zentner V, Zentner A. Frühbehandlung des seitlichen Kreuzbisses—eine Literaturrecherche. *Kieferorthopädie.* 2004;18:285–300.
 11. Rakosi T, Jonas I, Graber T. *Orthodontic Diagnosis. Color Atlas of Dental Medicine.* Stuttgart, Germany, and New York, NY: Thieme; 1993.
 12. Linder H. Biometrische Untersuchungen des Normalgebisses in verschiedenen Lebensaltern. *Fortschr Orthodont.* 1931;1:211,559.
 13. Harth G. Biometrische Untersuchungen über die Dimension des Normalgebisses in verschiedenen Lebensaltern. *Dtsch Mschr Zahnheilk.* 1930;48:1537.
 14. Panagiotidis G, Witt E. Der individualisierte ANB-Winkel. *Fortschr Kieferorthop.* 1977;38:408–416.
 15. Sokal RR, Rohlf FJ. *Biometry.* San Francisco, California: WH Freeman. 1981.
 16. Helm S. Malocclusion in Danish children with adolescent dentition: an epidemiologic study. *Am J Orthod.* 1968;54:352–366.
 17. Athanasiou AE, Droschl H, Bosch C. Data and patterns of transverse dentofacial structure of 6- to 15-year-old children: a posteroanterior cephalometric study. *Am J Orthod Dentofacial Orthop.* 1992;101:465–471.
 18. Boysen B, La Cour K. *Evaluation of the Changes in Facial Skeleton, Soft-tissue Profile and Dental Arch Dimensions After Crossbite Correction by Quad-helix and a Removable Appliance.* [thesis]. Aarhus: Royal Dental College; 1991.
 19. Broadbent BHS, Golden WH. *Bolton Standards of Dentofacial Developmental Growth.* St Louis, Mo: Mosby; 1975.
 20. Worms FW, Speidel TM, Isaacson RJ, Meskin LH. Pont's index and dental arch form. *J Am Dent Assoc.* 1972;85:876–881.
 21. Joondeph DR, Riedel RA, Moore AW. Pont's index: a clinical evaluation. *Angle Orthod.* 1970;40:112–118.
 22. Joondeph DR, Moore AW, Riedel RA. Use of Pont's index in orthodontic diagnosis. *J Am Dent Assoc.* 1972;85:341–345.
 23. Nimkarn Y, Miles PG, O'Reilly MT, Weyant RJ. The validity of maxillary expansion indices. *Angle Orthod.* 1995;65:321–326.
 24. Dalidjan M, Sampson W, Townsend G. Prediction of dental arch development: an assessment of Pont's Index in three human populations. *Am J Orthod Dentofacial Orthop.* 1995;107:465–475.
 25. Haas AJ. Long-term posttreatment evaluation of rapid palatal expansion. *Angle Orthod.* 1980;50:189–217.
 26. Sandstrom RA, Klapper L, Papaconstantinou S. Expansion of the lower arch concurrent with rapid maxillary expansion. *Am J Orthod Dentofacial Orthop.* 1988;94:296–302.
 27. Moussa R, O'Reilly MT, Close JM. Long-term stability of rapid palatal expander treatment and edgewise mechanotherapy. *Am J Orthod Dentofacial Orthop.* 1995;108:478–488.
 28. Geran RG, McNamara JA Jr, Baccetti T, Franchi L, Shapiro LM. A prospective long-term study on the effects of rapid maxillary expansion in the early mixed dentition. *Am J Orthod Dentofacial Orthop.* 2006;129:631–640.
 29. Hicks EP. Slow maxillary expansion. A clinical study of the skeletal versus dental response to low-magnitude force. *Am J Orthod.* 1978;73:121–141.
 30. Spillane LM, McNamara JA Jr. Maxillary adaptation to expansion in the mixed dentition. *Semin Orthod.* 1995;1:176–187.
 31. Lee RT. Arch width and form: a review. *Am J Orthod Dentofacial Orthop.* 1999;115:305–313.
 32. Schiffman PH, Tuncay OC. Maxillary expansion: a meta analysis. *Clin Orthod Res.* 2001;4:86–96.
 33. Litowitz RA. A study of the movement of certain teeth during and following orthodontic treatment. *Angle Orthod.* 1948;18:113–132.
 34. Isaacson RJ, Zapfel RJ, Worms FW, Erdman AG. Effects of rotational jaw growth on the occlusion and profile. *Am J Orthod.* 1977;72:276–286.
 35. Glynn SW, Sinclair PM, Alexander RG. Nonextraction orthodontic therapy: posttreatment dental and skeletal stability. *Am J Orthod Dentofacial Orthop.* 1987;92:321–328.
 36. Riedel RA. A review of the retention problem. *Angle Orthod.* 1960;30:179–199.
 37. Nanda RS, Nanda SK. Considerations of dentofacial growth in long-term retention and stability: is active retention needed? *Am J Orthod Dentofacial Orthop.* 1992;101:297–302.
 38. Thilander B. Orthodontic relapse versus natural development. *Am J Orthod Dentofacial Orthop.* 2000;117:562–563.
 39. Baccetti T, Franchi L, Cameron CG, McNamara JA Jr. Treatment timing for rapid maxillary expansion. *Angle Orthod.* 2001;71:343–350.
 40. Wertz R, Dreskin M. Midpalatal suture opening: a normative study. *Am J Orthod.* 1977;71:367–381.
 41. Hesse KL, Artun J, Joondeph DR, Kennedy DB. Changes in condylar position and occlusion associated with maxillary expansion for correction of functional unilateral posterior crossbite. *Am J Orthod Dentofacial Orthop.* 1997;111:410–418.