

# Unusual Extraction Treatment of Class I Bialveolar Protrusion Using Microimplant Anchorage

Jong-Moon Chae<sup>a</sup>

**Abstract:** This case report describes the treatment of a 16-year-old girl who had severe bialveolar protrusion. Patients with bialveolar protrusion are commonly treated with four first premolar extractions and retraction of the anterior teeth. Unfortunately in this patient, the mandibular left second molar had to be extracted because of extensive caries. To create sufficient space for retraction of the anterior teeth, the mandibular left posterior teeth were retracted with the mandibular posterior microimplant (1.2 mm in diameter, 6 mm long) placed into the retromolar area followed by en masse retraction of the mandibular anterior teeth. Microimplants can provide anchorage for obtaining a good facial profile even without premolar extraction in the case of bialveolar protrusion with the absence of the second molar.

## INTRODUCTION

Bialveolar protrusion is a condition characterized by protrusive and proclined upper and lower incisors and an increased procumbency of the lips. The goals of orthodontic treatment of bialveolar protrusion include the retraction and retroclination of maxillary and mandibular incisors with a resultant decrease in soft tissue procumbency and convexity.<sup>1</sup>

A common treatment approach for patients with severe bialveolar protrusion is to extract four first premolars and then retract the anterior teeth by using maximum anchorage mechanics. However, the treatment plan becomes more complex and controversial when the patients have hopeless mandibular second molars that should be extracted and also want to preserve the mandibular premolars.<sup>2</sup>

To solve this situation, the mandibular posterior teeth should be distalized. However, the distal movement of mandibular molars has been considered as one of the most difficult biomechanical problems to achieve in clinical orthodontics and is even more difficult than the distalization of maxillary molars.

To date, there have been several studies of mandibular molar distalization. However, the procedure has not been widely used because the successful distalization of molars relies considerably on patient cooperation, and adverse effects include forward movement of the anterior teeth during molar distalization and forward movement of the distalized molars during anterior tooth retraction.

With the use of miniplates<sup>3</sup> and microimplants (MIs)<sup>4</sup> as anchorage, it has become possible to distalize the mandibular posterior teeth without anchorage loss. However, there have been few case reports involving the distalization of the mandibular posterior teeth with MIs. Therefore, this case report demonstrates the efficacy and potency of MIs as an anchorage aid in the case of severe bialveolar protrusion with the absence of mandibular second molar.

## CASE REPORT

### Diagnosis

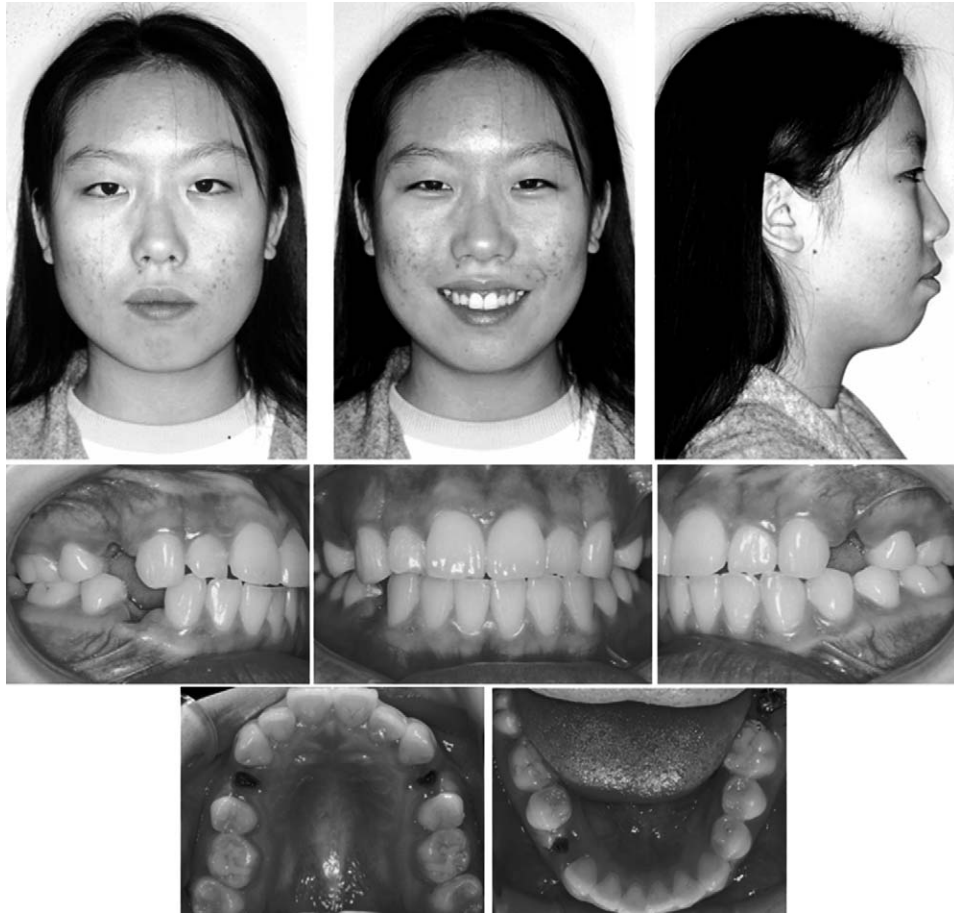
A 16-year-old girl presented with the chief complaint of having lip protrusion. Facially, the patient exhibited a convex profile with a marked protrusion of her lips. Intraorally, she had Class I canine and molar relationships with minor crowding (Figures 1 and 2). The panoramic radiograph showed the presence of severe decay on the mandibular left second molar. It also revealed the presence of four third molars (Figure 3).

The lateral cephalogram (Figure 4) and its tracing showed a Class I bialveolar protrusive skeletal pattern. As evidenced by the FMA (Frankfort mandibular angle) of 28.5° and the FHI (facial height index) of 0.67%, the skeletal pattern was normodivergent. The occlusal

<sup>a</sup> Assistant Professor, The Korean Orthodontic Research Institute Inc and School of Medicine, Eulji University, Orthodontics/Dentistry, Daejeon, South Korea.

Corresponding author: Dr Jong-Moon Chae, The Korean Orthodontic Research Institute Inc and School of Medicine, Eulji University, Orthodontics/Dentistry, 1306, Dunsan-Dong, Seo-Gu, Daejeon, 302-799, South Korea (e-mail: jongmoon@eulji.ac.kr)

Accepted: April 2006. Submitted: February 2006.  
© 2006 by The EH Angle Education and Research Foundation, Inc.



**Figure 1.** Pretreatment facial and intraoral photographs.

plane angle of  $15.5^\circ$  reflected the vertical dental problem. The IMPA (incisor mandibular plane angle) of  $103.0^\circ$  reflected the proclination of the lower incisors. The Z-angle of  $55.5^\circ$  quantified the facial imbalance (Table 1). There were no significant signs or symptoms of temporomandibular disorders.

### Treatment Objectives

Treatment objectives included the following: (1) align and level the teeth in both arches and establish functional occlusion, (2) normalize the overjet and overbite relationships, (3) obtain a balanced facial profile, and (4) improve smile esthetics.

### Treatment Alternatives

The first alternative was retraction of the maxillary and mandibular anterior teeth by using maximum anchorage after four first premolar extractions. This option is commonly used to reduce the patient's lip proclivity, but it would require additional prosthetic treatment. The loss of a decayed tooth and adjunctive expenditure would be a burden to the patient.

The second alternative was distalization of the left

mandibular posterior teeth without extraction of the mandibular left first premolar by using conventional molar distalization methods. However, this option would depend considerably on patient cooperation and result in an even longer treatment time than with extraction of the first premolars.

The third alternative was retraction of the anterior teeth with simultaneous distal movement of the mandibular posterior teeth by using absolute anchorage. In this option, additional prosthesis would be avoided because of the retention of the mandibular left first premolar. This option would preserve the mandibular left first premolar, shorten the treatment time, and result in a good result without patient compliance. Therefore, this treatment plan was chosen.

### Treatment Progress

The treatment plan involved sliding and loop mechanics in the maxilla and mandible, respectively, after the extraction of the maxillary first premolars, the mandibular right first premolar, and the mandibular left second molar. After the extractions, fixed preadjusted appliances ( $0.022 \times 0.028$ -inch slot) and a 0.018-inch

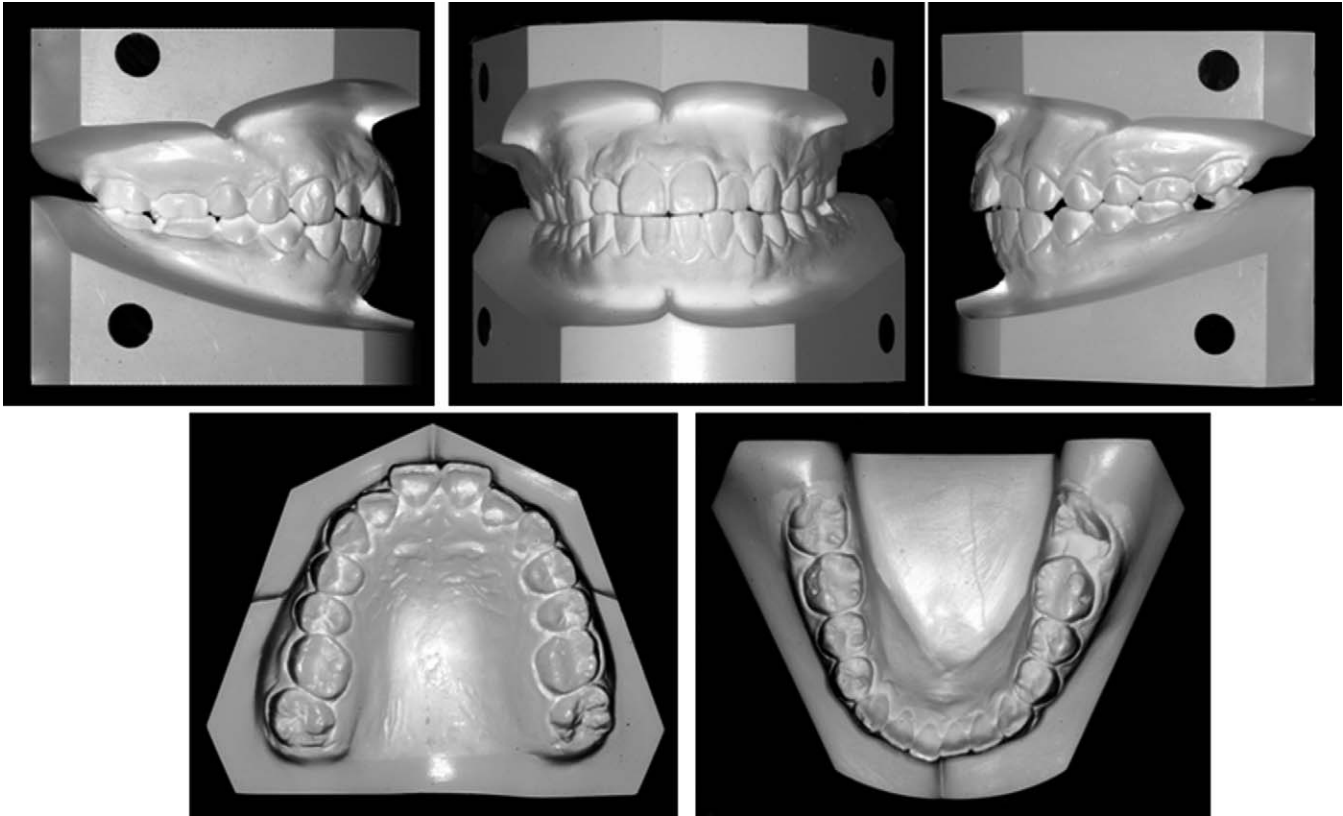


Figure 2. Pretreatment dental casts.

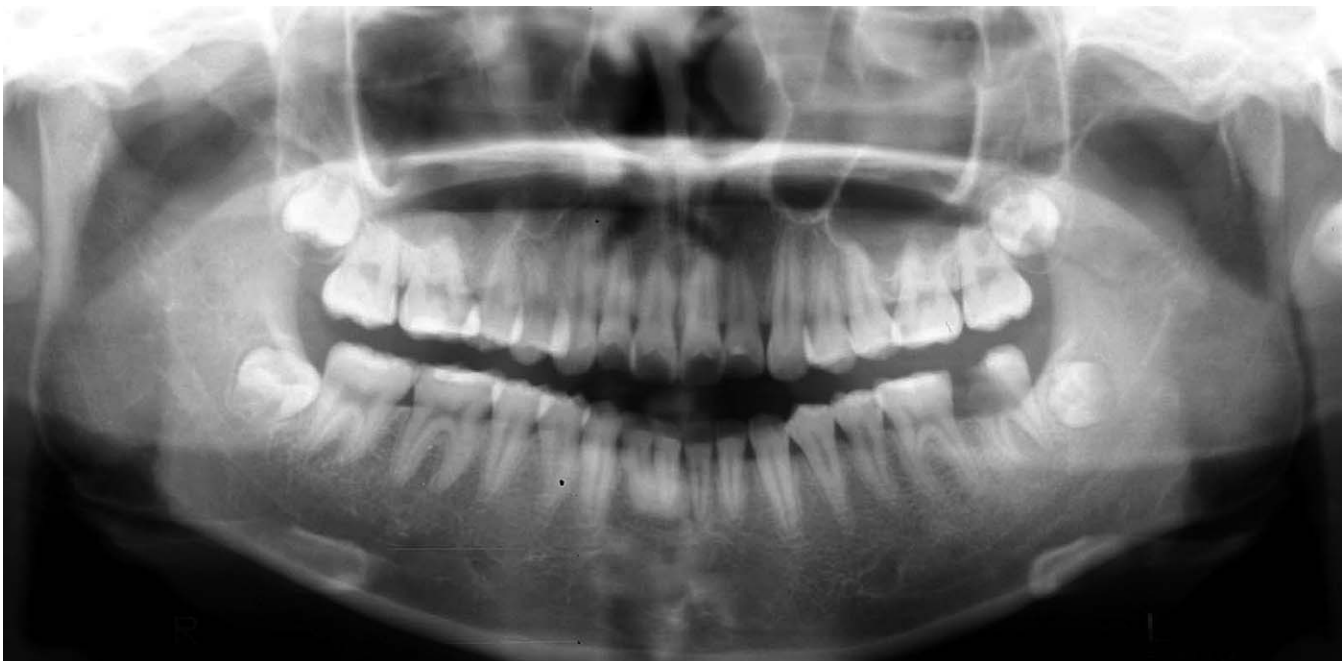
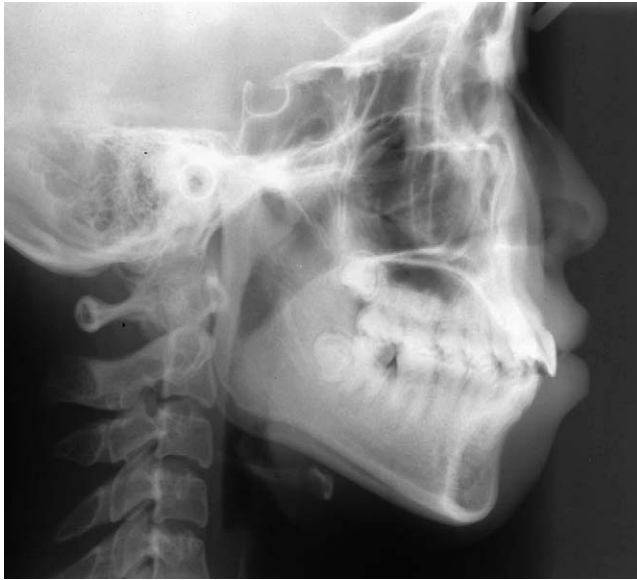
Figure 3. Pretreatment panoramic radiograph.





**Figure 4.** Pretreatment lateral cephalometric radiograph.

nickel titanium (Ni-Ti) archwire were placed in the maxillary arch, and 0.022- × 0.028-inch nontipped, nontorqued edgewise appliances and a 0.018-inch stainless-steel (S-S) archwire were placed in the mandibular arch (Figure 5).

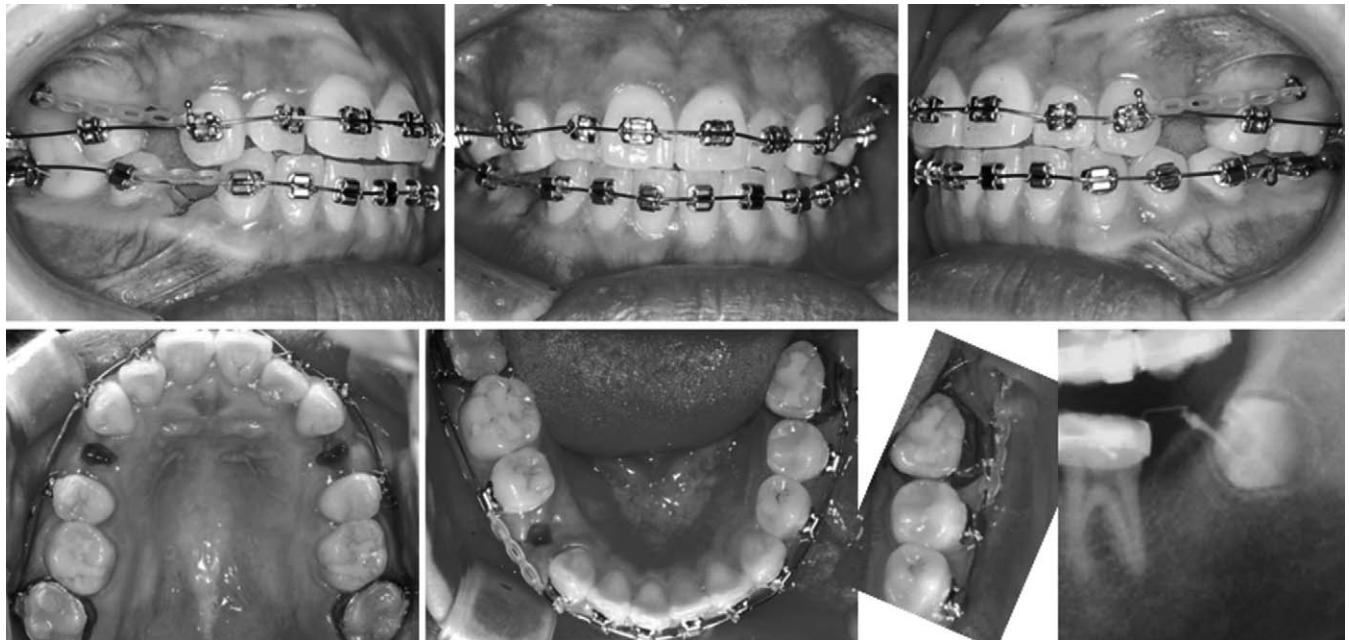
The maxillary posterior MIs (1.2 mm in diameter, 7 mm in length; Absoanchor AX12-107, Dentos Co, Taegu, South Korea) were implanted into the buccal alveolar bone between the maxillary second premolars and first molars, and the mandibular posterior MI (1.2

**Table 1.** Cephalometric Measurements<sup>a</sup>

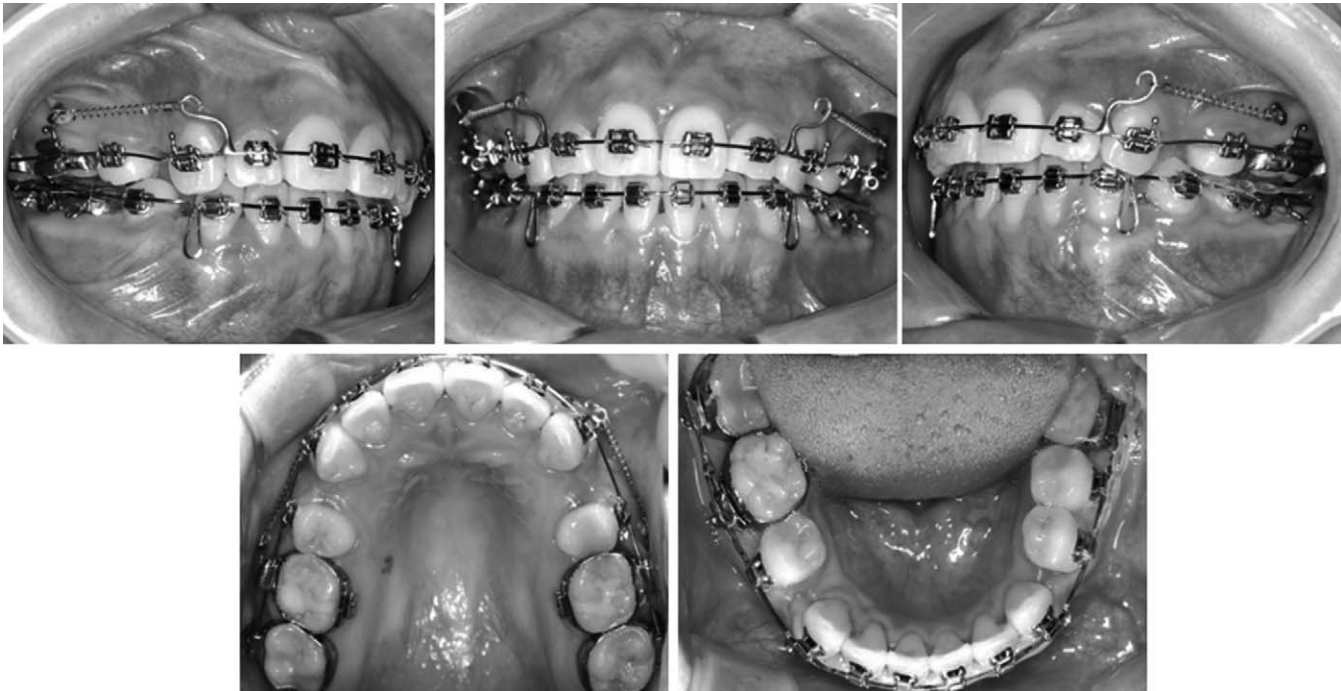	Pretreatment	Posttreatment
FMIA (°)	48.5	62.5
FMA (°)	28.5	28.5
IMPA (°)	103.0	89.0
SNA (°)	77.5	76.0
SNB (°)	73.5	73.5
ANB (°)	4.0	2.5
AO-BO (mm)	-5.0	-5.5
Occlusal plane angle (°)	15.5	16.0
FH to U1 (°)	113.5	106.0
Z-angle (°)	55.5	68.0
FHI (PFH/AFH) (%)	0.67 (52.0/76.5)	0.68 (52.0/77.0)

<sup>a</sup> FMIA indicates angle between Frankfort plane and mandibular incisor axis; FMA, angle between Frankfort plane and mandibular plane; IMPA, angle between lower incisor axis and mandibular plane; SNA, angle between SN and NA; SNB, angle between SN and NB; ANB, difference between the SNA and SNB angles; AO-BO, distance between perpendiculars drawn from point A and point B onto the occlusal plane; FH, Frankfort horizontal plane; UI, maxillary incisor axis; FH to UI, angle between Frankfort plane and maxillary incisor axis; FHI, ratio of PFH to AFH; PFH, linear measurement from articulare, along a line tangent to the posterior border of the mandible, to the intersection with the mandibular plane; and AFH, linear measurement from palatal plane to menton, measured perpendicular to palatal plane.

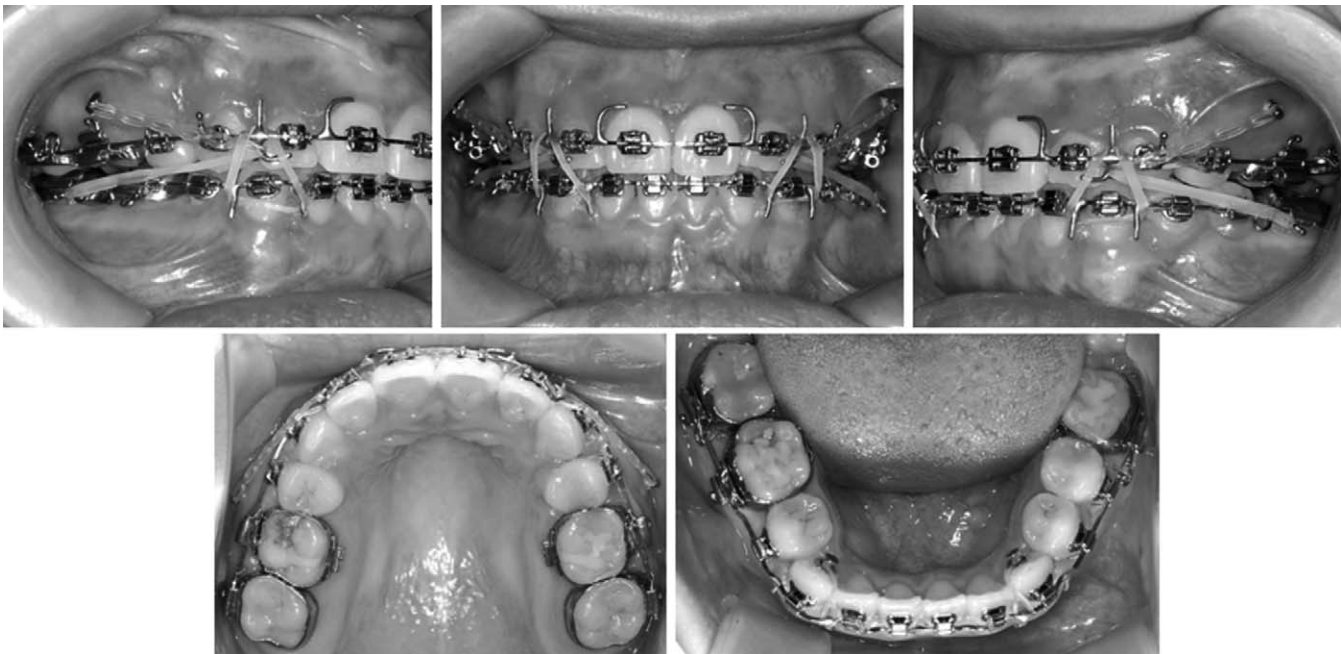mm in diameter, 6 mm in length; Absoanchor AX12-106, Dentos Co) was implanted into the retromolar area. In the mandible, a ligature wire was extended from the head of the MI, which was submerged by soft tissue, to the distal area of the mandibular left first molar (Figure 5).



**Figure 5.** Leveling and retraction of canines, 0.018-inch nickel titanium archwire in maxillary arch, 0.018-inch stainless-steel archwire with omega loop stop in mandibular arch, and placement of microimplants.



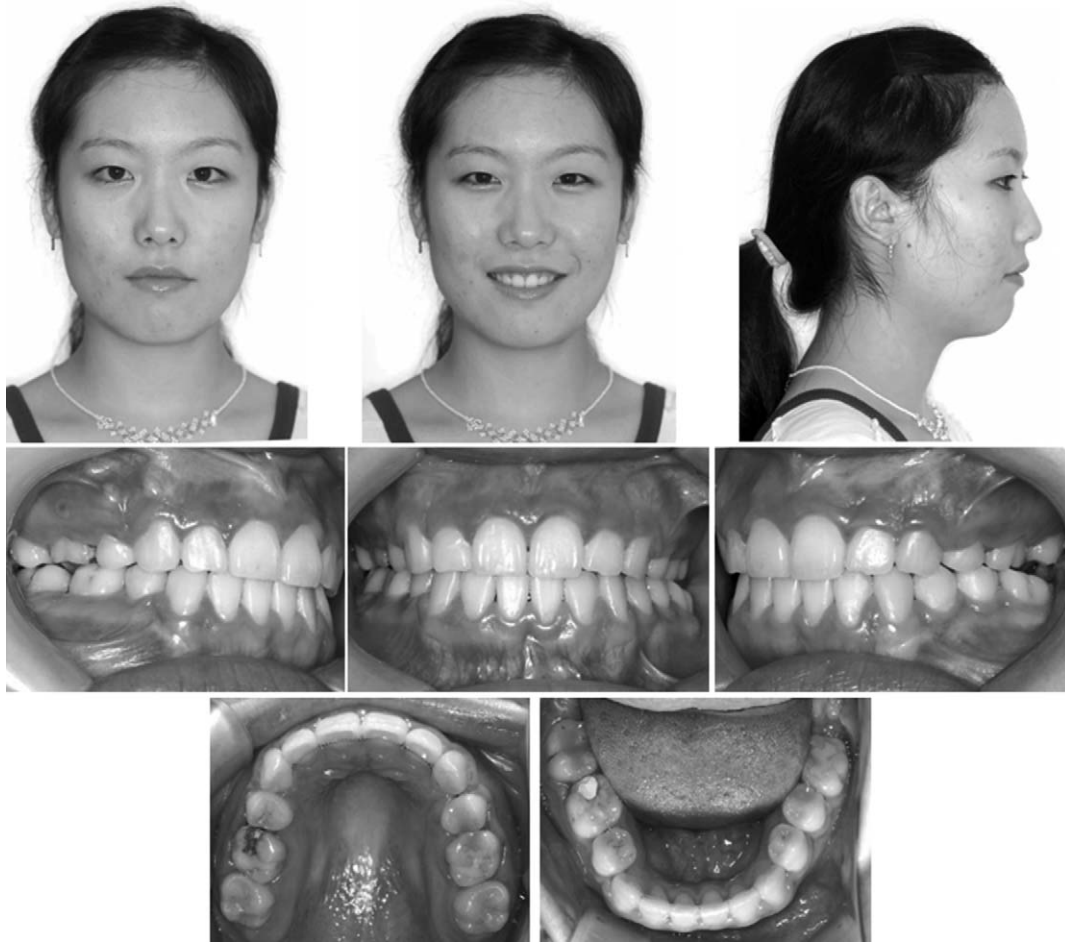**Figure 6.** Distalization of mandibular left posterior teeth, en masse retraction of six anterior teeth in both arches.



**Figure 7.** Directional forces after periodontal surgical treatment with the removal of mandibular microimplant and third molar.

Immediately after placement of the MIs, an elastic chain force was loaded from the maxillary posterior MIs to the canine brackets on both sides, retracting the maxillary canines to create enough space to align the anterior teeth. After the maxillary anterior teeth

were aligned, a 0.017- × 0.022-inch S-S archwire with anterior hooks was placed, Ni-Ti retraction force was applied from the maxillary posterior MIs, and the six anterior teeth were retracted simultaneously (Figures 5 and 6).



**Figure 8.** Posttreatment facial and intraoral photographs.

In the mandible, an elastic chain force was loaded from the extended ligature wire to the mandibular left first premolar, retracting the mandibular left posterior teeth simultaneously to create enough space to retract the anterior teeth. After the mandibular left posterior teeth were distalized into a Class II molar relationship, a 0.019- × 0.025-inch S-S archwire with closing loops was placed, and the six anterior teeth were retracted simultaneously (Figure 6).

After en masse movement, directional force control was used to promote a mandibular response after the removal of the mandibular third molars and the MI (Figure 7). The treatment was completed with ideal archwires and cusp seating elastics. Lingual bonded retainers on the six anterior teeth and circumferential clear retainers were delivered for both arches. The total treatment time was 30 months.

### Treatment Results

The posttreatment facial photographs showed a nicely balanced and harmonious face by retracting the upper and lower lips (Figure 8). The posttreatment

casts illustrated a good interdigitation of the teeth and an acceptable overjet-overbite relationship (Figure 9). The posttreatment panoramic radiograph (Figure 10) revealed uprighting of the mandibular left first molar.

On cephalometric superimposition, the maxillary anterior teeth were bodily retracted with intrusion, the maxillary posterior teeth were slightly intruded, the mandibular anterior teeth were retracted with uprighting, the mandibular posterior teeth were slightly extruded, and the mandibular left posterior teeth were considerably distalized. The ANB angle was reduced by 1.5°, which resulted from a 1.5° decrease of the SNA angle. The FMA was maintained by a vertical control of the dentition. The lower incisors were uprighted from 103.0° to 89.0° and the Z-angle was improved from 55.5° to 68.0° (Table 1). All these changes contributed to improving the facial profile (Figures 11 and 12).

### DISCUSSION

Bialveolar protrusion, which is characterized by den-  
toalveolar flaring of both the maxillary and mandibular



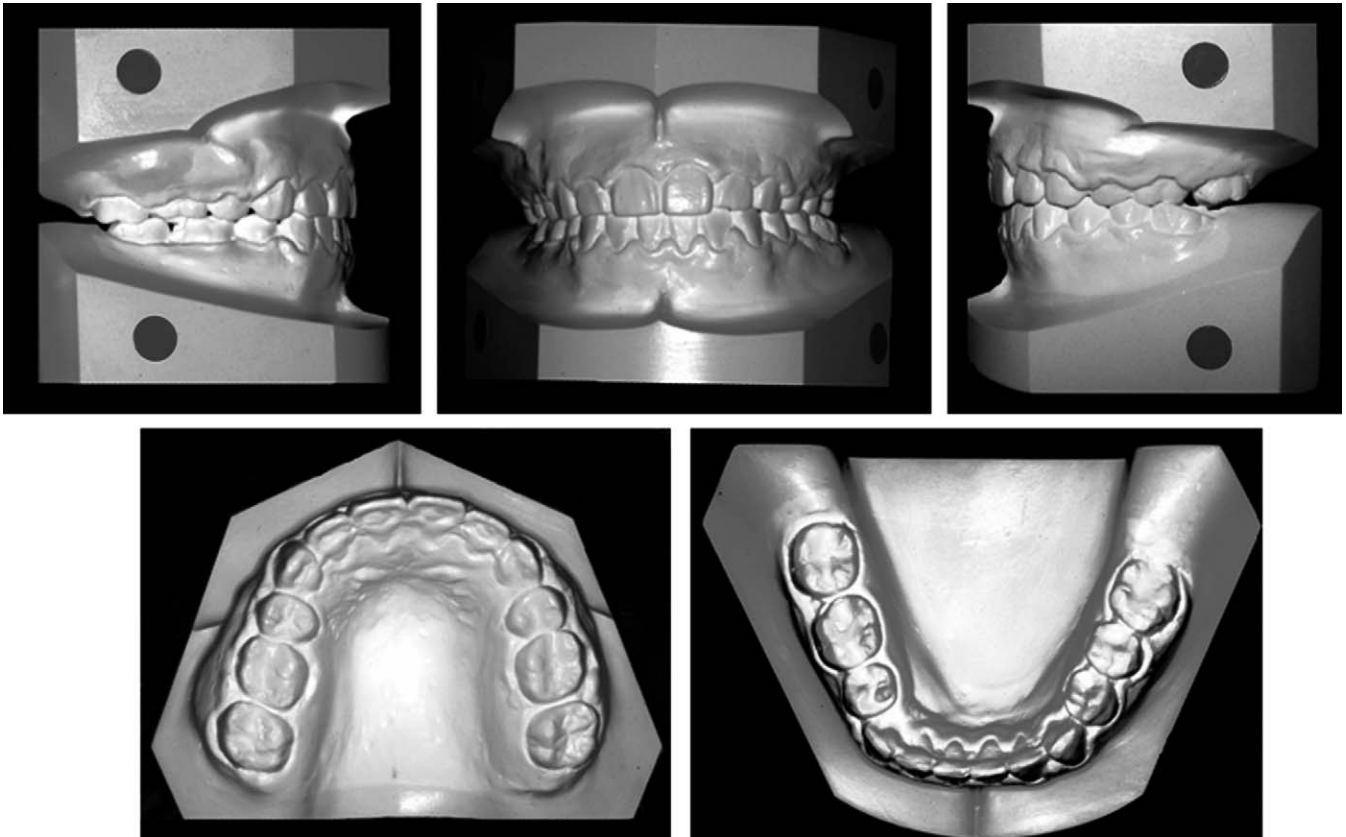


Figure 9. Posttreatment dental casts.

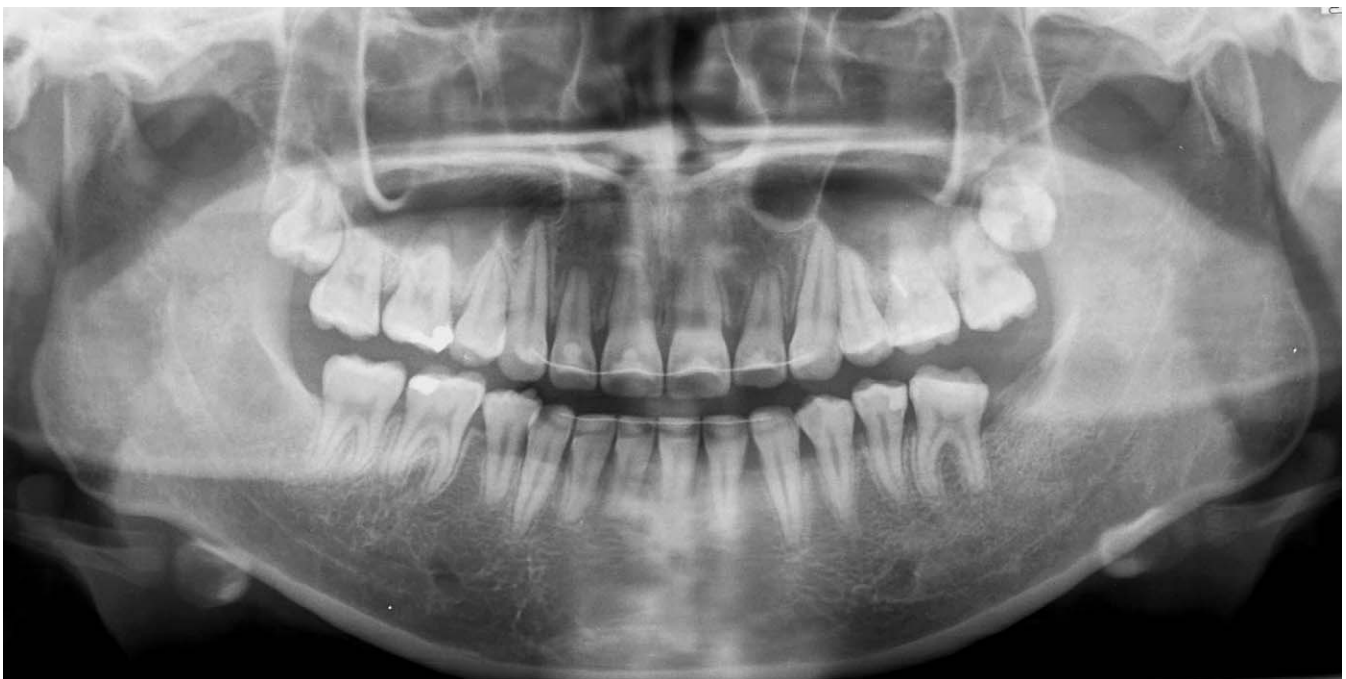

Figure 10. Posttreatment panoramic radiograph.

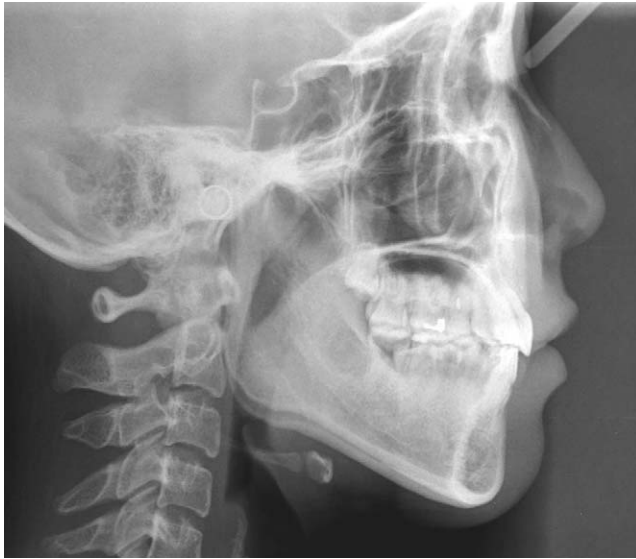

Figure 11. Posttreatment lateral cephalometric radiograph.

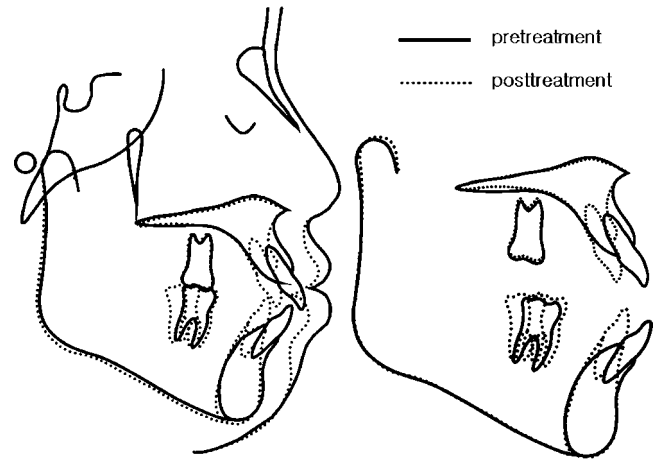


Figure 12. Cephalometric superimposition.

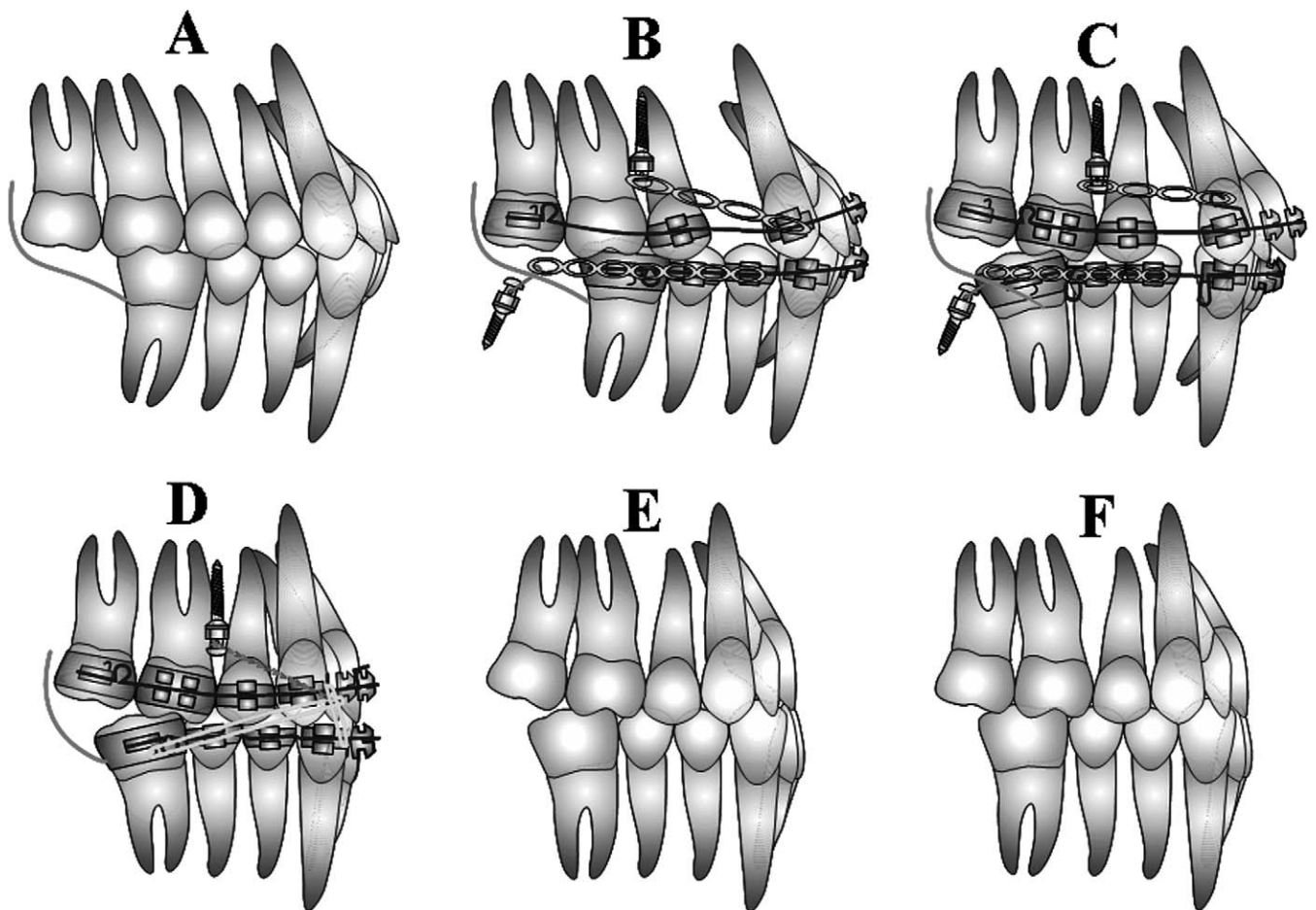


Figure 13. Schematic illustration of the use of microimplant (MI) anchorage in the case of unusual extraction of Class I bialveolar protrusion. (A) Before treatment. (B) Placement of MIs, leveling and canine retraction in maxillary arch, and distalizing force application from MIs to mandibular posterior teeth. (C) En masse retraction of six anterior teeth by using sliding mechanics in maxillary arch and loop mechanics after distalization of posterior teeth in mandibular arch. (D) Directional forces after periodontal surgical treatment with removal of mandibular MIs. (E) Tweed occlusion. (F) Denture recovery.



anterior teeth, with resultant protrusion of the lips and convexity of the face, is commonly seen in Asian populations.<sup>5</sup> Facial esthetics is an important consideration in orthodontic treatment particularly when extractions are considered. It is accepted in orthodontics that extraction of permanent teeth reduces facial convexity. On the basis of the patient's chief complaint and the diagnosis of the malocclusion, extracting the maxillary and mandibular first premolars is a viable option to decrease lip procumbency.

There are many clinical situations necessitating unusual extraction of molars that have extensive caries, large restorations, canal fillings, and apical pathology. The second molar extraction is indicated when (1) they are severely carious, ectopically erupted, or severely rotated; (2) mild-to-moderate arch length deficiencies exist with good facial profiles; and (3) there is crowding in the posterior area with a need to facilitate first molar distal movement.<sup>6</sup> The patient had a severely decayed mandibular second molar on the left side. Therefore, it was removed as an alternative to the extraction of the first premolar.

When the second molars are extracted in a patient with bialveolar protrusion, distal movement of molars and maximum retraction of the anterior teeth are essential to preserve healthy, sound premolars and achieve the treatment goals. Numerous extraoral and intraoral appliances have been proposed for distalizing maxillary molars, but there have not been many studies of mandibular molar distalization.<sup>7,8</sup> These appliances have disadvantages such as the need for patient cooperation, tipping movement, anchorage loss, and flaring of the incisors.

To date, clinical efficacy<sup>9-12</sup> and stability<sup>13,14</sup> of temporary skeletal anchorage devices have been widely described. It has turned out to be a very efficient method in solving an orthodontic problem that could not be corrected by a conventional method.

With the use of the MI, distalization of the mandibular left posterior teeth into the second molar extraction space and maximum en masse retraction of the mandibular anterior teeth were possible without patient compliance. During retraction of the anterior teeth, MI anchorage (MIA) was used to prevent the mesial movement of the posterior teeth. After en masse movement of the anterior teeth, periodontal surgical treatment for clearing the accumulated soft tissue over the crown of the first molar was accompanied with the removal of the MI and third molar, and directional forces were applied. In the maxilla, the entire dentition was retracted with sliding mechanics by using MIA according to the method previously described (Figure 13).<sup>11</sup>

The vertical and horizontal component of force is determined by the vertical position of ligature wire ex-

tended from the MI head. The mandibular left posterior teeth had a tendency toward distal tipping with slight extrusion. Therefore, the position of MI head and extended ligature wire should be carefully considered according to the type of malocclusion and the amount and direction of tooth movement required.

## CONCLUSIONS

- MIs can provide absolute anchorage for distal movement of buccal teeth in a group and maximum retraction of the anterior teeth without removal of premolars in a patient with bialveolar protrusion.
- MIA can simplify the treatment plan in the unusual mandibular second molar extraction treatment of Class I bialveolar protrusion.

## REFERENCES

1. Bills DA, Handelman CS, BeGole EA. Bimaxillary dentoalveolar protrusion: traits and orthodontic correction. *Angle Orthod.* 2005;75:333-339.
2. Langberg BJ, Todd A. Treatment of a Class I malocclusion with severe bimaxillary protrusion. *Am J Orthod Dentofacial Orthop.* 2004;126:739-746.
3. Sugawara J, Daimaruya T, Umemori M, Nagasaka H, Takahashi I, Kawamura H, Mitani H. Distal movement of mandibular molars in adult patients with the skeletal anchorage system. *Am J Orthod Dentofacial Orthop.* 2004;125:130-138.
4. Park HS, Lee SK, Kwon OW. Group distal movement of teeth using microscrew implant anchorage. *Angle Orthod.* 2005;75:510-517.
5. Lamberton CM, Reichart PA, Triratnanimit P. Bimaxillary protrusion as a pathologic problem in the Thai. *Am J Orthod.* 1980;77:320-329.
6. Bishara SE, Ortho D, Burkey PS. Second molar extractions: a review. *Am J Orthod.* 1986;89:415-424.
7. Davidovitch M, McInnis D, Lindauer SJ. The effects of lip bumper therapy in the mixed dentition. *Am J Orthod Dentofacial Orthop.* 1997;111:52-58.
8. Byloff F, Darendeliler MA, Stoff F. Mandibular molar distalization with the Franzulum Appliance. *J Clin Orthod.* 2000;34:518-523.
9. Creekmore TD, Eklund MK. The possibility of skeletal anchorage. *J Clin Orthod.* 1983;17:266-269.
10. Kanomi R. Mini-implant for Orthodontic Anchorage. *J Clin Orthod.* 1997;31:763-767.
11. Park HS, Bae SM, Kyung HM, Sung JH. Micro-implant anchorage for treatment of skeletal Class I bialveolar protrusion. *J Clin Orthod.* 2001;35:417-422.
12. Chae JM. A new protocol of Tweed-Merrifield directional force technology using Micro-Implant Anchorage (MIA). *Am J Orthod Dentofacial Orthop.* 2006;130:100-109.
13. De Pauw GA, Dermaut L, De Bruyn H, Johansson C. Stability of implants as anchorage for orthopedic traction. *Angle Orthod.* 1999;69:401-407.
14. Miyawaki S, Koyama I, Inoue M, Mishima K, Sugahara T, Takano-Yamamoto T. Factors associated with the stability of titanium screws placed in the posterior region for orthodontic anchorage. *Am J Orthod Dentofacial Orthop.* 2003;124:373-378.