

## AP Relationship of the Maxillary Central Incisors to the Forehead in Adult White Females

Will Alan Andrews<sup>a</sup>

### ABSTRACT

**Objective:** To evaluate and compare the anteroposterior relationship of the maxillary central incisors to the forehead in adult white females with harmonious profiles and in adult white female orthodontic patients.

**Materials and Methods:** Ninety-four photographic images of adult white females with good facial harmony (control sample) were compared with 94 photographs of adult white females seeking orthodontic treatment (study sample). All images were of the face in profile with the maxillary central incisors and the forehead in full view. The images were scanned, resized, and rotated to the upright head position. Reference lines were constructed to assess the anteroposterior positions of the maxillary central incisors as well as forehead inclinations.

**Results:** In the control sample, 93% had maxillary central incisors positioned between the FFA point and glabella, 4% posterior to the FFA point, and 3% anterior to glabella. The positions of the maxillary central incisors were strongly correlated with forehead inclination ( $r^2 = .642$ ). In the study sample, 21% had maxillary central incisors positioned between the FFA point and glabella, 64% posterior to the FFA point, and 15% anterior to glabella. The positions of the maxillary central incisors were poorly correlated with forehead inclination ( $r^2 = .094$ ). The difference between the means for anteroposterior maxillary incisor position was statistically significant ( $P = .0001$ ).

**Conclusion:** The forehead is an important landmark for anteroposterior maxillary incisor positioning for adult white female patients seeking improved facial harmony.

**KEY WORDS:** Incisors; Forehead

### INTRODUCTION

Facial esthetics is an important motivating factor for many patients seeking orthodontic treatment.<sup>1-3</sup> Evaluating the face in profile is an integral part of a complete orthodontic diagnosis. Differing methods for evaluating facial profiles have been proposed in the orthodontic literature including traditional cephalometrics and repose soft-tissue analysis. Traditional cephalometrics uses internal osseous landmarks to define points, lines, and/or planes, which in turn are used to quantify anteroposterior (AP) jaw and incisor positions. The use of such landmarks, however, can be unreliable because of both errors in identification and variability in their positions between individuals.<sup>4-10</sup> In ad-

dition, good facial harmony has been shown to exist within a wide range of cephalometric values.<sup>11,12</sup>

Recognition of these limitations led others to advocate for the use of external soft tissue landmarks such as the nose, lips, and chin to replace or augment cephalometric profile analysis.<sup>13-25</sup> Soft tissue structures, however, may not reliably convey the positions of the underlying hard tissue structures.<sup>26,27</sup> There is no reliable correlation, for example, between the nasolabial angle and the position of the maxillary incisors in profile (Figure 1). Furthermore, there may not be a predictable response of the nasolabial angle or upper lip curvature to treatment-induced AP hard tissue changes.<sup>28-34</sup> Changing the AP position of the maxilla or maxillary incisors to establish a desired nasolabial angle or a desired relationship of the lips to the nose or chin may result in undesirable positions of the maxillary incisors in relation to other external facial structures when the maxillary incisors are directly viewed in profile.

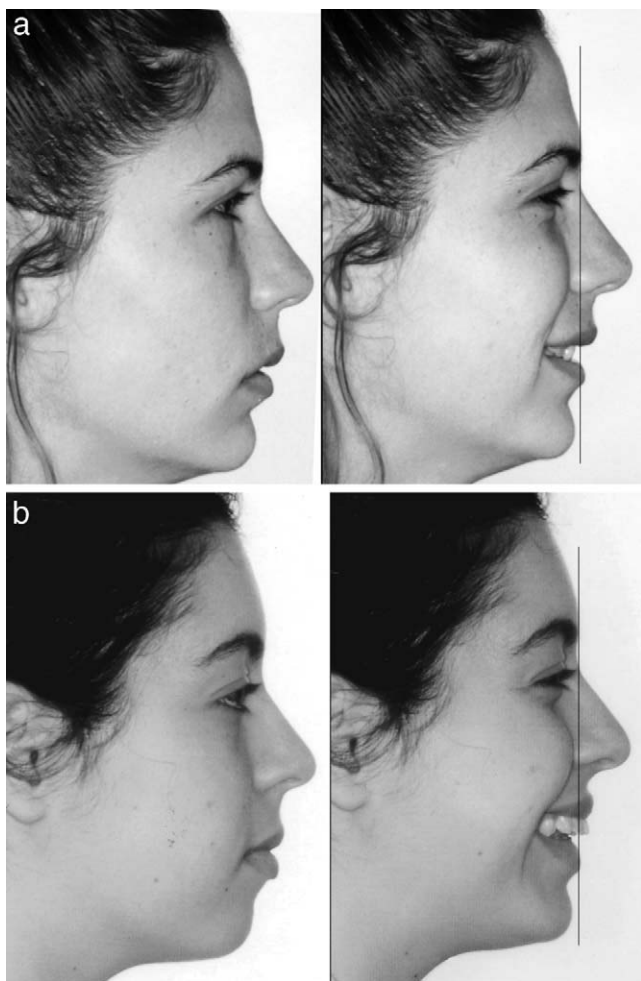The maxillary incisors, when displayed, should be considered a part of the face both from the frontal and

<sup>a</sup> Private practice, San Diego, Calif.

Corresponding author: Dr Will Alan Andrews, 2025 Chatsworth Blvd, San Diego, CA 92107  
(e-mail: drandrews@msn.com)

Accepted: September 2007. Submitted: July 2007.

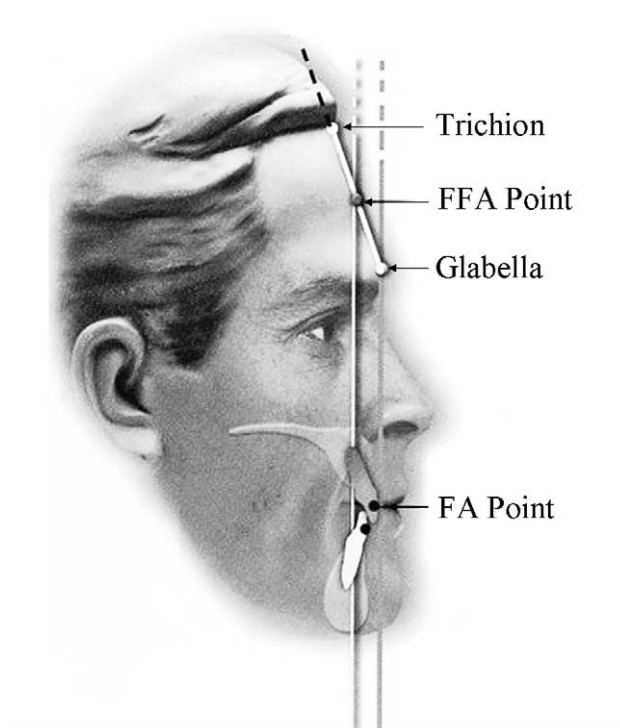
© 2008 by The EH Angle Education and Research Foundation, Inc.



**Figure 1.** The inclination of the upper lip (nasolabial angle) does not reliably reflect the underlying anteroposterior position of the maxillary central incisors when they are directly viewed. (A) A patient with an acute nasolabial angle with the maxillary central incisors positioned well behind glabella. (B) A patient with an acute nasolabial angle with the maxillary central incisors positioned forward of glabella.

lateral perspectives. Contemporary orthodontic diagnosis includes assessing the display of the maxillary incisor teeth from the frontal perspective. In profile, however, the maxillary incisors are not typically assessed with regard to how they directly relate to the face. Instead, the soft tissue drape is relied on to reflect indirectly their positions, despite the potential unreliability of that method. Previous studies have not specifically examined the relationship between the maxillary central incisors and other external facial landmarks in profile when the incisors are displayed.

Andrews has written about the use of the forehead as a landmark for assessing the AP position of the maxillary central incisors in profile.<sup>35</sup> Andrews defined forehead landmarks and observed the correlation between the forehead's prominence and inclination and the position of the maxillary central incisors in individ-



**Figure 2.** Landmarks used by Andrews to assess the anteroposterior position of the maxillary central incisors relative to the forehead.

uals with good facial profiles (Figure 2). Schlosser et al<sup>36</sup> found that Andrews' method of profile assessment was "a useful method to evaluate attractiveness relative to the maxillary incisor position."

The purpose of this study is to evaluate and compare the AP relationship of the maxillary central incisors to the forehead in adult white females with harmonious profiles (control sample) with a random sample of adult white female orthodontic patients not specifically selected for any skeletal, dental, or facial characteristics (study sample). Finding a predictable relationship between the AP position of the maxillary central incisors and the forehead in individuals with good facial harmony could provide guidelines for orthodontic diagnosis and treatment planning for patients seeking improved facial harmony.

## MATERIALS AND METHODS

The control sample consisted of 94 printed facial photographic images of adult white females in profile collected from various publications including fashion magazines and product advertisements. The criteria for inclusion were that the maxillary central incisors and forehead were fully bared and that the subjects had a generally pleasing appearance in profile (Figure 3). The subjects, by virtue of having been selected to appear in such publications, were deemed to possess inherently good facial harmony and were excluded

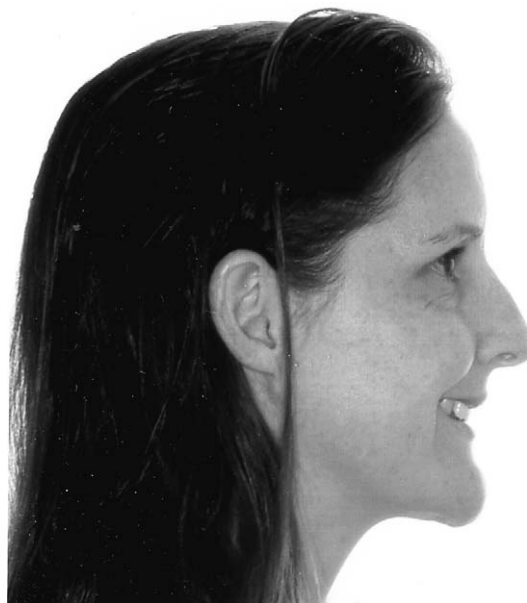

**Figure 3.** Example of an image used in the control sample.

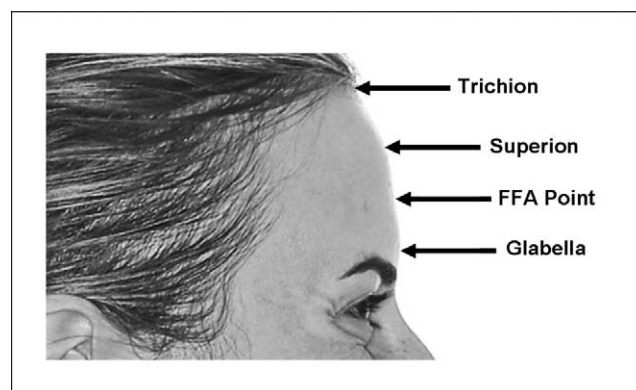
only if the image quality was insufficient to be able to identify the required landmarks.

The study sample consisted of facial profile photographs from pretreatment records of a random sample of 94 of adult white females seeking orthodontic treatment. The first 94 adult white females with a complete set of beginning records selected in alphabetic order from the active patient files in one orthodontic practice were used. Pleasing appearances in profile were not a required selection criterion for this sample, nor were individuals excluded from the sample if they had a pleasing appearance in profile. No specific skeletal, dental, or facial characteristics were used to select the sample. All images were in profile with the maxillary central incisors and the forehead fully bared (Figure 4).

Each image was digitally scanned (Epson Perfection 2400 photo scanner) to a computer (Sony VAIO). The images were then imported into a PowerPoint file (Microsoft PowerPoint version 2002, Seattle, Wash), resized to approximate life size, and rotated to an estimated upright head position. The final upright head position was confirmed by two independent observers. Approximate life size was determined the using the average vertical distance from trichion (hairline) to the incisal edge of the maxillary central incisors measured on the pretreatment lateral cephalograms of a random-



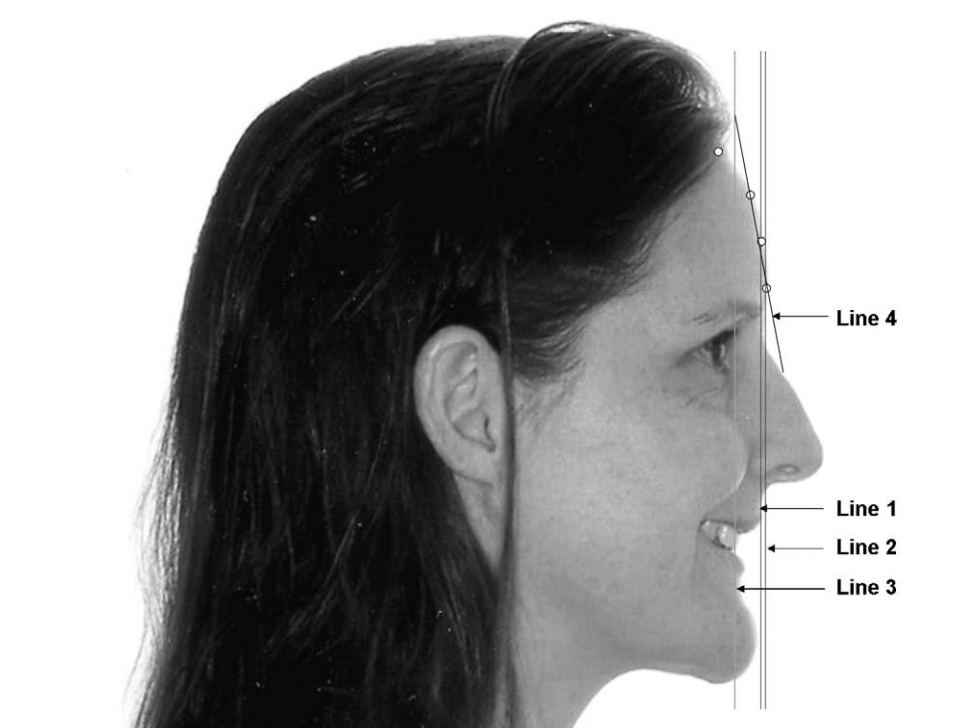
**Figure 4.** Example of an image used in the study sample.



**Figure 5.** Forehead landmark points.

ly selected sample of 10 adult white patients. The 10 subjects all had the trichion marked with barium paste prior to taking the head film. This distance was 142 mm.

Landmark points for the forehead were identified as described by Andrews<sup>35</sup> (trichion, superior, glabella, and the FFA point) and marked on each image using the drawing tool in PowerPoint (Figure 5). Trichion is defined as the hairline and is the most superior aspect of the forehead when the forehead is of relatively flat contour. Glabella is defined as the most inferior aspect of the forehead. Superior is defined as the most superior aspect of the forehead when the forehead is either rounded or angular in contour. The FFA point is defined as the midpoint between trichion and glabella for foreheads with flat contour or the midpoint between superior and glabella for foreheads with rounded or angular contour. All of these points lie on the midsag-



**Figure 6.** Reference lines used in the study. Line 1 is through the forehead's FFA point. Line 2 is through glabella. Line 3 is through the maxillary central incisor's FA point. Line 4 is through superior (or trichion for straight foreheads) and glabella.

ittal plane of the head. Three vertical reference lines were constructed: line 1 through the FFA point, line 2 through glabella, and line 3 through the maxillary central incisor's FA point. A fourth reference line (line 4) for assessing forehead inclination was constructed by connecting glabella to the uppermost point of the clinical forehead (superion point or trichion) as described by Andrews<sup>35</sup> (Figure 6). Forehead inclination was defined as the angle between line 1 and line 4.

The photographic image was deleted from each PowerPoint slide, leaving only the constructed reference points and lines. The slides were then printed on 8½" × 11" standard white paper (Figure 7). All measurements were made on the printed paper by one examiner. The AP relationship of the maxillary central incisors to the forehead was measured as the distance between line 1 and line 3 using a metric ruler to the closest 0.5 mm. A positive value was assigned when the maxillary central incisors (line 3) were anterior to the forehead's FFA point (line 1) and negative when posterior. Forehead inclination was measured as the angle between line 4 and line 1 using a protractor to the closest 0.5°.

### Statistical Analysis

Descriptive and comparative statistical analyses were performed using StatView Student computer software (Abacus Concepts Inc, Berkeley, Calif). The

means, standard deviations, and ranges were calculated for maxillary central incisor position relative to the forehead and for forehead inclination in both samples. The means for both samples were compared using a paired two-tailed *t*-test. *P* values of .05 or less indicated significant differences. A simple second-order regression analysis was performed between the maxillary central incisor position and forehead inclination for both samples. Confidence intervals were set at 95%.

### Error Analysis

All measurements were repeated by the same examiner on a random sample of 20 subjects (10 from the study sample, 10 from the control sample). The systematic error between the first and second measurements was calculated using a paired *t*-test, for *P* < .05. The error variance was calculated according to the Dahlberg formula.<sup>37</sup>

### RESULTS

Table 1 shows the results of the measurement error analysis. The systematic errors were statistically insignificant for both incisors position (*P* = .157) and forehead inclination (*P* = .453). The error variance (Dahlberg formula) was .842 for forehead inclination and .367 for incisor position.

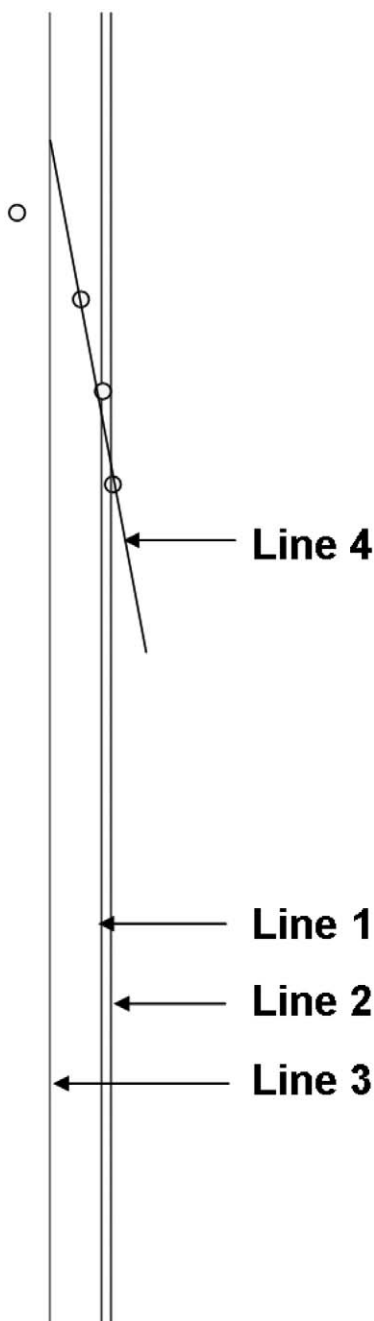


Figure 7. Reference lines with the facial image deleted.

Table 2 shows the AP position of the maxillary central incisors relative to the forehead's FFA point for the control and study samples. For the control sample, the AP position of the maxillary central incisors relative to the forehead's FFA point ranged from -1 mm to 7.5 mm, with a mean of 2.5 mm and standard deviation of 1.9 mm. For the study sample, the AP position of the maxillary central incisors relative to the forehead's FFA point ranged from -8.5 mm to 9.0 mm, with a mean of -1.2 mm and a standard deviation of 4.0 mm. The maxillary central incisor position relative to the

Table 1. Measurement Error Analysis

	First Measurement		Second Measurement		P	Dahlberg
	Mean	SD	Mean	SD		
	Incisor position	0.95	4.41	1.22		
Forehead inclination	14.02	4.41	14.25	4.34	.45	.84

Table 2. Anteroposterior Position (mm) of the Maxillary Central Incisors Relative to the Forehead's FFA Point (Distance Between Line 1 and Line 3)

	Mean	SD	Minimum	Maximum
Control sample (n = 94)	2.5	1.9	-1	7.5
Study sample (n = 94)	-1.2	4	-8.5	9

Table 3. Differences in Maxillary Central Incisor Position and Forehead Inclination Between Control and Study Samples

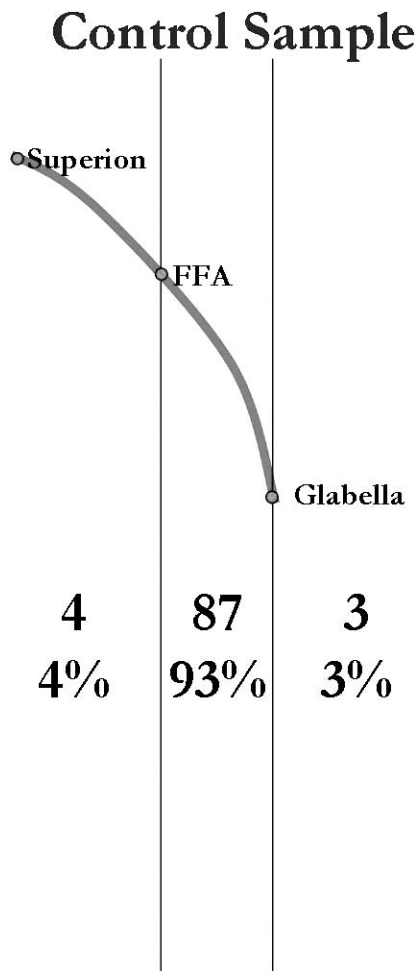
	Control	Study	t-Test
Position, mm	2.5	-1.2	.0001
Forehead inclination, °	13.7	12.5	.07

forehead's FFA point was significantly different between the control sample and the study sample ( $P = .0001$ ; Table 3).

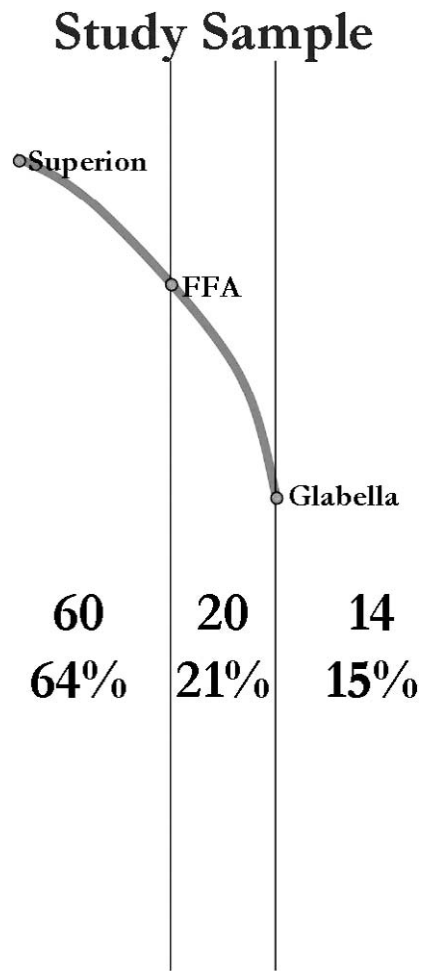
In the control sample, 4 subjects (4%) had maxillary central incisors positioned posterior to the forehead's FFA point, 3 subjects (3%) had maxillary central incisors positioned anterior to glabella, and 87 subjects (93%) had maxillary central incisors positioned somewhere at or between the FFA point and glabella (Figure 8). In the study sample, 60 subjects (64%) had maxillary central incisors positioned posterior to the forehead's FFA point. Fourteen subjects (15%) had maxillary central incisors positioned anterior to glabella. Only 20 subjects (21%) had maxillary central incisors positioned somewhere at or between the FFA point and glabella (Figure 9).

Table 4 shows the forehead inclinations for the control and study samples. For the control sample, the forehead's inclination ranged from 2° to 26°, with a mean of 13.7° and standard deviation of 4.7°. For the study sample, the forehead's inclination ranged from 2° to 27°, with a mean of 12.5° and standard deviation of 4.5°. Forehead inclination between the control sample and the study sample was not significantly different ( $P = .07$ ; Table 3).

Table 5 shows the results of the regression analysis between the AP maxillary central incisor position and forehead inclination for both samples. In the control sample, the AP positions of the maxillary central incisors were strongly correlated with forehead inclination ( $r^2 = .642$ ). When the forehead inclination was 7.5°,



**Figure 8.** Distribution of the anteroposterior maxillary central incisor positions relative to the forehead for the control sample.



**Figure 9.** Distribution of the anteroposterior maxillary central incisor positions relative to the forehead for the study sample.

the incisors tended to be directly below the forehead's FFA point (0 mm). For each degree the forehead was inclined greater than 7.5°, the incisors were correspondingly 0.5 mm more anterior to the forehead's FFA point (Figure 10). In the study sample, the AP positions of the maxillary central incisors were poorly correlated with the inclinations of the forehead ( $r^2 = .094$ ; Figure 11).

**DISCUSSION**

If the maxillary incisors are considered a part of the face, then orthodontists should evaluate the facial profile with the maxillary incisors bared. Facial landmarks other than the lips, nose, and chin are needed for assessing their position in profile when those teeth are displayed. The results of this study indicate that the forehead can be used as such a landmark. Using the forehead as a primary landmark for AP incisor positioning avoids the potential pitfalls of relying on cephalometric analysis or repose soft tissue analysis.

The AP positions of the maxillary central incisors

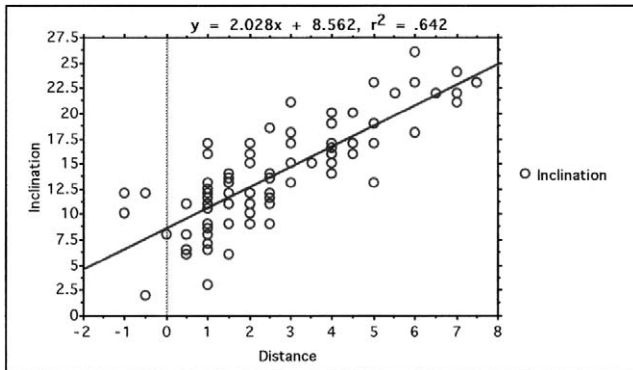
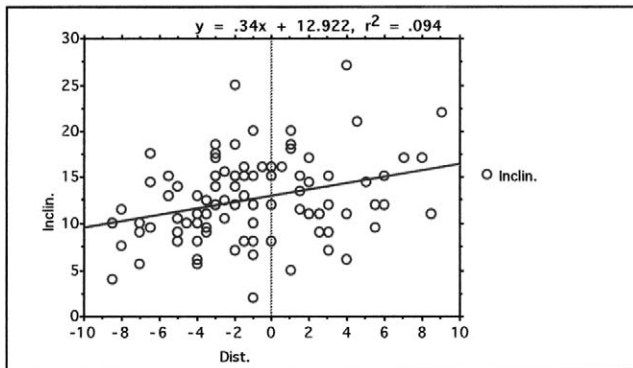
**Table 4.** Forehead Inclination (Angle Between Line 4 and Line 1, °)

	Mean	SD	Minimum	Maximum
Control sample (n = 94)	13.7	4.7	2	26
Study sample (n = 94)	12.5	4.5	2	27

were strongly associated with the forehead landmarks used in this study and strongly correlated with forehead inclination in adult white females with good facial harmony (control sample). These findings support Andrews' observations.<sup>35</sup> The study sample, which represents a typical orthodontic patient population of adult white females, exhibited characteristics distinctly different from the control sample. Most (64%) of the study sample had maxillary central incisors positioned posterior to the forehead's FFA point, compared with only 4% of the controls. Those in the study sample were also much more likely (15%) to have maxillary central incisors anterior to glabella than those in the control sample (3%). Furthermore, AP maxillary incisor position was not correlated with forehead inclination in

**Table 5.** Correlations Between Incisor Position and Forehead Inclination

Sample	Position, mm	Inclination, °	$r^2$
Control (n = 94)	2.5	13.75	.642
Study (n = 94)	-1.2	12.5	.094

**Figure 10.** Change in anteroposterior maxillary central incisor position vs change in forehead inclination for the control sample,  $r^2 = .642$ .**Figure 11.** Change in anteroposterior maxillary central incisor position vs change in forehead inclination for the study sample,  $r^2 = .094$ .

the study sample, despite the fact that forehead inclination was not found to be statistically different between the two samples.

The findings from this study can be incorporated into routine orthodontic records, diagnosis, and treatment planning. The addition of a smiling profile photograph with the forehead and maxillary incisors fully bared to diagnostic records as well as a clinical evaluation of the smiling facial profile will allow the orthodontist to document the orientation of the patients' maxillary central incisors to the forehead. The findings from the control sample can be applied as a treatment goal for adult white female patients seeking improved facial harmony. Treatment goals for adult white females should include the condition that the maxillary central incisors be positioned somewhere at or between the

forehead's FFA point and glabella and correlated with forehead inclination. Additional studies are needed to extend these findings to other racial, age, and gender groups.

## CONCLUSIONS

- Most (93%) of the adult white females with harmonious profiles examined in this study had maxillary central incisors positioned anterior to the forehead's FFA point and posterior to glabella. Furthermore, the positions of the maxillary central incisors were strongly correlated with forehead inclination.
- Comparatively few (20%) adult white females seeking orthodontic treatment (study sample) had maxillary central incisors positioned between the forehead's FFA point and glabella. Most (64%) of the control sample had maxillary incisors positioned posterior to the forehead's FFA point (compared with only 4% of the study sample). The positions of the maxillary central incisors were poorly correlated with forehead inclination.
- The forehead is a useful landmark for assessing the facial profile for adult white females as it relates to AP maxillary central incisor position. Treatment goals should include a harmonious AP relationship between the maxillary central incisors and the forehead for adult white female patients.

## REFERENCES

1. Dorsey J, Korabik K. Social and psychological motivations for orthodontic treatment. *Am J Orthod.* 1977;72:460-467.
2. Kilpelanien P, Phillips C, Tulloch JFC. Anterior tooth position and motivation for early treatment. *Angle Orthod.* 1993; 63:171-174.
3. McKiernan EXF, McKiernan F, Jones ML. Psychological profile and motives of adults seeking orthodontic treatment. *Int J Adult Orthod Orthognath Surg.* 1992;7:1887-1898.
4. Baumrind S, Frantz RC. The reliability of head film measurements. 1. Landmark identification. *Am J Orthod.* 1971; 60:111-127.
5. Baumrind S, Frantz RC. The reliability of head film measurements. 2. Conventional angular and linear measures. *Am J Orthod.* 1971;60:505-517.
6. Kvam E, Krogstad O. Variability in tracings of lateral head plates for diagnostic orthodontic purposes. *Acta Odont Scand.* 1969;27:359-369.
7. Richardson A. An investigation into the reproducibility of some points, planes, and lines used in cephalometric analysis. *Am J Orthod.* 1966;52:637-651.
8. Sandler PJ. Reproducibility of cephalometric measurements. *Brit J Orthod.* 1988;1:105-110.
9. Tourne LPM, Bevis RL, Cavanaugh G. A validity test of cephalometric variables as a measure of clinical applicability in antero-posterior profile assessment. *Int J Adult Orthod Orthognath Surg.* 1993;8:95-112.
10. Tulloch C, Phillips C, Dann C. Cephalometric measures as indicators of facial attractiveness. *Int J Adult Orthod Orthognath Surg.* 1993;8:171-179.

11. Cox NH, van der Linden FPGM. Facial harmony. *Am J Orthod*. 1971;60:175–183.
12. Moss JP, Linney AD, Lowey MN. The use of three-dimensional techniques in facial esthetics. *Semin Orthod*. 1995;1:94–104.
13. Arnett GW, Bergman RT. Facial keys to orthodontic diagnosis and treatment planning—part I. *Am J Orthod Dentofacial Orthop*. 1993;103:299–312.
14. Arnett GW, Bergman RT. Facial keys to orthodontic diagnosis and treatment planning—part II. *Am J Orthod Dentofacial Orthop*. 1993;103:395–411.
15. Bergman RT. Cephalometric soft tissue facial analysis. *Am J Orthod Dentofacial Orthop*. 1999;116:373–389.
16. Burstone CJ. Lip posture and its significance in treatment planning. *Am J Orthod*. 1967;58:262–284.
17. Burstone CJ. The integumental profile. *Am J Orthod*. 1958;44:1–25.
18. Farkas LG, Katic MJ, Hreczko TA, Deutsch C, Munro IR. Anthropometric proportions in the upper lip–lower lip–chin area of the lower face in young white adults. *Am J Orthod*. 1984;86:52–60.
19. Hambleton RS. The soft-tissue covering of the skeletal face as related to orthodontic problems. *Am J Orthod*. 1982;50:405–420.
20. Hambleton RS. The orthodontic curtain. *Angle Orthod*. 1963;33:294–298.
21. Merrifield LL. The profile line as an aid in critically evaluating facial esthetics. *Am J Orthod*. 1966;52:804–822.
22. Peck H, Peck S. A concept of facial esthetics. *Angle Orthod*. 1970;40:284–318.
23. Powell N, Humphreys B. *Proportions of the Esthetic Face*. New York, NY: Thieme-Stratton; 1984.
24. Satravaha S, Schlegel KD. The significance of the integumentary profile. *Am J Orthod Dentofacial Orthop*. 1987;92:422–426.
25. Spradley FL, Jacobs JD, Crowe DP. Assessment of the antero-posterior soft-tissue contour of the lower facial third in the ideal young adult. *Am J Orthod*. 1981;79:316–325.
26. Fields HW, Vann WF, Vig KW. Reliability of soft tissue profile analysis in children. *Angle Orthod*. 1982;52:159–165.
27. Kuyil MH, Verbeek RMH, Dermaut LR. The integumental profile: a reflection of the underlying skeletal configuration? *Am J Orthod Dentofacial Orthop*. 1994;106:597–604.
28. Kasai K. Soft tissue adaptability to hard tissues in facial profiles. *Am J Orthod Dentofacial Orthop*. 1998;113:674–684.
29. Lin PT, Woods MG. Lip curve changes in males with premolar extraction or non-extraction treatment. *Aust Orthod J*. 2004;21:71–86.
30. Lo FD, Hunter WS. Changes in nasolabial angle related to maxillary incisor retraction. *Am J Orthod*. 1982;82:384–391.
31. Moseling KP, Woods MG. Lip curve changes in females with premolar extraction or nonextraction treatment. *Angle Orthod*. 2004;74:51–62.
32. Rains MD, Nanda R. Soft-tissue changes associated with maxillary incisor retraction. *Am J Orthod*. 1982;81:481–488.
33. Ramos AL, Sakima MT, Pinto AS, Bowman SJ. Upper lip changes correlated to maxillary incisor retraction—a metallic implant study. *Angle Orthod*. 2005;75:499–505.
34. Talass MF, Talass L, Baker RC. Soft-tissue profile changes resulting from retraction of maxillary incisors. *Am J Orthod Dentofacial Orthop*. 1987;91:385–394.
35. Andrews LF, Andrews WA. *Syllabus of the Andrews Orthodontic Philosophy*. 8th ed. San Diego, Calif: Lawrence F. Andrews; 1999.
36. Schlosser JB, Preston CB, Lampasso J. The effects of computer-aided anteroposterior maxillary incisor movement on ratings of facial attractiveness. *Am J Orthod Dentofacial Orthop*. 2005;127:17–24.
37. Houston WJB. The analysis of errors in orthodontic measurements. *Am J Orthod*. 1983;83:382–390.