

NUTRITIONAL SECONDARY HYPERPARATHYROIDISM IN ALASKAN RED FOX KITS

R. W. VAN PELT, Institute of Arctic Biology, University of Alaska, Fairbanks, Alaska 99701, U.S.A.

M. T. CALEY,[□] College of Biological Sciences and Renewable Resources, University of Alaska

Abstract: Nutritional secondary hyperparathyroidism occurred in 16 red fox kits (*Vulpes vulpes*) ranging in age from 8 to 10 weeks. The kits were thin and unthrifty. The canine teeth varied in appearance from dull-pink to dull-gray. Most kits were affected with a mild bilateral conjunctivitis and some degree of kyphosis. There were palpable bilateral enlargements of the distal epiphyses of the radius, ulna, and femur, and the costochondral junctions of the ribs. Two kits examined by necropsy had lesions of progressive fibrous osteodystrophy. In four of the kits, mean plasma calcium levels (8.3 mg/100 ml) were reduced in conjunction with a concomitant rise in the mean phosphorous level (7.4 mg/100 ml). The mean plasma urea nitrogen level (24.7 mg/100 ml) was elevated and the mean total protein content (4.6 gm/100 ml) was reduced. Mean plasma activity values for alkaline phosphatase (107.8 mU/ml), lactic dehydrogenase (355.5 mU/ml), and glutamic oxaloacetic transaminase (896.8 mU/ml) were markedly elevated.

INTRODUCTION

Secondary hyperparathyroidism is the most common cause of fibrous osteodystrophy in animals.⁷ Hypocalcemia regardless of the cause stimulates increased activity of the parathyroid glands in order to maintain normal blood calcium levels. The resultant compensatory hyperparathyroidism and its associated fibrous osteodystrophy is usually caused by a lack of dietary calcium in conjunction with an excess intake of phosphorous.⁶ Chronic renal disease can also cause hypocalcemia with its attendant hyperparathyroidism. Increased parathyroid activity not only results in hypocalcemia, but hyperphosphatemia and elevated alkaline phosphatase activity levels as well.⁷ These alterations in calcium and phosphorous levels lead to varying degrees of fibrous osteodystrophy.

Rickets and osteomalacia may pro-

gress to fibrous osteodystrophy if severe hyperparathyroidism develops in the course of the disease.⁷ Frequently, fibrous osteodystrophy develops in young animals in the absence of rickets.

Presented in this report are the clinicopathologic findings for 16 red fox kits affected with lowgrade nutritional secondary hyperparathyroidism.

MATERIALS AND METHODS

Eleven red fox kits were live-trapped in June of 1971 and five in June of 1972, in conjunction with a study of red fox behavior. The kits were approximately 8 to 10 weeks of age at time of capture and were trapped in the immediate vicinity of Fairbanks, Alaska.

All of the kits received a thorough physical examination shortly after capture. Prior to transfer from individual

[□] Present address: 12217 - 126th Street, Edmonton, Alberta, Canada T5L 0W9.

This study was supported by N.I.H. Grant No. GM-10402 and N.S.F. Grant No. GB-23196.

cages to a holding pen, they were vaccinated against canine distemper, infectious hepatitis and leptospirosis,^[2] and rabies.^[3] At time of vaccination they were administered 0.5 ml of a preparation composed of 500,000 IU of vitamin A, 75,000 IU of vitamin D₂, and 50 IU of vitamin E per milliliter.^[4] The kits were then placed on a commercial dog ration^[5] supplemented with an artificial bitch's milk.^[6]

Blood samples were collected from the jugular vein of four of the kits trapped in June of 1972 and from one healthy 9-month-old female kit maintained in an animal colony by the Arctic Health Research Center, Fairbanks, Alaska. Heparin (ammonium salt)^[7] was used as the anticoagulant. Biochemical tests on plasma were performed by a commercial laboratory.^[8]

Two of the kits were examined by necropsy and their tissues subjected to detailed histopathologic examination. Tissue specimens were fixed in Bouin's fixative with 10% dimethylsulfoxide^[9] (v/v). Bone specimens were decalcified. All specimens were trimmed, paraffin embedded, sectioned 7 μ in thickness, and stained with Harris' hematoxylin and eosin Y (H & E) for routine microscopic examination.⁵ Selected specimens of bone were stained with Gomori's one-step trichrome stain and by the periodic-acid-Schiff (PAS) method employing Schiff's leucofuchsin and counterstained with Harris' hematoxylin.

RESULTS

Clinical Findings

All of the kits were thin and unthrifty in appearance. One of the kits had numerous gingival ulcers 2 to 3 mm in diameter. The canine teeth of all the kits

varied from dull-pink to dull-gray. Most kits were affected with a mild bilateral conjunctivitis. Facial enlargement was not encountered in any of the kits. There were palpable bilateral enlargements of the distal epiphyses of the radius and ulna, the distal epiphyses of the femur, and the costochondral junctions of the ribs. The radius and ulna were slightly bowed posteriorly. Most of the kits had

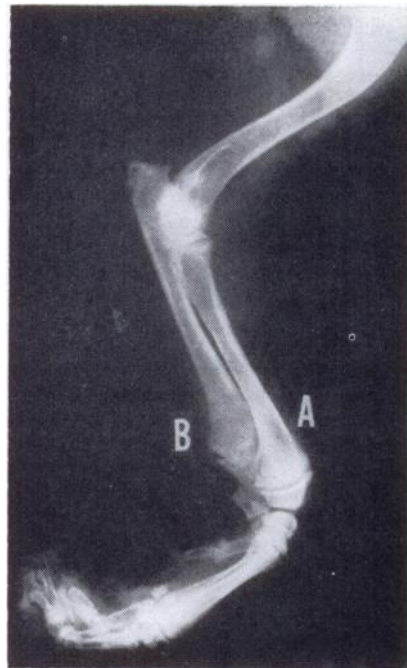

FIGURE 1. Lateral radiograph of the right forelimb. Notice the thinning of the distal cortices of the radius (A) and ulna (B) and the transverse widening of the metaphyses at the epiphyseal line. There is suggestive lipping of the margins of the metaphyses.

[2] Enduracell D-H-L, Norden Laboratories, Inc., Lincoln, Neb.

[3] Endurall-R, Norden Laboratories, Inc., Lincoln, Neb.

[4] Injectable Vitamin A-D-E-500, Biö-Ceutic Laboratories, St. Joseph, Mo.

[5] Purina Dog Meal, Ralston Purina Co., St. Louis, Mo.

[6] Esbilac, Borden's Feed Supplements Division, New York, N.Y.

[7] Sherwood Medical Industries, Inc., St. Louis, Mo.

[8] Reference Laboratory, North Hollywood, Calif.

[9] J. T. Baker Chemical Co., Philipsburg, N.J.

some degree of kyphosis. None of the kits were lame or had signs of neuromuscular hyperexcitability.

Radiographs of the forelimbs of one of the kits revealed a pronounced thinning of the bony cortices of the radius and ulna, with transverse widening of the metaphyses at the epiphyseal line (Figure 1). There was also increased radiodensity on the metaphyseal side of the diaphysis and suggested lipping of the margins of the metaphysis. Similar radiographic changes were noticed in the metacarpal bones of both limbs.

Pathologic Findings

Pathologic changes in the two kits presented for necropsy were similar. Body fat deficiencies indicated malnourishment in both kits. The costochondral junctions of the ribs were enlarged and the rib bones were pliable and easily cut. One of the kits had a partially healed fracture of the rib. The distal metaphyses and epi-

physes were enlarged transversely. The marrow of the long bones and ribs was highly vascular. The cortices of all examined bony tissues were thin and pliable. The bones that made up the cranium were thin and cut easily with autopsy shears.

Microscopic examination of the costochondral junctions revealed a minor disarray of the chondrocytes. In specimens of rib and femur, the trabeculae were scanty and diffusely arranged, and consisted mainly of pink-staining osteoid with minor evidence of calcification. Some trabeculae consisted of unmineralized osteoid tissue, the margins of which were PAS-positive. Osteoblasts were arranged along the margins of osteoid trabeculae. Osteoclastic activity was most prominent adjacent to the cortex of the bones. There was a scarcity of cellular elements in the marrow cavity, and in many areas, especially adjacent to the cortices there was a marked overgrowth of capillaries and fibrous tissue. In some areas along the shafts of the

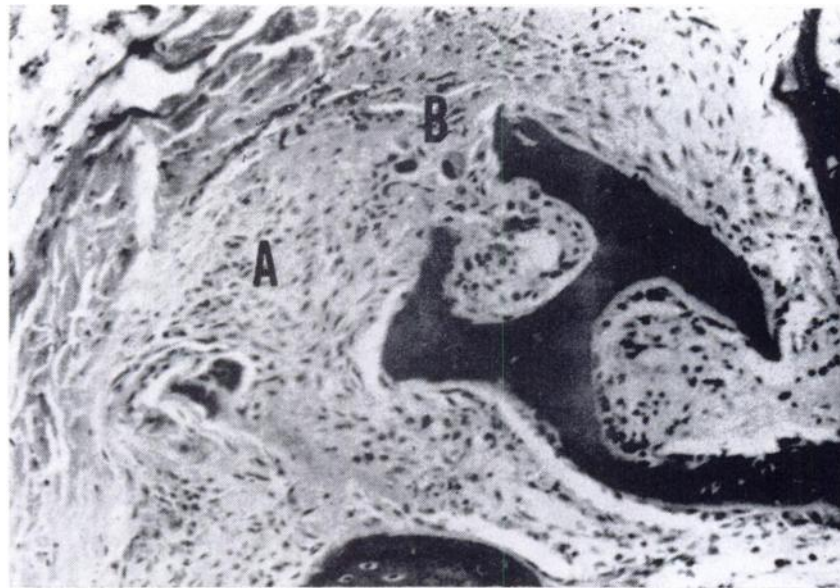


FIGURE 2. Cross section of a rib from a red fox with fibrous osteodystrophy. The cortex has been replaced by fibrous tissue (A). Osteoclasts can be seen adjacent to osteoid trabeculae (B). H and E stain 150 X.

bones, especially rib sections, the cortex appeared to be entirely absent, having been replaced by the proliferating fibrous tissue (Figure 2). Numerous giant cells were present in fibrous tissue along the shafts of the bones. The cortices of all examined bony specimens were thin. On cross-section, the Haversian canals appeared enlarged.

Present in the marrow cavity of a rib specimen from one of the kits was a homogeneous, blue-gray material surrounded by a monolayer of cells that appeared to be osteoblasts. This material was strongly PAS-positive at the margins. There was little or no evidence of calcium deposition in most of the osteoid tissue. When calcification was in evidence, it was denoted by a fine wavy blue line (H & E stain) throughout the islet of osteoid.

Biochemical Findings

Results of biochemical analyses of plasma samples from four of the osteodystrophic kits and one healthy control kit are presented (Table 1). All of the kits were hypocalcemic (mean of 8.3 mg/100 ml) with marked hyperphosphatemia (mean of 7.4 mg/100 ml). These values resulted in a mean Ca:P ratio of 1.14:1 for the osteodystrophic kits as compared to a ratio of 2.40:1 for the control kit.

The mean plasma level of urea nitrogen (24.7 mg/100 ml) was in excess of the value determined for the control kit. Only one of the kits had a plasma urea nitrogen level less than that of the control kit (Table 1; kit 1). The mean total plasma protein content of 4.6 gm/100 ml was markedly reduced in comparison to the total protein content in plasma from the control kit.

Mean activity values for alkaline phosphatase (107.8 mU/ml), lactic dehydrogenase (355.5 mU/ml), and glutamic oxaloacetic transaminase (896.8 mU/ml) for the four osteodystrophic kits were markedly elevated in comparison to these values determined for the control kit.

Response to Treatment

Surviving kits that were maintained in holding pens and fed a commercial dog ration supplemented with an artificial bitch's milk recovered and had no signs of nutritional secondary hyperparathyroidism.

DISCUSSION

The most important cause of nutritional secondary hyperparathyroidism is excessive dietary phosphorus.⁶ Regardless of its cause, hyperparathyroidism causes a rapid osteoclasts and over-

TABLE 1. Biochemical Findings in Plasma from Alaskan Red Fox Kits.

Fox No.	Calcium (mg/100 ml)	Phosphorus (mg/100 ml)	Urea nitrogen (mg/100 ml)	Total protein (gm/100 ml)	Alkaline phosphatase activity (mU/ml)	Lactic dehydrogenase activity (mU/ml)	Glutamic oxaloacetic transaminase activity (mU/ml)
1	8.3	6.1	18.1	4.5	124	487	1,120
2	8.0	7.0	30.4	4.7	121	217	1,197
3	8.6	8.4	26.3	4.6	84	456	705
4	8.4	8.1	24.0	4.7	102	262	565
Mean	8.3	7.4	24.7	4.6	107.8	355.5	896.8
Control Fox	10.1	4.2	19.3	7.1	38	55	52

growth of loose fibrous connective tissue in the bones.⁴ The disease can also occur when calcium and vitamin D are deficient, and the Ca:P ratio is greater than 1:7. In captive carnivores, it is necessary to supplement meat diets with calcium since meat has a Ca:P ratio of about 1:20 or greater. If the diet is deficient in vitamin D, rickets may occur concomitantly with fibrous osteodystrophy.⁴ Correction of the vitamin deficiency repairs the rachitic changes; however, it exacerbates osteoporosis and osteodystrophy, apparently because vitamin D is essential to the action of parathyroid hormone. The addition of iodine to the diet has proven to be of value in correcting the calcium imbalance, while at the same time it retards the dystrophic changes.

Rickets and fibrous osteodystrophy were reported in farm-raised silver foxes fed a diet (wet basis) that consisted of 75% horsemeat, 10% horse tripe, lungs, livers and 15% commercial mink cereal.³ Horsemeat and cereal grains had resulted in an unfavorably low calcium to phosphorous ratio. Clinical signs of retarded growth and skeletal deformities were observed at about 6 months of age. Lack of vitamin D either due to lack of sunlight or ration supplementation was considered an additional osteodystrophic factor in these kits. Rickets complicated by spontaneous fractures of the long bones of the hindlimbs occurred in a captive coyote (*Canis latrans inocularis*) at 1 month of age.² The pup had been fed a diet that consisted mainly of meat and creamed rice. Recovery occurred

when steamed bone meal and vitamin D were added to the diet.

Remains of kills found around den sites of the kits studied in this report consisted mainly of snowshoe hare (*Lepus americanus*). Examination of the remains of such kills indicated that mainly skeletal muscle had been consumed with almost no evidence that bone had been ingested. The easy availability of snowshoe hares at a time when their population was at a high level undoubtedly accounted for the predominance of snowshoe hares in the diet of both adult and young red foxes. In Sweden, field observations indicate that young weaned kits are fed by their parents, a factor that accounts for the high frequency of hares in the diet.² Rodents are included in the diet with increasing frequency as the kits mature. Remains of rodents were not observed at den sites of red foxes in the Fairbanks, Alaska area; however, this was not surprising since if rodents are caught by foxes, they are generally consumed *in toto*.

It appeared from observations made on the eating habits of Alaskan red fox kits that insufficient calcium and excess phosphorous in the diet was the osteodystrophic factor in the development of nutritional secondary hyperparathyroidism observed in the 16 captive kits.

In view of the long hours of sunlight at that time of year in interior Alaska, inadequate vitamin D was not considered as a complicating factor in the development of nutritional secondary hyperparathyroidism and the resultant fibrous osteodystrophy.

LITERATURE CITED

1. DIETERICH, R. A. and R. W. VAN PELT. 1972. Juvenile osteomalacia in a coyote. *J. Wildl. Dis.* 8: 146-148.
2. ENGLUND, J. 1970. *Population Dynamics of the Swedish Red Fox, *Vulpes vulpes* (L.)*. Almquist & Wiksells Boktryckeri AB, Uppsala, Sweden. pp. 3-4.
3. GORHAM, J. R., J. C. PECKHAM and J. ALEXANDER. 1970. Rickets and osteodysplasia fibrosa in foxes fed a high horsemeat ration. *J. Am. vet. med. Ass.* 156: 1331-1333.
4. JUBB, K. V. F. and P. C. KENNEDY. 1970. *Pathology of Domestic Animals*. 2nd edition, Vol. 1, Academic Press, Inc., New York, N.Y. pp. 35-38.

5. LUNA, L. G. 1968. *Manual of Histologic Staining Methods of the Armed Forces Institute of Pathology*. 3rd edition, McGraw-Hill Book Co., New York, N.Y.
6. MILLER, R. M. 1969. Nutritional secondary hyperparathyroidism. *Vet. Med./ Small Anim. Clin.* 64: 400-408.
7. SMITH, H. A., T. C. JONES and R. D. HUNT. 1972. *Veterinary Pathology*. 4th edition, Lea & Febiger, Philadelphia, Pa. pp. 1064-1066.

Received for publication 28 February 1973
