

## TOXOPLASMOSIS IN DASYURID MARSUPIALS

H. D. ATTWOOD, P. A. WOOLLEY and M. D. RICKARD, Department of Pathology, University of Melbourne, Department of Zoology, La Trobe University, School of Veterinary Science, University of Melbourne, Melbourne, Australia

**Abstract:** During a histopathologic survey of 240 dasyurid marsupials a high prevalence of infection of *Toxoplasma gondii* was found in eight of the nine species examined. Amongst the infected species, endemic infection in field animals was proved in *Dasyuroides byrnei*, but there was also good evidence of laboratory infection probably derived from raw sheep tissues in their diet. Infection was never demonstrated in animals less than six months of age. The 21 *Antechinus stuartii* examined remained free from infection despite a lengthy stay in the laboratory and a similar diet. This freedom from infection may indicate a particular resistance to *Toxoplasma* infection by this species.

### INTRODUCTION

Toxoplasmosis is a common infection in man, domestic and free-living animals. The prevalence of infection varies considerably among different species and this variation has been related, amongst other things, to modes of feeding and climatic conditions.<sup>5,7,9,18,24</sup> We have found histologic toxoplasmosis to be prevalent in a group of dasyurid marsupials whose reproductive biology is being studied at La Trobe University. The dasyurids are a group of flesh- and insect-eating marsupials widely distributed throughout Australia. Five of the nine species examined are found only in the more arid regions.

An early analysis of the present topic has been presented at a meeting of The Royal College of Pathologists and published in abstract form.<sup>1</sup>

### ANIMALS AND METHODS

#### Animals

All animals found dead or killed are submitted to a routine macroscopic and microscopic examination. The species examined include *Antechinomys spenceri*, *Antechinus apicalis*, *Antechinus macdonnellensis*, *Antechinus stuartii*, *Dasyercus*

*cristicauda*, *Dasyuroides byrnei*, *Sminthopsis crassicaudata*, *Sminthopsis larpinta* and *Sminthopsis leucopus*. The majority of animals examined have been either laboratory-reared or wild-caught specimens maintained in the laboratory for varying periods, but 17 *D. byrnei*, 3 *A. stuartii* and 7 *S. leucopus* were killed immediately after capture in the field. In the laboratory, animals were fed on a diet of raw meat, including sheep's heart, liver and brain, and insects.<sup>20</sup> The number of each species examined is shown in Table 1.

#### Histologic Examination

Tissues for histologic study were generally taken from the heart, both lungs, at least one kidney and adrenal, stomach, gut, spleen, pancreas and parapancreatic node. The eyes of 3 *D. byrnei* were examined histologically. Tissue blocks were fixed in formol-acetic alcohol for at least 24 h and processed to paraffin wax. The head was opened and immersed in fixative for at least 24 h before removal of the brain. In 109 animals the greater part of the vertebral column with attached musculature was fixed as a block, decalcified in 5% trichloroacetic acid or a formic acid-sodium citrate mixture and then cut transversely into multiple blocks for histological study of the spinal cord.

In 3 *D. byrnei* multiple blocks taken from the cervical, dorsal and lumbosacral segments of the cord were cut serially and in two of these animals, the head, following decalcification, was cut into several blocks which were also cut serially.<sup>8</sup>

Paraffin sections were stained routinely with hematoxylin and eosin. The following additional methods were used on occasions: periodic-acid-Schiff, Giemsa, Gordon and Sweet's method for reticulin and Alcian blue-Van Gieson.

#### Serologic Examination

Sera from 9 *D. byrnei* and 5 *D. cristicauda* were examined for complement-fixing antibodies to *Toxoplasma gondii* and the same sera were later tested using a modification of the Sabin-Feldman dye test.<sup>21,22</sup>

#### Mouse Passage

An adult female *D. byrnei* was killed and blood was collected from the posterior vena cava. The brain was removed,

divided sagittally, and one half fixed in 10% neutral formalin for histologic examination. The other half was homogenised in normal saline and the homogenate used for the first mouse passage.

Three pairs of *Toxoplasma*-free mice were bled from the orbital sinus 2 days before passage. Pairs were inoculated with 0.2 ml of brain homogenate either orally, subcutaneously or intraperitoneally. Thirty-five days later blood samples were taken and the animals killed by decapitation. The brain from each mouse was divided sagittally and half fixed in 10% neutral formalin. The other portions were pooled and homogenised for use in a second passage.

Three more pairs of mice, previously bled, were inoculated as before with the second homogenate and 35 days later were bled, killed and their brains fixed for histologic examination. Paraffin sections from all the fixed brains were stained with haematoxylin and eosin.

All samples of sera were stored at -20 C until submitted to the Sabin-Feldman dye testing.

TABLE 1. Prevalence of *Toxoplasma* Infection in Various Species of Dasyurid Marsupials Obtained from the Field, or Maintained or Reared in the Laboratory.

	Field	Maintained	Reared	%
<i>Antechinomys spenceri</i>		9/12		75
<i>Antechinus apicalis</i>		2/3	3/6	56
<i>Antechinus macdonnellensis</i>		5/9	4/5	64
<i>Antechinus stuartii</i>	0/3	0/16	0/2	0
<i>Dasyercus cristicauda</i>		21/32	13/19 <sup>①</sup>	67
<i>Dasyuroides byrnei</i>	4/17	25/25	23/65 <sup>②</sup>	49
<i>Sminthopsis crassicauda</i>		2/2	2/5 <sup>③</sup>	57
<i>Sminthopsis larapinta</i>		1/2		50
<i>Sminthopsis leucopus</i>	0/7	8/10		47
Total	4/27	73/111	45/102	51

① Includes 5 pouch young from 2 litters.

② Includes 36 pouch young from 7 litters.

③ Includes 3 pouch young from 1 litter.

## RESULTS

### Toxoplasma Cysts

The identification of a protozoal cyst (Fig. 1) in one or more tissues was the only criterion of infection. Using this criterion 51% of all the dasyurids examined were infected, but the prevalence of infection varied greatly among species (Table 1). As inflammation or granulomata without associated cysts were not by themselves accepted, these prevalences must be minimal.

The characteristic tissue cyst was generally round, with a capsule demonstrable by silver impregnation and a diameter which varied between 50 and 120  $\mu\text{m}$ . The cyst was never divided by septa although a double infection of a single cell or infection of adjacent cells might very occasionally produce an apparent septation. On staining with the periodic-acid-Schiff technique the fuchsinophilia

of the cytoplasm of individual organisms brilliantly highlights the cysts (Fig. 2) and facilitates identification of individual organisms. The organisms in the cysts stained well with Giemsa and were consistently Gram negative, unlike the uniform blue staining shown by *Nosema cuniculi*.<sup>1,27</sup>

Free organisms in the paraffin sections were crescentic or cigar-shaped and 3  $\mu\text{m}$  long by 1  $\mu\text{m}$  wide.

Cysts were never recognised in any animals less than 6 months of age.

### Serologic Examination

The serologic findings are given in Table 2 together with the relevant histologic findings. In general there was a close relationship between high serologic titres and histologic evidence of an inflammatory reaction to *Toxoplasma*.

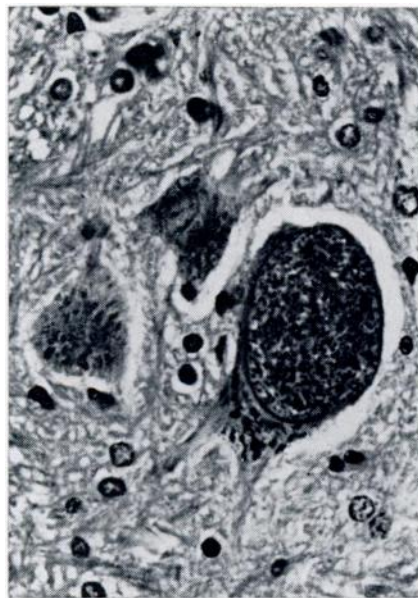


FIGURE 1. *Toxoplasma* cyst occupying the greater part of an anterior horn cell. H. & E. X 450.

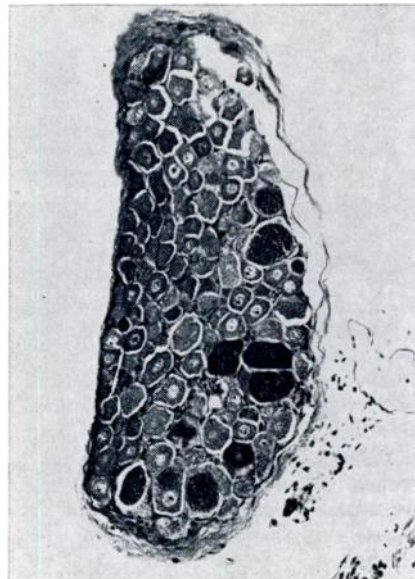


FIGURE 2. Dorsal root ganglion with many ganglion cells parasitised by fuchsinophil *Toxoplasma* cysts. P.A.S. X 80.

**Biologic Examination**

The brain, spinal cord, voluntary muscle and lung from the single *D. byrnei* used for the mouse passage experiment contained cysts similar to those seen in other animals in the series and the serum gave a positive dye test. Mice used for passage experiments gave uniformly negative dye test titres before passage and gave titres greater than 1:16 before they were killed. Histologic examination of brains from mice showed cysts similar to those from dasyurids.

**Signs of Infection**

Despite the presence of numerous cysts and often widespread evidence of an inflammatory response in several organs

the majority of animals showed no outward evidence of infection.

Three *D. byrnei* and 1 *S. leucopus* showed clouding of the cornea or lens of one or both eyes. The eyes of the 3 *D. byrnei* examined showed a destructive retinochoroiditis quite consistent with *Toxoplasma* infection. In one there was also a chronic iridocyclitis with a secondary cortical cataract.

Of the 240 animals examined, 13 (7 *D. byrnei*, 5 *D. cristicauda* and 1 *A. apicalis*) had difficulty in walking and dragged one or both hind limbs. The spinal cord from all these animals showed histologic evidence of a meningo-myelitis with *Toxoplasma* cysts often replacing anterior horn cells (Fig. 1). An additional 36 animals (7 *D. cristicauda*, 27

TABLE 2. Serologic and Histologic Findings.

Animal		Dye Test Titres	Histologic Findings*
<i>Dasyuroides byrnei</i> :			
Female	61	1024	Meningitis. Focal myocarditis.
	83	256	No cysts. Focal calcification myocardium.
	9	64	Cerebral cyst only.
	20	64	Granulomatous encephalitis and myocarditis.
Male	135	512	Cerebral meningitis: granulomatous myelitis.
	19	256	No cysts. Cerebrovascular cuffing.
	18	16	No cysts.
	76	4	Cerebellar granuloma.
	78	Not done	Granulomatous meningomyelitis.
<i>Dasyercus cristicauda</i> :			
Female	69	256	Focal myelitis and myocarditis.
Male	27	8192	Encephalomyelitis. Focal myocarditis.
	66	4096	Granulomatous encephalitis and myocarditis.
	73	1024	Granulomatous encephalitis and myocarditis.
	69	256	Focal myelitis and myocarditis.

\* Cysts identified in all specimens unless otherwise stated. All sera were negative to the complement fixation test.

*D. byrnei* and 2 *S. leucopus*) had histologic evidence of meningo-myelitis without apparent weakness of the hind limbs.

Microscopically, streak-like calcification of the heart was obvious in 4 *D. byrnei* all of which had myocardial toxoplasmosis.

#### Histopathologic Sites of Infection

Amongst the eight infected species the total prevalence of infection was 56%; brain (42%) and spinal cord (53%) were most frequently involved. The heart (38%) and lungs (18%) were also commonly involved, but liver (4%), pancreas (3%) and spleen (1%) were unusual sites for cysts. The kidney was never the site of cysts although one cyst was seen in the musculature of a ureter in the region of the pelvi-ureteric junction in a *S. crassicaudata*.

Other sites of infection were strap muscle on the neck, pericranial and paravertebral muscles, muscle coats of the stomach, oesophagus and urinary bladder. In the pericranial and paravertebral muscles there were associated inflammatory changes, but in the other areas cysts were isolated and without associated reactive changes.

In the brain, cysts were seen in all lobes of the cerebrum, the cerebellum and brain stem. Although local conglomerates were found in individual animals there was no preferential site. Cysts were seen in a trigeminal ganglion of a *D. byrnei* which also had a cyst in the choroid plexus of a lateral ventricle.

Cysts were widely distributed in both grey and white matter of the spinal cord, but most frequently involved the large anterior horn cells (Fig. 1). In 3 *D. byrnei* a serial section study of the root areas from cervical, dorsal and lumbar blocks was made. Roots were certainly involved occasionally, but the surprising finding was the very heavy infection of the spinal ganglia (Fig. 2) with not only multiple cysts in each ganglion but, on occasion, two cysts in a single ganglion cell. In one of these animals the dorsal

root ganglia were the only site of infection of the cord; no cysts were seen in the other 2248 sections of the cord.

Although cysts, without an associated reaction, were the only evidence of infection of the central nervous system in a few animals, in the majority a meningitis or perivascular cuffing with lymphocytes was also present. Animals most severely affected showed a severe meningo-encephalomyelitis with a radiculitis and ganglionitis. In such animals there were scattered granulomata mainly consisting of spherical aggregates of mononuclear cells including plasma cells. However, multiple cysts could be present without any granulomata.

Infection of the myocardium was most frequently seen as isolated cysts without reaction in the substance of the left ventricle. On occasion, an interstitial myocarditis with involvement of the epicardium in the region of the atria was seen. Calcification of necrotic fibres or cysts was an infrequent finding. In 2 *S. leucopus* and 1 *S. crassicaudata* partly organised thrombi lined much of the endocardium of the left atrium of hearts showing a focal necrotising pancarditis.

Infection of the lung was most frequently seen as a cyst bulging from the wall of an alveolus. No characteristic type of pneumonia was identified with the cysts although isolated organisms were seen in otherwise typical examples of "chronic murine pneumonitis".<sup>15</sup>

Cysts or isolated organisms were occasionally seen within Kupffer cells in the liver. Many organisms were seen in the liver of 2 *A. macdonnellensis* which died with leukaemia.<sup>3</sup>

In 78 adrenals examined 21 (27%) were infected. In 6 animals (1 *A. apicalis*, 1 *S. crassicaudata* and 4 *S. leucopus*) this was associated with a necrotising inflammation and considerable destruction of the gland.

As *Toxoplasma* cysts were identified in 4 of the 17 *D. byrnei* killed immediately after capture the infection is not merely of laboratory origin.

## DISCUSSION

The infection of dasyurid marsupials now reported has been proved morphologically, serologically and by animal transfer to be due to *T. gondii*. The negative results of the complement-fixation tests remain unexplained. Cook and Pope<sup>5</sup> have reported positive complement-fixation tests in a number of marsupials, including grey and red kangaroos, brush-tailed and ring-tailed possums and both short-nosed and long-nosed bandicoots.

*Toxoplasma* previously has been recognised in the following dasyurids—*Phascogale tapoatafa* by Cook and Pope<sup>5</sup> and in *Antechinus swainsoni* and *A. minimus* by Munday<sup>24</sup> who also gives an excellent review of serologic and histologic investigations into a range of marsupials. The present report is the first histopathologic survey of dasyurids in which the living animals also have been studied and correlations thereby made. The prevalence of infection, although high, is not dissimilar to that reported by previous investigators of toxoplasmosis. The isolation rate might have been increased if the pepsin hydrochloric acid digestion of the diaphragm method had been used as described by Jacobs *et al.*<sup>18</sup> and advocated by Munday.<sup>24</sup> The diaphragm, in fact, was rarely examined during this survey; likely this deficiency was offset by the multiplicity of tissues examined from each animal.

The distribution of cysts in the organs is similar to that described in many other surveys in that brain, spinal cord, heart and lungs were most frequently involved. Renal infection, absent from this series and generally thought to be rare with *Toxoplasma*,<sup>8,20</sup> has been reported in swine<sup>12,20</sup> and in the Rottneest quokka, *Setonix brachyurus*.<sup>11</sup>

Weakness in the hind limbs seen in our animals was at first thought to be due to vitamin E deficiency, which is known to cause this symptom in the Rottneest quokka.<sup>17</sup> However, the skeletal muscles showed a denervation atrophy rather than a dystrophy and this appearance led to

the examination of the spinal cords. Histologic evidence of a meningo-myelitis frequently associated with an anterior poliomyelitis and posterior root ganglionitis are adequate reasons for the denervation atrophy and limb weakness. Involvement of the spinal cord is infrequently mentioned in the literature probably because of the technical difficulties in examining the spinal cord from small animals.

The prevalence of infection with *Toxoplasma* seems to vary with age and varying resistance in the host.<sup>7,9</sup> Serologically, in man and swine, the frequency of *Toxoplasma* antibodies increases with age.<sup>10,21</sup> Intra-uterine transmission of *Toxoplasma* is well documented in man,<sup>6</sup> occurs frequently in sheep, but rarely in cattle even if grazing the same pasture.<sup>14,24</sup> Intra-uterine transfer does not appear to occur in dasyurids. In our series, 44 pouch young (36 *D. byrnei*, 5 *D. cristicauda* and 3 *S. crassicaudata* ranging from 1-81 days of age) were examined and none showed any histologic evidence of toxoplasmosis, although cysts are said to form as early as 5-7 days after infection.<sup>19</sup> Eight of the 9 mothers had *Toxoplasma* cysts. *S. crassicaudata* are dependent on their mothers for ten weeks: *D. byrnei* and *D. cristicauda* are dependent on their mothers for up to 4 months.<sup>20</sup> When the numbers of pouch young are removed from the data given in Table 1 the prevalence of infection in adult animals is greatly increased (*D. byrnei*: 52/71 (73%); *D. cristicauda*: 34/46 (74%); *S. crassicaudata*: 4/4 (100%) ).

An alteration in the resistance of the host seems to influence the incidence of toxoplasmosis. In man, toxoplasmosis has been associated with immunosuppression after renal transplantation<sup>27</sup> and has been superimposed on neoplastic conditions, such as Hodgkin's disease of lymph nodes.<sup>28</sup> In the dog, there is a known association between canine distemper and toxoplasmosis.<sup>4,18,19</sup> In our infected dasyurids the widest dissemination of free organisms was seen in 2 *A. macdonnellensis* with lukaemia.<sup>2</sup>

The failure to find cysts in *A. stuartii* is unexplained. Eighteen of these animals had been kept in the laboratory from 1 to 19 months and fed the same diet as the other species. Their ages ranged from 3 months to approximately 2 years. The histologic survey was as extensive as in any other group, but no serologic studies were conducted. One laboratory-reared male did show a transient stiffness of the hind limbs, but the brain and spinal cord of this animal showed no evidence of inflammation or of *Toxoplasma* cysts. The only abnormality found in this animal was a viral prostatitis. Factors in individual susceptibility and host resistance have been very well reviewed.<sup>28</sup>

There is also good evidence that the prevalence of toxoplasmosis varies with climatic conditions and that a cold moist climate is associated with a high prevalence of serologic reactors in animal populations.<sup>24</sup> Cook and Pope could find no evidence of infection in the 239 animals they tested from areas with an annual rainfall less than 62.5 cm and suggested that *Toxoplasma* was relatively uncommon west of the Dividing Range in Australia. Of the animals we examined, *A. stuartii*, *A. apicalis* and *S. leucopus* are found in areas where the average annual rainfall is 55 cm or more, while the remaining species, with the exception of *S. crassicaudata*, are all confined to the more arid regions of Australia, where the average rainfall is less than 25 cm. *S. crassicaudata* is found in both high and low rainfall areas, but the animals examined were from arid zone stock. The 17 *D. byrnei* killed on

capture were trapped on Sandringham Station, Queensland, in an arid region west of the Dividing Range. *Toxoplasma* cysts were found in four of these animals, a prevalence lower than in our laboratory series. This lower prevalence could be related to their younger ages as five of the animals trapped were less than 1 year old. The incidence of infection with *T. gondii* may be less in arid regions, but there can be no doubt that toxoplasmosis still occurs in native animals from such areas.

Although endemic infection in field animals has been proved in *D. byrnei*, the absence of infection in other field animals and the high prevalence of infection in nearly all species maintained and reared in the laboratory strongly suggests that infection within the laboratory occurs. Their diet included raw sheep's heart and brain, a likely source for laboratory infection. Histologic sampling of 13 sheep's heart showed a myocarditis in all, *Sarcocystis* in 11, but no *Toxoplasma* cysts. Five sheep's brain showed neither cysts nor inflammation. However, as 24% of Victorian sheep give positive dye tests and cysts can be isolated from 25% of Tasmanian sheep's diaphragms<sup>28</sup> it would seem highly unlikely that any animal maintained on our laboratory diet for any length of time could escape being fed *Toxoplasma* tissue cysts.

The absence of toxoplasmosis in *A. stuartii* maintained on the same diet in the laboratory for up to 19 months is all the more puzzling. This species appears to be resistant to infection by *T. gondii*.

#### Acknowledgements

Professor W. M. Hutchison, University of Strathclyde, was kind enough to start the mice transfer experiment during his visit to Australia in 1973 as a British Council Travelling Fellow.

We are grateful to Dr. John White, Serologist, Fairfield Infectious Diseases Hospital and Dr. W. J. Hartley, Department of Veterinary Medicine, The University of Sydney, for serological studies and to Dr. C. H. Greer, Pathologist, Royal Victorian Eye and Ear Hospital, East Melbourne, for examining the eyes.

Grateful thanks are given to Mrs. Helen Makin and her technological staff in the Pathology Department, Austin Hospital, and to Mr. R. Hill and his staff in the Department of Experimental Pathology, The John Curtin School of Medical Research, Canberra, for the very great deal of histological preparations necessary.

The *Toxoplasma*-free mice were obtained from Fairfield Infectious Diseases Hospital.

## LITERATURE CITED

1. ATTWOOD, H. D. and P. A. WOOLLEY. 1970. Toxoplasmosis in dasyurid marsupials. *Pathology*, 2: 77-78.
2. ——— and ———. 1973. Malignant neoplasms in dasyurid marsupials. *J. Comp. Path.* 83: 569-581.
3. ——— and ———. 1974. Arachnoid villi in the spinal cord of dasyurid marsupials. *J. Comp. Neur.* 155: 343-354.
4. CAMPBELL, R. S. F., W. B. MARTIN and E. D. GORDON. 1955. Toxoplasmosis as a complication of canine distemper. *Vet. Rec.* 67: 708-715.
5. COOK, I. and J. H. POPE. 1959. *Toxoplasma* in Queensland: A preliminary survey of animal hosts. *Aust. J. exp. Biol. med. Sci.* 37: 253-262.
6. COWEN, D., A. WOLF and H. PAIGE. 1939. Toxoplasmic encephalomyelitis. *Amer. J. Path.* 15: 657-694.
7. FRENKEL, J. K. 1953. Host, strain and treatment variations as factors in the pathogenesis of toxoplasmosis. *Amer. J. trop. Med.* 2: 390-415.
8. ———. 1956. Pathogenesis of toxoplasmosis and of infections with organisms resembling *Toxoplasma*. *Ann. N.Y. Acad. Sci.* 64: 215-231.
9. ———. 1970. Pursuing *Toxoplasma*. *J. infect. Dis.* 122: 553-559.
10. GARVEN, ALISON. 1957. Toxoplasmosis: The diagnosis of clinical and latent infection in Australia. *Aust. Ann. Med.* 6: 141-144.
11. GIBB, D. G. A., B. A. KAKULAS, D. H. PERRET and D. J. JENKYN. 1966. Toxoplasmosis in the Rottneest Quokka (*Setonix brachyurus*). *Aust. J. exp. Biol. med. Sci.* 44: 665-671.
12. HARDING, J. D. J., J. K. A. BEVERLEY, I. G. SHAW, B. L. EDWARDS and G. H. BENNETT. 1961. *Toxoplasma* in English pigs. *Vet. Rec.* 73: 3-6.
13. HARTLEY, W. J. 1956. Some observations on canine toxoplasmosis. *N.Z. vet. J.* 4: 115-118.
14. ———. 1964. Toxoplasmosis in sheep with particular reference to perinatal mortality and epidemiology. Thesis, University of Sydney.
15. INNES, J. R. M., A. J. McADAMS and P. YEVICH. 1956. Pulmonary disease in rats. *Amer. J. Path.* 32: 141-159.
16. JACOBS, L., J. S. REMINGTON and M. L. MELTON. 1960. A survey of meat samples from swine, cattle and sheep for the presence of encysted *Toxoplasma*. *J. Parasit.* 46: 23-28.
17. KAKULAS, B. A. 1961. Myopathy affecting the Rottneest Quokka (*Setonix brachyurus*) reversed by  $\alpha$  tocopherol. *Nature*, 191: 402-403.
18. KOZAR, Z. 1970. Toxoplasmosis and Coccidiosis in Mammalian Hosts. In *Immunity to Parasitic Animals*, G. T. Jackson, R. Herman and I. Singer, Appleton-Century-Crofts, Vol. 2: 871.
19. MØLLER, T. and S. W. NIELSEN. 1964. Toxoplasmosis in Distemper-susceptible carnivora. *Path. Vet.* 1: 189-203.
20. MOMBERG-JØRGENSEN, H. C. 1956. Toxoplasmosen hos svinet. *Nord. vet-med.* 8: 227-238.
21. MOYLE, G. G. 1965. Toxoplasmosis Part 2. *Aust. J. Med. Tech.* 7: 154-167.
22. ———. 1967. The effect of incubation temperature on *Toxoplasma* dye test titres. *Aust. J. exp. Biol. med. Sci.* 45: 571-573.



23. MUNDAY, B. L. 1966. Diseases of Tasmania's Free-Living Animals, 29 in Research Bulletin No. 5, Tasmanian Department of Agriculture, Government Printer, Hobart, Tasmania.
24. ———. 1970. The Epidemiology of Toxoplasmosis with particular reference to the Tasmanian Environment. M.V.Sc. Thesis, University of Melbourne. Monograph, Tasmanian Department of Agriculture, Launceston, Tasmania.
25. NICOLLE, C. and MANCEAUX, L. 1908. Sur une infection à corps de Leishman (ou organisme voisins) du gondi. C. R. Acad. Sci. (Paris). 147: 763-766.
26. PERRIN, T. L. 1943. *Toxoplasma* and *Encephalitozoon* in spontaneous and in experimental infections in animals. Arch. Path. 36: 568-578.
27. REYNOLDS, E. S., K. W. WALLS and R. I. PFEIFFER. 1966. Generalised toxoplasmosis following renal transplantation. Arch. intern. Med. 118: 401-405.
28. SYMMERS, W. St. C. 1965. Opportunistic Infections. Proc. R. Soc. Med. 58: 341-346.
29. WOOLLEY, P. 1971. Maintenance and breeding of laboratory colonies of *Dasyuroides byrnei* and *Dasyercus cristicauda*. In *International Zoological Year Book*, Vol. II: 351.
30. ———. 1973. Breeding Patterns and the Breeding and Laboratory Maintenance of Dasyurid Marsupials. Experimental Animals, Supplement: "Proc. of the I.C.L.A. Asian Pacific Meeting of Laboratory Animals, September 20-25, 1971, Tokyo and Inuyama". 22: 161.
31. WORK, K. 1971. Toxoplasmosis with special reference to transmission and life cycle of *Toxoplasma gondii*. Munksgaard. Copenhagen.

Received for publication 3 March 1975

---