

## LESIONS ASSOCIATED WITH *Orthohalarachne attenuata* (Halarachnidae) IN THE NORTHERN FUR SEAL (*Callorhinus ursinus*)

J. S. DUNLAP and R. C. PIPER<sup>1</sup>, Department of Veterinary Pathology, College of Veterinary Medicine, Washington State University, Pullman, WA 99163, USA.

MARK C. KEYES, Marine Mammal Division, Northwest Fisheries Center, National Marine Fisheries Service, Seattle, WA 98115, USA

**Abstract:** In northern fur seals (*Callorhinus ursinus*) up to at least 4 years of age there is virtually 100% prevalence of infestation with the nasal mite *Orthohalarachne attenuata*. Although clinical observations and gross examination indicate that the condition is not serious, some erosion and inflammation of the nasal turbinates and nasopharynx were seen associated with mites in histological sections.

### INTRODUCTION

The Halarachnidae are parasitic mites in the respiratory tract of various mammals. Lesions associated with members of the genus *Pneumonyssus* have been reported in the upper respiratory tract of dogs and in the bronchi of monkeys.<sup>1,4,5</sup> The morphology and systematics of two other genera, *Halarachne* and *Orthohalarachne*, parasitizing pinnipeds have been described.<sup>3,5,6</sup> However, lesions associated with these mites have not been described previously, although they have been associated with disability in a captive sea otter.<sup>2</sup> Lesions in northern fur seals infected with *O. attenuata* are reported here.

### MATERIALS AND METHODS

Heads or nasal turbinates were collected, during annual harvest of surplus males on the Pribilof Islands, from 200 subadult male northern fur seals, 3 to 4 years of age. Heads from eight male northern fur seals were fixed in 10% buffered formalin and transported to Washington State University for examination.

In addition, two fur seal pups, less than 6 months of age, under study at Pullman, Washington were also available for study. The skulls were sawn sagittally, the turbinates were removed, and the specimens were examined for the presence of mites. The location of mites and the associated gross lesions were recorded for each fur seal. Representative tissues from areas containing mites were embedded in paraffin, sectioned at 4 to 10  $\mu$ m and stained with Harris hematoxylin, phloxine and eosin, or Giesma stain. Serial sections were made at sites of mite attachment in the nasal turbinates and in the nasopharyngeal mucosa.

### RESULTS

Examination of nasal turbinates and nasopharyngeal mucosa of 200 subadult male northern fur seals on the Pribilof Islands revealed virtually 100% prevalence of mite infestation.

All eight specimens examined in this laboratory contained mites. The larval stage was found on the turbinate mucosa; the adults were found attached to the

<sup>1</sup> Present address—Pathology and Toxicology Research, The Upjohn Company, Kalamazoo, Michigan, USA.

nasopharyngeal mucosa. There has been no report of an octopod nymphal stage with this mite, and no nymphal forms were found. Examination of the entire turbinate area of one seal head resulted in the recovery of 670 hexapod larvae. The greatest number of adult mites recovered from a single animal was 65, and all but three of these were in the nasopharyngeal area. Although adults were attached to the mucous membranes there was very little gross evidence of an inflammatory response. Clinical signs of respiratory difficulty were not observed in any of the eight animals, and there was no evidence of occlusion of the respiratory passages.

#### HISTOPATHOLOGY

##### Nasal turbinates

Variable degrees of mucosal erosion were seen adjacent to mites, with accumulations of cellular detritus and effusion of neutrophils in the eroded areas in some cases (Fig. 1). Inflammatory edema and a mild to moderate infiltration of neutrophils was often present in the subadjacent lamina propria. There was frequently squamous metaplasia of the epithelium around the periphery of eroded areas. Well-preserved or partially hemolyzed anisocytotic red blood cells were occasionally seen within the mites.

In noneroded areas adjacent to mites, the epithelium varied from normal to atrophic, disorganized, devoid of Goblet cells or slightly hyperplastic, and the mucosa appeared compressed in some instances.

##### Nasopharynx

At the point of attachment of legs and mouth parts, the mucosa was often compressed and eroded or ulcerated, with necrosis of the superficial lamina propria and effusion of inflammatory cells. (Fig. 2). There was a heavy local infiltrate of inflammatory cells, mainly lymphocytes with occasional histocytes and plasma cells, in the mucosa and submucosa. Occasional lymphoid follicles with germinal centres were observed.

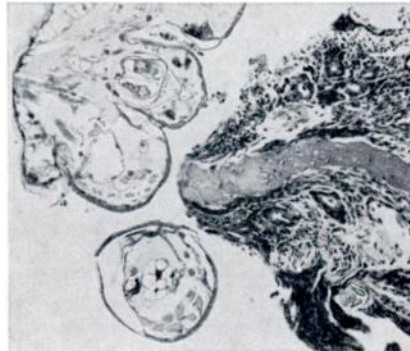


FIGURE 1. *Orthohalarachne*, hexapod larvae, section of turbinates, 350 X. Erosion of epithelium and lamina propria with moderate infiltration of neutrophils.

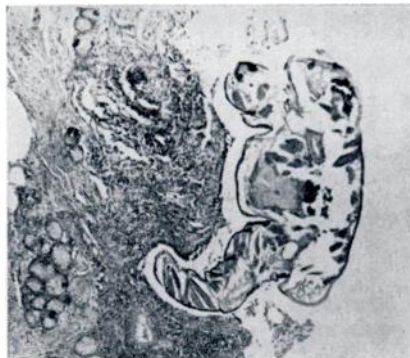


FIGURE 2. *Orthohalarachne*, adult, section of naso-pharynx, 140 X. Mucosa with erosion and ulceration of surface, necrotic cellular debris around leg.

#### DISCUSSION

Although larvae are prevalent in the turbinate and adults in the nasopharyngeal areas of northern fur seals, clinical and gross observations indicate that *O. attenuata* is usually of minor significance. The damage associated with mites seen in histologic sections suggest that impairment of respiration or predisposition to a more serious disease might ensue as a result of heavy infection or under stressful conditions.

## LITERATURE CITED

1. JAMES, M. T. and R. F. HARWOOD. 1969. *Herm's Medical Entomology*. 6th ed. McMillan Co., New York, pp. 364-365.
2. KENYON, K. W., C. E. YUNKER and I. M. NEWELL. 1965. Nasal mites (Halarachnidae) in the sea otter. *J. Parasit.* 51: 960.
3. NEWELL, I. M. 1947. Studies on the morphology and systematics of the family Halarchnidae Oudemans 1906 (Acari, Parasitoidea). *Bull. Bingham Oceanogr. Coll.* 10: 235-266.
4. SMITH, H. A. and T. C. JONES. 1966. *Veterinary Pathology*. 3d ed. Lea and Febiger, Philadelphia, pp. 650-653.
5. SOULSBY, E. J. L. 1968. *Helminths, Arthropods and Protozoa of Domestic Animals (Monnig)*. 6th ed. Williams and Wilkins, Baltimore, pp. 464-465.
6. STRANDTMAGN, R. W. and G. W. WHARTON. 1958. *Manual of Mesostigmatid Mites, No. 4*. The Institute of Acarology, Univ. Maryland, College Park, pp. 147-156.

Received for publication 12 February 1975

---

---