

SOME OBSERVATIONS ON CHRONIC LEPTOSPIRAL CARRIER STATE IN GERBILS EXPERIMENTALLY INFECTED WITH *Leptospira grippotyphosa*¹

D. N. TRIPATHY and L. E. HANSON, College of Veterinary Medicine, University of Illinois, Urbana, Illinois 61801, USA

Abstract: Leptospiuria with persistent microscopic agglutinating antibody titers were maintained in gerbils that became carriers following experimental infection with *Leptospira grippotyphosa*, strain F 4397. Leptospire were isolated from kidneys of a gerbil which died 28 months after experimental inoculation.

INTRODUCTION

Wild rodents act as reservoirs for various serotypes of leptospire pathogenic to man and animals. Such animals shed leptospire in their urine without showing clinical signs of disease and their sera often lack measurable microscopic agglutinating (MA) antibody. The duration of carrier state in the wild rodent following leptospiral infection is difficult to determine in nature. During our studies on the pathogenicity of serotype *grippotyphosa*, strain F 4397, some gerbils (*Meriones unguiculatus*) became carriers, shedding leptospire in their urine without clinical signs of disease. Therefore, to determine the duration of the carrier state under experimental conditions carrier animals were maintained for an extended period of time.

MATERIALS AND METHODS

The serotype *grippotyphosa*, strain F 4397, was isolated from swine in 1965.² The culture had been maintained either by regular gerbil and hamster passages or by continuous subculture in the liquid bovine albumin polysorbate 80 medium.¹

Gerbils which became urinary shedders were 10 to 12 weeks old when inoculated. Each animal was inoculated intra-

peritoneally with 0.5 ml of 7-day-old liquid culture of *L. grippotyphosa* which, after isolation from gerbil kidney, had been maintained in liquid medium for 6 months with subculture every 15 days prior to inoculation. The naturally voided urine of inoculated animals was examined after 4 days under darkfield microscopy and 3 to 4 times a month until the animals died. Sera were tested for MA antibody at different times as given in Table 1. When the gerbils died, their kidney suspension was inoculated in both liquid and semisolid bovine albumin polysorbate 80 medium. One kidney from each animal was forced through a 2.5 ml sterile disposable syringe into 5 ml of liquid medium. When the tissue debris had settled, 0.1 ml of the supernatant fluid was inoculated into a liquid and semisolid medium tube. Inoculated tubes were incubated at 29 C and examined regularly at weekly intervals under darkfield. Long-term observations were made on a total of four gerbils which became chronic leptospiral carriers.

RESULTS

Urine collected directly on a clean slide and examined under darkfield showed large numbers of leptospire in the urine of all gerbils as early as 5 to

¹ Supported by University of Illinois Agricultural Experiment Station, Hatch Project 70-302.

TABLE 1. Chronic Leptospirosis and Persistent Microscopic Agglutinating Antibody Response in Gerbils Infected with *Leptospira grippityphosa*, Strain F 4397.

Animal No.	Post Inoculation Leptospirosis and Microscopic Agglutinating Antibody Titers at								Kidney	
	5 months	10 months	13 months	17 months	20 months	26 months	28 months	Remarks		
1	1:1000								Died after collection of blood	+
2	1:1000	1:1000	1:100,000	NT	NT				Died 20 months after inoculation	+
3	1:1000	NT	1:1000	1:1000	1:10,000	NT			Died 26 months after inoculation	+
4	1:1000	NT	1:1000	1:1000	1:10,000	NT	NT	NT	Died 28 months after inoculation	+

+ = Positive for leptospire.

— = Leptospirosis detected by darkfield microscopic examination.

NT = not tested.

7 days after inoculation. One gerbil which had been shedding leptospire continually in its urine died 5 months post-inoculation after collection of blood. The serum had a titer of 1:1000 and leptospire were isolated from the kidneys.

One of the chronic carriers whose serum had an MA titer of 1:1000 or higher at 5, 10 and 13 months after inoculation died 20 months after inoculation without showing clinical signs. Both kidneys were grossly enlarged, cystic in appearance and contained large amounts of urine. Leptospire were isolated from the kidneys. Histopathologic examination revealed interstitial nephritis characterized by mononuclear cellular infiltration, cystic

dilatation of the renal tubules, presence of hyaline tubular casts and degeneration of glomeruli (Fig. 1 and 2).

Two gerbils, both chronic leptospiral carriers, had MA titers of 1:1000 5 months after inoculation. Their sera tested at 13, 17 and 20 months after inoculation had titers of 1:1000 or higher. These gerbils died at 26 and 28 months after inoculation without clinical signs. Leptospire were isolated from the kidneys of both animals.

DISCUSSION

L. grippityphosa, strain F 4397, had been pathogenic for gerbils and hamsters during continuous passages while the same organism maintained continually in the liquid medium for 5 years appeared nonpathogenic.⁶ Van der Hoeden⁷ suggested that leptospirosis in gerbils is self-limiting in nature because these animals succumb soon after infection. Leptospiuria in skunks experimentally infected with serotype *L. pomona* was observed up to the end of observation period of 197 days.⁵ Leptospiuria in striped skunks naturally infected with *L. pomona* was detected for 321 days and with *L. tarasovi* (*L. hyos, hyos*) for 774 days by Roth.⁴ Frerichs² observed leptospiuria in mice inoculated with serotype *L. ballum* for two years after inoculation. A carrier state may occur in rats infected with *L. icterohemorrhagiae*, mice with serotype *L. saxkoebing* or *L. ballum* and voles with serotype *L. grippityphosa* for more than 1 year and sometime even for the remainder of their lives.⁸ Present observations support these findings. Although no clinical signs of disease were shown by the animals in these observations it is believed that death was due to chronic leptospiral infection as observed by gross and histopathologic changes. Persistence of a prolonged carrier state as in the present observations are of epidemiological significance when susceptible man and animals are exposed to the environment contaminated by the urine from such carrier animals.

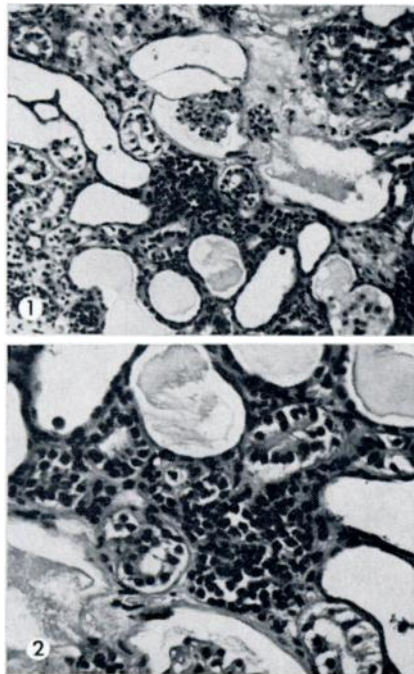


FIGURE 1. Chronic nephritis characterized by interstitial mononuclear cell infiltration, cystic tubular dilatation, tubular casts and glomerular atrophy. H & E stain x 200.

FIGURE 2. Chronic interstitial nephritis with mononuclear cell infiltration and cystic tubular dilatation. H & E stain x 400.

Acknowledgement

Technical assistance of Mrs. R. Marlowe and W. Manuel is highly appreciated.

LITERATURE CITED

1. ELLINGHAUSEN, H. C. Jr. and W. G. McCULLOUGH. 1965. Nutrition of *Leptospira pomona* and growth of 13 other serotypes: Fractionation of oleic albumin complex and a medium of bovine albumin and polysorbate 80. *Am. J. vet. Res.* 26: 45-51.
2. FRERICHS, W. M. 1966. Changes in Antigenic Structure of *Leptospira pomona* during chronic infection. Ph.D. Thesis. Washington State University, Pullman.
3. HANSON, L. E., H. A. REYNOLDS and L. B. EVANS. 1971. Leptospirosis in swine caused by serotype *grippotyphosa*. *Am. J. vet. Res.* 32: 885-860.
4. ROTH, E. E., W. V. ADAMS, G. E. SANFORD, M. MOORE, K. NEWMAN and B. GREER. 1963. Leptospiruria in striped skunks. *Pub. Hlth. Reports* 78: 994-1000.
5. TABEL, H. and L. KARSTAD. 1967. The renal carrier state of experimental *Leptospira pomona* infections in skunks (*Mephitis mephitis*). *Am. J. Epidemiol.* 85: 9-16.
6. TRIPATHY, D. N. and L. E. HANSON. 1974. Pathogenicity of *Leptospira grippotyphosa* for hamsters, gerbils and voles. *Am. J. vet. Res.* 35: 547-549.
7. VAN DER HOEDEN, J. 1954. The pathogenicity of leptospiras to field rodents in Israel (A new test animal for use in leptospira research). *J. Infect. Dis.* 95: 213-219.
8. VAN DER HOEDEN, J. 1964. Leptospirosis. In: *Zoonoses*. Ed. by J. Van der Hoeden. Elsevier Publishing Company, Amsterdam-London-New York.

Received for publication 7 April 1975