

RENAL CAPILLARIASIS IN THE SMALL INDIAN MONGOOSE, *Herpestes auro punctatus*¹

HARRY W. HUIZINGA, Department of Biological Sciences, Illinois State University,
Normal, Illinois 61761, USA

G. E. COSGROVE, Biology Division, Oak Ridge National Laboratory,²
Oak Ridge, Tennessee 37830, USA

ROBERT F. STURROCK,³ Wellcome Trust Research Laboratories, P.O. Box 43640,
Nairobi, Kenya, East Africa

Abstract: A *Capillaria* sp. was recovered from the kidneys of 28 (93.3%) of 30 small Indian mongooses (*Herpestes auro punctatus*) collected in St. Lucia, West Indies. The nematodes were embedded within distended pelvic fornices of the kidney and surrounded by accumulations of eggs. A chronic, low-level inflammation of the transitional epithelium was characterized by hyperplasia, giant cells surrounding embedded eggs and a plasmacytic infiltration. This is the first record of a capillarid nematode from the kidney of the mongoose.

INTRODUCTION

During a survey of wild animals for parasites in St. Lucia, West Indies in 1969, a *Capillaria* sp. was recovered from the renal pelvis of 28 (93.3%) of 30 small Indian mongooses (*Herpestes auro punctatus*).¹ The nematodes were deeply embedded in the pelvic fornices⁴ of both kidneys, but not observed in the cortex or medulla. Upon dissection of individual kidneys, a range of 2 to approximately 10 male and female nematodes was recovered, but exact worm counts were not made because the fragile worms were usually broken during removal. Adult worms were not recovered from the ureters or urinary bladder, but eggs (58 x 16 μ m) were present in the urinary bladder. Mongooses trapped in most available habitats on St. Lucia (banana plantations, grass fields, along streams, rain forest and near human dwellings) were infected. Gross lesions were not evident.

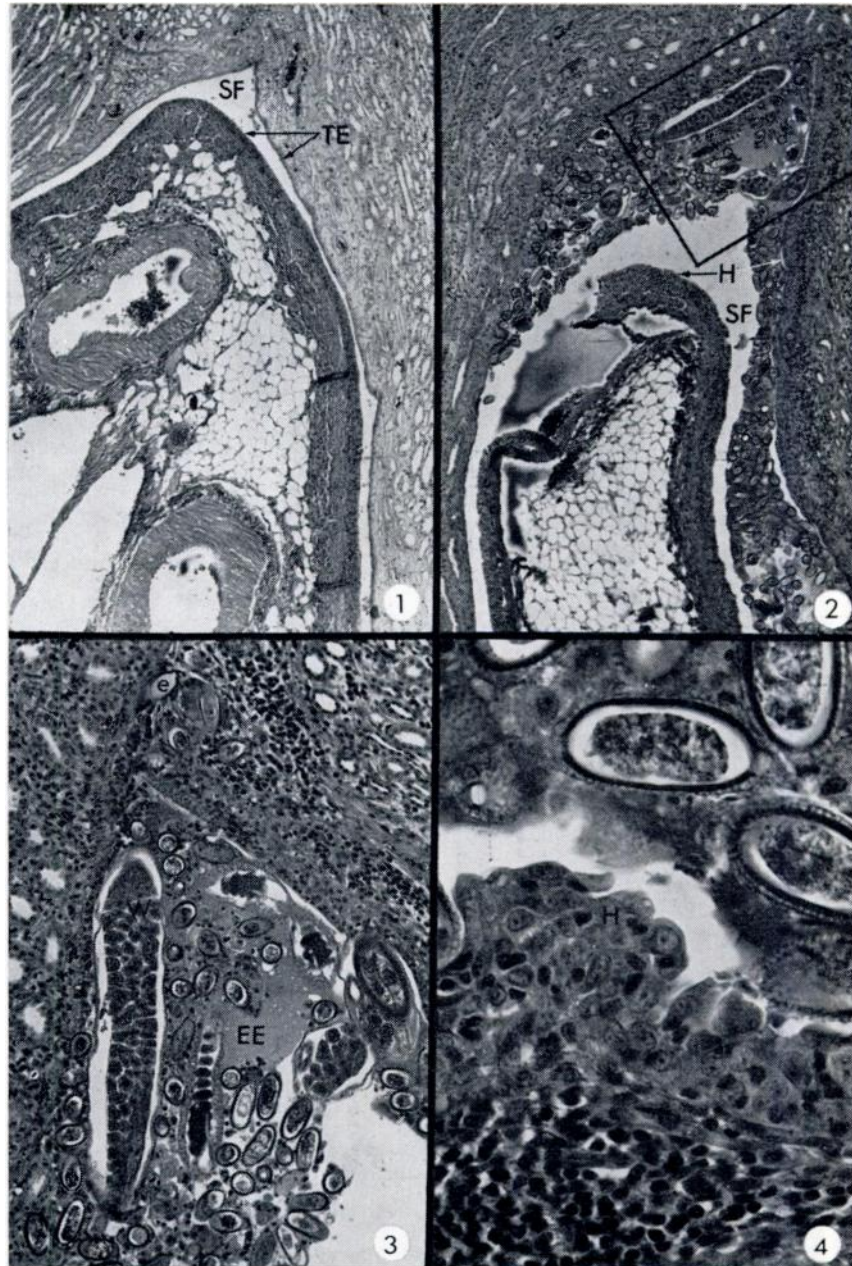
HISTOPATHOLOGY

Kidneys from three mongooses were fixed in 10% buffered formalin, sectioned by routine histologic methods, stained with hematoxylin and eosin (H&E) and examined for lesions. Longitudinal sections of kidneys revealed adult worms and numerous eggs throughout the pelvis where they caused distention of the terminal ends of the pelvic fornices (Fig. 2). Nematodes were not observed in sections of cortex and medulla. The worms and eggs were closely applied to, and occasionally embedded within, the transitional epithelium of the pelvis. In various sections containing parasites, the epithelium was moderately hyperplastic (6 cell nuclei thick, Figs. 2 and 4, H) in comparison with uninfected tissue (1 to 3 cell nuclei thick, Fig. 1, TE). A chronic, low-level inflammation observed throughout the transitional epithelium was characterized by reactive

¹ Supported by a travel grant from the Rockefeller Foundation (to H.W.H.)

² Operated for the U.S.-E.R.D.A. by Union Carbide Corp.

³ Formerly staff member Rockefeller Foundation, 111 West 50th St., New York, N.Y. 10020, USA.



FIGURES 1-4. Longitudinal sections through region of specialized pelvic fornices of mongoose kidney. (H & E).

FIGURE 1. Uninfected kidney with thin transitional epithelium (TE) lining specialized fornix (SF). (88X)

FIGURE 2. Infected kidney with numerous capillarid eggs and worms in distended specialized fornix (SF). Note hyperplasia of transitional epithelium (H, arrows). (88X)

FIGURE 3. Closeup of outlined area in Fig. 2 showing worm (W) and eggs (e) embedded within transitional epithelium and surrounded by plasmacytic reaction. An eosinophilic exudate (EE) surrounds parasites in lumen of fornix. (217X)

FIGURE 4. Closeup of transitional epithelium showing capillarid eggs, hyperplasia (H) and plasmacytic reaction. (788X)

areas of plasma cells in addition to scattered macrophages, lymphocytes and eosinophils (Figs. 3 and 4). Giant cells occasionally surrounded deeply embedded eggs and macrophages contained shell remnants. Accumulations of eggs and worms within the lumens of the fornices were surrounded by an eosinophilic exudate, degenerating leukocytes and desquamated epithelial cells (Fig. 3). An inflammatory reaction was not present in the renal tubules and glomeruli.

DISCUSSION

Jubb and Kennedy² and Levine³ stated that *Capillaria plica* normally parasitizes the urinary bladder, but may enter the

kidney of various domestic and wild mammals as a secondary location. However, the parasite in question appears to utilize the kidney of the mongoose as a preferred location.

Capillaria has not been reported from the kidney of the small Indian mongoose either in its native country or in the West Indies where it was introduced. The high prevalence and mild host reaction indicates a balanced host-parasite association; suggesting that the nematode may have been introduced into St. Lucia with the mongoose. The egg and adult of the *Capillaria* sp. differ morphologically from *C. plica* and *C. felis-cati*,^{5,6,7} and the new species will be described elsewhere.

Acknowledgements

We are grateful to the following individuals from the University of Guelph: Department of Zoology—Mr. Eric Butterworth for examining the unknown capillarid; Department of Pathology—Drs. Ian Barker, Lars Karstad, and Nigel Palmer (Ontario Ministry of Agriculture and Food) for advice on histopathologic interpretations, Dr. Paul Presidente and Ted Eaton for photographic assistance.

LITERATURE CITED

1. HINTON, H. E. 1967. *Mongoose, Their Natural History and Behavior*. Univ. Cal. Press.
2. JUBB, K. V. F. and P. C. KENNEDY. 1970. *Pathology of Domestic Animals*. Vol. 2, 2nd ed. Academic Press, New York, New York.
3. LEVINE, N. D. 1968. *Nematode Parasites of Domestic Animals and Man*, Burgess Pub. Co., Minneapolis, Minn.
4. PFEIFFER, E. W. 1968. Comparative anatomical observations of the mammalian renal pelvis. *J. Anat.* 102: 321-331.

5. READ, C. P. 1949. Studies on North American Helminths of the Genus *Capillaria* Zeder, 1800 (Nematoda). II. Additional capillarids with keys to the North American species. *J. Parasit.* 35: 231-239.
6. SKRJABIN, K. I., N. P. SHIKHOBALOVA and I. V. ORLOV 1957. Trichocephalidae and Capillaridae of Animals and Man and the Diseases Caused by Them. Academy of Sciences of the USSR, Essentials of Nematodology. Vol. VI. Translated from Russian by Israel Program of Scientific Translations. Jerusalem, 1970.
7. WADDELL, A. H. 1967. *Capillaria felis-cati* in the bladder of cats in Australia. *Aust. Vet. J.* 43: 297.

Received for publication 23 May 1975
