

HEPATIC FATTY CIRRHOSIS IN TEXAS WHITE-TAILED DEER

LYTLE H. BLANKENSHIP, Texas Agricultural Research and Extension Center,
Texas A&M University, Uvalde, Texas 78801, USA

L. G. ADAMS and R. M. ROBINSON, Department of Veterinary Pathology,
College of Veterinary Medicine, Texas A&M University, College Station, Texas 78843, USA

J. E. ELLISOR, Texas Parks and Wildlife Department, Chaparral Wildlife Management Area,
Artesia Wells, Texas 78001, USA

Abstract: Hepatic fatty cirrhosis (HFC) has been known to occur in certain domestic livestock species since 1931. Early studies in Texas indicated that HFC was restricted to five western counties. Recently HFC was identified in white-tailed deer (*Odocoileus virginianus texanus*) in South Texas for the first time. Of the deer examined, 25% were affected. The etiology of HFC was not determined.

INTRODUCTION

Hepatic fatty cirrhosis (HFC), commonly called hard yellow liver disease, was first reported in sheep and cattle in 1931,⁵ although a similar appearing hepatic condition had been reported earlier by Buckley *et al.*⁸ Adams¹ indicated that goats and pronghorn antelope (*Antilocapra a. americana*) also were subject to HFC. Although a few white-tailed deer (*Odocoileus virginianus texanus*) were examined during the early studies, no HFC was observed.

HFC was found in a restricted area of West Texas including all or parts of five counties.¹ The four major counties were Glasscock, Midland, Reagan, and Upton and the fifth was Irion, where affected antelope were found. Dollahite *et al.*⁴ suggested that the disease also might occur in Tom Green and Sterling Counties.

The occurrence, distribution and frequency of the disease were reviewed by Adams¹ and Dollahite *et al.*⁴

In April, 1974, three adult female and one yearling male deer were collected on the Chaparral Wildlife Management Area for certain morphological and physiological studies. The livers of two females were abnormal in color and contained multiple white, fat-like globules, but

were not examined histologically. On 27 June 1974, a tissue sample from a liver of similar appearance was taken from a 3-year-old female deer. The condition was diagnosed as HFC by personnel of the Department of Veterinary Pathology, Texas A&M University. This was the first verification of HFC in white-tailed deer, and the first case of the disease reported in any animal species in Texas outside of the aforementioned counties.

MATERIALS AND METHODS

Livers from 112 white-tailed deer shot on the Chaparral Wildlife Management Area in Dimmit and LaSalle Counties of South Texas were examined grossly for evidence of abnormalities. Of these deer, 88 were harvested by hunters in the 1974 hunting season. The other 24 were collected in April, June and October, 1974 and January, 1975 for nutritional studies.

Sections of tissue 2 to 3 mm in thickness were collected from any abnormal areas. Where questionable, the liver was cut at the hilar areas for further evidence of the disease. Tissue samples were fixed in 10% buffered formalin and delivered to the Department of Pathology, College of Veterinary Medicine, Texas A&M University, for further analysis.

The tissues collected in the field were processed in the laboratory, embedded in paraffin, sectioned at 4 μ m and stained with hematoxylin and eosin or other histochemical stains as needed.⁷

RESULTS

Gross pathology

Affected livers were characterized by having bright yellow, irregular foci 1-3 mm in size which contrasted with the dark brown of normal hepatic parenchyma (Fig. 1 and 2). In more advanced cases the foci became confluent to produce larger, irregular yellow zones. The most typical appearance was that of random yellow foci, with some of the livers having solid bands of tissue as reported in sheep and pronghorns. The affected tissue was contracted and firm in texture, suggesting extensive fibrosis.

Of the 112 deer examined, 25% had affected livers (Table 1). Ten of 47 females and 18 of 65 males were affected. Most of the deer were in good condition regardless of the degree of hepatocellular degeneration.




FIGURE 2. Cross-sections of the dorsal and ventral lobes of a deer liver with subcapsular light foci of fatty cirrhosis (arrows) as well as diffuse stippling throughout the hepatic parenchyma.

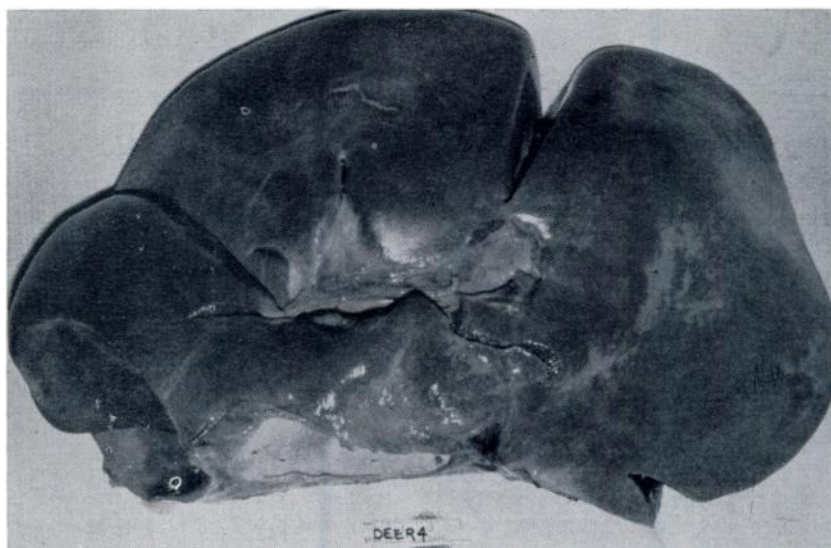


FIGURE 1. Visceral surface of a deer liver with areas of fatty cirrhosis in the ventral lobe and surrounding the hilus.

TABLE 1. Sex, age and body condition characteristics of white-tailed deer affected by hepatic fatty cirrhosis on the Chaparral Wildlife Management Area.

Date	Sex	Age (Yr)	Body Weights (Kg)		Condition
			Live	Dressed	
4-23-74	F	5.0	60.9	35.0	Good
6-26-74	F	2.0	52.3	28.2	Good
10- 3-74	F	4.5	46.8	25.5	Good
10- 3-74	F	3.5	49.5	27.3	Good
10- 4-74	F	5.5	47.3	26.4	Good
11-16-74	M	2.5		38.6	Good
11-16-74	M	2.5		42.3	Good
11-16-74	M	3.5	76.4	59.1	Excellent
11-16-74	F	6.5		53.6	Good
11-16-74	F	4.5		40.0	Good
11-17-74	M	3.5		68.2	Good
12- 1-74	M	5.5		59.1	Good
12- 1-74	M	6.5		56.8	Good
12-14-74	M	3.5		54.5	Good
12-15-74	M	2.5		38.6	Good
12-15-74	M	4.5		55.9	Good
12-15-74	M	2.5		53.2	Good
12-15-74	M	2.5		45.5	Excellent
12-28-74	M	4.5		55.0	Good
12-29-74	M	3.5		57.3	Fair
12-29-74	M	2.5		47.7	Fair
12-29-74	M	5.5		56.8	Good
12-29-74	M	4.5		34.1	Fair
12-29-74	M	5.5		39.1	Good
1-15-75	F	7.5	48.2	28.6	Fair
1-16-75	F	6.5	42.3	26.4	Fair
1-16-75	M	2.5	47.7	30.5	Good
4-10-75	F	3.0	44.1	24.5	Good

Histopathology

The first stages of fatty cirrhosis consisted of fine lipid droplet vacuolation of the hepatic parenchyma (Fig. 3), which then progress to large multi-nucleated vacuoles of fat in the hepatocytes (Fig. 4). The vacuoles become confluent, producing highly vacuolated hepatocytes which could then be observed grossly. The ultimate change was complete re-

placement of the hepatic parenchyma with multinucleated fatty cysts (Fig. 5).

Hepatocellular necrosis associated with replacement fibrous connective deposition occurred subsequent to the formation of large fatty cysts, as demonstrated by the Masson's Trichrome Connective Tissue stain and Oil Red O stain for fats. Minimal hepatocellular regeneration occurred in peripheral lobular areas.

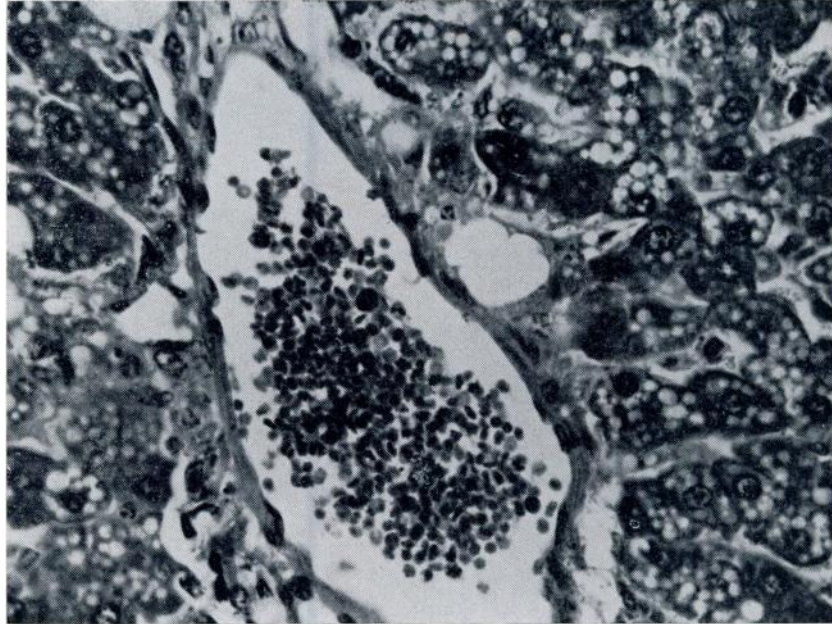


FIGURE 3. Diffuse multiple small lipid droplet vacuolation of the cytoplasm of hepatocytes. Hematoxylin and eosin, 800X.

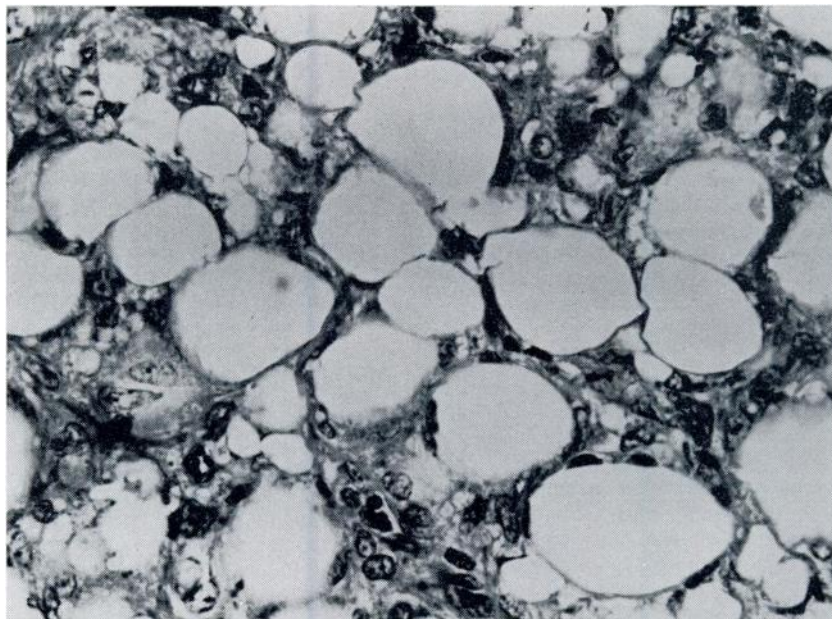


FIGURE 4. Coalescence of small lipid droplets to form large multinucleated fatty cysts within hepatocytes. Hematoxylin and eosin, 820X.

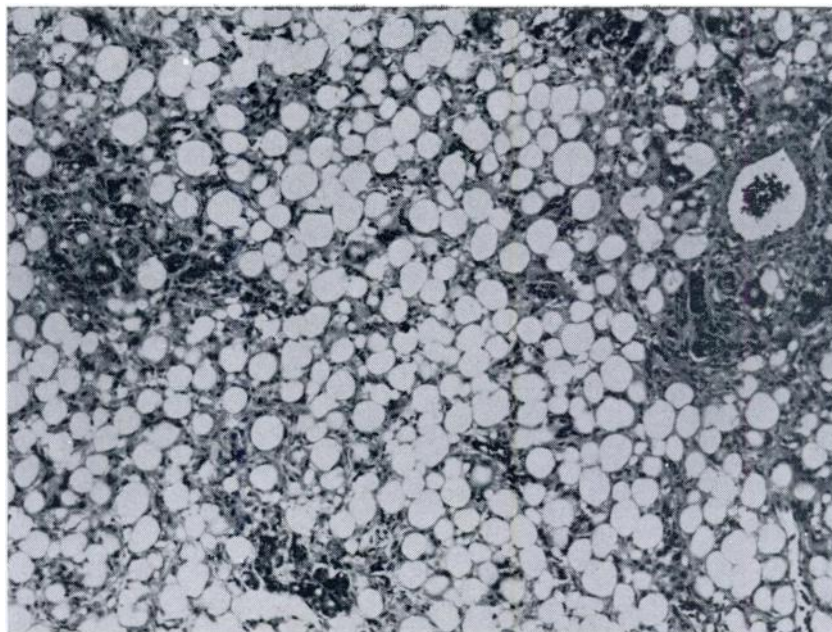


FIGURE 5. Generalized distribution of large fatty cysts throughout the hepatic parenchyma. Hematoxylin and eosin, 130X.

DISCUSSION

The etiology of HFC in white-tailed deer has not been established. Consequently, it is not known why the disease has appeared in an area where it had not been reported in livestock. Original investigations of the disease in livestock and pronghorns in West Texas indicated toxic substances, possibly from plants, as the cause of the disease.⁹ Dollahite *et al.*⁴ summarized many of the past attempts to establish the etiology of HFC including feeding trials and confined pasture grazing but could not provide any definitive conclusions.

Unlike the West Texas area where the disease seems to occur at sporadic intervals of 4 to 7 years⁴ abnormal livers have been noted in deer each hunting season since 1969 on the Chaparral Wildlife Management Area. Also, abnormal livers were found throughout the period of scientific collections described earlier. Not only has the disease had a history of

longevity on Chaparral, but it has occurred in all seasons of the year.

If the disease is related to plant toxins, the lack of consistent rainfall patterns in West Texas could be significant. The growth cycles of many of the plants suggested as possible causes of HFC in the western counties are dependent on the sporadic rainfall and consequently these plants do not appear annually. The Lower Rio Grande Plain has a more abundant and consistent rainfall and hence more frequent occurrence of potentially toxic plants.

The etiology of HFC requires definition because of the serious economic impact of the disease on the livestock industry.^{1,4} The significance of the disease for white-tailed deer survival and quality is not known; however, because HFC is quite common in deer on Chaparral and occurs throughout the year, the species could be used as an experimental animal for determining the etiology of HFC for all ruminants, both domestic and wild.

Acknowledgements

The authors wish to thank Tom Fillinger, Dr. Larry Varner and Jed Elrod of the Texas Agricultural Research and Extension Center, Uvalde, Texas; Max Traweek and Jim Hillje of Texas Parks and Wildlife Department; and Janet Hillje for their assistance in field collections of deer and postmortem examinations.

LITERATURE CITED

1. ADAMS, L. G. 1968. A morphological and biochemical study of the pathogenesis of ovine hepatic fatty cirrhosis. A Doctoral Dissertation, Graduate College, Texas A&M University, College Station, Texas. 143 pp.
2. ————. 1974. Morphogenesis of ovine hepatic fatty cirrhosis. *Vet. Path.* 11: 459, abstract.
3. BUCKLEY, J. S., E. C. JOSS, G. T. CREECH and J. F. COUCH. 1930. Carotenosis of bovine livers associated with parenchymatous degeneration. *J. Agr. Res.* 40: 991-1005.
4. DOLLAHITE, J. W., P. D. OHLENBUSCH and L. D. ROWE. 1971. Hard yellow liver disease in ruminants. *Prog. Rpt. Texas A&M University, TAES, College Station, Texas.* 15 pp.
5. HARDY, W. T., I. B. BOUGHTON and L. V. CORY. 1932. A new liver disease of sheep and cattle. *Tex. Agric. Exper. Sta. 45th Ann. Rpt.* pp. 12-13.
6. ————. 1933. A new liver disease of sheep and cattle. *Tex. Agric. Exper. Sta. 46th Ann. Rpt.* p. 15.
7. LUNA, L. G. 1968. *Manual of Histologic Staining Methods.* 3rd Edition. McGraw-Hill Book Co., N.Y. pp. 140-142.

Received for publication 24 September 1975