

SPONGIFORM ENCEPHALOPATHY OF ROCKY MOUNTAIN ELK [□]

ELIZABETH S. WILLIAMS and STUART YOUNG, Wild Animal Disease Center and Department of Pathology, College of Veterinary Medicine and Biomedical Sciences, Colorado State University, Fort Collins, Colorado 80523, USA.

Abstract: A disease with striking clinical and pathologic similarities to the spongiform encephalopathies is described in six Rocky Mountain elk (*Cervus elaphus nelsoni*) maintained in wildlife facilities in Colorado and Wyoming. Clinical signs included behavioral alterations and progressive weight loss over a period of weeks or months. Consistent microscopic lesions were limited to the central nervous system and characterized by widespread spongiform transformation of the neuropil, intracytoplasmic vacuoles in neuronal perikaryons, and astrocytic hypertrophy and hyperplasia.

INTRODUCTION

The purpose of this report is to describe the clinical and pathologic features of a spontaneous spongiform encephalopathic disease in six Rocky Mountain elk. We have recently reported such a disease syndrome, identified as "chronic wasting disease" (CWD), in captive mule deer (*Odocoileus hemionus hemionus*), a black-tailed deer (*O. hemionus columbianus*), and a mule deer x white-tailed deer (*O. virginianus*) hybrid in the wildlife facilities in Colorado and Wyoming (Williams and Young, 1980). The disease in elk occurred in the same facilities.

MATERIALS AND METHODS

Elk had sporadic fence-line contact with affected and clinically normal deer and were occasionally maintained in pens that had previously held CWD-affected deer. The elk also had occasional

contact with other captive and free-ranging mammalian species [□] and, in one facility, with domestic sheep and goats that were confined in separate pens within the compound. Elk were maintained for nutritional and metabolic research purposes and generally occupied pens up to 1 ha. Good quality alfalfa or grass hay, commercially mixed grains supplemented with minerals and vitamins, and fresh water were fed to the animals except during experimental feeding trials.

Two of the elk were captured as adults in Wyoming in the winter of 1977-1978 and transported to and maintained at the Wyoming Game and Fish Department Sybille Wildlife Research Unit. Four elk calves were hand-raised in the Colorado Division of Wildlife facilities or at the Wild Animal Disease Center, Fort Collins, Colorado, on cow's milk supplemented with vitamins and weaned onto alfalfa hay and grain mixture

[□] This study was supported in part by National Institutes of Health, Biomedical Research Support Grant 2-S07-RR05458-19 and by a Burroughs Wellcome Fellowship administered by the American College of Veterinary Pathologists.

[□] White-tailed deer, pronghorns (*Antilocapra americana*), bighorn sheep (*Ovis canadensis*), mouflon (*Ovis musimon*), deer mice (*Peromyscus maniculatus*), house mice (*Mus musculus*), white-tailed jackrabbits (*Lepus townsendii*), black-tailed jackrabbits (*L. californicus*), desert cottontails (*Sylvilagus audubonii*), raccoons (*Procyon lotor*), striped skunks (*Mephitis mephitis*), Richardson ground squirrels (*Spermophilus richardsonii*), 13-lined ground squirrels (*S. tridecemlineatus*), domestic dogs and cats.

(Hobbs and Baker, 1979). Three of these calves were obtained from either Sybille or the Denver Zoo in 1976 and one was collected from the wild in 1975.

Blood samples in EDTA and for serum were obtained from two affected elk for hematologic evaluation and determination of chemical and electrolyte levels; the elk were immobilized with xylazine hydrochloride[□] during sample collection. Erythrocyte and leukocyte cell counts were performed on a Coulter counter[□] and hemoglobin content was determined using a Coulter hemoglobinometer.[□] A Hycel-17 autoanalyzer[□] was used for analysis of blood urea nitrogen (BUN), creatinine, cholesterol, bilirubin, sodium, inorganic phosphorus, chloride, potassium, creatinine phosphokinase (CPK), serum glutamic oxaloacetic transaminase (SGOT), total protein, globulin, and alkaline phosphatase.

Cerebrospinal fluid was collected (0.5 hr following euthanasia) from one elk; urinalysis was performed on urine collected from the bladder of two elk at necropsy.

Samples of liver from two elk were oven-dried overnight at 100 C, weighed, ashed at 600 C, dissolved in HNO₃, and diluted in H₂O, and analyzed by atomic absorption spectrometry[□] for copper.

Brain and other tissues[□] of affected elk were fixed by immersion in neutral buffered 10% formalin solution within 1 hr of euthanasia. Brains from 15 1 to 2-yr-old captive elk, two captive adult bull elk, and 22 2 to 9-yr-old free-ranging cow elk unaffected with the clinical syndrome were examined as controls; these elk were

euthanized and tissues collected and fixed as described for the affected animals. Tissue sections representing various regions of the brain were embedded in paraffin, sectioned at 6-7 μ m, and stained with hematoxylin and eosin. Selected tissues were post-fixed in formalin-ammonium bromide, sectioned at 15-20 μ m on a freezing microtome, and stained by the Cajal's gold sublimate method for astrocytes (Lillie and Fullmer, 1976).

RESULTS

Clinical signs occurred in elk after captivity for a period of 3 to 5 yr, whether hand-raised or captured in the wild as adults (Table 1). Females, males and castrates were affected. The clinical course of the disease lasted 1 to 6 mo and was characterized by nervousness or hyperexcitability, alterations in personality, changes in behavior toward handlers, and progressive weight loss leading to emaciation (Fig. 1). Most elk showed signs of excessive salivation, teeth-grinding, lowering of the head, and drooping of the ears. Conspicuous polydipsia, polyuria or pruritis were not observed. Although behavioral changes were consistently present, specific motor or sensory neurologic deficits were not identified. In each instance, the disease was terminated by euthanasia.

Hematologic values, serum electrolytes and serum chemistry (Tables 2 and 3) were considered to be in the normal range for elk (Kitchen, 1978) or to reflect their emaciated condition. Cerebrospinal fluid was colorless and clear, the specific gravity was 1.006, pH

[□] Rompun, Haver Lockhart, Shawnee, Kansas 66201, USA.

[□] Coulter Electronics, Inc., Hialeah, Florida 33010, USA.

[□] Hycel Inc., Houston, Texas 77053, USA.

[□] Varian Techtron 1250 atomic absorption spectrophotometer, Varian Techtron Pty. LTD., Springvale, Victoria, Australia.

[□] Heart, spleen, mesenteric lymph node, rumen, abomasum, jejunum, ileum, colon, spinal cord, lung, skeletal muscle, adrenal gland, pituitary gland, thyroid gland, pancreas, liver, kidney, gonads and eyes were collected from most animals.

TABLE 1. Clinical and pathologic features of spongiform encephalopathy in Rocky Mountain elk.

Elk number	Sex	Age (years)	Duration of clinical disease (months)	Origin	Clinical signs	Intercurrent pathology
1	F (pregnant)	4	>1	Fort Collins	Weight loss, Grind teeth, Salivation, Weakness	Traumatic reticulitis, pericarditis Suppurative broncho-pneumonia
2	M	3	>1	Fort Collins	Weight loss, Grind teeth, Salivation, Behavioral changes	Traumatic reticulitis, pericarditis
3	F	≥6	4	Sybillie	Weight loss, Nervousness, Salivation	None
4	CM ^a	5	6	Fort Collins	Weight loss, Grind teeth, Behavioral changes	None
5	CM	5	2	Fort Collins	Weight loss, Grind teeth, Behavioral changes	None
6	F	≥6	2	Sybillie	Weight loss, Nervousness	None

^aCastrated male.




FIGURE 1. Emaciated cow elk, 4 yr of age, showing excessive salivation and depressed attitude characteristic of the syndrome.

TABLE 2. Hematologic values of two Rocky Mountain elk with spongiform encephalopathy.

Parameter	Elk #4	Elk #5
PCV (%)	33	38
Hg (g dl)	12.9	14.6
Serum protein (g dl)	6.2	6.4
WBC, mm ³	4200	5700
Neutrophils (%)	65	58
Lymphocytes (%)	29	39
Monocytes (%)	1	1
Eosinophils (%)	5	2
Basophils (%)	0	0

was 7, and total protein was 50 mg. Pandy test and CPK were negative; few erythrocytes and one monocyte were present in the sample. Urine specific gravity and pH were 1.008 and 7.5 and 1.006 and 8.0, respectively, for two elk. The urine samples were negative for protein, glucose, ketones, and bilirubin,

but one sample had a trace of hemoglobin and both contained a few epithelial cells. Liver copper levels (Table 3) were considered to be within the normal range for elk and red deer (*Cervus elaphus*) (Reid et al., 1980; McTaggart et al., 1981).

The primary gross lesions were emaciation and dry, rough pelage.

TABLE 3. Serum electrolytes, serum chemistry, and liver copper levels of two Rocky Mountain elk with spongiform encephalopathy.

Parameter	Elk #4	Elk #5
BUN (g/dl)	25	19
Globulin (g/dl)	2.4	2.2
Cholesterol (mg/dl)	40	37
Total bilirubin (mg/dl)	0.33	0.33
Creatinine	2.7	3.2
Alk. phos. (U ^a /l)	33	37
SGOT (U ^a /l)	102	34
Inorganic		
phosphorus (mg/dl)	6.0	6.2
Calcium (mg/dl)	8.9	8.7
Chloride (meg/dl)	109	104
Sodium (meg/dl)	138	138
Potassium (meg/dl)	4.3	4.5
Liver copper (ppm) ^b	40	37

^aInternational units.

^bParts per million, dry weight.

Traumatic reticulitis and pericarditis were associated with small pieces of baling wire penetrating the fore-stomachs of two animals. One elk was pregnant and a healthy full-term calf was removed at the time of euthanasia. The calf remained clinically normal until killed when 2.5 yr of age. Microscopically the brain was normal.

Consistent histopathologic change was not identified in extraneural tissues of affected elk. Neurohistologic changes, similar in all affected elk, were characterized by spongiform transformation of the neuropil, predominantly of the gray matter (Fig. 2) and to a lesser degree the white matter, by single or multiple intracytoplasmic vacuoles in neuronal perikaryons (Fig. 2), and by neuronal degeneration. Inflammation was not observed. Spongiform change was widespread, variable in severity, and spared only portions of cerebral cortex and basal ganglia. Astrocytic hypertrophy and hyperplasia were demonstrable in gold sublimate stained sections (Fig. 3).

Examination of brains from 39 captive or free-ranging elk, clinically unaffected with the syndrome, did not reveal the

presence of a spongiform encephalopathy. Only occasional discrete single vacuoles were observed intracytoplasmically and in the neuropil of grey and white matter. Many control elk showed vascular and neuropathologic evidence of elaeophorosis.

DISCUSSION

CWD of mule deer was first identified in 1967 at Fort Collins; the first two elk cases were in 1979 in the same pens. Subsequently, cases in elk were diagnosed at Sybille, 2 yr after the first case of CWD was recognized in deer at that facility. Morbidity and mortality of elk since recognition of this syndrome varied between the two facilities. Four of eight elk hand-raised and maintained for longer than 3 yr in the Fort Collins facility died of this disease, while in the Sybille facility only two of 60 have been affected. Management of the elk was somewhat different at these facilities. At Fort Collins, all elk were hand-raised and had close contact with humans and with other captive wild species, including mule deer. In contrast, elk at Sybille were captured as adults from the wild and had only sporadic direct contact with

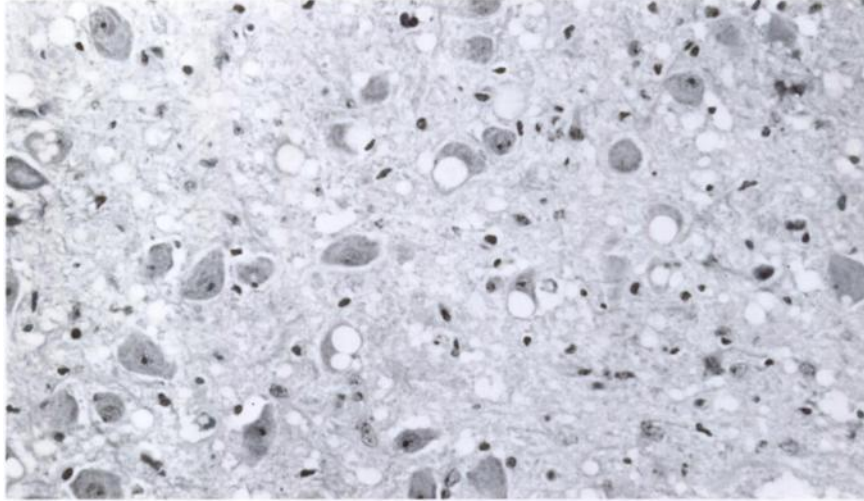


FIGURE 2. Diffuse spongiform change in the neuropil and intracytoplasmic vacuoles in neurons of the medulla oblongata. H&E \times 630.

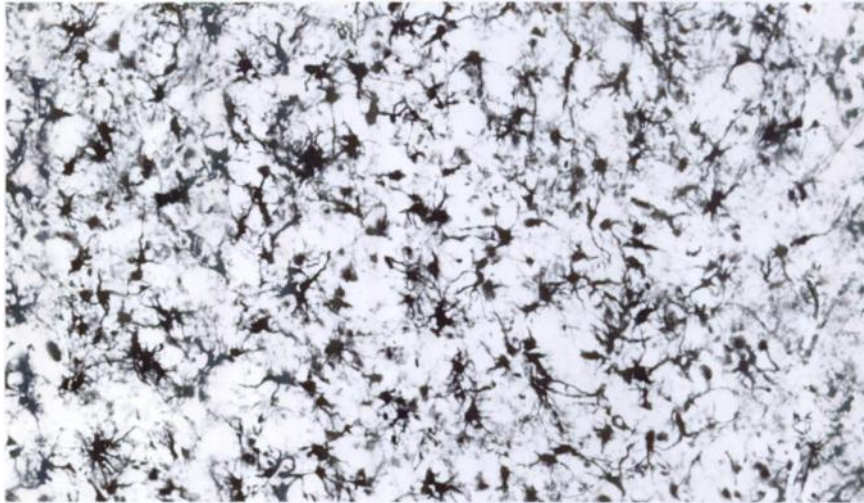


FIGURE 3. Astrocytic hypertrophy and hyperplasia in the thalamus. Cajal's gold chloride impregnation \times 400.

humans and fence-line contact with other species. Many more cases of CWD in deer have occurred in the Fort Collins facility than at Sybille. It is not known if these management differences sig-

nificantly influenced development of the disease.

Clinical pathologic values of affected elk were considered to be in the normal range for elk, with the exception of low

urine specific gravity. Degenerative changes were consistently present in the hypothalamus and, in some elk, specific lesions were identified in the supraoptic and paraventricular nuclei. This damage could influence production of antidiuretic hormone with resultant compromised ability to concentrate the urine. All animals were in a normal state of hydration when killed.

The clinical signs and neurohistopathology of this syndrome in elk closely resemble CWD of mule deer (Williams and Young, 1980) and are qualitatively comparable to other spongiform encephalopathies of animals (scrapie, transmissible mink encephalopathy) and man (kuru, Creutzfeldt-Jakob disease) (Prusiner and Hadlow, 1979). The

association between CWD in mule deer and the spongiform encephalopathy of elk held in the same facilities is unclear. The disease is apparently limited to wildlife facilities in Colorado and Wyoming. The indirect or fence-line contact of elk in both facilities with affected mule deer provides only circumstantial evidence of transmission of the disease between these species. Similar circumstantial evidence indicating possible horizontal transmission among mule deer exists, but the primary source of the disease in mule deer and elk has not been identified. Established transmissible spongiform encephalopathies have been transmitted to a variety of species and are thought to be caused by "slow virus" infection.

Acknowledgements

We wish to thank Mr. Paul Neil, Mr. Dan Baker, Mr. Huey Dawson, and Drs. Tom Thorne and Bill Lance for assistance and case material.

LITERATURE CITED

- HOBBS, N.T. and D.L. BAKER. 1979. Rearing and training elk calves for use in food habits studies. *J. Wildl. Manage.* 43: 568-570.
- KITCHEN, H. 1978. Hematological values and blood chemistries for a variety of artiodactylids. In: *Zoo and Wild Animal Medicine*. M.E. Fowler (ed.). W.B. Saunders Co., Philadelphia, Pennsylvania. pp. 815-830.
- LILLIE, R.D. and H.M. FULLMER. 1976. *Histopathologic Technique and Practical Histochemistry*. 4th ed. McGraw-Hill Book Co., New York, New York. 942 pp.
- McTAGGART, H.S., V.P.N. LOWE, P.J. BARDEN and J.B.M. GELLATLY. 1981. Copper status of red deer on the island of Rhum. *Vet. Rec.* 109: 155-157.
- PRUSINER, S.B. and W.J. HADLOW. 1979. *Slow Transmissible Diseases of the Nervous System. Vol. 1.: Clinical, Epidemiological, Genetic and Pathologic Aspects of the Spongiform Encephalopathies*. Academic Press, New York, New York. 472 pp.
- REID, T.C., H.J.F. McALLUM and P.D. JOHNSTONE. 1980. Liver copper concentrations in red deer (*Cervus elaphus*) and wapiti (*C. canadensis*) in New Zealand. *Res. Vet. Sci.* 28: 261-262.
- WILLIAMS, E.S. and S. YOUNG. 1980. Chronic wasting disease of captive mule deer: a spongiform encephalopathy. *J. Wildl. Dis.* 16: 89-98.

Received for publication 26 April 1982