

## Vertebral Osteomyelitis and Suspected Diskospondylitis in an Atlantic Bottlenose Dolphin (*Tursiops truncatus*)

J. W. Alexander,<sup>1</sup> Mobashir A. Solangi,<sup>2</sup> and Leon S. Riegel,<sup>3</sup> <sup>1</sup> College of Veterinary Medicine, Oklahoma State University, Stillwater, Oklahoma 74078, USA; <sup>2</sup> Institute for Marine Mammal Studies, Gulfport, Mississippi 39501, USA; <sup>3</sup> Valley Animal Hospital, Palmyra, Pennsylvania 17078, USA

**ABSTRACT:** A 21-yr-old male Atlantic bottlenose dolphin (*Tursiops truncatus*) was performing at an aquatic park when it developed a soft tissue swelling anterior to the flukes. Subsequent radiographic evaluation revealed the animal to have vertebral osteomyelitis and suspected diskospondylitis. The case was successfully managed with long-term antibiotic therapy.

**Key words:** Vertebral osteomyelitis, diskospondylitis, sclerosis, intervertebral disk space, periosteal response, case history.

Diskospondylitis is defined as intervertebral disk infection with concurrent osteomyelitis of contiguous vertebrae. The syndrome was recognized in man as early as 1887 and has been the subject of several review articles and clinical reports over the past 50 yr (Kulowski, 1936; Hewson and Coventry, 1956; Garcia and Grantham, 1960; Griffiths and Jones, 1971). A similar disease has been reported in the dog (Henderson et al., 1974; Hurov and Turnwald, 1978; Kornegay, 1979; Kornegay and Barber, 1980; Gilmore, 1983; Johnson and Prata, 1983), horse (Adams et al., 1985), and a California sea lion (Thomas-Baker, 1986). Because these infections usually begin within the body of the vertebrae adjacent to the endplates, they may be most accurately defined as osteomyelitis. Depending on the pathway of extension from the endplate zone, an ensuing diskitis, paravertebral abscess, epidural abscess, meningitis or myelitis may occur (Johnson and Prata, 1983).

The only previously reported case of diskospondylitis in a marine mammal involved a 6-wk-old female California sea lion (*Zalophus californianus*) with neurologic dysfunction of the foreflippers and dorsum and absence of neurologic function in the hindflippers. Radiographs of the cervical region and subsequent necropsy

revealed necrosis and loss of the C2-C3 intervertebral disk and lysis of the vertebral bodies and endplates of C2 and C3. The present case report presents the history, clinical signs, radiographic findings and treatment of a 21-yr-old male Atlantic bottlenose dolphin (*Tursiops truncatus*) with vertebral osteomyelitis and suspected diskospondylitis.

The dolphin, which was performing in an aquatic park (Marine Life, Gulfport, Mississippi 39502, USA), was first noticed on 5 May 1986, to have a hard 4 cm lump on the right side in the posterior lumbar region approximately 15 cm anterior to the flukes. The dolphin was normal in all other respects and treatment was not indicated. On 6 September 1986, the lump had enlarged in size to approximately 9.0 cm, and a similar but smaller enlargement was noted on the left side in the same anatomical location (Fig. 1). Routine hematologic evaluation revealed a white blood cell count of 13,900/ $\mu$ l with a relative neutrophilia (80%). On 9 September 1986, the animal was depressed, anorexic and refused to perform selected previously mastered behaviors (tail walk and flips). Radiographs of the posterior lumbar region centered over the mass showed a chronic, but active, proliferative process involving one of the vertebrae near the caudal end of the spinal column proximal to the fluke region. The vertebral body of this segment was intensely sclerotic. There was evidence of a large soft tissue swelling dorsolateral to the affected vertebral segment. The intervertebral disk space between this vertebra and the one just cranial to it was significantly narrowed by at least 50% of its normal diameter. There was a slight involvement of this more cranial vertebra with a mild

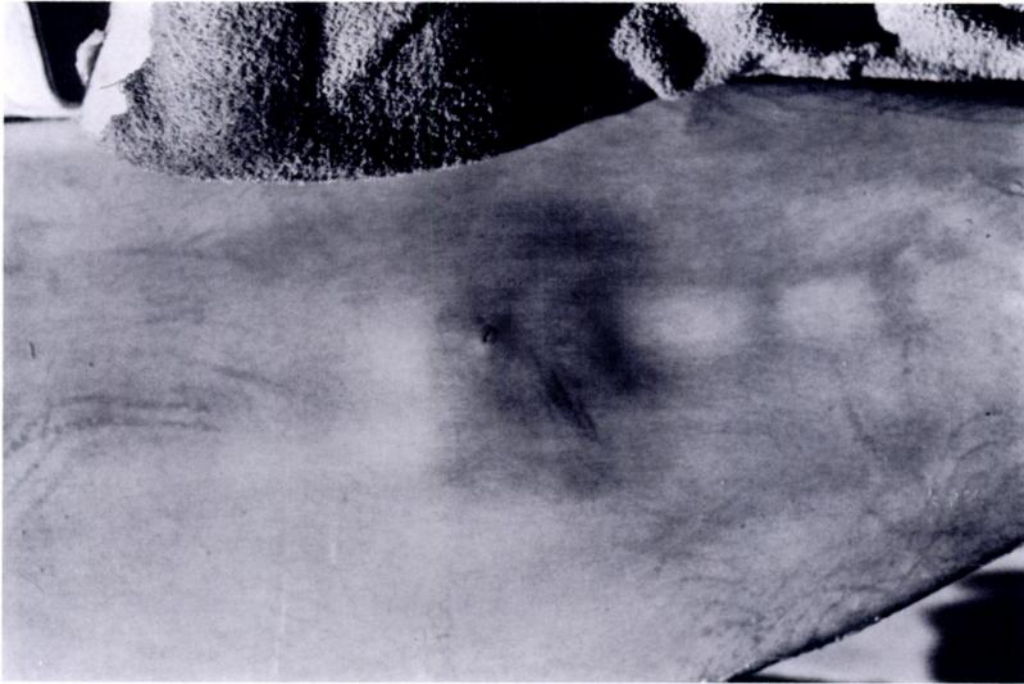


FIGURE 1. Dorsal view of the posterior lumbar region of a 21-yr-old male Atlantic bottlenose dolphin (*Tursiops truncatus*) showing a 9 cm soft tissue swelling approximately 15 cm anterior to the flukes.

periosteal response along its right lateral aspect; however, there was no interior sclerosis (Fig. 2).

A tentative diagnosis of vertebral osteomyelitis and suspected diskospondylitis was made and the animal was treated with flunixin meglumine (Banamine, Schering, Irving, Texas 75061, USA), and a combination of gentamycin sulfate (Schering, Irving, Texas 75061, USA) and ampicillin (Mylan Pharmaceuticals, Morgantown, West Virginia 26505, USA). The antibiotic combination was discontinued after 7 days and the animal was placed on cephalexin (Keflex, Dista, Indianapolis, Indiana 46280, USA) for 30 days. Trimethoprim-sulfadiazine (Tribrissen, Cooper Animal Health, Kansas City, Missouri 64112, USA) was used for an additional 60 days. During this time period serial blood samples revealed a decrease in the white blood cell count with a return to normal approximately 10 days after the beginning of antibiotic therapy. Although it was necessary to force-feed the animal on one occasion, the ap-

petite gradually returned to normal. Approximately 6 wk after the initial diagnosis the animal's activity returned to normal along with the ability to perform all previously mastered behaviors. Subsequently, radiographs taken approximately 4 mo after the initial diagnosis showed no further extension of the disease process with a less aggressive appearing periosteal response. The intervertebral disk space remained unchanged and the interior sclerosis of the most involved vertebrae had a more homogeneous appearance (Fig. 3). The soft tissue mass had significantly decreased in size and was now a hard, fibrous consistency. It has been 1.5 yr since the initial diagnosis and the animal has remained free of clinical signs.

In dogs with vertebral osteomyelitis and diskospondylitis the bacteria most often isolated from the blood or from affected tissue are *Staphylococcus aureus*, *Brucella canis*, *Corynebacterium* spp., *Pasteurella multocida*, *Escherichia coli* and *Proteus* spp. (Kornegay, 1979). Fungal agents that

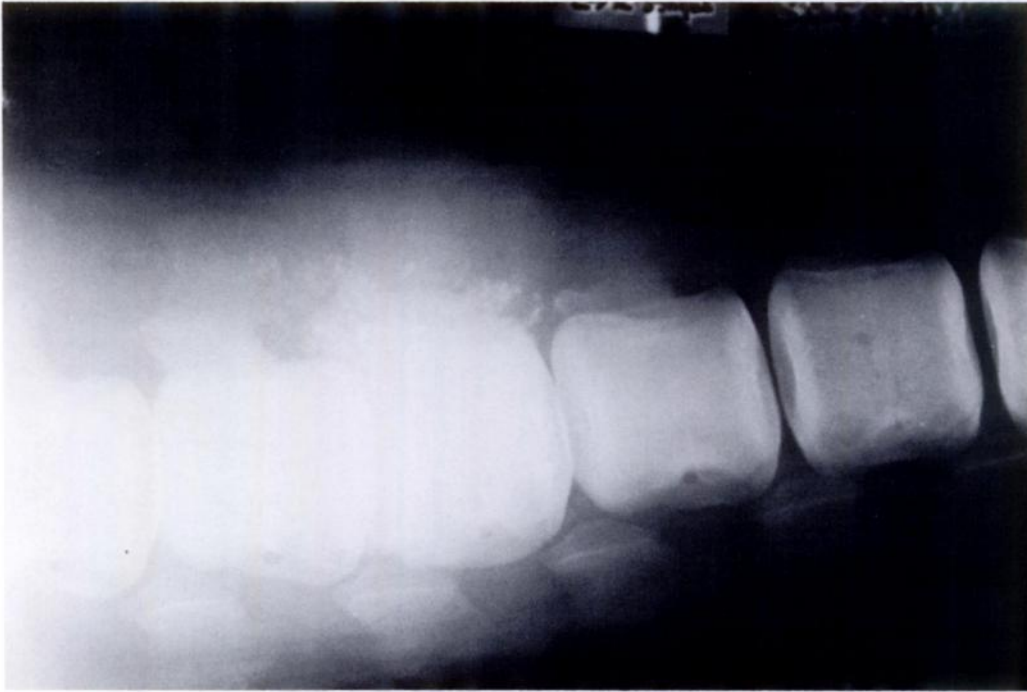


FIGURE 2. Radiograph of the posterior lumbar spine demonstrating a sclerosis of the vertebral bodies, collapse of the intervertebral disk space and periosteal new bone formation in an Atlantic bottlenose dolphin.

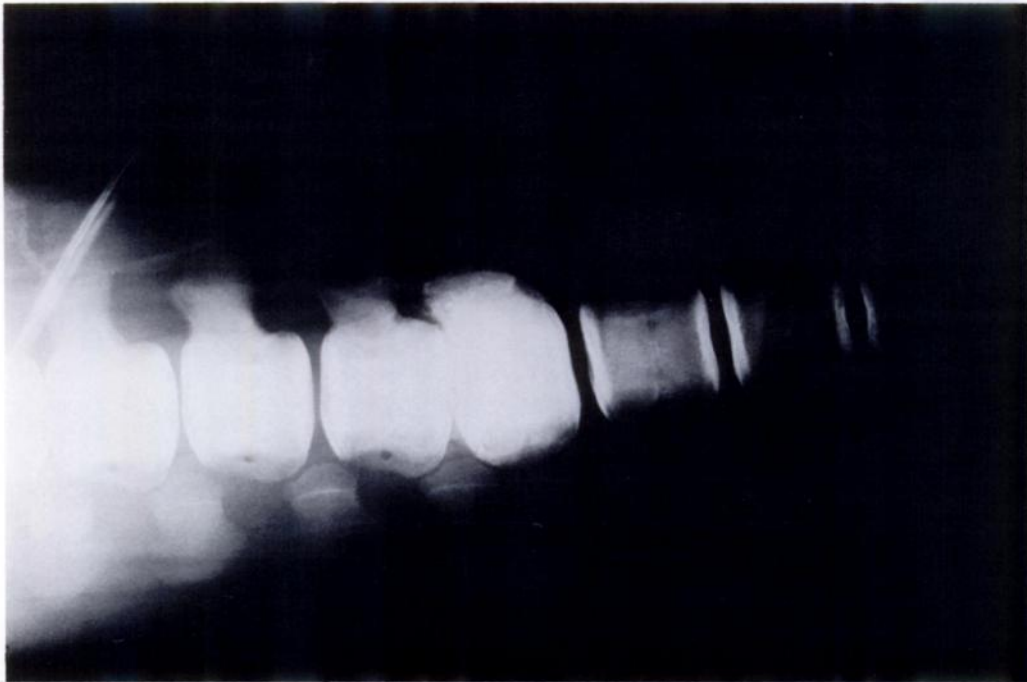

FIGURE 3. Radiograph of the posterior lumbar spine of an Atlantic bottlenose dolphin 4 mo posttreatment. Although the disk space has remained collapsed there has been no further extension of the disease process as compared to Figure 2.

have been associated with this syndrome include *Paecilomyces* spp., *Aspergillus terreus*, *Nocardia* spp., *Fusarium* spp. and *Mucor* spp. (Kornegay, 1979). In the case involving a California sea lion a *Streptococcus* sp. of the *Viridans* group from the disk space (Thomas-Baker, 1986). Usually, the mode of introduction of organisms is hematogenous and rarely associated with the direct extension from adjacent areas (Johnson and Prata, 1983). Urinary tract infections are thought to serve as primary foci of infection in both human beings (Hewson and Coventry, 1956) and animals (Gilmore, 1983) affected with vertebral osteomyelitis. Bacterial endocarditis (Hurov et al., 1978) and testicular infections (Henderson et al., 1974; Kornegay and Barber, 1980) also have been cited as sources of infection. Bacteria were initially thought to spread from the urinary system to the vertebral column through the venous plexus; however, studies of the vertebral arterial and venous blood supply in humans have shown that vertebral osteomyelitis and diskospondylitis probably develop from spread via the arterial system (Wiley and Trueta, 1959). As with any infection involving the bone, successful treatment is based upon an early diagnosis and aggressive, long-term antibiotic therapy.

#### LITERATURE CITED

- ADAMS, S., R. STECKEL, AND W. BLEVINS. 1985. Diskospondylitis in five horses. *Journal of the American Veterinary Medical Association* 186: 270-272.
- GARCIA, A., AND S. A. GRANTHAM. 1960. Hematogenous pyogenic vertebral osteomyelitis. *Journal of Bone and Joint Surgery (American)* 42: 429-436.
- GILMORE, D. R. 1983. Diskospondylitis and multifocal osteomyelitis in two dogs. *Journal of the American Veterinary Medical Association* 182: 64-66.
- GRIFFITHS, H. E. D., AND D. M. JONES. 1971. Pyogenic infection of the spine: A review of twenty-eight cases. *Journal of Bone and Joint Surgery (British)* 53: 383-391.
- HENDERSON, R. A., B. F. HOERLEIN, AND T. T. KRAMER. 1974. Diskospondylitis in 3 dogs infected with *Brucella canis*. *Journal of the American Veterinary Medical Association* 165: 451-455.
- HEWSON, S. W., AND M. B. CONVENTRY. 1956. Osteomyelitis of the vertebrae as the result of infection of the urinary tract. *Surgery, Gynecology and Obstetrics* 102: 207-214.
- HUROV, L., G. TROY, AND G. TURNWALD. 1978. Diskospondylitis in the dog: 27 cases. *Journal of the American Veterinary Medical Association* 173: 275-281.
- JOHNSON, R. G., AND R. G. PRATA. 1983. Intradiskal osteomyelitis. *Journal of the American Animal Hospital Association* 19: 743-750.
- KORNEGAY, J. N. 1979. Canine diskospondylitis. *Compendium on Continuing Education* 1: 930-933.
- , AND D. L. BARBER. 1980. Diskospondylitis in dogs. *Journal of the American Veterinary Medical Association* 177: 337-341.
- KULOWSKI, J. 1936. Pyogenic osteomyelitis of the spine. An analysis and discussion of 102 cases. *Journal of Bone and Joint Surgery (British)* 18: 343-364.
- THOMAS-BAKER, B. 1986. Diskospondylitis in a California sea lion. *Journal of the American Veterinary Medical Association* 189: 1151.
- WILEY, A. M., AND J. TRUETA. 1959. The vascular anatomy of the spine and its relationship to pyogenic vertebral osteomyelitis. *Journal of Bone and Joint Surgery (British)* 41: 796-809.

Received for publication 23 May 1988.