

Aberrant Migration by *Toxocara pteropodis* in Flying-Foxes—Two Case Reports

Paul Prociv, Department of Parasitology, The University of Queensland, St. Lucia, Queensland 4067, Australia

ABSTRACT: Adults of the large nematode, *Toxocara pteropodis*, have not previously been reported from extra-intestinal sites in their hosts, juvenile flying-foxes (fruit-bats of the genus *Pteropus*). In one captive bat which died unexpectedly, a nematode was found coiled within the gall bladder and common bile duct; in another, a nematode was in the esophagus and protruded into the laryngopharynx. Like other ascaridoids, this species is capable of aberrant migration.

Key words: Ascaridoid nematodes, *Toxocara pteropodis*, flying-foxes, fruit-bats, *Pteropus* spp., aberrant migration, biliary obstruction.

Toxocara pteropodis, a nematode parasite of flying-foxes (fruit-bats of the genus *Pteropus*), is found in species from Australia, Oceania and southeastern Asia. The life-cycle, as reviewed by Prociv (1989a), indicates that adult nematodes mature in the intestines of suckling bats, which pass eggs in feces until the infections terminate spontaneously at about the time of weaning. Third-stage larvae, hatched from infective eggs ingested by adult bats, migrate to the liver. In females, at the end of parturition, some hepatic larvae are mobilized and pass through the mammary glands into the intestine of the neonate.

In the grey-headed flying-fox of eastern Australia (*P. poliocephalus*), patent infections with *T. pteropodis* develop in >50% of juveniles (Prociv, 1989a), which each has an average of 3.2 mature nematodes (excluding bats with only male nematodes). A maximum of only 5 mature adult nematodes (4 females and 1 male) has ever been found in a bat (P. Prociv, unpubl.). Such a low intensity of infection may result from mechanisms utilised by the parasite to avoid overloading the host; suckling bats weigh only 120 to 250 g, while the nem-

atode grows to 150 mm in length. Consequently, many bats have only single-sex nematode infections. The release of as many as 25,000 eggs/female nematode/day (Prociv, 1989b) within a restricted environment ensures continuity of the life-cycle (Prociv, 1985).

Infected bats usually show no external signs of illness. However, during a 5-yr study of several hundred free and captive flying-foxes in coastal Queensland (Australia), two juveniles which died in captivity were found with *T. pteropodis* in abnormal sites.

In December 1981, a 135 g juvenile female was retrieved from a recently abandoned spectacled flying-fox (*P. conspicillatus*) camp in mangroves along the Mossman River, northern Queensland (16°26'S, 145°27'E). It was kept in a 60 × 45 × 45 cm steel mesh cage, on a laboratory bench, and maintained on a diet of fresh fruit and vitamin-enriched reconstituted milk. It was handled frequently and engaged vigorously in the normal activities of eating, defecating, urinating, vocalising, climbing, wing flapping and interacting with other bats. Seven days after capture, it spontaneously passed two adult female *T. pteropodis*, following which ascarid egg output ceased. Three days later, it stopped eating and the following day was found dead in its cage. At necropsy, an adult male nematode was found coiled within the gall bladder and common bile duct (Fig. 1). The liver was slightly paler than normal and coarsely mottled.

In January 1984, a 150 g male *P. poliocephalus* was captured in mangroves along the North Pine River, 20 km north of Brisbane (27°11'S, 152°55'E). It was passing infertile ascaridoid eggs. Three days after

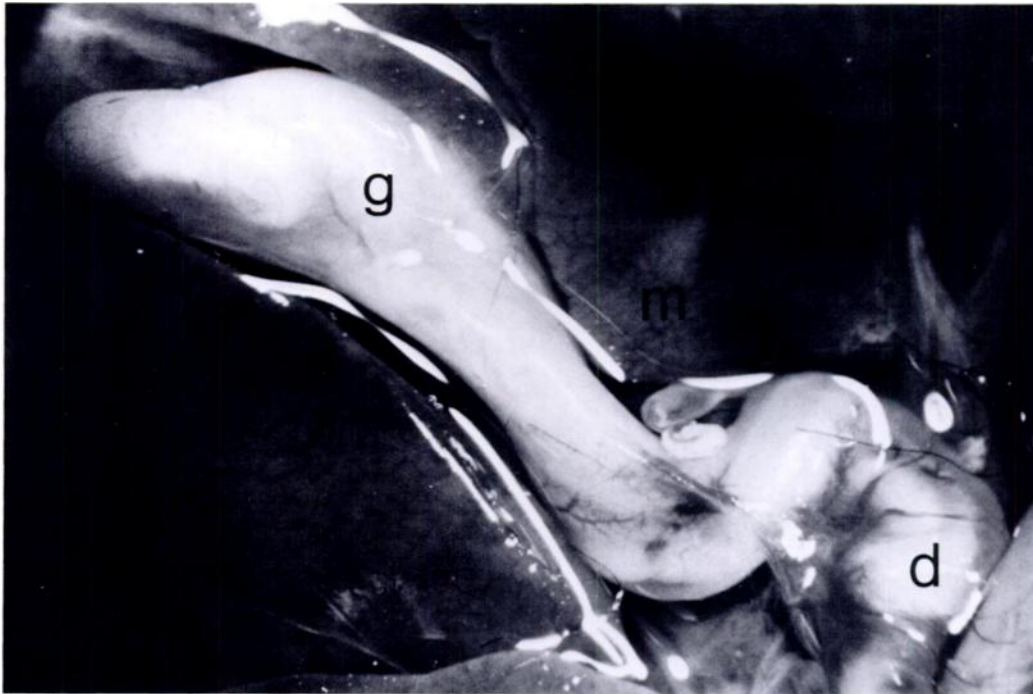


FIGURE 1. Adult male *Toxocara pteropodis* distending gall-bladder (g) and common bile duct (d) of juvenile *Pteropus conspicillatus*. Note coarse pale mottling (m) of hepatic parenchyma.

capture it was found dead, hanging in its cage with tongue protruding; both tongue and oral mucosae were blue. At necropsy, the lungs appeared congested with blood, but otherwise were macroscopically normal. Parasites were not found in the intestine, but a solitary adult female *T. pteropodis* was found in the esophagus, extending into the laryngopharynx.

In both of these cases, death may have been the consequence of abnormal parasite migration. The refusal of the first bat to eat perhaps was an early sign of biliary tract irritation. The precise cause of death was not clear, especially as there were no histological or microbiological studies to exclude secondary bacterial infection. In the other case, death may have resulted from asphyxia. Flying-foxes have a narrow faucial passage which would obstruct the exit of such a large nematode. It is unlikely the parasite migrated post-mortem, as the bat was cyanosed, which is uncommon in bats dying of other causes, and its lungs were more congested than usual.

Other ascaridoid species can cause intestinal obstruction in their definitive hosts, or undergo aberrant migration. These include *Toxocara canis* and *Ascaris suum* in dogs and pigs, respectively (Soulsby, 1982), and *A. lumbricoides* in humans which may increase its activity in response to fever and other stimuli (Arean and Crandall, 1971). However, such complications usually occur in heavy infections, in contrast to the cases presented here.

In both of these bats, nematode migration may have been associated with captivity, perhaps in response to an abnormal diet. The pathogenicity of *T. pteropodis* under natural conditions is unknown, as dead suckling juvenile bats were never found during this study.

LITERATURE CITED

- AREAN, V. M., AND C. A. CRANDALL. 1971. Ascariasis. In Pathology of protozoal and helminthic diseases, R. A. Marcial-Rojas (ed.). Williams & Wilkins Co., Baltimore, Maryland, pp. 769-807.

- PROCIV, P. 1985. Observations on the prevalence and possible infection source of *Toxocara pteropodis* (Nematoda: Ascaridoidea) in Queensland flying-foxes. *Australian Mammalogy* 8: 319–323.
- . 1989a. *Toxocara pteropodis* and visceral larva migrans. *Parasitology Today* 5: 106–109.
- . 1989b. Observations on egg production by *Toxocara pteropodis*. *International Journal for Parasitology* 19: 441–443.
- SOULSBY, E. J. L. 1982. *Helminths, arthropods and protozoa of domesticated animals*. Bailliere Tindall, London, United Kingdom, 809 pp.