

Dental and Mandibular Injury in an Antarctic Fur Seal, *Arctocephalus gazella*, at Heard Island, Southern Ocean

E. Erb,^{1,4} P. D. Shaughnessy,² and R. J. de B. Norman,^{3,5} ¹Australian Antarctic Division, Kingston, Tasmania 7050, Australia; ²CSIRO Division of Wildlife and Ecology, PO Box 84, Lyneham, Australian Capital Territory 2602, Australia; ³Department of Veterinary Science, University of Melbourne, Parkville, Victoria 3052, Australia; ⁴Present address: Park Beim Betonwerk, 5622 Waltenschwil, Switzerland; ⁵Present address: Department of Veterinary Pathology, University of Glasgow Veterinary School, Glasgow G61 1QH, United Kingdom

ABSTRACT: The skull of an adult male Antarctic fur seal (*Arctocephalus gazella*) collected at Heard Island, Southern Ocean, October 1992, had chronic changes attributable to a fracture of the left lower canine, luxation of the mental symphysis, osteomyelitis of the left and right mandibles, and periostitis of the left maxilla.

Key words: *Arctocephalus gazella*, Antarctic fur seal, Heard Island, mandibular injury, pathology.

Antarctic fur seals *Arctocephalus gazella* breed at South Georgia and at other subantarctic islands in the Southern Ocean (Bonner, 1981). There are small breeding colonies at Heard Island (53°10'S, 73°30'E), where pup production in the 1987 to 1988 season was 248, and 15,000 molting animals were ashore during in February 1988 (Shaughnessy and Goldsworthy, 1990).

Acquired dental and craniofacial lesions in wild pinnipeds have been reported infrequently. Eight cases of dental disease including one of tooth loss and mandibular osteomyelitis were found in 36 gray seals *Halichoerus grypus* (Baker, 1987). Cave and Bonner (1987) described the skull of a leopard seal (*Hydrurga leptonyx*) with hypoplastic facial asymmetry, and Rounsevell and Pemberton (1994) reported mandibular fractures in this species in Tasmania and at Heard Island. In adult males of colonially breeding species such as southern elephant seals (*Mirounga leonina*), tooth fracture may lead to infection of the jaw (Carrick and Ingham, 1962). In Antarctic fur seals two cases of broken canines among 44 dead adult males were reported by Baker and McCann (1989). Here we report a case of dental loss, and mandibular and maxillary osteomyelitis in

an adult male Antarctic fur seal from Heard Island.

Twenty-two Antarctic fur seal skulls were collected from beaches near Spit Bay at the eastern end of Heard Island from February 1992 to March 1993. They were deposited in the Australian Museum, Sydney, Australia (accession numbers M28909-28915, M29109-M29122). The skull described here (M32062) was part of a complete skeleton found in October 1992, buried in sand on the north-eastern shore of Scholes Lagoon, 100 m from the Spit Bay coast. From the state of the bones and teeth, we inferred that the animal had died a few years earlier.

Examination of the skull was assisted by radiography of disarticulated mandibles. Dental changes were mapped using a universal dental notation system (Kertesz, 1993). Individual teeth were identified by arcade or quadrant numbered clockwise when viewing the skull rostral-caudally, beginning with the upper right arcade as 1, the upper left as 2, the lower left as 3 and the lower right as 4. Within an arcade, teeth were identified by an alphanumeric couplet consisting of an initial (I, C, P or M) denoting incisor, canine, premolar and molar, respectively, followed by a number corresponding to the position of the tooth within a tooth type; teeth were numbered from 1 for each tooth type within an arcade, progressing rostral-caudally. Teeth were noted in sequence of arcade number, each arcade being separated by a solidus. For example, the upper permanent right first incisor, lower permanent left second premolar and permanent first molar were denoted as 1-I1/3-P2, M1.

The age of the seal was determined as

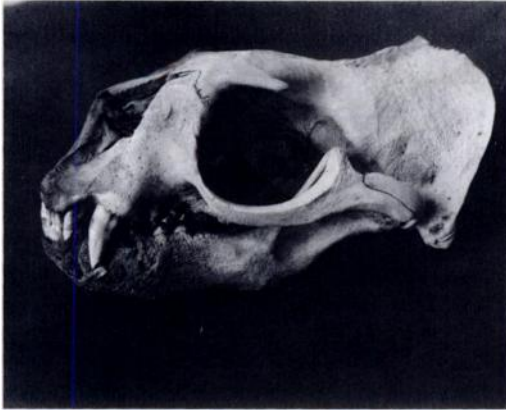


FIGURE 1. Lateral oblique view of the left side of the skull of the injured Antarctic fur seal; note the difference in mandible length.

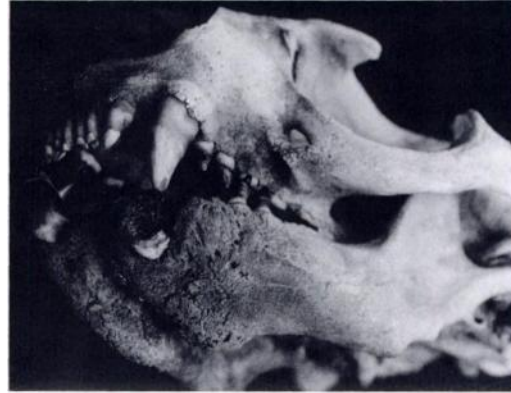


FIGURE 2. Vertical oblique view of the left rostral aspect of the skull of the injured Antarctic fur seal, with porosity of the bony proliferation and the broken root of 3-C1.

9 to 10 yr by counting cementum layers of a premolar tooth in longitudinal sections 150 μm thick (Payne, 1978). We assumed that each dark and light layer corresponded to one year.

The skull (Figs. 1 and 2) had a condylobasal length of 250 mm. The formula of the normal permanent dentition in *Arctocephalus* spp. is I3/2 C1/1 P4/4 M2/1 = 36 (Thenius, 1989). The following teeth had been lost: 1-P3, P4/3-I1, I2, P1, P2, M1/4-I1, I2, P3, P4, and M1. Other teeth were worn heavily, their crowns were deeply stained brown, and there were varying degrees of enamel loss and dentine exposure.

The left and right mandibles were not united at the symphysis (Fig. 2). There was complete loss of both incisor alveoli from the pars incisiva of the right mandible. Tooth 4-P1 was displaced labially. The rostral ventrolateral margin and mental symphyseal surface of the right mandible had a florid proliferation of periosteal new bone. There was a defect in the mesial margin of the alveolus of 4-C1 leading into the remodelled alveolus of 4-I2, and a sinus tract opened to the surface of the mandible immediately ventral to this.

The left mandible was 15 mm shorter than the right owing to remodelling centered on the pars incisiva (Fig. 3). Based on radiography of the associated periosteal

proliferation, we observe alternating layers of dense and rarefied bone (Fig. 4). The two incisor alveoli were missing, and 3-C1 was represented by a fragment of root projecting rostrad from the center of the periosteal proliferation (Fig. 3).

Depressions in the periosteal proliferation of the left mandible on the lingual side of the intact 3-P2, P3 received the crowns of 2-P1, P2, P3. There was extreme periosteal proliferation concentrated over the mental symphysis. There was focal hypertrophy of the ventral margin of the mandible corresponding to part of the insertion of the *musculus digastricus*.

There was irregular periosteal proliferation on the maxilla adjacent to and involving the left infraorbital foramen. The diameter of the bony foramen was re-

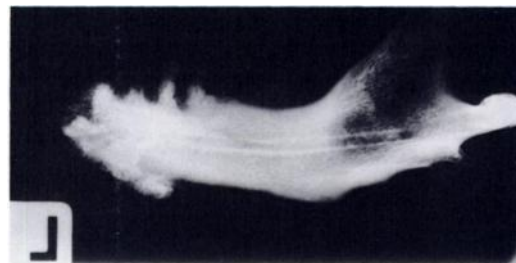

FIGURE 3. Radiograph of the disarticulated mandible of the injured Antarctic fur seal; lateral view of left mandible.

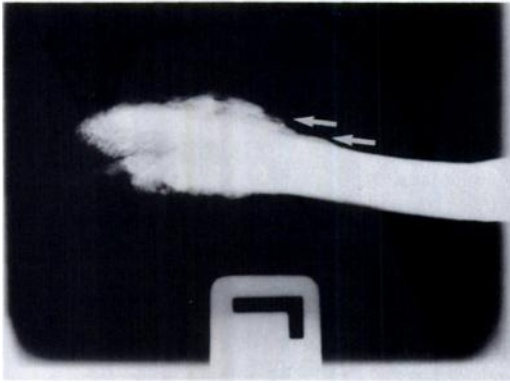


FIGURE 4. Radiograph of the disarticulated mandible of the injured Antarctic fur seal; dorsoventral view of rostral extremity of left mandible. Lamellae of periosteal new bone (arrows) are associated with an inflammatory lesion, although similar onion-ring lesions may be present in neoplasms such as Ewing's sarcoma.

duced to approximately half that of the contralateral foramen. The articular surfaces of the condylar processes of both mandibles had erosions and epiphytic lipping, with corresponding zones of moderate erosion in the mandibular fossae of the temporal bones.

The conclusion from inspecting the skull was that a single traumatic event several months to a year or more before death resulted in the simultaneous fracture of the crown of 3-C1 and luxation of the mental symphysis.

Pathological changes in this skull were dominated by periosteal proliferation associated with severe osteomyelitis in the left mandible, osteomyelitis confined to the pars incisiva of the right mandible and periostitis of the left maxilla. A pulpitis following fracture of the crown of 3-C1 was a likely origin of the osteomyelitis.

The chronic instability of the occlusion resulting from tooth loss and mental symphyseal luxation was highlighted by arthritic changes in both temporomandibular joints.

From the bony lesions, we inferred extensive associated soft tissue pathology. The periostitis involving the left infraorbital foramen would be expected to result

in compressive and inflammatory neuropathy of the left infraorbital nerve. The deep depressions in the left maxilla and mandible that received crowns of the teeth of the ipsilateral dental arcade would have been formed by pressure necrosis as a result of trismus. The chronicity of the condition was emphasized by the significant degree of secondary change caused by infection and trismus following the initial trauma.

At Heard Island, based on many observations in 1992 and 1993, dental damage in live fur seals was mostly restricted to fully mature males (E. Erb, unpubl.). Most commonly, a canine or an ipsilateral pair of canines was damaged, and upper and lower incisors were often involved. Dentition of most juveniles and sub-adults was undamaged.

Several live adult males were seen with orofacial lesions. The damage was often associated with chronic osteomyelitis. Furthermore, there were several cases of dead animals with dental alveolar osteomyelitis without dental or mandibular/maxillary fractures.

A few weeks after finding the skeletal remains at Scholes Lagoon, an old male was observed with a recent fracture of the body of the left mandible and luxation of the mental symphysis. The distal fragment was displaced so that the canine was pointing forwards and standing out like a tusk.

We speculate that biting may have damaged the Scholes Lagoon skull. Although dental enamel is a crystalline structure and easily cleaved when struck (Harvey, 1989), the large size and strength of canine teeth of adult male fur seals must minimize the possibility of their fracture during fighting. Dental crowns fracture during fights between domestic dogs, and occasionally torsion forces on the mandible through the prominent lower canines result in failure of both the dental crown and the mental symphysis (R. Clarke, pers. comm.). The chronic progression of such an injury might have had a similar presentation to the fur seal specimen.

Because tooth and mandibular damage was limited to adult male fur seals, it might be inferred that dental accidents were connected with contests for territory establishment and mating supremacy. But most tournaments of contesting adult males were ritualistic and involved bluff; the small amount of physical contact consisted of well-aimed (and often efficient) slashes at opponents' shoulders or elbows (E. Erb, unpubl.). Similarly, Bonner (1968) reported that most fighting among adult males on breeding beaches at South Georgia consisted of minor skirmishes between neighbors. Baker and Doidge (1984) reported only two animals at South Georgia that died from infected injuries caused by fighting, and Baker and McCann (1989) found that the primary cause of death over two of three consecutive summers was fight wounds. The most frequent sites of these injuries were the foreflippers, and the dorsal half of the neck and chest. There was no evidence in these studies of mortality in adult male Antarctic fur seals that injuries to the head resulted from fighting.

We suggest the reported damage was caused by a traumatic accident to the teeth and mandible. This could be caused by heavy surf through which the animals access and exit the seas. Rocks, boulders and heavy gravel form most of the beaches. Large males were frequently surprised, rolled, and smashed into the rocks by huge seas. It seems likely that massive knocks to the head could have resulted in direct, blunt trauma to the exposed muzzle and teeth. Mandibular symphyseal luxation is a common sequel to facial trauma in other members of the Carnivora, such as domestic cats (Umphlet and Johnson, 1988).

The universal dental notation system was a modification of earlier systems used to map human and animal teeth. It has the advantages of being adaptable to all dentitions, and it does not resort to non-standard characters. Its utility is demonstrated here in identifying concisely individual teeth in a pinniped. The system should be

applied widely in clinical record keeping to enhance communication about oral pathology in zoological medicine.

The life of fur seals on Heard Island is made arduous by frequent dental accidents. More material and further observation is needed to elucidate the relative importance of misadventure and fighting in the etiology of dental and craniofacial pathology in male Antarctic fur seals.

We thank the Director, Australian Antarctic Division for the opportunity to work at Heard Island, Dr. R. Clarke, Dr. D. Middleton and Dr. D. Pemberton for comments on the manuscript, Ms. S. Troy for estimating the seal's age, Dr. D. Lugg for encouragement, and Mr. K. Bell, Dr. E. Norman and Dr. B. O'Donohue for preparing the figures.

LITERATURE CITED

- BAKER, J. R. 1987. Causes of mortality and morbidity in wild juvenile and adult grey seals (*Halichoerus grypus*). *British Veterinary Journal* 143: 203–220.
- , AND D. W. DOIDGE. 1984. Pathology of the Antarctic fur seal (*Arctocephalus gazella*) in South Georgia. *British Veterinary Journal* 140: 210–219.
- , AND T. S. MCCANN. 1989. Pathology and bacteriology of adult male Antarctic fur seals, *Arctocephalus gazella*, dying at Bird Island, South Georgia. *British Veterinary Journal* 145: 263–275.
- BONNER, W. N. 1968. The fur seal of South Georgia. *British Antarctic Survey Scientific Reports* 56: 1–81.
- . 1981. Southern fur seals *Arctocephalus* (Geoffroy Saint-Hilaire and Cuvier, 1826). In *Handbook of marine mammals*, Vol. 1. S. H. Ridgway and R. J. Harrison (eds.). Academic Press, London, United Kingdom, pp. 161–208.
- CARRICK, R., AND S. E. INGHAM. 1962. Studies on the southern elephant seal, *Mirounga leonina* (L.) V. Population dynamics and utilization. *C.S.I.R.O. Wildlife Research* 7: 198–206.
- CAVE, A. J. E., AND W. N. BONNER. 1987. Facial asymmetry in a leopard seal (*Hydrurga leptonyx*). *British Antarctic Survey Bulletin* 75: 67–71.
- HARVEY, C. E. 1989. Oral, dental, pharyngeal and salivary gland disorders. In *Textbook of veterinary internal medicine*. S. J. Ettinger (ed.). W. B. Saunders, Philadelphia, Pennsylvania, pp. 1203–1254.
- KERTESZ, P. 1993. A colour atlas of veterinary den-

- tistry and oral surgery. Wolfe Publishing, London, United Kingdom, 312 pp.
- PAYNE, M. R. 1978. Population size and age determination in the Antarctic fur seal *Arctocephalus gazella*. *Mammal Review* 8: 67-73.
- ROUNSEVELL, D., AND D. PEMBERTON. 1994. The status and seasonal occurrence of leopard seals, *Hydrurga leptonyx*, in Tasmanian waters. *Australian Mammalogy* 17: 97-102.
- SHAUGHNESSY, P. D., AND S. D. GOLDSWORTHY. 1990. Population size and breeding season of the Antarctic fur seal *Arctocephalus gazella* at Heard Island—1987/88. *Marine Mammal Science* 6: 292-304.
- THENIUS, E. 1989. Zähne und Gebiss der Säugetiere. *Handbook of zoology*, Vol. VIII, Mammalia, Part 56. J. Niethammer, H. Schliemann, and D. Starck (eds.). Walter de Gruyter, Berlin, Germany, p. 275.
- UMPHLET, R. C., AND A. L. JOHNSON. 1988. Mandibular fractures in the cat: a retrospective study. *Veterinary Surgery* 17: 333-337.

Received for publication 25 April 1995.