

PATHOLOGY OF MUCORMYCOSIS OF CANE TOADS IN AUSTRALIA

R. Speare,¹ L. Berger,^{1,2} P. O'Shea,³ P. W. Ladds,³ and A. D. Thomas⁴

¹ Department of Public Health and Tropical Medicine, James Cook University, Townsville, Queensland, Australia 4811

² CSIRO Australian Animal Health Laboratory, Geelong, Victoria, Australia 3220

³ Department of Biomedical and Tropical Veterinary Sciences, James Cook University, Townsville, Queensland, Australia 4811

⁴ Oonoonba Veterinary Laboratory, Department of Primary Industries, Oonoonba, Townsville, Queensland, Australia 4811

ABSTRACT: The gross and microscopic pathology of a fungal septicaemia caused by the zygomycete, *Mucor amphibiorum* in 27 free-ranging cane toads, *Bufo marinus*, in Australia is described. Seven of the 27 toads had clinical signs of illness when discovered and five of these seven were moribund. Multiple granulomas were found in many organs, and in massive infections granulomas tended to coalesce. Liver, spleen, kidneys, urinary bladder, heart and lung were most commonly involved, but granulomas also occurred in subcutaneous lymph spaces, skin, gastrointestinal tract, voluntary muscle, bone, cranial cavity and the oral cavity. Single lesions appeared grossly as a lemon coloured nodule ≤ 5 mm in diameter. Histologically, the primary lesion was a granuloma composed of multinucleate giant cells, macrophages, occasional lymphocytes and eosinophils surrounding the distinctive sphaerules of *M. amphibiorum*. Fibroblasts occurred in greater numbers at the periphery and collagen formed a dense fibrous capsule around some nodules. A less common lesion resembled a microabscess and consisted of mononuclear cells, neutrophils and eosinophils surrounded by macrophages. Many of the centrally placed mixed inflammatory cells appeared necrotic. This reaction appeared to be more acute. Both types of lesions sometimes occurred concurrently, but the latter was less common. The pattern of lesions and natural history of *M. amphibiorum* suggested that ingestion of contaminated soil may have been the route of infection.

Key words: *Bufo marinus*, *Mucor amphibiorum*, cane toad, amphibia, fungus, pathology, mucormycosis.

INTRODUCTION

Mucor amphibiorum was first reported as a cause of death in captive anurans in Europe (Frank et al., 1974). In natural and experimental infections it produced a disseminated mycosis (Frank et al., 1974; Frank, 1976). *Mucor amphibiorum* existed in tissues in a unique spherical form, which Frank et al. (1974) called a "sphaerule." The species could not be identified in the original publication, but the fungus was subsequently described (Schipper, 1978) as a new taxon, *M. amphibiorum*. Frank et al. (1974) suspected that the original source of the fungus in the European collections may have been specimens of the green tree frog (*Litoria caerulea*), from Australia. However, the only evidence in favour of this hypothesis was the occurrence of mucormycosis in *L. caerulea* in the captive collections and its apparent absence from Europe.

Recently *M. amphibiorum* has been

found as a pathogen in free-ranging platypus (*Ornithorhynchus anatinus*) in southern Australia (Munday and Peel, 1983; Obendorf et al., 1993) and in free-ranging cane toads (*Bufo marinus*) in northern Australia (Speare et al., 1994). In Australia cane toads are an introduced pest and options for biological control have been reviewed (Speare, 1990). The discovery of *M. amphibiorum* as a natural pathogen of the cane toad postdates Speare's (1990) review of diseases. Frank et al. (1974) gave an incomplete description of the pathological changes associated with *M. amphibiorum* in anurans. They found granulomas with dense connective tissue in liver, spleen, kidney, lung, brain and heart, but gave no other details. This paper gives a comprehensive description of the pathology associated with *M. amphibiorum* in free-ranging cane toads in Australia.

MATERIALS AND METHODS

To obtain the infected toads described here, 3,518 free-ranging toads were necropsied in

the survey of Speare et al. (1994) as well as an additional 72 necropsied at the Australian Animal Health Laboratory (AAHL). The toads examined at AAHL were all wild-caught, and had been kept in captivity for a maximum of 6 mos. All toads were killed by pithing or by injection of pentobarbitone sodium (324 mg/ml) (Lethabarb, Arnolds of Reading Pty. Ltd., Victoria, Australia) into the subcutaneous lymph sinuses or by percutaneous absorption of pentobarbitone. Carcasses were opened along the mid-ventral line, viscera removed and examined grossly for lesions. Samples of tissue for histological examination were preserved in 10% buffered neutral formalin and sections were prepared by routine paraffin embedding and stained with haematoxylin and eosin (HE).

Blocks of tissue for culture were collected aseptically and placed in sterile plastic vials prior to processing. Tissue and intestinal contents were inoculated into Sabouraud's dextrose agar with added penicillin (20 IU/ml) and streptomycin (40 IU/ml) and Mycosel agar with added thiamine (1 µ/ml) either by placement into the agar or spreading by means of an inoculating loop. Plates were incubated at 28 C and checked daily for growth.

Diagnosis of mucormycosis was made by identifying the characteristic sphaerules of *M. amphibiorum* in tissues (Speare et al., 1994) with, in some cases, confirmation by isolation of *M. amphibiorum* in culture (Schipper, 1978; Speare et al., 1994).

For 16 of the 27 toads snout-urostyle length (SU) and weight were available and a condition index (CI) was calculated from cube root of weight (mg) divided by SU (mm). Each of these toads was then graded using CI to determine which percentile they occupied with respect to toads in excellent nutritional condition (R. Speare et al., unpubl. data). Measurements are given as mean ± standard deviation (range).

RESULTS

Twenty seven of the 3,590 free-ranging toads had mucormycosis caused by *M. amphibiorum* (see Speare et al., 1994). The 27 infected toads include three infected toads from AAHL originally wild-caught at Tilpal (22°48'S, 150°8'E), about 80 km north of Rockhampton, Queensland, Australia. Thus, Tilpal is an additional site of this infection to those reported by Speare et al. (1994). The 27 toads consisted of eight males, 17 females and two of unrecorded sex, with an average snout-urostyle

length of 97.1 ± 19.3 mm (49–120 mm) and weight of 108.9 ± 60.3 g (11–253 g). For 16 toads for which both weight and SU were available, average condition index was 0.47 ± 0.03 (0.45–0.55) with 10 toads less than the 5th percentile (63%), 4 between the 5th and 25th percentiles (25%), and one each between the 25th–50th and 50–75th percentiles (6% each) (R. Speare et al., unpubl. data). Seven of the 27 toads had clinical signs and five of these were found in a moribund state. These latter toads were emaciated, incoordinated and reluctant to hop. Two of these five were found in exposed positions in the early morning and showed signs of dehydration, obviously being too weak to return to a hiding place. Three of the moribund toads died within 6 hr of capture. One of these toads had a discharge from an eye with thickening of the eyelid. Another of the symptomatic toads had skin lesions occurring as elevated papules up to 8 mm in diameter, some with ulcerated centres. Twenty of the 27 toads (74%) were clinically normal.

At necropsy, lesions appeared grossly as lemon-coloured nodules ≤5 mm in diameter (Fig. 1). Nodules were multiple in many organs and on serosal surfaces. In some toads nodules coalesced in liver, spleen and kidney to form larger irregularly-shaped masses, although in most larger lesions the primary nodular units could be discerned.

Mucor amphibiorum occurred in tissues as a sphaerule (Fig. 2), a spherical form which contained, in many cases, morphologically similar daughter sphaerules as previously documented (Frank et al., 1974; Frank, 1976; Obendorf et al., 1993; Speare et al., 1994). The walls of sphaerules were eosinophilic and easily seen in HE sections. Size of sphaerules ranged from 4.9–37.2 µm. Detailed descriptions of the sphaerules are given in Speare et al. (1994).

Two types of primary lesion were noted microscopically. The more common was a granuloma composed of epithelioid histi-

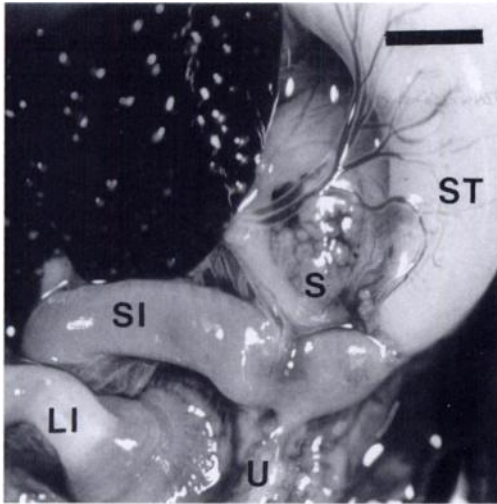


FIGURE 1. Lesions of mucormycosis caused by *M. amphibiorum* in a cane toad. Note the multiple small granulomatous nodules in liver, spleen (S), and urinary bladder (U). The spleen appears as a pale, irregular oval body (largely above the S in the figure) which has been replaced by coalescing nodules. A normal spleen is dark, round and about one third the size of the spleen shown here. Nodules in the urinary bladder appear as small, pale, irregular masses at the site of the U in the figure, above it on the left and largely beside the U on its right. LI, large intestine; SI, small intestine; ST, stomach. H&E. Scale line = 5 mm.

ocytes and fibroblasts with occasional lymphocytes, multinucleate giant cells and eosinophils (Fig. 3). The giant cells were of both Langerhan's type and foreign body type and occasionally contained phagocytosed fungal elements. Fibroblasts occurred in greater numbers at the periphery of granulomas with increased amounts of collagen in some forming a dense fibrous capsule. Nodules ranged in size from 130 to 600 μm (mean 350 μm ; $n = 33$). Larger lesions were formed by coalescence of primary nodules, retained the basic nodular structure, and consisted of multiple adjacent granulomas forming a continuous mass. In the spleen, coalescence of nodules was more common and the boundaries of nodules were more difficult to define; in other organs nodules were generally well demarcated.

The less common lesion also was a gran-

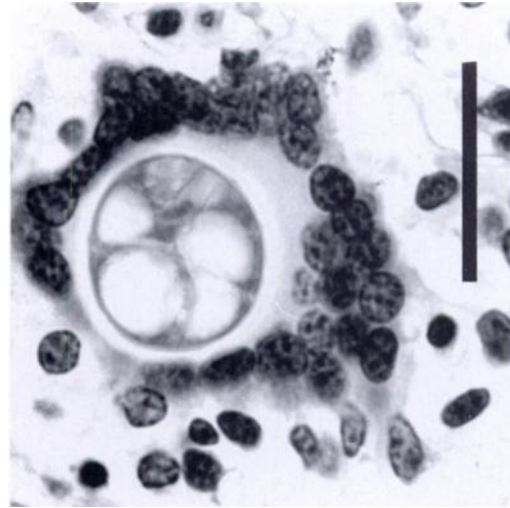


FIGURE 2. Sphaerule of *M. amphibiorum* in the liver of a cane toad. Daughter sphaerules are partly formed in the mother sphaerule. H&E. Scale line = 25 μm .

uloma, but with features of a microabscess. The inflammatory cell population was predominantly mononuclear with scattered neutrophils and eosinophils surrounded by epithelioid histiocytes, fibroblasts and collagen (Fig. 4). Eosinophils also occurred as focal accumulations. The lymphocytes often had a pinkish cytoplasm and in the centre of many of these lesions the inflammatory cells appeared to be necrotic. The histiocytic granuloma and the microabscess occurred concurrently in occasional toads, but the latter response was less common, with none of the toads having only an acute lesion. In all organs, the parenchyma which was not involved by granulation appeared normal.

Aside from occurring within the parenchyma of organs, nodules also were seen as small, pedunculated, roughly spherical masses on serosal surfaces, particularly mesentery, and occasionally on the serosa of spleen, kidney and urinary bladder. These were surrounded by a fibrous capsule attached to the serosa of the underlying organ. Most of these serosal nodules were of the chronic histiocytic type.

All toads had lesions in the liver and

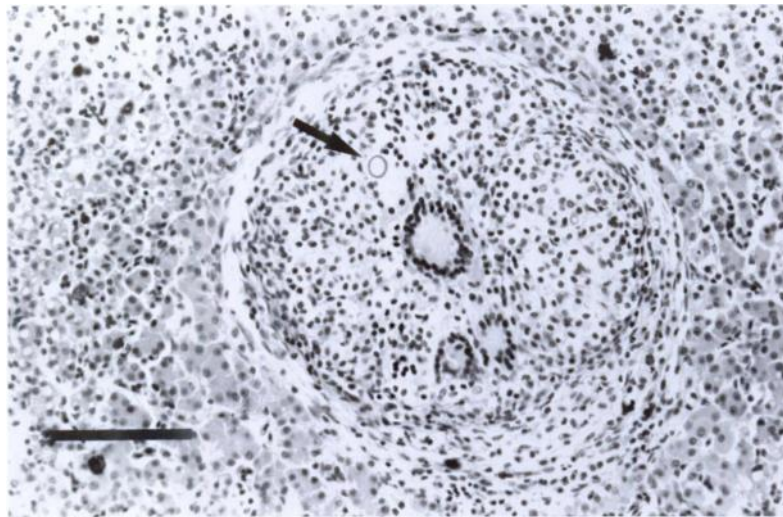


FIGURE 3. Section of liver of a cane toad showing a histiocytic granuloma in response to *M. amphibiorum* consisting of histiocytes and multinucleate giant cells centrally with fibroblasts and collagen peripherally. The arrow marks a sphaerule of *M. amphibiorum*. H&E. Scale line = 100 μ m.

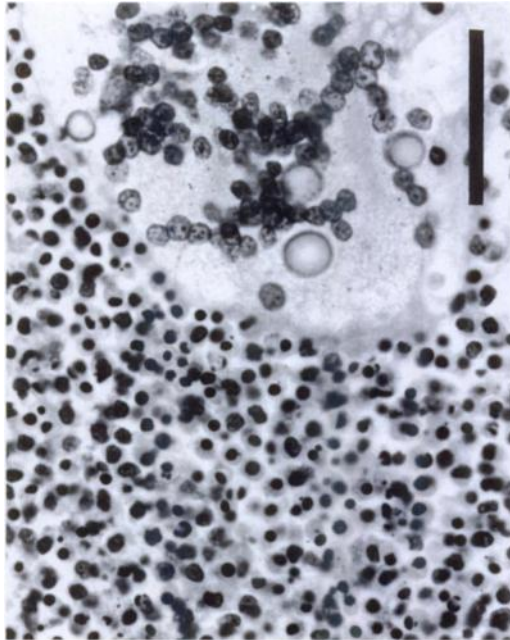


FIGURE 4. Granuloma with mononuclear cells, neutrophils, eosinophils and necrotic debris with sphaerules of *M. amphibiorum* in a multinucleate giant cell from the lung of a cane toad. H&E. Scale line = 50 μ m.

most had lesions in the kidneys, spleen and other organs (Table 1). Lesions involving the urinary bladder were primarily on the serosal surface, although they sometimes extended through the full thickness of the bladder wall. Most lesions in the subcutaneous lymph sinuses were not associated with skin lesions. Large skin lesions were uncommon. They appeared as papules with regular outlines, elevated

TABLE 1. Distribution of histologically confirmed lesions of mucormycosis in organs of free-ranging *Bufo marinus* in northern Australia.

Organ	Number examined	Number positive	Prevalence (%)
Liver	27	27	100
Kidney	27	24	89
Spleen	26	22	85
Lung	27	20	74
Urinary bladder	24	15	63
Heart	27	14	52
Skin	21	9	43
Pancreas	21	10	48
Large intestine	23	11	48
Subcutaneous lymph sinuses	23	7	30
Skeletal muscle	25	8	32
Small intestine	23	4	17
Stomach	24	3	13
Gonads	24	1	4

about 1 to 5 mm above the surface, with central ulceration associated with extensive dermal granulation. Microscopic skin lesions were seen in the stratum spongiosum of the dermis, often in association with blood vessels. None of the microscopic skin lesions found were in the epidermis, suggesting that infection in the skin had commenced in the dermis rather than from an epidermal focus. One toad had lesions in the head which underran the palate, invaded the orbit on one side, and entered the cranial cavity via the optic foramen. Brain lesions were not seen, but there was a localised infiltration of the meninges by histiocytes and lymphocytes. Fungi were not seen inside the cranial cavity.

In all toads the lesions were multifocal. In none of the toads did the infection appear to have arisen from a single focus and expanded centrifugally.

DISCUSSION

This is the first comprehensive description of the histopathology of mucormycosis caused by *M. amphibiorum* in anurans. Previous descriptions have been incomplete and lacked details of the gross pathology and the histopathology (Frank et al., 1974; Frank, 1976). The cellular response is primarily histiocytic with multinucleate giant cell formation. The granulomatous response of the cane toad to *M. amphibiorum* is similar to its response to the fungus *Fonsecaea pedrosoi* reported by Cicmanec et al. (1973). Nodules in chromoblastomycosis consisted of epithelioid histiocytes, mononuclear cells and multinucleate giant cells (Cicmanec et al., 1973). The multinucleate giant cells formed by the cane toad in response to *M. amphibiorum* are of both Langerhan's and foreign body types. This confirms the comment of Elkan and Philpot (1973) that in amphibians both types of multinucleated giant cells occur simultaneously. Elkan and Philpot (1973) described the progression of histiocytic lesions in chromoblastomycosis to tubercles with central necrosis.

The less common nodular lesion in the cane toad with *M. amphibiorum* consisted of mononuclear cells, neutrophils and eosinophils, with occasional necrosis. These lesions had a superficial resemblance to a tubercle with central necrosis. However, caseous necrosis of epithelioid histiocytes was not seen in these cases.

In naturally infected platypus, *M. amphibiorum* caused skin lesions and occasionally a mycotic pneumonitis (Munday and Peel, 1983; Obendorf et al., 1993). Other internal organs were not involved. The histopathological response was of two types; a suppurating to caseating granulomatous response occasionally appearing as microabscesses, or a more diffuse proliferative process involving macrophages, fibroblasts and giant cells with few lymphocytes or plasma cells (Munday and Peel, 1983). In the cane toad similar reactions were seen with the more chronic histiocytic response predominating. The histiocytic response in the toad was usually well demarcated and not diffuse as in the platypus.

The liver was infected by *M. amphibiorum* in all cases involving the toad. In two toads solitary lesions were found only in the liver. Since the liver filters the blood from the hepatic portal system, the fungus probably enters the body via the gastrointestinal tract and is carried by the portal system into the hepatic capillaries. Speare et al. (1994) recovered *M. amphibiorum* from soil at a site where three of these infected toads were found over an 18 mo period. The cane toad commonly ingests soil with its prey (Zug and Zug, 1979) and ingestion of *M. amphibiorum* with soil seems a feasible route of infection.

The route of spread through the body of the toad appears to be both haematogenous, and direct by extension within organs and possibly across body cavities. However, the multicentric distribution of lesions suggests haematogenous spread is predominant.

Fungi reported previously from cane toads have been secondary pathogens in-

fecting only debilitated amphibians (Cicmanec et al., 1973; Speare, 1990). *Mucor amphibiorum* is naturally able to infect toads in good body condition. Measurements were available for 16 of the 27 toads and six of these 16 toads (37.5%) were above the 5th percentile for CI for toads in excellent nutritional condition (R. Speare, unpubl. data). One of these was between the 50th and 75th percentiles in spite of a heavy infection with *M. amphibiorum*. This suggests that *M. amphibiorum* is a virulent pathogen and does not require a debilitated host to establish an infection.

All seven moribund toads were thin. Unfortunately, CI was available for only two of these and both were less than the 5th percentile for CI. Two reasons could account for the emaciation; debilitated toads are more likely to succumb than toads in good body condition, or infection with the fungus is progressive leading to loss of condition and ultimately death. This can only be determined by further experimental studies.

Mucor amphibiorum can infect a range of anurans. It has been reported as a naturally transmitted pathogen in frogs (including captive specimens of the Australian green tree frog, *L. caerulea*), toads and salamanders in captivity (Frank, 1976), and as an experimental pathogen in *Rana esculenta*, *R. temporaria* and *Bufo bufo* (Frank et al., 1974). Slight degrees of infection also were established experimentally in undefined species of lizards (Frank et al., 1974). Mice, rats and guinea pigs did not become experimentally infected (Frank et al., 1974; Frank, 1976). In Australia, *M. amphibiorum* is a pathogen of free-ranging platypus (Munday and Peel, 1983; Obendorf et al., 1993). The host specificity of *M. amphibiorum* is reasonably wide and may include most anurans and some mammals with lower body temperatures. Platypus have a body temperature of 33 to 34 C, about 3 to 5 C lower than most Australian mammals (Grant and Dawson, 1978). Echidnas (*Tachyglossus*

aculeatus) also have low body temperatures (Augee, 1978) and might be at risk of infection. Cane toads, like other anurans, have a body temperature close to the ambient temperature.

The natural history of infection with *M. amphibiorum* is largely unknown. The sphaerules in tissue develop rapidly into hyphae when placed on soil (Speare et al., 1994). Toads probably become infected by ingesting an infectious stage in soil (possibly the sporangiospore), while platypus appear to be infected via the skin (Obendorf et al., 1993). Infected toads can excrete fungus in their feces (Speare et al., 1994) and the location of lesions in skin and bladder suggest that in some toads sphaerules could be excreted through ulcerated skin lesions and/or in urine. Therefore, infected toads could contaminate soil and water.

The distribution of *M. amphibiorum* in Australia is discontinuous since it has been reported only from platypus in Tasmania (Munday and Peel, 1983; Obendorf et al., 1993) and cane toads from 10 locations throughout its range in northern and eastern Australia (Speare et al., 1994; this paper). A key environmental question regarding the epidemiology of this infection is whether the fungus occurs in other locations, particularly whether it occurs on the Australian mainland outside the current range of the cane toad. If it does not, it is possible that the spread of the cane toad will introduce the fungus to new areas and enable it to become established in soil. If this is the case, risk of disease for native amphibians and the platypus may increase as the cane toad spreads north-west in the Northern Territory and south in New South Wales.

ACKNOWLEDGMENTS

This study was funded by the Council of Nature Conservation Ministers, Canberra, Australia. Lee Berger was supported by funds provided by Wet Tropics Management Authority, and by the Department of Environment and Heritage, Queensland. We wish to thank Clem Weller for provision of funds to collect toads in the

Mundubbera area, and C. E. Harrison of Townsville and Bill Freeland of the Conservation Commission of the Northern Territory for providing several specimens. We also thank John Humphrey for performing the necropsies on toads at AAHL.

LITERATURE CITED

- AUGEE, M. L. 1978. Monotremes and the evolution of homeothermy. *Australian Zoologist* 20: 111–119.
- CICMANEC, J. L., D. H. RINGLER, AND E. S. BENEKE. 1973. Spontaneous occurrence and experimental transmission of the fungus, *Fonsecaea pedrosoi*, in the marine toad, *Bufo marinus*. *Laboratory Animal Science* 23: 43–47.
- ELKAN, E., AND C. M. PHILPOT. 1973. Mycotic infections in frogs due to a *Phialophora*-like fungus. *Sabauraudia* 11: 99–105.
- FRANK, W. 1976. Mycotic infections in amphibians and reptiles. In *Proceedings of the Third International Wildlife Disease Conference*, L. A. Page (editor). Plenum Press, New York, pp. 73–88.
- , U. ROESTER, AND H. J. SCHOLER. 1974. Sphaerulen-bildung bei einer *Mucor*-spezies in inneren organen von amphibiien. *Vorläufige mitteilung, Zentrablatt für Bakteriologie und Parasitkunde*, 226: 405–417.
- GRANT, T. R., AND T. J. DAWSON. 1978. Temperature regulation in the platypus, *Ornithorhynchus anatinus*, maintenance of body temperature in air and water. *Physiological Zoology* 51: 1–6.
- MUNDAY, B. L., AND B. F. PEEL. 1983. Severe ulcerative dermatitis in platypus (*Ornithorhynchus anatinus*). *Journal of Wildlife Diseases* 19: 363–365.
- OBENDORF, D. L., B. F. PEEL, AND B. L. MUNDAY. 1993. *Mucor amphibiorum* infection in platypus (*Ornithorhynchus anatinus*) from Tasmania. *Journal of Wildlife Diseases* 29: 485–487.
- SCHIPPER, M. A. A. 1978. On certain species of *Mucor* with a key to all accepted species. *Studies in Mycology* 17: 1–52.
- SPEARE, R. 1990. A review of the diseases of the cane toad, *Bufo marinus*, with comments on biological control. *Australian Wildlife Research* 17: 387–410.
- , A. D. THOMAS, P. O'SHEA, AND W. A. SHIPTON. 1994. *Mucor amphibiorum* in the toad, *Bufo marinus*, in Australia. *Journal of Wildlife Diseases* 30: 399–407.
- ZUG, G. R., AND P. B. ZUG. 1979. The marine toad, *Bufo marinus*: A natural history resume of native populations. *Smithsonian Contributions to Zoology* 284: 1–58.

Received for publication 13 May 1996.