

Lead Toxicosis in a Captive Bottlenose Dolphin (*Tursiops truncatus*) Consequent to Ingestion of Air Gun Pellets

Alan Shlosberg,¹ Michel Bellaiche,¹ Sharon Regev,² Rivka Gal,³ Malka Brizzi,¹ Vera Hanjli,¹ Lilliana Zaidel,⁴ and Abraham Nyska,¹ ¹ Kimron Veterinary Institute, P.O. Box 12, 50250 Bet Dagan, Israel; ² Tel Aviv Dolphinarium, Tel Aviv, Israel; ³ Golda Medical Center, 49372 Petach Tiqva, Israel; ⁴ Wolfson Medical Center, 58100 Holon, Israel

ABSTRACT: A captive bottlenose dolphin (*Tursiops truncatus*) in a dolphinarium in Tel Aviv, Israel, had signs of anorexia, weight loss and a reluctance to train over a 4-week period in June 1995 and died shortly thereafter. On necropsy, it had an enlarged, yellow discolored liver, and about 55 air gun pellets in the second stomach. The pellets were composed of 40% lead. Samples of liver and kidney cortex contained 3.6 and 4.2 µg/g lead, respectively. There was hemosiderosis in the liver and kidneys, status spongiosus in the brain, and vacuolization in the optic nerve; acid-fast intranuclear inclusion bodies were seen in the kidneys. We propose that chronic lead toxicosis had been induced after the gradual dissolution of the lead-based pellets in the acid environment of the stomach.

Key words: Bottlenose dolphin, *Tursiops truncatus*, dolphinarium, air gun pellets, lead, toxicosis.

The health and welfare of dolphins (Family Delphinidae), due to their close association with humans, are of particular concern to marine biologists and conservationists. Bottlenose dolphins (*Tursiops truncatus*) are found in most of the world's oceans; but despite their cosmopolitan distribution and apparent abundance, reports of toxicoses have not been found, even in captive animals (Geraci, 1978). Most reports refer to levels of chlorinated hydrocarbons and metals in tissues of dolphins found moribund or dead (Law et al., 1992; Morris et al., 1989). The exception was a report of an apparent toxicosis, produced by a red tide dinoflagellate (Steidinger, 1989).

Lead is one of the most common causes of toxicoses in humans and domestic animals (Osweiler et al., 1978). We document a case of lead toxicosis in a captive bottlenose dolphin consequent to ingestion of lead-containing air gun pellets.

Two bottlenose dolphins (*Tursiops trun-*

catus) were kept in a dolphinarium in Tel Aviv, Israel (32°04'N, 38°48'E), in artificial sea water, and fed fish sold also for human consumption. On 6 June 1995, a male dolphin weighing 120 kg developed bilateral mydriasis. On ophthalmologic examination, edema of the optic disc was observed in the left eye. The mydriasis resolved after about 10 days, but on 21 June the dolphin was anorectic and reluctant to train. Swabs from the mouth, anus, genital slit, and blowhole were taken for bacteriologic examinations (Carter, 1984) and on several occasions subsequently. Blood was taken several times in the course of the illness and parameters therein (albumen, total protein, alkaline phosphatase (ALP), aspartate aminotransferase (AST), creatine phosphokinase, gamma-glutamyl transferase (GGT), lactic dehydrogenase, calcium, magnesium, sodium, potassium, chloride, phosphorus, cholesterol, total bilirubin, creatine, urea), were determined with a Kodak Ektachem 770XRC (Eastman Kodak Company, Rochester, New York, USA) by A.M.L., Herzliya Medical Center, Israel, and compared with routine tests carried out periodically over the previous 2 yr in the same animal. The condition of the dolphin deteriorated and by 25 June, no food was eaten and all training was refused; force feeding was instigated, but the condition of the dolphin continued to worsen, its body weight fell to 92 kg, and it died on 22 July. The only other specific clinical sign was pruritus, manifested as flank rubbing.

Post mortem examination was performed, and tissues and metallic material in the stomach were analyzed for metal content by furnace atomic absorption

TABLE 1. Some blood parameters in a lead poisoned dolphin before and during the toxicosis.

	Date	RBC ^a	WBC ^b	ALP ^c	AST ^d	GGT ^e	TB ^f
Mean before							
toxicosis	1994–95 ^g	4.12 ± 0.11	6.0 ± 0.79	418 ± 105	442 ± 105	75 ± 14.2	0.43 ± 0.05
During							
toxicosis	June 8	3.7	3.9	190	372	64	0.5
	June 21	4.1	5.5	168	552	94	0.8
	July 3	4.5	10.2	168	554	121	1.2
	July 21	4.5	7.8	122	1,435	182	3.7
Mean during							
toxicosis		4.2 ± 0.2	6.9 ± 1.4	162 ± 29	728 ± 239	115 ± 25	1.6 ± 0.8

^a Red blood cell count ($\times 10^{12}/l$).

^b White blood cell count ($\times 10^9/l$).

^c Alkaline phosphatase (U/l).

^d Aspartate aminotransferase (U/l).

^e Gamma-glutamyl transferase (U/l).

^f Total bilirubin (mg/dl).

^g Mean (\pm SE) of five samplings during 1994–95, prior to toxicosis.

spectrophotometry (Poldosky, 1980); a standard bovine liver sample (Standard reference material 1557b, National Institute of Standards and Technology, Gaithersburg, Maryland, USA) was run simultaneously. Samples of tissues for histopathology were fixed in 10% buffered formalin, embedded in paraffin, sectioned at 4 μ m, and stained with hematoxylin and eosin (H&E) (all tissues, except bones), Perl's Prussian blue for hemosiderin (liver, kidneys and spleen), Ziehl-Neelsen acid-fast stain for the identification of intranuclear inclusion bodies (kidneys and liver), luxol-fast-blue for myelin (optic nerve and

brain tissue), and phosphotungstic acid-hematoxylin stain (optic nerve and brain tissue) (Bancroft and Stevens, 1977).

No anemia was present, but lowered levels of ALP and elevated levels of AST, GGT and total bilirubin were evidence for progressive liver damage (Table 1). For other parameters not detailed (hemoglobin concentration, hematocrit, sodium, potassium, calcium, phosphorus) there were no changes in the sick dolphin from values found before the toxicosis. Even on repeated testing for bacterial pathogens (Carter, 1984), we found no potentially pathogenic organisms.

On post mortem examination, the subcutis and internal fat deposits were severely icteric and edematous. The liver was swollen, yellowish, and friable. In the second stomach, about 55 metallic pellets were found on the surface of the congested mucosa (Fig. 1). The brain meninges were markedly congested and edematous, and the cerebral and cerebellar sulci were flattened. Upon sectioning, the brain tissue was found to be softened, with multiple, dark foci.

There was a marked diffuse hepatocytic fatty vacuolation of the liver. Kupffer's cells were engorged with dark brownish granules which had a hemosiderinic nature

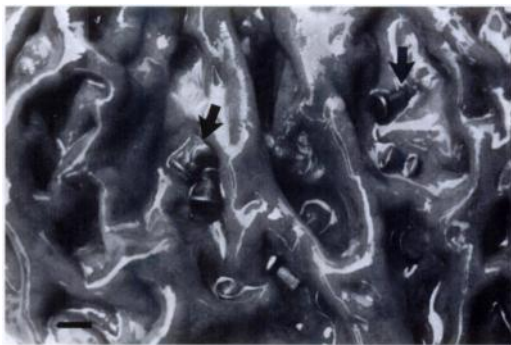

FIGURE 1. Macroscopic appearance of the exposed congested mucosa of the second stomach of a bottlenose dolphin, Tel Aviv, 1995. Note numerous airgun pellets embedded within the mucosal folds (arrows). Bar = 5 mm.

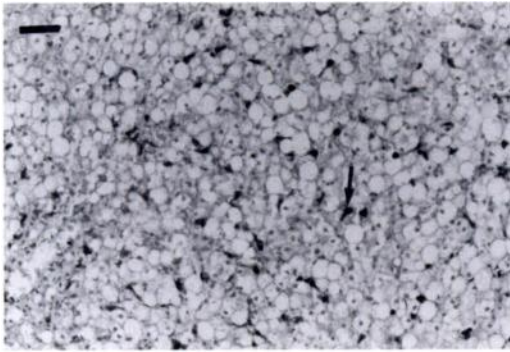


FIGURE 2. Liver tissue of a bottlenose dolphin, with marked fatty degeneration and presence of intracytoplasmic hemosiderin granules within the Kupffer's cells. Perl's Prussian blue. Bar = 50 μ m.

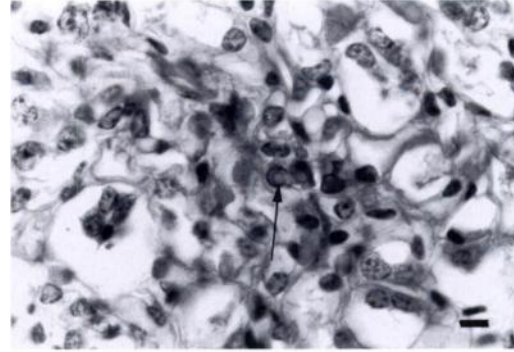


FIGURE 4. Intranuclear inclusion body (arrow) within epithelial medullary tubules of a bottlenose dolphin. Note the enlarged nucleus and its margined chromatin. H&E. Bar = 5 μ m.

on staining (Fig. 2). The spleen had a moderate accumulation of hemosiderin-laden macrophages in the red pulp. In the kidneys, the lining epithelium of the cortical tubules had variably sized, clear vacuolar degeneration with evidence of hydropic change. There were heavy hemosiderin deposits in the cortex (Fig. 3). Several acid-fast intranuclear inclusion bodies were noted in the kidney, mainly in the medullary tubules (Fig. 4). Mucosal congestion and erosions of the superficial lining epithelium of the second stomach were seen. Elongated and narrow intramyelinic vacuoles surrounded the axons in the optic nerve, probably resulting from edematous splitting of the myelin sheath along the intraperiodic line. The axons re-

mained intact and no reactive cells were noted (Fig. 5). The brain had markedly congested meninges and the adjacent superficial cortical layers were finely vacuolated; thus this was an edematous process, most probably resulting from increased vascular permeability (Fig. 6). In the cerebellar and cerebral white matter, long tracts of status spongiosus were evident. Based on the luxol-fast-blue stain, the vacuoles were intramyelinic, without evidence of inflammatory cell reactivity (Figs. 6, 7). The number of cerebellar Purkinje cells was apparently reduced in number, leaving empty spaces. Dispersed degenerating, swollen central chromatolytic neurons were noted in the cerebral cortex.

The liver (wet weight) contained 3.6 μ g/

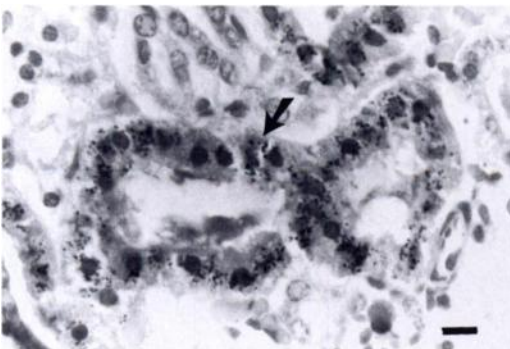


FIGURE 3. Photomicrograph of the renal cortex of a bottlenose dolphin, with marked Perl's Prussian blue-positive granular deposits within the tubular epithelium. Perl's Prussian blue. Bar = 7 μ m.



FIGURE 5. Photomicrograph of the optic nerve of a bottlenose dolphin. Note the long and narrow vacuoles surrounding the axons. Luxol-fast-blue. Bar = 50 μ m.

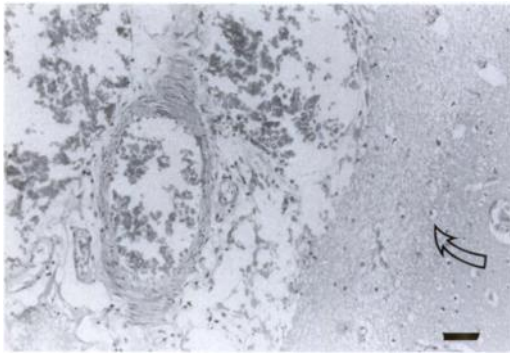


FIGURE 6. Photomicrograph of the meninges of a bottlenose dolphin, with marked vascular congestion and fine vacuolation of the adjacent superficial cortical layers. H&E. Bar = 100 μ m.




FIGURE 7. Photomicrograph of the cerebellar white matter tract vacuolation in a bottlenose dolphin. Luxol-fast-blue. Bar = 50 μ m.

g lead, <0.1 μ g/g cadmium, 1.7 μ g/g mercury, 4.2 μ g/g copper and 31 μ g/g zinc; the concentrations in kidney cortex were 4.3 μ g/g lead, <0.1 μ g/g cadmium, 3.4 μ g/g mercury, 7.3 μ g/g copper and 35 μ g/g zinc. The metallic objects were air gun pellets, weighing about 450 mg each; they contained 40% lead and traces of copper and zinc.

Once lead toxicosis was suspected, the other dolphin in the same pool, an 11 yr old female, was examined for blood lead (Bosnak et al., 1993); a level of 0.2 μ g lead/dl whole blood was found; this was not considered indicative of toxicosis. However, on an X-ray, about 40 pellets were observed in its stomach. This dolphin was treated for lead toxicosis (S. Regev, unpubl.) with penicillamine (Cuprimine, Merck Sharp & Dohme, Canada) 250 mg/kg BW orally, three times daily for 5 days, and the lead pellets were removed by stomach washing using an endoscope; this dolphin has remained healthy, is pregnant and is due to give birth in July 1996.

Lead toxicosis has not been found in domestic or wild animals in Israel during the last 20 yr. Domestic animals are exposed mainly by the ingestion of paint, used motor oil, lead drapery weights, fishing sinkers, or metallic lead (Osweiler et al., 1978). Toxicoses in wild animals have been recorded commonly in surface-feeding waterfowl, consequent to ingestion of lead

shot (Del Bono and Braca, 1973). Metallic lead is poorly absorbed and usually induces toxicity only when a metallic lead body remains in the stomach for a prolonged period of time (George, 1990), slowly dissolves, and causes subacute, or more commonly, a chronic toxicosis (Osweiler et al., 1978).

The data accumulated provide strong evidence that chronic lead toxicosis was the cause of death in the dolphin. A large quantity of lead pellets, some 25 g, was found in the stomach. The concentration of 3.6 μ g/g of lead in the liver is elevated compared with values for the same species of <0.7 μ g/g in four dolphins in the Irish Sea (Law et al., 1992), a mean of 0.23 μ g/g in stranded dolphins in the Atlantic Ocean (Geraci, 1989), and means of 0.18, 0.27 and 0.34 μ g/g, respectively, in three populations compared by Landgraf (1990). Baseline liver levels in dolphins were given as <0.6 μ g/g (Puls, 1994). The lead concentration of 4.3 μ g/g in the kidney is elevated compared with means of 0.03, and 0.15 μ g/g, respectively, in populations compared by Landgraf (1990), and normal levels in dolphins of <1.0 μ g/g (Puls, 1994). The tissue levels of the other metals were not elevated compared with values in other dolphins (Landgraf, 1990; Law et al., 1992).

Clinical signs seen vary with the degree and length of exposure to the lead, and syndromes with acute and subacute ex-

pression are seen, usually manifested in the central nervous and digestive systems, whereas chronic intoxication, as seen in wildfowl for example, has more subtle changes evident only on continuous observation. Such typical signs, depression and total anorexia, were essentially the only clinical signs seen in the dolphin, and are typical of lead toxicosis (Osweiler et al., 1985). In waterfowl, severe cachexia resulting in inanition and death is characteristic (Del Bono and Braca, 1973), and this was the culmination of the toxicosis in the dolphin. The pathological findings in the dolphin resembled those typically described in lead poisoning in other animal species (Osweiler et al., 1978). The clinical signs were probably caused by the lead-induced lesions in the brain.

The source of the lead pellets in the stomachs of the two dolphins is unknown. Malicious intent was ruled out, as it is not generally known that air gun pellets are toxic to animals. It may be that children, as spectators in the dolphinarium, threw the pellets in anticipation of an interplay with the dolphins.

LITERATURE CITED

- BANCROFT, J. D., AND A. S. STEVENS (editors). 1977. The theory and practice of histological techniques. Churchill Livingstone, Edinburgh, Scotland, 436 pp.
- BOSNAK, C. P., D. BRADSHAW, R. HERGENREDER, AND K. KINGSTONE. 1993. Graphite furnace analysis of lead in blood using continuum source background correction. Number 14, Perkin Elmer Corporation, Oak Brook, Illinois, pp. 80–82.
- CARTER, G. R. 1984. Isolation and identification of bacteria from clinical specimens. In Diagnostic procedures: Veterinary bacteriology and mycology. Charles C. Thomas, Springfield, Illinois, pp. 19–39.
- DEL BONO, G., AND G. BRACA. 1973. Lead poisoning in domestic and wild ducks. *Avian Pathology* 3: 195–209.
- GEORGE, L. W. 1990. Diseases of the nervous system. In *Large animal internal medicine*, B. P. Smith (editor). C. V. Mosby Co., St. Louis, Missouri, pp. 956–960.
- GERACI, J. R. 1978. Marine mammals (Cetacea, Pinnipedia, and Sirenia). In *Zoo and wild animal medicine*, M. E. Fowler (editor). W. B. Saunders, Philadelphia, Pennsylvania, pp. 553–610.
- LANDGRAF, W. W. 1990. An investigation into a possible relationship between metals and death loss in dolphins. M.Sc. Thesis, Iowa State University, Ames, Iowa, 99 pp.
- LAW, R. J., B. R. JONES, J. R. BAKER, S. KENNEDY, R. MILNE, AND R. J. MORRIS. 1992. Trace metals in the livers of marine mammals from the Welsh coast and the Irish Sea. *Marine Pollution Bulletin* 24: 296–304.
- MORRIS, R. J., R. J. LAW, C. R. ALLCHIN, C. A. KELLY, AND C. F. FILEMAN. 1989. Metals and organochlorines in dolphins and porpoises of Cardigan Bay, West Wales. *Marine Pollution Bulletin* 20: 512–523.
- OSWEILER, G. D., G. A. VAN GELDER, AND W. B. BUCK. 1978. Epidemiology of lead poisoning in animals. In *Toxicology of heavy metals in the environment, Part 1*, F. W. Oehme (editor). Marcel Dekker Inc., New York, New York, pp. 143–171.
- POLDOSKY, J. E. 1980. Determination of lead and cadmium in fish and clam tissue by atomic absorption spectrometry with a molybdenum and lanthanum treated pyrolytic graphite atomiser. *Analytical Chemistry* 52: 1147–1151.
- PULS, R. 1994. Mineral levels in animal health. *Sherpa International*, Clearbrook, Canada, p. 341.
- STEIDINGER, K. A. 1989. Implications of 1986–87 *Ptychodiscus brevis* red tide and 1987–88 mass bottlenose dolphin mortalities. In *Toxic dinoflagellates and marine mammal mortalities*. Woods Hole Oceanographic Institute, Woods Hole, Massachusetts, pp. 56–65.

Received for publication 9 November 1995.