

Malignant Mast Cell Tumor in an African Hedgehog (*Atelerix albiventris*)

James T. Raymond, M. Randy White, and Evan B. Janovitz, Animal Disease Diagnostic Laboratory, Purdue University, West Lafayette, Indiana 47907, USA

ABSTRACT: In November 1995, a malignant mast cell tumor (mastocytoma) was diagnosed in an adult African hedgehog (*Atelerix albiventris*) from a zoological park (West Lafayette, Indiana, USA). The primary mast cell tumor presented as a firm subcutaneous mass along the ventrum of the neck. Metastasis to the right submandibular lymph node occurred.

Key words: Mast cell tumor, hedgehog, *Atelerix albiventris*, neoplasm.

In September 1995, a 10 mm in diameter, subcutaneous mass was first noted along the ventrum of the neck of an adult (estimated 1 yr of age), female, African hedgehog (*Atelerix albiventris*). The hedgehog was housed at the Columbian Park Zoo, West Lafayette, Indiana (USA) with four other African hedgehogs in an indoor enclosure consisting of a plexiglass front display window, concrete walls, and pine chip bedding. The hedgehogs were fed a daily diet consisting of Nebraska brand Bird of Prey diet (Animal Spectrum, Lincoln, Nebraska, USA) (240 ml per hedgehog), Iams dry cat food (The Iams Company, Dayton, Ohio, USA) (15 ml per hedgehog), diced fruits and vegetables (15 ml per hedgehog), and six beemoth larvae (*Galleria mellonella*).

The mass enlarged to 40 mm in diameter, and in November 1995, the hedgehog was euthanized by intravenous injection of sodium pentobarbital (Euthanasia-6 solution, Vet Labs Limited, Lenexa, Kansas, USA) and submitted to the Animal Disease Diagnostic Laboratory at Purdue University, West Lafayette, Indiana (USA) for routine necropsy. The skin covering the mass had multiple foci of hemorrhage, alopecia and ulceration (Fig. 1). On section, the mass was gray to white, firm, well-circumscribed, but loosely attached to the underlying cutaneous trunci musculature. The only other mass found was a firm, 2

mm in diameter, black nodule that encompassed approximately 75% of the right submandibular lymph node.

Samples of subcutaneous mass, submandibular lymph nodes, brain, heart, lungs, stomach, small intestine, large intestine, liver, spleen, kidney, pancreas, bone marrow, parotid salivary gland, tongue, uterus, and adrenal gland were fixed in 10% neutral buffered formalin, embedded in paraffin, sectioned at 5 μ m, and stained with hematoxylin and eosin (H+E). Select microscopic sections of subcutaneous mass, submandibular lymph node, bone marrow, and spleen were stained with Toluidine blue, Giemsa, and periodic acid-Schiff (PAS) stains (Luna, 1968). Histologically, the subcutaneous mass was a mast cell tumor consisting of sheets and chords of pleomorphic round cells that had singular, round to oval, variably sized, vesicular nuclei with singular nucleoli, and abundant, lightly eosinophilic cytoplasm with distinct cell borders (Fig. 2). With Toluidine blue and Giemsa stains, we observed low numbers of dark blue, variably sized, cytoplasmic granules that were also strongly positive with PAS stain. Scattered throughout the mass were moderate numbers of eosinophils, neutrophils, lymphocytes, and histiocytes. The mass was well circumscribed but not well encapsulated, and had infiltrated the underlying cutaneous trunci musculature. The overlying epidermis was focally acanthotic, hyperkeratotic, and ulcerated.

The mass in the right submandibular lymph node was a metastatic mast cell tumor. Within the splenic red pulp were low numbers of mast cells and extramedullary hematopoiesis. Additional histopathologic findings were bilateral renal infarcts, pul-

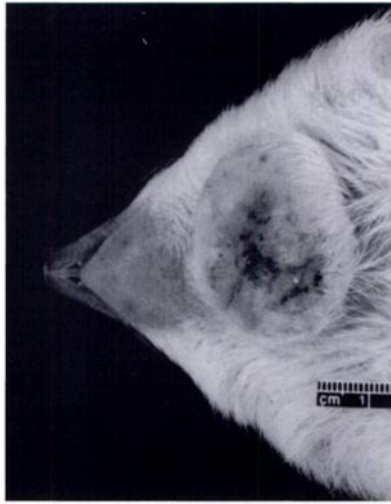


FIGURE 1. Subcutaneous mast cell tumor on the ventral neck of an African hedgehog.

monary edema, and periacinar hepatocellular degeneration.

A sample of formalin-fixed mast cell tumor was cut into 1 mm^3 sections, post-fixed in 1% osmium, embedded in 100% epoxy resin, sectioned, and stained with uranyl acetate and lead citrate. Ultrathin sections were examined using a JEOL 100 CX transmission electron microscope (JEOL Limited, Tokyo, Japan). Ultrastructurally, the cytoplasm of mast cells contained numerous, 0.3 to $1.0 \mu\text{m}$ in diameter, moderately electron dense, finely stippled, membrane-bound granules (Fig. 3).

A paraffin-embedded block containing representative tissue from the neoplasm was deposited in the Registry of Comparative Pathology (The Registry of Comparative Pathology, Armed Forces Institute of Pathology, Washington, D.C., USA, AFIP accession number 2531634).

The light microscopic, histochemical, and ultrastructural features of this neoplasm support a diagnosis of mast cell tumor with metastasis to a local lymph node. Tumors are common in adult African hedgehogs, but very few neoplastic cases have been reported (Frye and Dutra, 1973; Schmidt and Hubbard, 1987; Hruban et al., 1992; Reams and Janovitz, 1992;

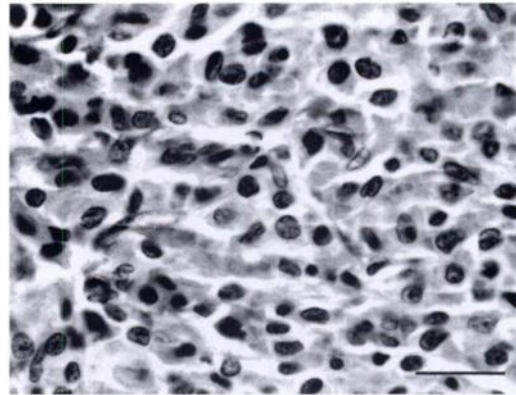


FIGURE 2. Sheets and chords of mast cells from a subcutaneous mast cell tumor in an African hedgehog. HE stain. Bar = $25 \mu\text{m}$.

and Peauroi et al., 1994). We believe this is the first published case of malignant mast cell tumor in an African hedgehog.

In dogs, regional lymph nodes and splenic red pulp are common sites for me-

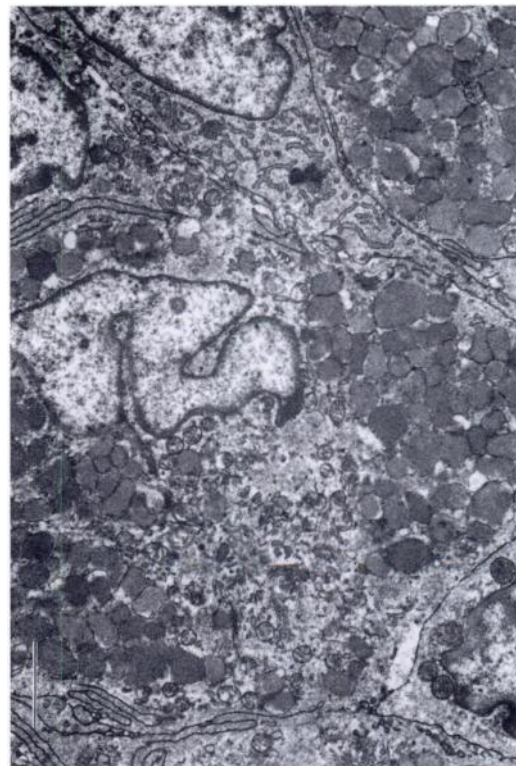


FIGURE 3. Electron micrograph of mast cells with numerous, moderately electron dense, membrane-bound granules. Bar = $2.0 \mu\text{m}$.

tastasis of mast cell tumors (Pulley and Stannard, 1990). In this case, there was histologic evidence of mast cell tumor metastasis to a local lymph node. Although mast cells were present in the spleen of this hedgehog, no discrete metastatic masses were noted, and their histologic presence within the spleen of insectivores may be common as it is in various mouse strains (Percy and Barthold, 1993).

The Tumor Node Metastasis (TNM) classification scheme is widely used for the staging of mast cell tumors (Crow, 1989). Based on the TNM classification system for cutaneous tumors, this mast cell tumor was T₂N₁M₀ (stage two). Gastric and duodenal ulcers, focal glomerulitis, delayed wound healing, and prolonged coagulation are complications associated with mast cell tumors of dogs (Macy, 1985). There was no gross or histologic evidence of these mast cell tumor sequelae in this hedgehog.

We thank Janiece Samman for preparation of histopathology specimens; Sam Royer for technical assistance with photography; Deborah VanHorn and Phyllis Lockard for preparation of electron microscopy specimens; and special thanks to Dr. Kurt Volle and the technical staff at the Columbian Park Zoo for submitting the case. This report was submitted as journal paper no. 14982, Purdue Agricultural Experiment Station, West Lafayette, Indiana.

LITERATURE CITED

- CROW, S. E. 1989. Tumor biology. In Textbook of veterinary internal medicine, 3rd ed., Stephen J. Ettinger (editor). W. B. Saunders Company, Philadelphia, Pennsylvania, pp. 522–523.
- FRYE, F., AND F. DUTRA. 1973. Squamous cell carcinoma of the feet of an Indian hedgehog. *Journal of Wildlife Diseases* 9: 249–250.
- HRUBAN, Z., J. VARDIMAN, T. MEEHAN, F. FRYE, AND W. E. CARTER. 1992. Haematopoietic malignancies in zoo animals. *Journal of Comparative Pathology* 106: 15–24.
- LUNA, L. G. 1968. Manual of histologic staining methods of the Armed Forces Institute of Pathology, 3rd ed. McGraw-Hill Book Company, New York, New York, pp. 158–159, 162–163, 235.
- MACY, D. W. 1985. Canine mast cell tumors. *Veterinary Clinics of North America: Small Animal Practice* 15: 783–803.
- PEAUROI, J. R., L. J. LOWENSTINE, R. J. MUNN, AND D. W. WILSON. 1994. Multicentric skeletal sarcomas associated with probable retrovirus particles in two African hedgehogs (*Atelerix albiventris*). *Veterinary Pathology* 31: 481–484.
- PERCY, D. H., AND S. W. BARTHOLD. 1993. Mouse. In *Pathology of laboratory rodents and rabbits*. Iowa State University Press, Ames, Iowa, pp. 6–7.
- PULLEY, T. L., AND A. A. STANNARD. 1990. Tumors of the skin and soft tissue. In *Tumors in domestic animals*, 3rd ed, J. E. Moulton (editor). University of California Press, Berkeley, California, pp. 38–44.
- REAMS, R. Y., AND E. B. JANOVITZ. 1992. Oronasal squamous cell carcinoma in an African hedgehog (*Erinaceidae albiventris*). *Journal of Wildlife Diseases* 28: 148–150.
- SCHMIDT, R. E., AND G. B. HUBBARD. 1987. Atlas of zoo animal pathology, Vol. 1. Mammals. CRC Press, Inc., Boca Raton, Florida, 241 pp.

Received for publication 4 April 1996.