

Mucormycotic Dermatitis in Captive Adult Wyoming Toads

Sharon K. Taylor,^{1,2,4} Elizabeth S. Williams,¹ A. C. Pier,¹ Kenneth W. Mills,¹ and Mitchell D. Bock,^{3,1} Department of Veterinary Sciences, University of Wyoming, 1174 Snowy Range Road, Laramie, Wyoming 82070, USA; ² Current Address: Florida Game & Fresh Water Fish Commission, 566 Commercial Boulevard, Naples, Florida 34104, USA; ³ Wyoming Game and Fish Department, Sybille Wildlife Research and Conservation Education Unit, Sybille Canyon, Wyoming 82201, USA; Corresponding author (email: staylor@wrl.gfc.state.fl.us).

ABSTRACT: During late May 1995, 50 adult captive endangered Wyoming toads (*Bufo baxteri*) were brought out of hibernation. Approximately 3 to 10 days after hibernation emergence, all toads were hormonally induced to breed, and paired. Each pair was placed in their own breeding tank. Four toads developed clinical signs of disease which included lethargy and multiple (4 to 12) small (2 mm) raised hyperemic nodules with white fuzzy caps on the ventral skin. The condition progressively worsened until death occurred, within 3 to 6 days. Mycotic dermatitis caused by *Mucor* sp. was diagnosed in the four toads through histology and isolation of the organism. This is the first case report of a *Mucor* sp. causing a fatal dermatitis in an amphibian without significant inflammatory response and without systemic involvement.

Key words: Amphibian, *Bufo baxteri*, mortality, *Mucor* sp., mycotic dermatitis, Wyoming toad.

Amphibians frequently inhabit moist soils of the aquatic terrestrial interface (Frye, 1977; Behler and King, 1977; Zug, 1993). This environment provides favorable conditions for a diversity of potentially pathogenic fungi to thrive. However, the literature contains relatively few reports of mycotic dermatitis in amphibians (Reichenbach-Klinke and Elkan, 1965; Taylor et al., 1995). Lethal mycotic infections in mammalian species manifest almost exclusively in those which have undergone severe physical stress, injury, and/or immunosuppression (Rippon, 1982; Koneman and Roberts, 1985; Roberts, 1986; Ajello, 1988). While there has been little research to evaluate potential predisposing factors, most amphibian mycoses also are believed to occur in compromised individuals (Anver and Pond, 1984).

Epizootics involving horizontal transmission of infections in free-ranging juvenile and adult amphibians are extremely

rare. These age classes of animals often live solitary lives and are not as likely to become infected directly from other amphibians. The exception occurs when amphibians congregate near ponds during the breeding season (Anver and Pond, 1984). However, in captive situations, amphibians are often group-housed and horizontal transmission may be more likely to occur.

Mucor spp. are usually considered non-pathogenic and occur worldwide in soil and decaying organic matter (Rippon, 1982; Roberts, 1986). Frequently *Mucor* sp. can be isolated from toads as non-pathogenic contaminants (Taylor et al., 1995). Disease due to *Mucor* sp. are thought to be acquired by inhalation of the spores or from direct inoculation through the skin or tissue by traumatic incident (Ajello, 1988). This organism also has been found in sections of intestinal mucosa and contents.

Speare et al. (1994, 1997) described free-ranging cane toads (*Bufo marinus*) in Australia systemically infected with *Mucor amphibiorum*. Prevalence of infections was 0.71% of 3,518 toads. Grossly, affected toads had granulomas in numerous internal organs but no skin lesions. Histologic examination of the granulomas revealed spherules ranging from 4.9 to 36.4 μm in diameter. Fungal hyphae were not formed. *Mucor amphibiorum* is known to grow well in soil, thus the animals may have become infected when incidentally ingesting soil during feeding. As the cane toad is regarded as an introduced pest animal to Australia, no avenues of treatment were attempted.

Systemic *Mucor* sp. infection also has been observed in a captive White's treefrog (*Pelodytes caerulea*) (Frank, 1975).

White nodules were found on the surface of the liver and spleen. Culture of these nodules yielded an undetermined species of the genus *Mucor*. The organism was experimentally inoculated into common toads (*B. americanus*) which resulted in same disease.

During late May 1995, 50 adult captive endangered Wyoming toads (*Bufo baxteri*) were brought out of hibernation at the Wyoming Game and Fish Department's Sybille Wildlife Research and Conservation Education Unit (Sybille Canyon, Wyoming, USA; 41°44'N, 105°23'W). Toads were housed in groups of six, in glass tanks (101 cm L × 38 cm W × 38 cm H) with pea gravel substrate that allowed areas for dry basking, and areas of graduated water depths up to 5 cm for swimming. The water was filtered biologically, treated chemically, and subjected to UV sterilization. Toads were provided free-choice live crickets (Top Hat Cricket Farm, Kalamazoo, Michigan, USA). The room was on a 16 hr light/8 hr dark cycle, room temperature ranged between 20 to 30 C, and the relative humidity in the room was approximately 40%.

All toads were observed eating on a regular basis and approximately 3 to 10 days after hibernation emergence, all toads were hormonally induced to breed. This was achieved by subcutaneous injection of 1 µg/10 g body weight luteinizing hormone releasing hormone (HRH 4513; Sigma Chemical, St. Louis, Missouri, USA). Toads were then paired and each pair was placed in their own breeding tank. These tanks were identical to those described above, except they were flooded with water to a depth of 5 to 8 cm. Within 8 to 36 hr, the toads were calling and in amplexus. Four toads developed clinical signs of disease after being in amplexus for at least 36 hr. These signs included lethargy and multiple (4 to 12) small (2 mm) raised hyperemic nodules with white fuzzy caps on the ventral skin (Fig. 1). The condition progressively worsened until death occurred, within 6 days.

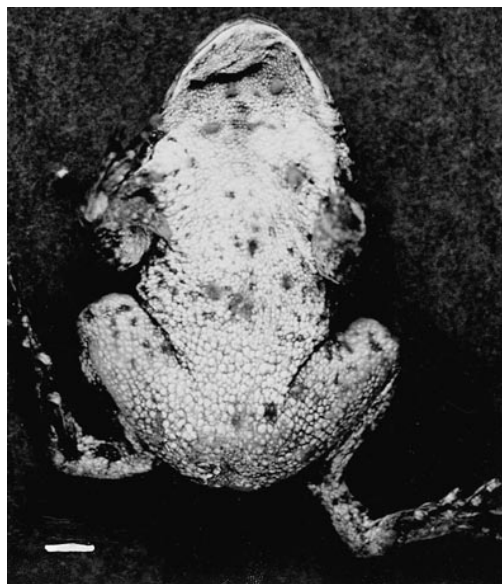

FIGURE 1. Ventral view of a Wyoming toad that died from mucormycotic dermatitis with multiple, small (2 mm), raised hyperemic nodules with white fuzzy caps. Bar = 5 mm.

Dead toads were placed in sterile plastic bags and delivered to the Wyoming State Veterinary Diagnostic Laboratory (Laramie, Wyoming, USA) for postmortem evaluation that same day. Body condition was subjectively evaluated by size of intestinal fat bodies and amount of pericardial fat. Sections of ventral abdominal skin, digits, tongue, gluteus muscle, lung, heart, liver, kidney, stomach, intestine, fat bodies, gonads or oviducts, and abnormal tissues were fixed in 10% buffered formalin, embedded in paraffin, sectioned at 5 to 7 µm, and stained with hematoxylin and eosin. Periodic-acid Schiff (PAS) and Gram's stain (Chandler et al., 1980; Rippon, 1982) were used on sections of skin (Chandler et al., 1980). Tissues were evaluated by light microscopy.

Swabs of ventral abdominal skin, subcutaneous fluid, liver, lung, kidney, and intestine were collected and placed in modified Stuart's bacterial transport medium (S/P Brand Culturette Systems, Baxter Diagnostics, Deerfield, Illinois, USA). These were plated immediately onto Columbia

agar with 5% sheep blood (Acumedia Manufacturing, Inc., Baltimore, Maryland USA). The plates were incubated at 35 C in atmospheric air for 96 hr. Plates were examined for bacterial growth each day. Bacterial isolates were inoculated into a commercial aerobic bacterial identification system which characterizes microbes based on carbon metabolic tests (Biolog Panels, Biolog Inc., Hayward, California, USA).

Fungal cultures were conducted by placing sections of ventral abdominal skin and digits on Sabouraud's dextrose agar slants (Rippon, 1982) and grown at room temperature (22 C) for 1 mo. Isolates were stained with lactophenol cotton blue and identified microscopically by morphology (Rippon, 1982).

All toads were judged to be in good body fat condition. All four toads had 1 piece of pea gravel of 0.5–1 cm in diameter in their stomachs on postmortem evaluation, however no gastric or intestinal lesions were observed. All other internal organs appeared grossly normal. Histologically, the nodules were characterized by numerous uniform fungal hyphae in the epidermis layer of the skin without significant inflammatory reaction (Fig. 2). Sections of other major organs did not demonstrate systemic mycosis. Pure cultures of a morphologically identical *Mucor* sp. were cultured from the skin nodules of all four toads (Fig. 3). The cultures did not morphologically resemble the *M. amphibiorum* identified in cane toads by Speare et al. (1994, 1997). Bacterial cultures revealed mixed isolates of *Pseudomonas aeruginosa*, *Citrobacter freundii*, *Acinetobacter lwoffii*, *Enterobacter cloacae*, *Escherichia coli*, *Klebsiella ozaenae*, *Proteus mirabilis*, *Proteus vulgaris*, and *Serratia liquefaciens*. We were unable to establish a specific bacterial relationship with this disease.

The stress of emergence from hibernation and breeding could have contributed to increased stress and infection by *Mucor* sp. respectively among these animals. The

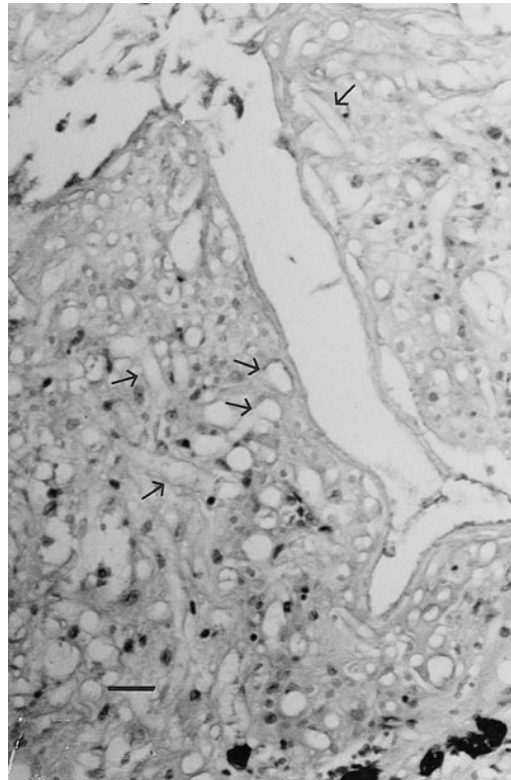


FIGURE 2. Hematoxylin and eosin stained section of a ventral skin nodule from a Wyoming toad that died from mucormycotic dermatitis that demonstrates the uniform hyphae. Bar = 10 μ m.

effect of the hormonal induction to breed could have contributed to increased stress or unknown effects in these toads. Nothing is known about the effect of this hormone on the amphibian immune system. The single injection site was not directly related to the diffuse locations of the ventral nodules. In addition, other Wyoming toads were hormonally induced to breed and did not demonstrate clinical disease.

An acute undetected change in water characteristics in these toad's tanks also could have irritated the toad's skin, and provided an environment for this organism to become pathogenic. Other husbandry factors such as temperature and humidity could also have occurred. However, hundreds of captive Wyoming toads have been maintained in this manner. All four toads had pea gravel in their stomachs on post-

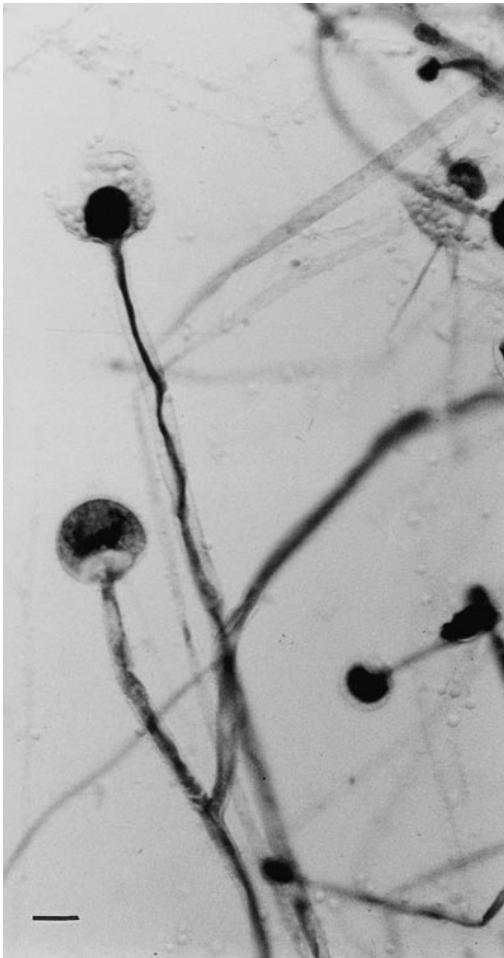


FIGURE 3. *Mucor* sp. that was cultured from a Wyoming toad that died from mucormycotic dermatitis on a wet mount stained with lactophenol cotton blue. Note the uniform branching hyphae and the columella that morphologically are unique to the genus *Mucor*. Bar = 10 μ m.

mortem examination. However, whether the gravel induced an underlying stress and increased mycosis susceptibility is unknown. All four toads were in good body condition, indicating that they had not undergone long term nutritional deprivation. We do believe that the gravel was incidentally ingested by the toads as they were predated on crickets and intentionally being consumed. We elected not to increase stress in the remaining healthy toads by transporting them several hours away to

the nearest facility with radiographic capabilities to evaluate them for ingested pea gravel. Shortly after this epizootic occurred the pea gravel was covered with florists moss to prevent consumption of gravel. Unfortunately this epizootic occurred very rapidly and thus no opportunity for treatment existed. This condition has also not occurred in the 3 yr following the epizootic.

We thank V. Welch, A. Boerger-Fields, and H. Edwards for technical expertise. This research was supported by the United States Fish & Wildlife Service, the Wyoming Game & Fish Department and the Veterinary Science Department, University of Wyoming.

LITERATURE CITED

- AJELLO, L. 1988. Zygomycosis. *In* Laboratory diagnosis of infectious diseases—Principles and practice, A Balows, W. J. Hausler, E. H. Lennette (eds.). Springer-Verlag, New York, New York, pp. 715–722.
- ANVER, M. R., AND C. L. POND. 1984. Biology and diseases of amphibians. *In* Laboratory animal medicine, J. G. Fox, B. J. Cohen, and F. M. Loew (eds.). Academic Press Inc, Orlando, Florida, pp. 427–447.
- BEHLER, J. L., AND F. W. KING. 1977. The Audubon Society field guide to North American reptiles & amphibians. Alfred A. Knopf, Inc., New York, New York, 743 pp.
- CHANDLER, F. W., W. KAPLAN, AND L. AJELLO. 1980. A colour atlas and textbook of the histopathology of mycotic diseases. Wolfe Medical Publications Ltd, Weert, Netherlands, 333 pp.
- FRANK, W. 1975. Mycotic infections in amphibians and reptiles. *In* Wildlife diseases, L. A. Page (ed.). Plenum Press, New York, New York, pp. 73–87.
- FRYE, F. L. 1977. General considerations in the care of captive amphibians. *In* Current veterinary therapy VI small animal practice, R. W. Kirk (ed.). W. B. Saunders, Philadelphia, Pennsylvania, pp. 772–778.
- KONEMAN, E. W., AND G. D. ROBERTS. 1985. Practical laboratory mycology, 3rd Edition. Williams & Wilkins, Baltimore, Maryland, 211 pp.
- REICHENBACH-KLINKE, H., AND E. ELKAN. 1965. Amphibia. *In* The principal diseases of lower vertebrates. Academic Press, New York, New York, 384 pp.
- RIPPON, J. W. 1982. Medical mycology: The pathogenic fungi and the pathogenic actinomycetes.

- W. B. Saunders Company, Philadelphia, Pennsylvania, 842 pp.
- ROBERTS, G. D. 1986. Laboratory methods in basic mycology. In Bailey and Scott's diagnostic microbiology, S. M. Finegold, and E. J. Baron (eds.). The C. V. Mosby Company, St. Louis, Missouri, pp. 678-774.
- SPEARE, R., A. D. THOMAS, P. O'SHEA, AND W. A. SHIPTON. 1994. *Mucor amphibiorum* in the toad, *Bufo marinus*, in Australia. Journal of Wildlife Diseases 30: 399-407.
- , L. BERGER, P. O'SHA, P. W. LADDS, AND A. D. THOMAS. 1997. Pathology of mucormycosis of cane toads in Australia. Journal of Wildlife Diseases 33: 105-111.
- TAYLOR, S. K., E. S. WILLIAMS, K. W. MILLS, A. M. BOERGER-FIELDS, C. J. LYNN, C. E. HEARNE, E. T. THORNE, AND S. J. PISTONO. 1995. A review of causes of mortality and the diagnostic investigation for pathogens of the Wyoming toad (*Bufo hemiophrys baxteri*). United States Fish & Wildlife Service, Cheyenne, Wyoming, 37 pp.
- ZUG, G. R. 1993. Herpetology. Academic Press, Inc., San Diego, California, 527 pp.

Received for publication 21 October 1997.