

CAUSES OF MORBIDITY AND MORTALITY AND THEIR EFFECT ON REPRODUCTIVE SUCCESS IN DOUBLE-CRESTED CORMORANTS FROM SASKATCHEWAN

Thijs Kuiken,¹ Frederick A. Leighton,¹ Gary Wobeser,¹ and Brent Wagner²

¹ Canadian Cooperative Wildlife Health Centre, Department of Veterinary Pathology, Western College of Veterinary Medicine, University of Saskatchewan, 52 Campus Drive, Saskatoon, Saskatchewan S7N 5B4, Canada

² Department of Veterinary Microbiology, Western College of Veterinary Medicine, University of Saskatchewan, 52 Campus Drive, Saskatoon, Saskatchewan S7N 5B4, Canada

ABSTRACT: The objectives of this study were to describe causes of morbidity and mortality in a breeding colony of double-crested cormorants (*Phalacrocorax auritus*) on Doré Lake (Saskatchewan, Canada), and to determine cause-specific mortality rates of juvenile birds. Morbidity and mortality were monitored every third day during the breeding season from 1994 to 1996 from inside a tunnel-and-blind system. Affected eggs and birds were collected for examination and diagnosis. The cause of mortality was determined for 105 eggs, 178 nestlings (≤ 4 -wk-old), 1393 post-nestling chicks (> 4 -wk-old), and 10 adults. The main causes of mortality were infertility or embryonal death, avian predation, displacement of eggs and chicks from the nest, starvation from sibling competition, Newcastle disease, coyote predation, human-induced suffocation, and entrapment. In 49% of the cases, avian predation and displacement from the nest of eggs or nestlings was associated with human disturbance. Thirty-six nestlings, 40 post-nestling chicks, and three adults were examined for the presence of parasites. *Contracaecum spiculigerum* was found in the proventriculus; *Amphimerus elongatus* in the liver; *Piagetiella incomposita* in the gular pouch; *Eidmanniella pellucida*, *Pectinopygus farallonii*, and *Ceratophyllus lari* in the plumage; and *Theromyzon* sp. in the nasal and oral cavity. *Contracaecum spiculigerum* was associated with ulcerative gastritis, *A. elongatus* with multifocal hepatitis and bile duct hyperplasia, and *P. incomposita* with ulcerative stomatitis, but these lesions were not considered fatal. Other diseases included beak deformity, abnormal rotation of the carpal joint, hypopigmentation, and eye loss. Overall mortality of cormorant chicks between hatching and the end of the breeding season varied from 25 to 48%. The most important causes of mortality were Newcastle disease, which killed 21% of hatched chicks in 1995, sibling competition (maximum 12% in 1994), and coyote predation (2% in 1994).

Key words: Double-crested cormorant, morbidity, mortality, Newcastle disease, parasitology, pathology, *Phalacrocorax auritus*, reproductive success.

INTRODUCTION

Little is known about causes of morbidity and mortality in double-crested cormorants (*Phalacrocorax auritus*—hereafter referred to as cormorants), nor about the effects of disease on their survival (Erwin, 1995). Newcastle disease caused high mortality in cormorant chicks in 1990, 1992, and 1995 (Wobeser et al., 1993; Meteyer et al., 1997; Kuiken et al., 1998). However, without estimates of mortality rates from other causes, it was not possible to assess the relative importance of Newcastle disease to these cormorant populations.

The average clutch size of cormorants ranges from 3.0 to 4.3, with a mean hatching success of 49 to 80%. Survival from

hatching to fledging is 77 to 95%, resulting in 1.8 to 2.4 young fledged per nest (Johnsgard, 1993). Van de Veen (1973) estimated first-year mortality at 52%, second-year mortality at 26%, and subsequent year mortality at 15%, based on sightings of cormorants banded as juveniles. Predation by gulls (*Larus* spp.) and corvids (*Corvus* spp.) is considered an important cause of mortality of eggs and nestlings (Johnsgard, 1993). Last-hatched chicks in broods of three or four commonly die of starvation due to non-aggressive sibling competition (Hunt and Evans, 1997). Mortality from Newcastle disease, which generally occurs after chicks have left their nests, was estimated at 10 to 90% of young of the year (Meteyer et al., 1997; Kuiken et al., 1998).

The relative magnitude and importance of different causes of morbidity and mortality during the breeding season have never been studied or analysed. The objectives of this study were to (1) categorize different forms of mortality and disease, describe their clinical signs and lesions, and, where possible, determine their cause, and (2) determine the effect of the causes of mortality on reproductive success.

MATERIALS AND METHODS

Study site

The study site was Island A, a 300 × 100 m island in the south-west part of Doré Lake (Saskatchewan, Canada; 54°46'N, 107°17'W) with ground-nesting colonies of cormorants and American white pelicans (*Pelecanus erythrorhynchos*). Island A is separated by a 250-m-wide shallow water channel from Smith Island, which is 2 × 1.5 km (Kuiken et al., 1998).

Monitoring of reproduction, morbidity, and mortality

Observations were made from within an 88-m-long above-ground tunnel-and-blind (TAB) system visited every third day from 1 June to 1 September from 1994 to 1996 (Kuiken et al., 1997). About 10% of the total nesting area of cormorants was visible from within this system. All cormorant and pelican nests within about 6 m of the TAB system (marked area) were marked with numbered stakes each year in the last week of May. At each visit, the number of eggs and chicks in each marked nest, presence of broken eggs, eggs displaced from the nest, and sick or dead birds were recorded. The location of broken and displaced eggs and carcasses was recorded in relation to the numbered stakes or TAB system to prevent counting them more than once. Whenever possible, displaced eggs and sick or dead birds were collected by hand or by use of a telescopic rod, without leaving the TAB system (Kuiken et al., 1997).

In addition to observations made from inside the TAB system, observations were made and samples were collected each year from outside the TAB system while marking nests, collecting eggs, collecting blood samples from cormorant chicks, collecting cormorant nestlings, surveying Island A for carcasses, and repairing the TAB system.

Nests and carcasses on Island A were counted at the end of the breeding season in August

of each year. Correction for the disappearance of nests after the chicks left them was made by determining the proportion of marked nests that were still visible at the end of the breeding season, and dividing the total number of nests counted on Island A by this proportion.

Reproductive success

Reproductive success was estimated directly instead of by the Mayfield (1975) method, which is poorly suited to situations such as those found on the cormorant colony site, with high visibility of nests, synchrony of nesting, and catastrophic mortality (Johnson and Shaffer, 1990).

Hatching date was recorded as the mid-point between the date when a chick was first seen in a nest and the preceding observation date (3 days previously); when a chick was seen pipping, that date was taken as hatching date. Clutch size was recorded as the maximum number of eggs seen in the nest within the average incubation period, 28 days (Johnsgard, 1993). Brood size was recorded as the maximum number of chicks in the nest within 4 days after the hatching date. Chick mortality between two observations was considered to have occurred at the mid-point of the interval. The number of chicks per nest was counted until 3 wk after hatching, when chicks start leaving the nest (Johnsgard, 1993). Hatching success was calculated as brood size divided by clutch size. Nests with eggs or chicks on previous visits were considered abandoned if nest contents disappeared and no adult birds were present during the period up to 3 wk after hatching. Reproductive success parameters were calculated only for nests from which no eggs or chicks had been collected for other studies, and for which clutch size, hatching date, brood size, and number of chicks surviving to 1, 2, and 3 wk of age were known. The null hypothesis that clutch size and number of 3-wk-old chicks per nest in the marked area were the same among years was tested by one-way ANOVA, followed by the Tukey test (Zar, 1996).

Necropsy

Necropsies followed a standard protocol. Carcasses were classed as fresh, moderately decomposed, or very decomposed. Fresh carcasses had no visible signs of autolysis. Moderately decomposed carcasses were visibly autolyzed, but the internal organs were intact and recognizable, and could be assessed for the presence of lesions. Very decomposed carcasses had internal organs which were discolored, misshapen or ruptured, and difficult to recognize. Car-

casses also were classed as being in good, moderate, or poor body condition. Birds in good body condition had well-developed musculature and visible fat in the coronary groove, intestinal mesentery, and abdominal subcutis. Birds in moderate body condition had moderately developed musculature, visible fat in the coronary groove but not in the intestinal mesentery or abdominal subcutis. Birds in poor body condition had poorly developed musculature and no visible fat in the coronary groove, intestinal mesentery, or abdominal subcutis. Samples for bacteriology were stored in liquid nitrogen, samples for histology were stored in 10% neutral-buffered formalin, and samples for parasite identification were stored in 70% ethanol until further use. Hepatic parasites were dissected free of small pieces of formalin-fixed liver for identification.

Formalin-fixed samples were embedded in paraffin, sectioned at 5 μm , and stained with hematoxylin and eosin (H & E) for examination by light microscopy (Luna, 1968). To quantify liver infection with the trematode *Amphimerus elongatus*, which was not always detectable grossly, liver from all carcasses was examined histologically. Several other tissues from 22 5- to 9-wk-old cormorant chicks with Newcastle disease also were examined for *A. elongatus* infection and are included in this study. Tissues examined in these 22 birds were brain, spinal cord, brachial and lumbosacral plexus, eye, eyelid, bursa of Fabricius, thymus, spleen, femoral bone marrow, esophagus, ventriculus, duodenum, pancreas, liver, jejunum, ileum, cecum, colon, trachea, lung, heart, aorta, pectoral and quadriceps muscle, kidney, thyroid, parathyroid, adrenal gland, uropygial gland, and testis or ovary and oviduct. Tissues were considered infected with *A. elongatus* if sections of adult trematodes, their eggs, or both were detected. The stomachs of 20 of these 22 cormorants were examined histologically for lesions associated with infection by the nematode *Contracaecum spiculigerum*. A selection of lesions evident on gross dissection also was examined histologically.

When gross lesions were suggestive of bacterial infection, samples were cultured on blood agar (Prepared Media Laboratory, Richmond, British Columbia, Canada). The inoculated media were incubated at 37 C in an aerobic atmosphere and examined daily for 2 days for bacterial growth. An isolated colony representative of each bacterial variant detected visually was selected and identified according to methods of Carter and Cole (1990).

Parasites were identified according to Yamaguti (1961) and Sarashina et al. (1987) for nematodes, Boyd and Fry (1971) and Mc-

Donald (1981) for trematodes, Kellogg (1896), Ryan and Price (1969) and Price (1970) for lice, Holland (1951, 1985) for fleas, and Davies (1991) for leeches. Representative adult specimens of parasites were deposited in the Canadian Museum of Nature Parasite Collection (Ottawa, Ontario, Canada). Catalogue numbers are CMNPA1998-0016 (*Amphimerus elongatus*), CMNPA1998-0017 (*Pectinopygus farallonii*), CMNPA1998-0018 (*Eidmanniella pellucida*), CMNPA1998-0019 (*Piagetiella incomposita*), CMNPA1998-0020 (*Ceratophyllus lari*), CMNPA1998-0021 (*Theromyzon* sp.), and CMNPA1998-0022 (*C. spiculigerum*).

Determination of length of incubation, age of embryos, and age of chicks

The length of incubation of eggs was estimated on the basis of the median date of the start of incubation. This was calculated as the median hatching date minus 28 days. Age of embryos was estimated as follows: 0 to 1 day—marginal vein not yet visible grossly (Romanoff, 1960), 2 to 8 days—marginal vein clearly visible as a red ring in the yolk sac and crown-rump length of embryo ≤ 10 mm (Van Scheik, 1985), > 8 days—age was estimated according to criteria provided by Hanbidge and Fox (1996). Age of chicks was estimated on the basis of the median hatching date for that year. Chicks were classed as nestlings (≤ 4 -wk-old) or post-nestling chicks (> 4 -wk-old).

Calculation of mortality rates

Weekly mortality rates for chicks from the marked area were calculated as the number of chicks that died or disappeared during a given week divided by the number of chicks alive at the beginning of that week. For the period up to 3 wk after hatching, mortality was estimated both by calculation and by observation. By calculation, the average disappearance of chicks per nest in a given week was multiplied by the total number of marked nests. By observation, the total number of nestlings of corresponding age observed moribund or dead in the marked area was summed. For the period between 3 wk after hatching and the end of the breeding season, weekly mortality rates from suffocation, predation by coyotes (*Canis latrans*), and Newcastle disease were calculated as the estimated number of cormorant chick carcasses in the whole colony attributable to a given cause divided by the estimated total number of 3-wk-old chicks and the number of weeks over which the carcasses were found. Carcass counts from Newcastle disease and coyote predation were multiplied by two to account for carcass disappearance between death and detection (Kui-

TABLE 1. Number of double-crested cormorant nests on Island A at Doré Lake (Saskatchewan, Canada) from 1994 to 1996.

Year	Marked area		Whole colony site	
	Number marked in May	Proportion visible in August	Number visible in August	Number corrected for disappearance
1994	232	0.51	3,551	6,963
1995	244	0.72	3,219	4,496
1996	189	0.65	1,689	2,619

ken et al., 1998). The mortality rate from suffocation was calculated on the basis of the number of 3-wk-old chicks in the marked area, because only these chicks were considered to have been at risk (see below); mortality rates from Newcastle disease and coyote predation were calculated on the basis of the number of 3-wk-old chicks in the whole colony. The number of 3-wk-old chicks in the marked area was calculated using the mean number of 3-wk-old chicks per nest. The number of 3-wk-old chicks outside the marked area was estimated by extrapolation from data for the marked area, after accounting for abandoned nests; nest abandonment in the marked area was caused mainly by human disturbance (see below), which was largely limited to this area. Overall mortality rates of cormorant chicks from the marked area were calculated as the cumulative calculated mortality from a given cause divided by the estimated number of chicks hatched.

RESULTS

Reproductive success

The number of cormorant nests on Island A in 1996 was about one-third of that

in 1994 (Table 1). Clutch size and number of 3-wk-old chicks per nest was significantly higher in 1994 than in the subsequent 2 yr (Table 2). Nest abandonment ranged from 30 to 40% per year (Table 2), and was spatially and temporally associated with human disturbance due to activities in the marked area and to arrival and departure at the TAB system by canoe (data not shown).

Infertility and embryonal mortality

Eggs failed to hatch because of infertility or pre-hatching mortality due to embryonal death, avian predation, or displacement from the nest (Table 3). In 33 of 79 (42%) eggs, avian predation or displacement from the nest was associated temporally and spatially with human disturbance.

Eggs were considered infertile, or the embryo was considered to have died during incubation, if they had been incubated ≥ 5 wk without hatching. Fourteen of these eggs were examined. All had brown-white to brown-grey shells. Ten eggs had no visible embryo; one of these was fresh, the other nine were decomposed with ruptured yolk sac and foul-smelling contents. Two eggs had embryos, incubated about 13 days and 26 days, with no visible abnormalities. Two eggs had deformed embryos. One of these, incubated about 21 days, had an encephalocele and spina bi-

TABLE 2. Comparison of reproductive success parameters at nests of double-crested cormorants in the marked area on Island A at Doré Lake (Saskatchewan, Canada) from 1994 to 1996.

Year	Total nests	Hatching date	Clutch size ($\bar{X} \pm SD$)	Hatching success (%)	Brood size ($\bar{X} \pm SD$)	Nests abandoned (%)	3-wk-old chicks per nest ($\bar{X} \pm SD$)	
							Including abandoned nests	Excluding abandoned nests
1994	53	20/6 ^a (14/6–23/6)	3.2 \pm 0.7 A ^b	78	2.5 \pm 1.3 A	30	1.6 \pm 1.3 A	2.3 \pm 0.9 A
1995	63	16/6 (13/6–23/6)	2.8 \pm 1.0 B	51	1.4 \pm 1.1 B	35	1.1 \pm 0.9 B	1.6 \pm 0.6 B
1996	53	29/6 (29/6–2/7)	2.4 \pm 0.8 C	60	1.4 \pm 1.1 B	40	1.1 \pm 1.0 B	1.8 \pm 0.6 B
Mean	56		2.8 \pm 0.9	63	1.8 \pm 1.3	35	1.2 \pm 1.1	1.9 \pm 0.8

^a Median date, recorded as day/month (first quartile–third quartile).

^b Tukey multiple comparison test; values with the same letter do not differ significantly, $P > 0.05$.

TABLE 3. Causes of mortality in double-crested cormorants on Island A at Doré Lake (Saskatchewan, Canada) from 1994 to 1996.

Cause of mortality	Embryos (<i>n</i> = 105)	Nest- lings (<i>n</i> = 178)	Post- nest- ling chicks (<i>n</i> = 1393)	Adults (<i>n</i> = 10)
Infertility or embryonal death	26 ^a	— ^b	—	—
Avian predation	6 ^c	29 ^d	0	0
Displacement from nest	73 ^e	107 ^f	—	—
Sibling competition	—	39	0	—
Newcastle disease	0	0	1,041 ^g	0
Coyote predation	0	0	241	5
Suffocation	—	0	61	0
Entrapment	—	1	6	2
Other ^h	0	2	2	0
Undetermined	0	0	42	3

^a Twenty-two eggs had been displaced from the nest.

^b Not relevant.

^c The eggs were taken directly from the nest by a common raven (*n* = 1), California gulls (*n* = 2), and unidentified gulls (*n* = 3), after the nest had been temporarily abandoned by the adult cormorant due to human disturbance.

^d Twenty-six nestlings were killed by herring gulls (*n* = 22) or unidentified gulls (*n* = 4), after the nest was temporarily abandoned by adult cormorant due to human disturbance. Three nestlings were killed or scavenged by a bald eagle.

^e In 27 eggs, displacement was associated temporally and spatially with human disturbance.

^f In 50 nestlings, displacement was associated temporally and spatially with human disturbance.

^g Two of these also had bacterial disease, one caused by *Escherichia coli*, the other by *Salmonella typhimurium*.

^h Abrasion wounds of the head (*n* = 2), back broken by falling branch (*n* = 1), and emaciation of unknown cause (*n* = 1).

fida. The dorsal part of the skull and cervical vertebral column were absent, leaving the dorsal part of cerebrum, cerebellum, and cervical spinal cord exposed. The maxilla (12 mm long) was 6 mm shorter than the mandible and deviated 4 mm to the left, and no eye development was visible. The other, incubated about 19 days, had eyes fused along the medial edges, and the beak was a 2-mm-long stump.

One adult cormorant in its nest was observed trying to roll a displaced egg back into the nest bowl by placing its closed bill beyond the egg and then drawing the head back toward the nest, but this maneuver

was not successful. Nine displaced eggs were examined by necropsy. One had a brown-white egg shell, ruptured yolk sac, no visible embryo and foul-smelling contents, suggesting that it was infertile or that the embryo had died in an early stage of incubation. Six had blue-white egg shells, an intact yolk sac, and fresh contents, and had been incubated 0 to 8 days. Two eggs had embryos, incubated about 16 and 21 days, with multiple petechiae in the skin.

Nestling mortality

Main causes of mortality in nestlings were avian predation, displacement from the nest, and sibling competition (Table 3). In 76 of 136 (56%) nestlings, avian predation or displacement from the nest was associated temporally and spatially with human disturbance. In general, avian predation and displacement from the nest affected all siblings in a nest and led to permanent nest abandonment.

Gulls taking live nestlings pecked them on the back of the rump and head, picked them up and dropped them onto the ground, sometimes after flying up into the air. They gained access to internal organs through a hole pecked in the back of the rump adjacent to the vertebral column. Sometimes, herring gulls (*Larus argentatus*) ate intact nestlings weighing up to about 500 g. When the nestlings were 3 to 4 wk of age, adult cormorants were no longer constantly present at the nest, and nestlings were seen themselves warding off herring gulls.

Necropsies were done on eight nestlings killed by an unidentified gull (*n* = 7) or herring gull (*n* = 1). Seven nestlings had lesions on the back of the rump ranging from subcutaneous hemorrhage to 1.5- to 4-cm-wide holes penetrating the celomic cavity. One nestling had subcutaneous hemorrhage on the back of the head, and another had subdural hemorrhage adjacent to the cerebellum. In carcasses with wounds penetrating into the celomic cavity (*n* = 5), most internal organs were absent

except for the stomach. Nestlings without such wounds ($n = 3$) were in good body condition and had fish remains in the stomach. They had a transverse rupture of the liver adjacent to the edge of the sternum, presumably caused by a gull either pecking at the nestling or dropping it onto the ground. There was extensive hemorrhage around the liver and pale musculature, indicating that the nestlings had exsanguinated from the liver rupture.

An immature bald eagle (*Haliaeetus leucocephalus*) was observed eating 2-wk-old, freshly dead nestlings on three consecutive days. It could not be determined whether this represented predation or scavenging. One or two bald eagles were seen on the colony site on 4 to 12 days each year, either in a tree or on the ground. Movement of the eagles across the colony site caused cormorants below the flight path to fly up from their nests.

Adult cormorants made no attempt to return displaced nestlings into the nest, nor were nestlings seen to be brooded or fed outside the nest. Six displaced nestlings examined by necropsy were in good body condition and had no gross lesions, except congestion of lungs and kidneys in one nestling. Four had fish remains in the stomach.

Nestlings that died from sibling competition came from nests with two ($n = 4$), three ($n = 18$), or four ($n = 11$) chicks. The nest of origin was not determined for the remaining six nestlings. On average, the affected nestlings were estimated to be about 25% of the size of their siblings (range 10 to 100%, $n = 22$). The 15 such nestlings examined by necropsy were in poor body condition, dehydrated, and had no fish remains in their digestive tract. Two had bone fractures. Carcasses retrieved from inside nests ($n = 5$) were flattened and decomposed.

Two 4-wk-old nestlings died with skin abrasions of the head, associated with multifocal suppurative dermatitis and fasciitis and intra-lesional bacteria. One also had a skull fracture with a bone fragment dis-

placed into the cerebrum and associated with multifocal suppurative encephalitis. One 3-wk-old nestling died from entrapment in a monofilament nylon fishing line, which was entangled around its neck and around the branch of a tree.

Post-nestling chick mortality

Main causes of mortality in post-nestling chicks were Newcastle disease, coyote predation, and suffocation (Table 3). An outbreak of Newcastle disease occurred in 1995, and caused mortality in 5- to 10-wk-old chicks (Kuiken et al., 1998). Two of these birds also had bacterial disease: colibacillosis in one (Kuiken et al., 1999), salmonellosis in the other. The heart, liver, and spleen of the latter bird were enlarged and congested with blood. Histologically, there were foci of rod-shaped bacteria and thrombi in blood vessels throughout the body, including cerebrum, lungs, myocardium, spleen, liver, and kidney. *Salmonella typhimurium* was isolated from these tissues.

Coyote predation was detected from 20 August to 14 September 1994. This was the only year when coyotes were heard and their tracks seen on Island A and adjacent Smith Island. Most cormorants killed were 9 to 12 wk of age. Carcasses were found distributed across Island A without any apparent pattern, and in piles of up to 20 carcasses in the vegetation lining the shore. Fourteen such carcasses, examined by necropsy, were in full juvenal plumage, good body condition, and had hemorrhage in subcutis and internal organs. Ten birds had bone fractures, one had a ruptured liver, and another had a ruptured trachea. Seven birds had puncture wounds in the skin with surrounding hemorrhage. The wounds were 3 to 5 mm in diameter and about 10 mm deep. Three birds had three to four wounds 1 to 3 cm apart in a row. Six birds had been partly eaten, with pectoral musculature and overlying skin missing, and a 6- to 10-cm-wide hole in the back of the rump.

Suffocation after human disturbance

TABLE 4. Prevalence of parasite infections in double-crested cormorants on Island A at Doré lake (Saskatchewan, Canada) from 1994 to 1996.

Parasite	Nestlings	Post-nestling chicks	Adults
<i>Contracaecum spiculigerum</i>	72 (26/36) ^a	100 (40/40)	100 (3/3)
<i>Amphimerus elongatus</i> ^b	35 (8/23)	45 (18/40)	0 (0/2)
<i>Eidmanniella pellucida</i> and/or <i>Pectinopygus farallonii</i> ^c	6 (1/17)	51 (19/37)	0 (0/1)
<i>Piagetiella incomposita</i> ^c	6 (1/17)	30 (11/37)	0 (0/1)
<i>Ceratophyllus lari</i> ^c	6 (1/17)	0 (0/37)	0 (0/1)
<i>Theromyzon</i> sp. ^c	0 (0/17)	5 (2/37)	0 (0/1)

^a Percent infected (number of birds infected/number of birds examined).

^b Presence of trematodes was determined by detection of adult trematodes and/or their eggs in the liver by light microscopy.

^c The prevalence of ectoparasites was calculated on the basis of freshly dead carcasses only.

caused death in 5-wk-old chicks, which had been herded together for blood sampling. Ten people herded several hundred chicks into a corner made by the main part and a side-branch of the TAB system. The chicks in the corner climbed on top of each other, and within a few minutes chicks on the bottom had died. Four suffocated chicks examined by necropsy were in good body condition and were partly in juvenile plumage. They had multiple hemorrhages in skeletal musculature, spleen, and/or myocardium, and diffuse acute congestion of the lungs or liver.

Entrapment caused death in six 5- to 10-wk-old chicks in full juvenal plumage. They were found hanging by the neck, mandible, cloaca, prepatagial ligament, or forearm from a branch ($n = 5$) or in between the supports of two adjacent tunnel modules of the TAB system ($n = 1$). One such chick examined by necropsy had no lesions except for severe dehydration. A branch fell on the back of a 7-wk-old chick, which had bilateral leg paralysis, bone fractures, dislocation of the vertebral column, and rupture of the spinal cord, liver, and kidneys.

Adult mortality

Causes of mortality in adults were coyote predation and entrapment (Table 3). Five adults were found dead among post-nestling chicks killed by coyotes (see above), and were also presumed to have

died from this cause. Two adults were found hanging from a branch by the gular pouch or cloaca.

Parasitic diseases

Nematodes (*C. spiculigerum*), lice (*E. pellucida*, *P. farallonii*, *P. incomposita*), a female flea (*C. lari*), and leeches (*Theromyzon* sp.) were found in cormorants examined (Table 4). Trematodes in the liver could not be extracted whole and were identified on the basis of their location as *A. elongatus*. Other parasites were found in the gastro-intestinal tract but were not identified. During observation of the cormorant colony from the TAB system, one breeding adult was observed regurgitating fish remains admixed with live nematodes for its newly-hatched nestlings.

The nematode *C. spiculigerum* was found by gross necropsy mainly in the proventriculus, either attached to the mucosa or loose in the lumen. The prevalence of *C. spiculigerum* in nestlings appeared to increase with age: 2/4 (50%) at 1 wk, 15/21 (71%) at 2 wk, 5/6 (83%) at 3 wk, and 4/5 (80%) at 4 wk of age. Prevalence in post-nestling chicks and adults was 100% (43/43). At least one of the 2-wk-old nestlings was infected with mature *C. spiculigerum*. Grossly, six 5- to 10-wk-old chicks had four to 10 ulcers, 0.1 to 15 mm in diameter and 1 to 2 mm deep, in the proventricular mucosa; one other 8-wk-old chick had multiple hemorrhages, 5 mm in

diameter, in the ventricular mucosa. Histologically, 19 of 20 chicks had a superficial gastritis, characterized by multifocal infiltration of granulocytes, lymphocytes, plasma cells, and macrophages in variable proportions into the lamina propria. The inflammation was closely associated with the presence of nematodes, which penetrated to the bottom of the crypts of the mucus-secreting epithelium and into the lumen of the proventricular glands. Other changes associated with the presence of *C. spiculigerum* in the superficial epithelium included ulceration, hemorrhage into the lamina propria and stomach lumen, and foci of rod-shaped and coccoid bacteria in the damaged epithelium.

The trematode *A. elongatus* and its eggs were found by histology mainly in the liver. However, trematode eggs, similar to those found in the liver, also were found in the kidney ($n = 1$), pancreas ($n = 1$), and gall bladder ($n = 1$). Prevalence of *A. elongatus* infection in nestlings appeared to increase with age: 0/3 (0%) at 1 wk, 3/13 (23%) at 2 wk, 3/4 (75%) at 3 wk, and 2/3 (67%) at 4 wk of age. In some cases, it was not clear where in the liver trematodes and their eggs were located; in other cases, they were clearly free in the liver parenchyma. The inflammatory response around trematodes and foci of eggs varied from a few granulocytes in the adjacent liver parenchyma to a thick wall of macrophages and fibroblasts, admixed with variable numbers of granulocytes, lymphocytes, and foreign body giant cells. Some foci included hemorrhage in the adjacent liver parenchyma. In general, the inflammatory response around trematode eggs was more marked than around trematodes. The liver parenchyma had spaces filled loosely with dissociated hepatocytes, erythrocytes and variable numbers of granulocytes and macrophages; these were probably migration paths of trematodes. Some bile ducts were hyperplastic, contained a few trematode eggs, or both. Four 5- to 7-wk-old chicks with histological evidence of *A. elongatus* infection had gross

liver lesions; these varied from miliary white nodules to contorted tubular white structures, 0.5 mm in diameter and up to 30 mm long, in the liver parenchyma.

The lice *E. pellucida* and *P. farallonii* were collected from the plumage, while *P. incomposita* was collected from inside the gular pouch. Between 1 and 10 *P. incomposita* ($\bar{x} \pm SD = 4.0 \pm 3.3$, $n = 12$) were found per bird. Grossly, the gular pouch mucosa was mildly thickened and roughened. Histologically, the mucosa of one bird had multiple foci of orthokeratotic hyperkeratosis and ulceration. The ulcers had crusts of necrotic cells and coccoid bacteria, and many granulocytes and lymphocytes in the subjacent connective tissue. A cross-section of a louse was present in one ulcer.

Two chicks with Newcastle disease, one found in the water and the other at the water's edge, had about 10 leeches of the genus *Theromyzon* attached to the mucosa of the nasal and oral cavity.

Other diseases

Deformed beaks were observed in five chicks. The first chick was tagged at 1 wk of age, at which time the beak appeared normal. At 2 wk, the maxilla was curved about 180° to the left and deviated slightly downwards. The mandible appeared normal. The deformation became progressively more severe, until, by 8 wk, the maxilla was curved >360° to the left and the tip was pointing forwards. The maxilla touched the left side of the mandible about 1 cm below the left eye, and there was blood on the mandible and gular pouch. The mandible was rotated 10° to the left along the longitudinal axis. At this age, the bird could fly and swim and appeared healthy except for the deformed beak. The second chick was captured alive at 3 wk of age. The maxilla was curved about 80° to the right and about 160° downwards. The mandible was straight and shaped normally, except for a rotation of about 10° to the right along the longitudinal axis, which fitted against the de-

formed maxilla. Except for the deformed beak and a wheezing call, which was different from other nestlings, no abnormalities were detected on clinical examination or gross necropsy of this bird. In the third chick, observed alive at 7 wk of age, the maxilla was curved about 360° downwards, and the mandible was curved about 90° to the right. In the fourth chick, observed alive at 7 wk of age, the maxilla was 0.5 cm shorter than the mandible, and the hook on the maxilla crossed the mandible on the left side. The fifth chick was found dead, in poor body condition, and very decomposed at 10 wk after the median hatching date. About halfway along the maxilla, there was a deviation of about 5° to the left, so that the tip of the maxilla was about 0.5 cm to the left of the mid-sagittal line.

Abnormal rotation of the carpal joint was observed in at least five post-nestling chicks from 6 to 12 wk of age. The abnormality affected the left ($n = 2$), the right ($n = 2$), or both wings ($n = 1$). All affected birds were in good body condition. In resting position, the primary feathers of the affected wing were held horizontal at a 30 to 45° angle to the median plane, with the undersurface of the primary feathers facing upward (Fig. 1). The elbow of the affected wing was held slightly higher than normal and on the contralateral side of the median plane. When the wing was spread, the carpal joint could not be extended more than about 90 to 135°. In the water, the primary feathers of the affected wing dragged through the water and slowed down the bird's progress. The bilaterally affected bird was observed diving, but it was slower than normal, water weeds caught in its wings, and it did not stay under water for longer than about 5 sec. A necropsy was carried out on this bird, a male in good body condition. In resting position of the wing, the right carpal joint was rotated 90° in a clock-wise direction, and the left carpal joint was rotated 90° in a counter-clock-wise direction. Other joints appeared normal.



FIGURE 1. Dorsal view of a 10-wk-old double-crested cormorant with bilateral 90° rotation of the carpal joint. The primary feathers are held at a 30 to 45° angle to the median plane, with the undersurface facing up.

Abnormal coloration of the plumage occurred in one chick, observed several times from 2 to 8 wk of age. As a nestling, it had light gray-brown down, legs and maxilla. In juvenal plumage, throat, neck and breast were whitish, head, wings, and tail were light gray-brown, gular pouch was yellow, and maxilla and legs were brown. In contrast, other nestlings had black down, legs, and maxilla, and other chicks in juvenal plumage had whitish to light-brown breast, and dark-brown head, wings and tail, dark-brown maxilla and black legs. The sibling and parents of this abnormally colored chick had normal coloration.

Absence of one eye occurred in at least three 5- to 10-wk-old chicks. The eye was replaced by pink to brown-black material over which the nictitating membrane could move freely, and the affected birds

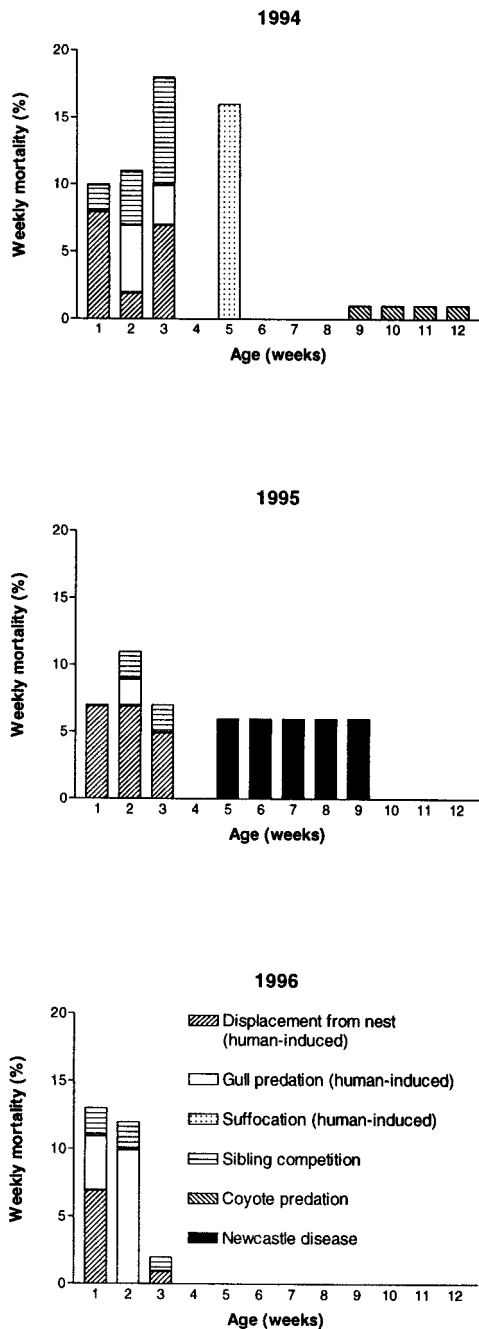


FIGURE 2. Weekly mortality rates in double-crested cormorants in the marked area of Island A at Doré Lake (Saskatchewan, Canada) from 1994 to 1996.

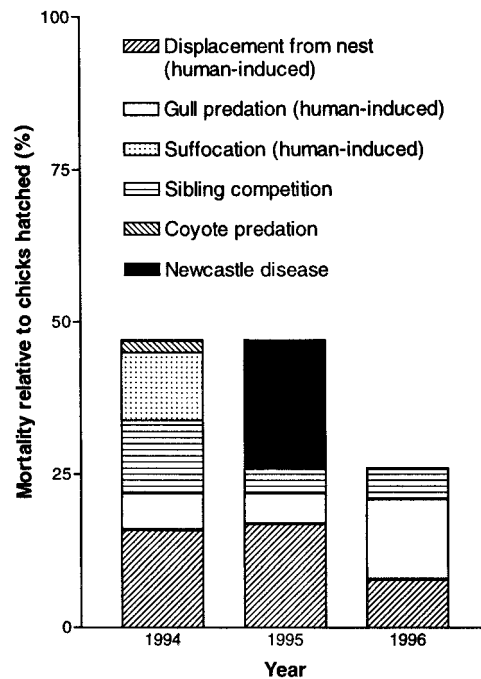


FIGURE 3. Overall mortality in double-crested cormorants from hatching until the end of the breeding season in the marked area of Island A at Doré Lake (Saskatchewan, Canada) from 1994 to 1996. Causes not shown, taken together, accounted for $\leq 1\%$ mortality per year.

showed no evident discomfort or change in behavior.

Mortality rates of cormorant chicks

Mortality in the nestling period in all 3 yr was caused by a similar set of causes, while mortality in the post-nestling period had different causes each year (Fig. 2). The calculated and observed weekly mortality rates were the same except for 2 wk, when observed mortality was six or seven less than the number calculated. The agreement between these two methods indicates that most nestling mortality in the marked area was observed during visits at 3-day intervals.

The most important single cause of mortality of chicks was Newcastle disease, which killed 21% of hatched chicks in 1995, two to 10 times more than coyote predation (2% in 1994) or sibling competition (12% in 1994; Fig. 3).

DISCUSSION

Mortality rates

Newcastle disease was important not only because it caused the highest mortality of cormorant chicks during the study period, but also because it killed chicks that had survived the nestling period. Comparison of survival of cormorant chicks in 1995, when Newcastle disease occurred, and in 1996, when there was no measurable mortality in the post-nestling period, suggests that 20% fewer juvenile cormorants were recruited into the cormorant population of Island A due to mortality from Newcastle disease (Fig. 3). It is not known if higher mortality from Newcastle disease in a given year-class of cormorants is compensated by lower mortality later in life. A long-term study is needed to understand the effects of Newcastle disease on population trends of cormorants. Results of long-term research on other species indicate that ≥ 20 yr of continuous data are required to discover causes of population trends (Potts and Aebischer, 1991; Pelton and Van Manen, 1996).

Starvation from sibling competition occurred each year during the nestling period (Fig. 2) and resulted in 1 to 2% mortality per week, except in the second and third weeks of 1994, when it was 4 to 8%. The higher rate in 1994 probably was related to the significantly larger mean brood size in that year. Mortality from sibling competition occurs at higher rates in nests with larger broods (Hunt and Evans, 1997).

Human-induced avian predation, displacement from the nest, and suffocation resulted in substantial mortality of cormorant chicks from the marked area (Fig. 3). However, these causes of mortality were of limited importance for the reproductive success on a colony-wide basis, because they did not occur elsewhere on the colony site.

Reproductive success

The decrease in clutch size and number of 3-wk-old chicks per nest from 1994 to

1995 (Table 2) may reflect a colony-wide change or a human-induced redistribution of breeding pairs on the colony site. Due to the human disturbance in the marked area, which first occurred in 1994, that part of Island A may have been considered a less desirable nest site in 1995 and 1996, and may have been used by reproductively less successful birds. In other cormorant species, poor nest sites are occupied later in the breeding season by younger, less experienced birds, which have a lower clutch size and fledging success (Potts et al., 1980).

Double-crested cormorants first colonized Island A in 1983 (Hanbidge, 1989). Their number increased until 1994, and then declined rapidly in the next 2 yr. The cause for this decline is unknown.

Causes of mortality

Embryonal deformities and hemorrhages, such as those found in this study, may be produced by a large variety of causes, including mutations, heat, cold, chemical compounds, nutritional deficiencies, and infectious agents (Romanoff, 1972). Ludwig et al. (1996) ascribed similar lesions in cormorant embryos from the Great Lakes to exposure to planar halogenated compounds. However, Doré Lake is remote from direct industrial discharges, and the concentration of these compounds in cormorant eggs from another Saskatchewan colony, 400 km from Doré Lake, was one-sixth of that in cormorant eggs from a Great Lakes colony (Sanderson et al., 1994).

Eggs and nestlings are easily displaced from the nest when adult birds leave hurriedly, because cormorants incubate eggs and brood nestlings up to 1 wk of age on top of their feet (Snow, 1960; Johnsgard, 1993). Displaced eggs or nestlings were not retrieved by their parents and had no chance of survival. Those not taken by predators probably died from exposure or starvation. Cormorant embryos and nestlings up to about 2 wk of age are very susceptible to hyperthermia, and die quickly

from exposure to the sun (Van Scheik, 1985). Nestlings older than 2 wk can effectively maintain homeothermy in the natural environment (Dunn, 1976). However, nestlings from 2 to 4 wk of age may have died of starvation, because they were incapable of climbing into the nest and were not fed by their parents outside the nest. Human disturbance was the only observed cause of hurried departure and subsequent egg or nestling displacement in this study. However, the occasional presence of bald eagles on the colony site probably had the same effect. Drent et al. (1964) considered disturbance by bald eagles to cause most natural loss of cormorant eggs on Mandarte Island (British Columbia, Canada).

Gull predation and nest abandonment as a result of human disturbance have been reported before in cormorant colonies (Kury and Gochfeld, 1975). The level of human activity on the colony site was a compromise between the requirements of different parts of this study. For example, the collection of blood samples and chicks during the nestling period, to study immunology of Newcastle disease (Kuiken et al., 1998), caused substantial disturbance and affected the data on reproductive success shown here.

Sibling competition and avian predation are important causes of nestling mortality (Johnsgard, 1993; Hunt and Evans, 1996), but the associated lesions have not been described previously. Because sibling competition caused substantially different lesions from those caused by avian predation, pathological examination may be used to distinguish between them.

Coyote predation has been recorded previously in colonial waterbirds, e.g., American white pelicans (Dunbar, 1984) and California gulls (*Larus californicus*; Vermeer, 1967), but not in cormorants. The coyotes on Smith Island in summer 1994 probably had reached the island over the ice of the frozen lake in winter and did not try to swim to the nearest mainland, which was about 1 km away. Therefore,

the colony on Island A was likely an important source of food for them. Carcasses partly eaten by coyotes were characterized by loss of pectoral musculature and overlying skin; this was different from carcasses fed upon by gulls, in which only the internal organs were removed through a small hole in the body wall.

Suffocation due to birds crowding or piling up in a corner has been recorded previously in cormorant chicks (Brechtel, 1983) and in domestic poultry (Riddell, 1997). The lesions in poultry, tracheal and pulmonary congestion, are similar to findings in cormorants from this study. After this accident, post-nestling chicks were not herded together for blood sampling. Instead, post-nestling chicks were trapped by leg-pole from within the TAB system, with no mortality of trapped birds and minimal disturbance of surrounding birds (Kuiken et al., 1997).

Most entrapped cormorants were 5 to 10 wk of age, when they were learning to climb trees and to fly (Johnsgard, 1993). In this period, they often were seen slipping off their intended perch, flapping their wings vigorously, and holding on with the hook on the maxilla or with the entire beak before falling to the ground. These activities probably increased the risk of entrapment.

Parasitic diseases

Contracaecum spiculigerum, *A. elongatus*, *E. pellucida*, *P. farallonii*, *P. incomposita*, and *C. lari* have been found in cormorants before (Huizinga, 1971; Pence and Childs, 1972; Threlfall, 1982; Holland, 1985). *Theromyzon* sp. is common in waterfowl (Wobeser, 1997), but has not been reported in cormorants. Infections with *C. spiculigerum*, *A. elongatus*, and *Theromyzon* sp. cause mortality in other species (Obendorf and McColl, 1980; Kingston, 1984; Wobeser, 1997). The parasitic infections of cormorants in this study were not considered to be the primary cause of death, although they may have caused some degree of debilitation.

The prepatent period of the nematode *C. spiculigerum* is not known, but is ≥ 4 wk in other members of the same superfamily (Soulsby, 1982). Therefore, cormorant chicks < 4 wk of age in this study probably did not acquire mature *C. spiculigerum* by eating fish containing encapsulated larvae, which is how fish-eating birds normally become infected with *C. spiculigerum* (Huizinga, 1971). The observation in this study of an adult cormorant feeding fish admixed with live nematodes to newly-hatched chicks indicates that cormorant nestlings acquire mature *C. spiculigerum* in this way, as suggested by Huizinga (1971).

Infections with the trematode *A. elongatus* are obtained by eating fish containing encysted metacercariae. After ingestion, young flukes (postmetacercariae) move quickly up the bile ducts, pancreatic ducts, or both (Kingston, 1984). In contrast to an adult cormorant from Louisiana, which had *A. elongatus* only in the bile ducts (Pence and Childs, 1972), cormorants in this study also had *A. elongatus* free in the liver parenchyma. In addition, trematode eggs were found in the kidney and pancreas, suggesting that *A. elongatus* in the cormorant migrates via the bile duct, pancreatic duct, and ureter to reach these organs. This is supported by the histologic detection of *A. elongatus*-like trematodes in the pancreas of a cormorant chick from another breeding colony on Doré Lake and in the kidney of a cormorant from Florida (T. Kuiken, unpubl. data). However, the trematodes in pancreas and kidney were not identified to species.

The lesions caused by the louse *P. incomposita*, which have not been described before, were similar in appearance, but much less severe, than those found in a juvenile American white pelican infected with the closely related *Piagetrella peralis* (Wobeser et al., 1974).

The flea *C. lari* is very similar to *C. niger*, and is differentiated from it by the more conspicuous frontal tubercle and, in

the female, by the larger abdominal spiracles, all of them with the atrial chamber appearing doubled-up (Holland, 1951, 1985). According to Holland (1985), *C. lari* is a relatively rare species of flea. It was found originally in nests of gulls (*Larus* sp.) in the North-West Territories (Canada), and has been collected from cormorants from Quebec (Canada) and the eastern United States (Holland, 1985).

Leeches of the genus *Theromyzon* were found only in cormorants with Newcastle disease, which probably impaired their ability to remove these parasites by preening. Leeches of this genus can be identified to species by the number of annuli separating the gonopores (Davies, 1991). The number of annuli could not be counted in the leeches from this study, because they were contracted due to fixation in ethanol.

Other diseases

The beak deformities in cormorants in this study were similar to those found in cormorants from the Great Lakes (Fox et al., 1991). The latter were ascribed to exposure to chemicals such as polyhalogenated aromatic hydrocarbons, an unlikely cause for the defect in cormorants in this study, as discussed above for embryonal abnormalities. Beak deformity due to vitamin D deficiency has been reported in cormorant chicks in captivity (Nichols et al., 1983). However, they also had deformed limbs, soft bones, and difficulty in staying upright, in contrast to the affected birds in this study, which appeared otherwise healthy. Whatever the cause of the beak deformities, once affected chicks reached independence from their parents at 9 to 10 wk of age (Johnsgard, 1993), it is questionable whether they were able to obtain enough food to survive.

The abnormal rotation of the carpal joint in some of the cormorants in this study is similar to a disease with a variety of names, including angel wing, slipped wing, and airplane wing (Kear, 1973; Kreeger and Walser, 1984; Ritchie et al., 1994).

Angel wing occurs in young waterfowl when the weight of the rapidly growing flight feathers on the manus is insufficiently supported by the non-rigid bones of the wing. The manus twists outwards, and remains in that position after the bones are ossified. It has been reported in domestic and wild waterfowl fed by humans, and has been associated with overfeeding, an unbalanced diet, including an excessive level of protein, and deficiencies in calcium, manganese, and vitamin D. It is found in rapidly growing birds, and occurs more frequently in male birds, in the larger individuals of a brood, and during warm weather, when energy otherwise used to maintain body temperature may be used for growth. The only report of an angel-wing-like disease in wild birds not fed by humans is in American white pelicans (Drew and Kreeger, 1986). A possible explanation for this disease in cormorants in the wild is very rapid growth. Such growth is most likely to occur in older chicks in the brood, in broods with parents superior in fishing skill, and in years of mild weather and abundant food supply (Dunn, 1976; DesGranges, 1982).

The abnormal coloration in the cormorant in this study was probably hypopigmentation or hypomelanism, an abnormally diminished pigmentation resulting from decreased melanin production (Taylor, 1988). Albino or partial albino cormorants have been reported previously (Ross, 1963). In chickens, several mutations occur which dilute eumelanin, the pigment of black or blue feathers. Black Australorp chickens have an autosomal recessive mutation which dilutes the black pigment to a light to dark brownish-grey (Smyth, 1990), similar in appearance to the hypopigmented cormorant in this study.

Absence of one eye was seen at 5 to 10 wk of age. During this period, chicks wander around the island and have a high rate of interaction with other chicks and adults, often pecking at each other (Lewis, 1929). Eye loss may have occurred as a result of

strikes with the hooked beak during such interactions.

ACKNOWLEDGMENTS

This project was supported by the Canadian Co-operative Wildlife Health Centre, Wildlife Health Fund of the Western College of Veterinary Medicine, Canadian Wildlife Service (Environment Canada), Canadian Food Inspection Agency, Saskatchewan Environment and Resource Management, Animal Health Trust of Canada, Alberta Sports, Recreation, Parks and Wildlife Foundation, and University of Saskatchewan. We thank the Diagnostic Bacteriology Laboratory of the Western College of Veterinary Medicine for isolation of bacteria and K. Caspell for preparing the figures.

LITERATURE CITED

- BOYD, E. M., AND A. E. FRY. 1971. Metazoan parasites of the eastern belted kingfisher, *Megaceryle alcyon alcyon*. *The Journal of Parasitology* 57: 150–156.
- BRECHTEL, S. H. 1983. The reproductive ecology of double-crested cormorants in southern Alberta. M.Sc. Thesis, University of Alberta, Edmonton, Alberta, Canada, 119 pp.
- CARTER, G. R., AND J. R. COLE, JR. (EDITORS). 1990. Diagnostic procedures in veterinary bacteriology and mycology. 5th Edition. Academic Press, San Diego, California, 620 pp.
- DAVIES, R. 1991. Annelida: leeches, polychaetes, and acanthobdellids. In *Ecology and classification of North American freshwater invertebrates*, J. H. Thorp and A. P. Covich (eds.). Academic Press, San Diego, California, pp. 437–479.
- DESGRANGES, J.-L. 1982. Weight growth of young double-crested cormorants in the St. Lawrence Estuary, Quebec. *Colonial Waterbirds* 5: 79–86.
- DRENT, R., G. F. VAN TETS, F. TOMPA, AND K. VERMEER. 1964. The breeding birds of Mandarte Island, British Columbia. *Canadian Field-Naturalist* 78: 208–263.
- DREW, M. L., AND T. J. KREEGER. 1986. Skeletal abnormalities in wings of free-flying juvenile white pelicans (*Pelecanus erythrorhynchos*) in Minnesota. *Journal of Wildlife Diseases* 22: 447–449.
- DUNBAR, D. L. 1984. The breeding ecology and management of white pelicans at Stum Lake, British Columbia. Fish and Wildlife Report R-6. Wildlife Branch, Ministry of Environment, Surrey, British Columbia, Canada, 85 pp.
- DUNN, E. H. 1976. Development of endothermy and existence energy expenditure of nestling double-crested cormorants. *Condor* 78: 350–356.
- ERWIN, R. M. 1995. The ecology of cormorants: some research needs and recommendations. Co-

- lonial Waterbirds 18 (Special Publication 1): 240–246.
- FOX, G. A., B. COLLINS, E. HAYAKAWA, D. V. WESELOH, J. P. LUDWIG, T. J. KUBIAK, AND T. C. ERDMAN. 1991. Reproductive outcomes in colonial fish-eating birds: a biomarker for developmental toxicants in Great Lakes food chains. II. Spatial variation in the occurrence and prevalence of bill defects in young double-crested cormorants in the Great Lakes, 1979–1987. *Journal of Great Lakes Research* 17: 158–167.
- HANBIDGE, B. A. 1989. Diet, growth, and reproductive success of double-crested cormorants (*Phalacrocorax auritus*) at Doré Lake, Saskatchewan. M.Sc. Thesis, University of Saskatchewan, Saskatoon, Saskatchewan, Canada, 115 pp.
- , AND G. A. FOX. 1996. Egg characteristics, growth and developmental landmarks of known-age embryos of double-crested cormorants from Manitoba. *Colonial Waterbirds* 19: 139–142.
- HOLLAND, G. P. 1951. Notes on some bird fleas, with the description of a new species of *Ceratophyllus*, and a key to the bird fleas known from Canada (Siphonaptera; Ceratophyllidae). *Canadian Entomologist* 83: 281–289.
- . 1985. The fleas of Canada, Alaska, and Greenland (Siphonaptera). *Memoirs of the Entomological Society of Canada* 130. Entomological Society of Canada, Ottawa, Ontario, 631 pp.
- HUIZINGA, H. W. 1971. Contracaeciasis in pelicaniform birds. *Journal of Wildlife Diseases* 7: 198–204.
- HUNT, J. D., AND R. M. EVANS. 1997. Brood reduction and the insurance-egg hypothesis in double-crested cormorants. *Colonial Waterbirds* 20: 485–491.
- JOHNSGARD, P. A. 1993. Cormorants, darters, and pelicans of the world. Smithsonian Institution Press, Washington, D.C., 445 pp.
- JOHNSON, D. H., AND T. L. SHAFFER. 1990. Estimating nest success: when Mayfield wins. *Auk* 107: 595–600.
- KEAR, J. 1973. Notes on the nutrition of young waterfowl, with special reference to slipped-wing. *International Zoo Yearbook* 13: 97–100.
- KELLOGG, V. L. 1896. New Mallophaga I. Proceedings of the California Academy of Sciences 6: 31–168.
- KINGSTON, N. 1984. Trematodes. In *Diseases of poultry*, 8th Edition, M. S. Hofstad, H. J. Barnes, B. W. Calnek, W. M. Reid, and H. W. Yoder, Jr. (eds.). Iowa State University Press, Ames, Iowa, pp. 668–690.
- KREEGER, T. J., AND M. M. WALSER. 1984. Carpo-metacarpal deformity in giant Canada geese (*Branta canadensis maxima* Delacour). *Journal of Wildlife Diseases* 20: 245–248.
- KUIKEN, T., F. A. LEIGHTON, G. WOBESER, K. L. DANESIK, J. RIVA, AND R. A. HECKERT. 1998. An epidemic of Newcastle disease in double-crested cormorants from Saskatchewan. *Journal of Wildlife Diseases* 34: 457–471.
- , G. WOBESER, F. A. LEIGHTON, D. M. HAINES, B. CHELACK, J. BOGDAN, L. HASSARD, R. A. HECKERT, AND J. RIVA. 1999. Pathology of Newcastle disease in double-crested cormorants from Saskatchewan, with comparison of diagnostic methods. *Journal of Wildlife Diseases* 35: 8–23.
- , G. WOBESER, F. A. LEIGHTON, I. SHIRLEY, AND L. BROWN. 1997. A modular tunnel-and-blind system to reduce investigator disturbance of breeding colonial waterbirds. *Colonial Waterbirds* 20: 532–536.
- KURY, C. R. AND M. GOCHFELD. 1975. Human interference and gull predation in cormorant colonies. *Biological Conservation* 8: 23–34.
- LEWIS, H. F. 1929. The natural history of the double-crested cormorant (*Phalacrocorax auritus auritus* (Lesson)). Ph.D. Thesis, Cornell University, Ithaca, New York, 94 pp.
- LUDWIG, J. P., H. KURITA-MATSUBA, H. J. AUMAN, M. E. LUDWIG, C. L. SUMMER, J. P. GIESY, D. E. TILLITT, AND P. D. JONES. 1996. Deformities, PCBs, and TCDD-equivalents in double-crested cormorants (*Phalacrocorax auritus*) and Caspian terns (*Hydroprogne caspia*) of the Upper Great Lakes 1986–1991: testing a cause-effect hypothesis. *Journal of Great Lakes Research* 22: 172–197.
- LUNA, L. G. (Editor). 1968. *Manual of histologic staining methods of the Armed Forces Institute of Pathology*, 3rd Edition. McGraw-Hill Book Company, New York, New York, 258 pp.
- MAYFIELD, H. F. 1975. Suggestions for calculating nest success. *Wilson Bulletin* 87: 456–466.
- MCDONALD, M. E. 1981. Key to trematodes reported in waterfowl. Resource Publication 142. Fish and Wildlife Service, United States Department of the Interior, Washington, D. C., 156 pp.
- METEYER, C. U., D. E. DOCHERTY, L. C. GLASER, J. C. FRANSON, D. A. SENNE, AND R. DUNCAN. 1997. Diagnostic findings in the 1992 epornitic of neurotropic velogenic Newcastle disease in double-crested cormorants from the upper mid-western United States. *Avian Diseases* 41: 171–180.
- NICHOLS, D., R. J. MONTALI, C. PICKETT, AND C. BUSH. 1983. Ricketts in double-crested cormorants (*Phalacrocorax auritus*). *Journal of Zoo Animal Medicine* 14: 115–124.
- OBENDORF, D. L., AND K. MCCOLL. 1980. Mortality in little penguins (*Eudyptula minor*) along the coast of Victoria, Australia. *Journal of Wildlife Diseases* 16: 251–259.
- PELTON, M. R., AND F. T. VAN MANEN. 1996. Benefits and pitfalls of long-term research: A case study of black bears in Great Smoky Mountains National Park. *Wildlife Society Bulletin* 24: 443–450.

- PENCE, D. B., AND G. E. CHILDS. 1972. Pathology of *Amphimerus elongatus* (Digenea: Opisthorchiidae) in the liver of the double-crested cormorant. *Journal of Wildlife Diseases* 8: 221–224.
- POTTS, G. R., AND N. J. AEBISCHER. 1991. Modelling the population dynamics of the grey partridge: conservation and management. *In* Bird population studies: Relevance to conservation and management, C. M. Perrins, J.-D. Lebreton, and G. J. M. Hirons (eds.). Oxford University Press, Oxford, UK, pp. 373–390.
- , J. C. COULSON, AND I. R. DEANS. 1980. Population dynamics and breeding success of the shag, *Phalacrocorax aristotelis*, on the Farn Islands, Northumberland. *Journal of Animal Ecology* 49: 465–484.
- PRICE, R. D. 1970. The *Piagetiella* (Mallophaga: Menoponidae) of the Pelecaniformes. *The Canadian Entomologist* 102: 389–404.
- RIDDELL, C. 1997. Developmental, metabolic, and other noninfectious disorders. *In* Diseases of poultry, 10th Edition. B. W. Calnek, H. J. Barnes, C. W. Beard, L. R. McDougald, and Y. M. Saif (eds.). Iowa State University Press, Ames, Iowa, pp. 913–950.
- RITCHIE, B. W., G. J. HARRISON, AND L. R. HARRISON. 1994. Avian medicine: Principles and application. Wingers Publishing, Lake Worth, Florida, 1384 pp.
- ROMANOFF, A. L. 1960. The avian embryo: Structural and functional development. Macmillan Company, New York, New York, 1305 pp.
- . 1972. Pathogenesis of the avian embryo. Wiley-Interscience, New York, New York, 476 pp.
- ROSS, C. C. 1963. Albinism among North American birds. *Cassina* 47: 2–21.
- RYAN, S. O., AND R. D. PRICE. 1969. A review of the genus *Eidmanniella* (Mallophaga: Menoponidae) from the Pelecaniformes. *Annals of the Entomological Society of America* 62: 815–823.
- SANDERSON, J. T., R. J. NORSTROM, J. E. ELLIOTT, L. E. HART, K. M. CHENG, AND G. D. BELLWARD. 1994. Biological effects of polychlorinated dibenzo-*p*-dioxins, dibenzofurans, and biphenyls in double-crested cormorant chicks (*Phalacrocorax auritus*). *Journal of Toxicology and Environmental Health* 41: 247–265.
- SARASHINA, T., H. TANIYAMA, AND J. YAMADA. 1987. A case of *Contracaecum spiculigerum* (Ascaroidea: Anisakinae) infection in a cormorant (*Phalacrocorax carbo*). *Japanese Journal of Veterinary Science* 49: 15–21.
- SMYTH, J. R., JR. 1990. Genetics of plumage, skin and eye pigmentation in chickens. *In* Poultry breeding and genetics, R. D. Crawford (ed.). Elsevier, Amsterdam, The Netherlands, pp. 109–167.
- SNOW, B. 1960. The breeding biology of the shag *Phalacrocorax aristotelis* on the Island of Lundy, Bristol Channel. *Ibis* 102: 554–575.
- SOULSBY, E. J. L. 1982. Helminths, arthropods and protozoa of domesticated animals. 7th Edition. Baillière Tindall, London, UK, 809 pp.
- TAYLOR, E. J. (Editor). 1988. Dorland's illustrated medical dictionary, 27th Edition. W. B. Saunders Company, Philadelphia, Pennsylvania, 1888 pp.
- THRELFALL, W. 1982. Ectoparasites (Mallophaga, Acarina) from the double-crested cormorant (*Phalacrocorax auritus*) in Florida. *Proceedings of the Entomological Society of Washington* 84: 369–375.
- VAN DE VEEN, H. E. 1973. Some aspects of the breeding biology and demography of the double-crested cormorants *Phalacrocorax auritus* of Mandarte Island. Final-year Thesis, State University of Groningen, Groningen, The Netherlands, 25 pp.
- VAN SCHEIK, W. J. 1985. Thermal aspects of the reproductive ecology of the double-crested cormorant (*Phalacrocorax auritus*) in southern Alberta. Ph.D. Thesis, University of Alberta, Edmonton, Alberta, Canada, 120 pp.
- VERMEER, K. 1967. A study of two species of gulls, *Larus californicus* and *L. delawarensis*, breeding in an inland habitat. Ph.D. Thesis, University of Alberta, Edmonton, Alberta, Canada, 128 pp.
- WOBESER, G., G. R. JOHNSON, AND G. ACOMPANADO. 1974. Stomatitis in a juvenile white pelican due to *Piagetiella peralis* (Mallophaga: Menoponidae). *Journal of Wildlife Diseases* 10: 135–138.
- , F. A. LEIGHTON, R. NORMAN, D. J. MYERS, D. ONDERKA, M. J. PYBUS, J. L. NEUFELD, G. A. FOX, AND D. J. ALEXANDER. 1993. Newcastle disease in wild water birds in western Canada, 1990. *Canadian Veterinary Journal* 34: 353–359.
- . 1997. Diseases of wild waterfowl, 2nd Edition. Plenum Press, New York, New York, 324 pp.
- YAMAGUTI, S. 1961. Systema helminthum, Vol. 3: The nematodes of vertebrates. Interscience Publishers, New York, New York, 1261 pp.
- ZAR, J. H. 1996. Biostatistical analysis. 3rd Edition. Prentice Hall, Upper Saddle River, New Jersey, 662 pp.

Received for publication 9 June 1998.