

Cryptosporidiosis in a Black Bear in Virginia

R. B. Duncan,^{1,4} D. Caudell,² D. S. Lindsay,¹ and H. D. Moll,³ ¹ Department of Pathobiology and Biomedical Sciences, Virginia-Maryland Regional College of Veterinary Medicine, Blacksburg, Virginia 24061, USA; ² DVM candidate May 2000, Virginia-Maryland Regional College of Veterinary Medicine, Blacksburg, Virginia 24061, USA; ³ Department of Large Animal Clinical Sciences, Virginia-Maryland Regional College of Veterinary Medicine, Blacksburg, Virginia 24061, USA; ⁴ Corresponding author (e-mail: duncanr@vt.edu).

ABSTRACT: Cryptosporidiosis has not been previously reported in black bears in North America, either free-roaming or captive. However, oocysts have been documented in two captive Malayan sun bears (*Helarctos malayanus*) located in zoological parks in Taiwan. Developmental stages of *Cryptosporidium parvum* were observed in tissue sections from the small intestine of a black bear cub found dead in Virginia (USA).

Key words: Black bear, case report, cryptosporidiosis, *Cryptosporidium parvum*, epidemiology, *Ursus americanus*.

Cryptosporidiosis is a gastrointestinal disease of mammals caused by the apicomplexan parasite *Cryptosporidium parvum*. Other species of this parasite exist in a variety of vertebrate animals but *C. parvum* is responsible for inducing disease in humans and other mammals. Interest in human cryptosporidiosis was initiated with the advent of the acquired immunodeficiency syndrome (AIDS) epidemic and the large numbers of cases seen in these immunocompromised hosts (O'Donoghue, 1995). Profuse, watery diarrhea is the main clinical manifestation of human cryptosporidiosis. Associated symptoms are cramps, abdominal pain, low grade fever, nausea, and vomiting with malaise, fatigue, headache, myalgia, and anorexia less common symptoms (O'Donoghue, 1995). The length of time the diarrhea remains is dependent on the immune status of the individual. The duration is generally a few days to a few weeks in immunocompetent individuals. The diarrhea persists for months to years in immunocompromised patients and can be life-threatening. Outbreaks of human cryptosporidiosis are associated with contaminated drinking water (MacKenzie, 1994). The role of wild mammals in the epidemiology of human cryp-

tosporidiosis is poorly understood. Wild ruminants in zoos have been shown to be commonly infected with *C. parvum* (Heuschele, 1986) and infections have been reported in wild raccoons (*Procyon lotor*) (Carlson, 1982; Snyder, 1988), gray foxes (*Urocyon cinereoargenteus*) (Davidson, 1992), gray squirrels (*Sciurus carolinensis*) (Sundberg, 1982), cotton rats (*Sigmodon hispidus*) (Elangbam, 1993), and bats (*Eptesicus fuscus*) (Dubey et al., 1998). This case report documents cryptosporidiosis in a black bear cub (*Ursus americanus*) from North America.

A male black bear cub was found dead by bowhunters in Rockingham County, Virginia (USA; 79°17'35"N; 38°27'0"W). Officials of the Virginia Department of Game and Inland Fisheries were notified and they presented the cub to the Virginia-Maryland Regional College of Veterinary Medicine (Virginia Polytechnic Institute and State University, Blacksburg, Virginia) for necropsy.

At necropsy, the carcass of the cub was in good body condition. The estimated time lapse between death and necropsy was approximately 24 to 48 hr. The orbits were slightly sunken and the viscera had tacky, dry surfaces, consistent with dehydration. Lack of postmortem hypostasis of blood suggested anemia. The stomach was devoid of ingesta. There was brown granular material in the stomach and melena in the colon suggesting luminal gastrointestinal hemorrhage. The contents of the colon appeared scant and liquid. Three large nematodes were present in the small intestine and were identified as *Bayliascaris transfuga*. There was a small fracture of the left ischium associated with adjacent perforation of the rectum. The fracture ex-

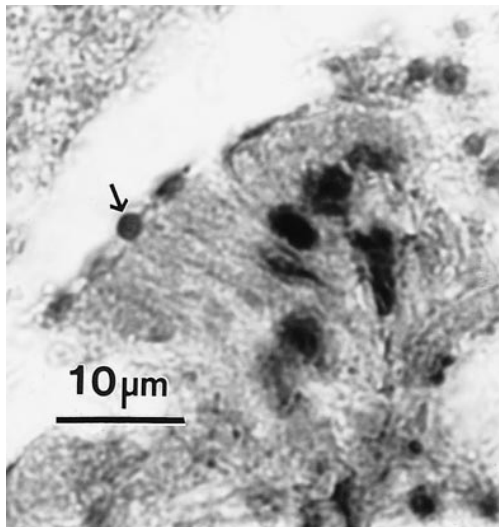


FIGURE 1. Photomicrograph of cryptosporidial stages in the microvillous border of enterocytes in the intestine of a black bear cub. An arrow points to one of the stages that is in the best plane for observation. H&E.

tended into the caudal aspect of the acetabulum and there was a subacute septic arthritis.

Selected tissue samples collected at necropsy were fixed in 10% buffered neutral formalin, processed routinely, and thin sections were stained with hematoxylin and eosin. Histological examination of the intestine documented moderate to marked autolysis. Several sections had small, round basophilic bodies (approximately 2–3 µm in diameter). These bodies were intimately associated with the apical surfaces of enterocytes and were consistent with *C. parvum* (Fig. 1) and inflammation was minimal. Peyer's patches were moderately well populated by lymphocytes. The colon had a severe segmental ulcerative colitis. The mucosa was completely absent and replaced by pyogenic granulation tissue. Inflammation was characterized by neutrophils, macrophages, lymphocytes, and plasma cells. Occasional macrophages had phagocytized bacteria. Inflammation extended from the ulcerated surface to the serosa. There was multifocal pyogranulomatous hepatitis and focal hepatocellular ne-

erosis. Cryptosporidia were not observed in these hepatic lesions.

Additional sections of small intestine were examined using rabbit-anti-*C. parvum* antisera (1:500 dilution) and the avidin-biotin peroxidase complex immunohistological test as previously described (Lindsay and Dubey, 1989). Sections of intestine from a calf with cryptosporidiosis were used as a positive control for reactivity. Protozoa in the bear's intestine reacted positively with the rabbit anti-*C. parvum* rabbit serum confirming their identity as stages of cryptosporidia.

Less than 2 g of feces was present in the colon and it was examined by flotation in sucrose solution. No parasites were seen in the sample.

The cause of death in this case was attributed to dehydration secondary to bacterial-induced colitis; however, bacterial culture was not performed to confirm the presence of pathogenic bacterial species. Anemia was attributed to gastrointestinal blood loss and intercurrent disease. Concurrent ascarid endoparasitism and cryptosporidiosis may have contributed to this animal's debility, but were regarded as incidental. Multifocal hepatitis was attributed to sepsis secondary to the enterocolitis. The cause of the ischial fracture was not determined.

Cryptosporidiosis has not been previously reported in black bears, either free-ranging or held in captivity. However, oocysts have been documented in two captive Malayan sun bears (*Helarctos malayanus*) located in zoological parks in Taiwan (Wang 1990).

We acknowledge the cooperation of the Virginia Department of Game and Inland Fisheries, without which this manuscript would not have been possible. We thank C. C. Dykstra for providing the rabbit anti-*C. parvum* antisera.

LITERATURE CITED

- CARLSON, B. L., AND S. W. NIELSEN. 1982. Cryptosporidiosis in a raccoon. *Journal of the Amer-*

- ican Veterinary Medical Association 181: 1405–1406.
- DAVIDSON, W. R., V. F. NETTLES, L. E. HAYES, AND E. W. HOWERTH. 1992. Diseases diagnosed in gray foxes (*Urocyon cinereoargenteus*) from the southeastern United States. *Journal of Wildlife Diseases* 28: 28–33.
- DUBEY, J. P., A. N. HAMIR, R. J. SONN, AND M. J. TOPPER. 1998. Cryptosporidiosis in a bat (*Eptesicus fuscus*). *The Journal of Parasitology* 84: 622–623.
- ELANGBAM, C. S., C. W. QUALIS, S. A. EWING, AND R. L. LOCHMILLER. 1993. Cryptosporidiosis in a cotton rat (*Sigmodon hispidus*). *Journal of Wildlife Diseases* 22: 493–496.
- HEUSCHELE, W. P., J. OOSTERHUIS, D. JANSSEN, P. T. ROBINSON, P. K. ENSLEY, E. MEIER, T. OLSON, M. P. ANDERSON, AND K. BENIRSCHKE. 1986. Cryptosporidial infections in captive wild animals. *Journal of Wildlife Diseases* 22: 493–469.
- LINDSAY, D. S., AND J. P. DUBEY. 1989. Immunohistochemical diagnosis of *Neospora caninum* in tissue sections. *American Journal of Veterinary Research* 50: 1981–1983.
- MACKENZIE, W. R., N. J. HOXIE, M. E. PROCTOR, M. S. GRANDUD, K. A. BLAIR, D. E. PETERSON, J. J. KAZMIERCZAK, D. G. ADDISS, K. R. FOX, J. R. ROSE, AND J. P. DAVIS. 1994. A massive outbreak in Milwaukee of *Cryptosporidium* infection transmitted through the public water supply. *New England Journal of Medicine* 331: 161–167.
- O'DONOGHUE, P. J. 1995. *Cryptosporidium* and cryptosporidiosis in man and animals. *International Journal of Parasitology* 25: 139–195.
- SNYDER, D. E. 1988. Indirect immunofluorescent detection of oocysts of *Cryptosporidium parvum* in the feces of naturally infected raccoons (*Procyon lotor*). *The Journal of Parasitology* 74: 1050–1052.
- SUNDBERG, J. P., D. HILL, AND M. J. RYAN. 1982. Cryptosporidiosis in a gray squirrel. *Journal of the American Veterinary Medical Association* 181: 1420–1422.
- WANG, J. S., AND C. T. LIEW. 1990. Prevalence of *Cryptosporidium* spp. in birds in Taiwan. *Taiwan Journal of Veterinary Medicine and Animal Husbandry* 56: 45–57.

Received for publication 22 September 1998.