

Adenocarcinoma of the Mammary Gland in a Red Fox from Austria

Martin Janovsky and Theodora Steineck, Research Institute of Wildlife Ecology, University of Veterinary Medicine, Savoyenstraße 1, A-1160 Vienna, Austria.

ABSTRACT: A mammary gland adenocarcinoma was diagnosed in an adult red fox (*Vulpes vulpes*) which was shot in Austria in August 1995. Metastases were found in the kidneys and liver. This is the first reported case of an adenocarcinoma in a fox, and lack of mammary gland carcinoma in this species may be age related.

Key words: Adenocarcinoma, case report, mammary gland, red fox, *Vulpes vulpes*.

Tumors of the mammary gland are well known and common in domestic carnivores, but they are rare in other domestic species (Yager and Scott, 1993). They are the second most common tumors of male dogs (*Canis lupus domestica*) (Jones and Hunt, 1983; Schulz, 1991) and the most common neoplasms of female dogs (Theilen and Madewell, 1987). In cats (*Felis silvestris domestica*) they are the third most common malignancy in order of frequency after skin tumors and haemolymphatic malignancies (Theilen and Madewell, 1987). However, the percentage of carcinomatous mammary tumors is much higher in the cat than in the dog. While the accumulated literature is vast on domestic species, published information on the occurrence of tumors in free ranging carnivores is limited. Generally, tumors of the mammary glands in free-ranging carnivores are considered to be very rare (Williams et al., 1989). Carpenter (1980) reported the occurrence of a cystadenocarcinoma of the mammary gland in a black-footed ferret (*Mustela nigripes*) and Williams et al. (1989) mentioned a case of adenocarcinoma of the mammary gland in an European pine marten (*Martes martes*). In red foxes (*Vulpes vulpes*) only a few cases of neoplasms are described and tumors of the mammary glands are not reported. According to Lutz (1990) no neoplasms were seen in 530 red foxes submitted for necropsy; while Elvestad et al. (1984) found

one case of neoplasia in 873 foxes investigated. Other tumors in foxes were described by Kerschagl (1965), Burgisser (1983), Ippen (1987), Wenzel and Berestov (1987), and Williams et al. (1989). In a 10 yr study of the cause of death of 2,482 ranched foxes, neoplasms were diagnosed in only 19 cases. Carcinomas of the duodenum, colon, spleen, bladder, lungs, tongue, and skin fibromas were described. Tumors of the mammary gland were not seen (Chaddock, 1948).

On 19th June 1995, a free-ranging adult female red fox weighing 3,650 g, exhibiting abnormal behaviour (missing attempts to escape) and poor condition, was shot by a hunter at the suburbs of Vienna, Austria (48°13'N, 16°22'W). The animal was submitted for necropsy to the Research Institute of Wildlife Ecology (Vienna, Austria).

The red fox appeared undernourished and had two suppurating lesions on the left hindleg. The skin of the tail showed areas of hair loss but skin scrapings for diagnosis of sarcoptic mites (*Sarcoptes scabiei*) were negative. A few fleas (*Ctenocephalides canis*) and ticks (*Ixodes ricinus*) were found. Further parasitologic examinations by using a flotation technique (Eckert et al., 1992), indicated ascarid eggs (*Toxocara canis*) in moderate numbers. On the right side of the thorax and abdomen there were four fibrous, poorly demarcated subcutaneous 5 × 4 × 4 cm nodules. The skin above the lesions was thin, partly ulcerated and inflamed. The cut surface was white and lobulated and areas of necrosis and hemorrhage were present. Yellow, viscous fluid could be expressed from the nodules. The lymph nodes of the intestine were enlarged. The regional lymph nodes of the mammary glands were of normal size. Other gross findings were pale

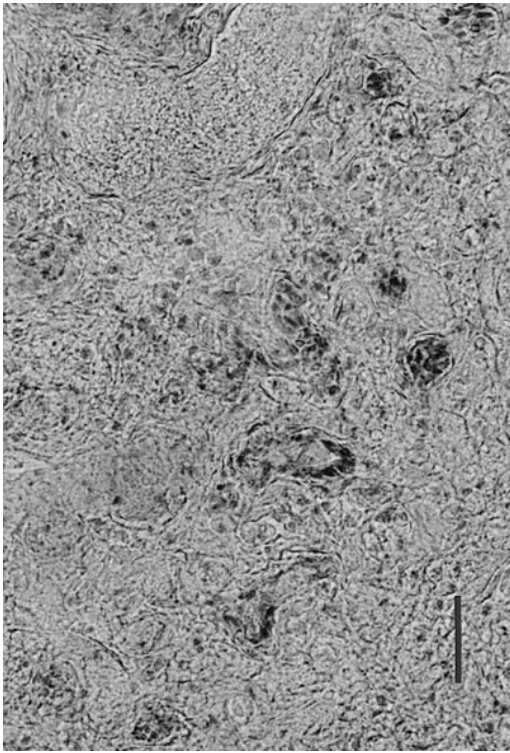


FIGURE 1. Mammary gland. Ductular structure of the neoplastic tissue. H&E. Bar = 40 μ m.

muscles, swollen spleen and liver, and a turgid gall bladder. The kidneys appeared pale red, the heart had low-grade hypertrophy. The uterus and the ovaries were inactive and appeared normal.

Tissue samples of the mammary gland, lung, heart, liver, kidney, lymph nodes, and the spleen were fixed in 8% formalin, embedded in celloidin, sectioned, and stained with hematoxylin and eosin. In the mammary gland multiple foci of neoplastic epithelial cells forming ductular structures as well as solid formation of cells were evident (Fig. 1). Tumor cells were surrounded by fibrous connective tissue and necrosis was widespread. Tumor cells had large, pleomorphic nuclei, the mitotic index was low. Due to the partly ductular structure of neoplastic tissue, the tumor in the mammary gland was classified as adenocarcinoma. We found similar tumor cells also in the cortex of kidneys surrounding the glomeruli and in the interstitium partly

compressing the lumen of tubuli. Some cross-sections of tubuli contained pale blue to dark blue masses resembling foci of calcification. In the liver, tumor cells could be seen near the blood vessels, and cells with swollen nuclei or with karyorrhexis were disseminated throughout the liver.

In spite of the high number of red foxes submitted for veterinary investigations in Europe due to rabies control measures, reports of tumors are rare in this species. This is the first report of tumors of the mammary gland. This absence of reports in red foxes is surprising, since the incidence of mammary gland tumors is very high in domestic dogs (Moulton, 1978). One possible explanation could be that tumors of the mammary gland remain undetected because in red foxes sent in for rabies control measures the whole carcass is not examined routinely. Alternatively, most free ranging red foxes may not become old enough to develop tumors of the mammary gland. It is well known that the risk of cancer is negligible in younger animals, but becomes much higher in older individuals.

LITERATURE CITED

- BURGISSER, H. 1983. Compte-rendu sur les maladies des animaux sauvages de 1975 à 1982. Schweiz. Arch. Tierheilk. 125: 519–527.
- CARPENTER, J. W., J. P. DAVIDSON, M. N. NOVILLA, AND J. C. M. HUANG. 1980. Metastatic papillary cystadenocarcinoma of the mammary gland in a black-footed ferret. *Journal of Wildlife Diseases* 16: 587–592.
- CHADDOCK, T. T. 1948. Veterinary problems in the fur ranch. *Veterinary medicine* 43: 13.
- ELVESTAD, K., V. HENRIQUES, AND J. KROUSTRUP. 1984. Insulinproducing islet cell tumor in an ex-topic pancreas of a Red Fox (*Vulpes vulpes*). *Journal of Wildlife Diseases*. 20: 70–72.
- ECKERT, J., M. ROMMEL, E. KUTZER, AND H.-J. BÜRGER. 1992. Allgemeines. In *Veterinärmedizinische Parasitologie*, 4th Edition, J. Eckert (ed.). Verlag Paul Parey, Berlin, Germany, pp. 1–104.
- IPPEN, R. 1987. Geschwülste. In *Krankheiten des jagdbaren Wildes*, 1st Edition, R. Ippen, S. Nickel, and H. D. Schröder (eds.). Deutscher Landwirtschaftsverlag, Berlin, Germany, pp. 53–63.

- JONES, T. C., AND R. D. HUNT. 1983. Veterinary pathology. 5th Edition, Lea & Febinger, Philadelphia, Pennsylvania, pp. 1550–1562.
- KERSCHAGL, W. 1965. Wildkrankheiten. Österreichischer Jagd- und Fischereiverlag, Wien, Austria, 328 pp.
- LUTZ, W. 1990. Erkrankungs- und Todesursachen beim Fuchs nach den Fallwilduntersuchungen in Nordrhein-Westfalen. *In* Fuchs-Symposium Koblenz 1990, C. Commichau und H. Sprankel (eds.). Verlag J. Neumann-Neudamm Melsungen, Germany, 20: 119–123.
- MOULTON, J. E. 1978. Tumors of the mammary gland. *In* Tumors in domestic animals. 2nd Edition, J. E. Moulton (ed.). University of California Press, Berkeley, California, pp. 346–371.
- SCHULZ, L.-CL. 1991. Weibliche Geschlechtsorgane und Milchdrüse. *In* Pathologie der Haustiere. Teil 1. L.-Cl. Schulz (ed.). Gustav Fischer Verlag, Jena, Germany, pp. 649–655.
- THEILLEN, G. H., AND B. R. MADEWELL. 1987. Veterinary cancer medicine. 2nd Edition, Lea & Febinger, Philadelphia, Pennsylvania, pp. 435–447.
- WENZEL, U. D., AND V. A. BERESTOV. 1987. Pelztierkrankheiten, Nerz und Fuchs. Schober Verlags-GmbH, Hengersberg, Germany, 279 pp.
- WILLIAMS, E. S., E. T. THORNE, AND T. STEINECK. 1989. Spontaneous tumors of free-ranging terrestrial mammals of North America. *In* Comparative aspects of tumor development. H. E. Kaiser, (ed.). Kluwer Academic Publishers, Dordrecht, Netherlands, pp. 214–225.
- YAGER, J. A., AND D. W. SCOTT. 1993. The skin and appendages. *In* Pathology of domestic animals. 4th Edition, Vol. 1, K. V. F. Jubb, P. C. Kennedy and N. Palmer (eds.). Academic Press, Inc., San Diego, California, pp. 531–738.

Received for publication 10 March 1997.