

GUIDELINES FOR THE FIELD EVALUATION OF DESERT TORTOISE HEALTH AND DISEASE

Kristin H. Berry^{1,3} and Mary M. Christopher²

¹ U.S. Geological Survey, 6221 Box Springs Boulevard, Riverside, California 92507, USA

² Department of Pathology, Microbiology and Immunology, School of Veterinary Medicine, University of California-Davis, Davis, California 95616-8739, USA

³ Corresponding author (e-mail: kristin_berry@usgs.gov)

ABSTRACT: Field evaluation of free-ranging wildlife requires the systematic documentation of a variety of environmental conditions and individual parameters of health and disease, particularly in the case of rare or endangered species. In addition, defined criteria are needed for the humane salvage of ill or dying animals. The purpose of this paper is to describe, in detail, the preparation, procedures, and protocols we developed and tested for the field evaluation of wild desert tortoises (*Gopherus agassizii*). These guidelines describe: preparations for the field, including developing familiarity with tortoise behavior and ecology, and preparation of standardized data sheets; journal notes to document background data on weather conditions, temperature, rainfall, locality, and historic and recent human activities; procedures to prevent the spread of disease and parasites; data sheets for live tortoises to record tortoise identification, location, sex, body measurements and activity; health profile forms for documenting and grading physical abnormalities of tortoise posture and movements, general condition (e.g., lethargy, cachexia), external parasites, and clinical abnormalities associated with shell and upper respiratory diseases; permanent photographic records for the retrospective analysis of progression and regression of upper respiratory and eye diseases, analysis of shell lesions and evaluation of growth and age; and indications and methods for salvaging ill or dying tortoises for necropsy evaluation. These guidelines, tested on 5,000 to 20,000 tortoises over a 10 to 27 yr period, were designed to maximize acquisition of data for demographic, ecological, health and disease research projects; to reduce handling and stress of individual animals; to avoid spread of infectious disease; to promote high quality and consistent data sets; and to reduce the duration and number of field trips. The field methods are adapted for desert tortoise life cycle, behavior, anatomy, physiology, and pertinent disease; however the model is applicable to other species of reptiles. Comprehensive databases of clinical signs of disease and health are crucial to research endeavors and essential to decisions on captive release, epidemiology of disease, translocation of wild tortoises, breeding programs, and euthanasia.

Key words: Chelonian, desert tortoise, diagnosis, disease, field evaluations, *Gopherus agassizii*, health assessments.

INTRODUCTION

Most research on populations of wild animals is conducted by wildlife biologists, zoologists, and ecologists without collaboration with veterinary medical specialists. Many research projects, especially those involved with rare and endangered animals, could benefit from the contributions of veterinarians and other health specialists (Boyce et al., 1992) at every phase. Veterinarians and wildlife health specialists can assist in identifying diseases and their ecological significance to wild animal populations, determining the effects of anthropogenic impacts (e.g., stress), and developing management options for recovery and rehabilitation (Kirkwood, 1993, 1994).

Research on the desert tortoise (*G-*

phorus agassizii), a species of the arid southwestern United States and Mexico, provides an excellent model for how interdisciplinary teams of research scientists developed techniques to evaluate health and diagnose disease. The tortoise was listed by the federal government as a threatened species under the Endangered Species Act (ESA) of 1973 (as amended) over approximately 30% of its geographic range in the arid southwestern USA and Mexico in 1990, because several populations were experiencing declines (Fish and Wildlife Service [FWS], 1994; Berry, 1997a). Two recently described diseases, upper respiratory tract disease (URTD) and cutaneous dyskeratosis, were associated with population declines in some areas (Brown

et al., 1994; Jacobson et al., 1995; Berry, 1997b). Upper respiratory tract disease is caused by *Mycoplasma agassizii* (Jacobson et al., 1991; Brown et al., 1994) and an as yet unnamed new mycoplasma organism (Brown et al., 1995). An enzyme-linked immunosorbent assay (ELISA) test was developed to measure antibodies to *Mycoplasma agassizii* in tortoises (Schumacher et al., 1993). URTD and exposure to mycoplasma, as evidenced by positive ELISA tests and presence of mycoplasma in nasal secretions by cultures or polymerase chain reaction tests, have been documented in tortoises at multiple sites in the Mojave Desert (Jacobson et al., 1995; Dickinson et al., 1995; Homer et al., 1998; Brown et al., 1999). Upper respiratory tract disease is a transmissible disease, often subclinical and generally chronic (Brown et al., 1994; Jacobson et al., 1995; Homer et al., 1998). Cutaneous dyskeratosis produces lesions on the shell and integument and is of unknown etiology (Jacobson et al., 1994), although environmental toxicants and nutritional deficiencies are suspected contributors (Homer et al., 1998).

We developed a model set of standardized field guidelines for collecting and analyzing qualitative and quantitative data on clinical and physical signs of health, disease, and trauma for wild desert tortoises. The guidelines and techniques were designed to maximize acquisition of data for demographic, ecological, health and disease research projects; to reduce handling and stress of individual animals; to avoid spread of infectious disease; to promote high quality and consistent data sets; and to reduce the duration and number of field trips. Techniques for recording journal notes and information about live tortoises were developed, tested, and revised between 1971 and 1998 at 27 study plots in the California deserts (e.g., Berry and Medica 1995; Berry 1997b) with >20,000 captures of wild tortoises. Most techniques for assessing health and disease were developed and tested between 1988 and

1998 at 36 sites in California with >5,000 captures of tortoises (e.g., Berry, 1997b; Henen et al., 1998; Homer et al., 1998; Brown et al. 1999; Christopher et al., 1999). These standardized field methods represent a productive collaboration between wildlife biologists, veterinarians and pathologists, and are applicable to other chelonians and reptiles.

PREPARATIONS FOR THE FIELD

Prior to initiating field work, project participants should familiarize themselves with the literature on wild desert tortoises to optimize time and expedite location of tortoises (e.g., FWS, 1994; Grover and DeFalco, 1995). The annual cycle of above-ground activity for tortoises varies according to location within the geographic range and depends on such environmental factors as number of freezing days per annum, timing and amounts of precipitation, day- and night-time temperatures, and the type of desert (FWS, 1994). The exact timing of above ground activity is also dependent on availability of forage, local weather patterns, and ambient daytime temperatures (Nagy and Medica, 1986; Ruby et al., 1994; Zimmerman et al., 1994; Henen, 1997), as well as the size and age of tortoises (Berry and Turner, 1986).

Wild tortoises are easily accessible (near entrances of their burrows or dens, or above ground) to the field worker about 1.7% of each year in the Mojave Desert (Nagy and Medica, 1986). They hibernate in late fall and winter, can be active above ground in late winter and spring, may estivate in summer, and may become active again in late summer and early fall. In the Sonoran Desert, the seasonal activity pattern is associated with monsoon rains, with tortoises active above ground primarily in summer and fall (Johnson et al., 1990). Immediately after emergence from hibernation in late winter and early spring, tortoises usually have a single activity period during the middle of the day, and shift to a bimodal pattern as ambient temperatures increase in late spring (Zimmerman

et al., 1994). During drought years, tortoises can be considerably more difficult to locate above ground. To ensure success in planning field work and locating tortoises, the field biologist should gather information on regional climatic patterns and local weather conditions, particularly precipitation during the previous year, from National Oceanic and Atmospheric Administration weather stations. The windows of activity when field workers can easily capture the tortoises are narrow, so each tortoise should be processed quickly to maximize encounters and sample sizes.

Field workers should familiarize themselves with the full repertoire of postures, behaviors, and display patterns of healthy desert tortoises (Ruby and Niblick, 1994) and the contexts in which they normally occur. Courtship in the Mojave Desert, for example, may occur in any month in which tortoises are above ground, with intense mating activity in both spring (April–May) and fall (August–November) (Rostal et al., 1994a; Ruby and Niblick, 1994). Nesting occurs between April and July (Turner et al., 1986; Rostal et al., 1994a). The timing of reproductive activities may be different in tortoise populations in the Sonoran and Chihuahuan deserts. Field workers also should be knowledgeable of abnormal behaviors and signs of ill health and disease by reviewing the literature on wildlife diseases.

Wild desert tortoises are similar to other members of the Testudinidae and exhibit a wide variety of responses when captured. They can be tame and curious, try to escape, or retreat tightly into their shells, posing difficulties for a thorough examination of the accessible soft parts (limbs, head, and tail). Since the species is threatened and protected under the ESA of 1973, as amended, efforts must be taken to reduce stress and handling time and to release the tortoise at the site of capture within 15 to 20 min. To ensure expeditious processing, new field workers should practice under an experienced supervisor on

legally held captive desert tortoises or other chelonians.

Effective and efficient data collection can be accomplished by following written protocols and recording data on standardized forms printed on archival paper. These forms should document background environmental data, individual tortoise data, and data from physical examination of the tortoise. The forms can be modified to suit special projects and other species, and can be handwritten or directly entered into portable computerized databases in the field.

JOURNAL NOTES

Journal Notes should provide background data essential for interpreting whether the activities and behaviors of tortoises are typical of ill or healthy animals, as well as for identifying potential sources of trauma, illness, or disease. Journal notes should contain survey times, numbers of live and dead tortoises observed, starting and ending times of field work, time expended in searching for and processing tortoises, and observations of other animals (Fig. 1). Details of actual times spent in observing tortoise behavior from a distance as opposed to handling are recorded in more detail on other data sheets (Figs. 2, 3).

Daily weather conditions can substantially alter the interpretation of tortoise activity levels, behavior and physiology, so Journal Notes should contain a daily summary of weather conditions. For example, a rainfall event during late spring, summer or early fall can stimulate *en masse* emergence of tortoises to drink and rehydrate (Henen et al., 1998). In contrast, precipitation during cold weather in winter is unlikely to elicit emergence when tortoises are hibernating. Similarly, if air temperatures exceed 40, a panting tortoise may be interpreted as being overheated and unable to find shelter (an abnormal situation). Therefore the field biologist should begin each day by recording percentage and type of cloud cover, amount and tim-

JOURNAL

Desert Tortoise (*Gopherus agassizii*)
Paradise Mountains
San Bernardino County, California

Date _____

Start & Finish Times (PST) _____

Areas Searched (by section & grid no.; map also) _____

Capture type 1: _____

Capture type 2: _____

Capture type 3: _____

Shells: _____

Other Capture types: _____

Names of field workers	Start & end times	Search times	Processing times	Total field time

Pacific Standard Time	Temperatures (°C)			Wind speed & direction	Cloud cover
	1.5 m	1 cm	soil surface (shaded bulb)		
0800					
1200					
1600					

min. temperature for the day: _____

max. temperature for the day: _____

HUMAN USES

People: _____

Vehicles (type & numbers): _____

Livestock: _____

Shooting: _____

Other: _____

Other Notes: _____

Downloaded from http://meridian.allenpress.com/jwd/article-pdf/37/3/427/2236047/0090-3558-37_3_427.pdf by guest on 09 August 2024

FIGURE 1. Sample data sheet for Journal Notes.

DO NOT ABBREVIATE

WRITE ON THIS SIDE ONLY

Data Sheet for Live Desert Tortoises

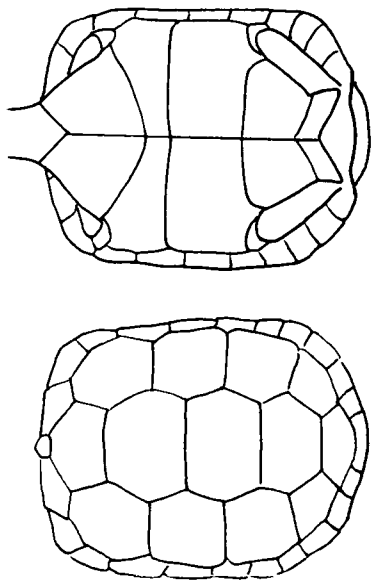
Field Worker _____ Tortoise ID Number _____
 Study site name _____ Verification of ID _____
 Study site number _____
 Township _____ Range _____
 Section _____ Grid no. _____
 COORDINATES (Reference SW corner)
 _____ meters North, _____ meters East
 County _____
 State _____

Year first marked _____
 Capture Type _____ Sex _____
 Date (day/month/yr) _____
 Time (PST): Start _____ End _____
 On Plot _____ Off Plot _____
 ← Show location of tortoise in grid

TORTOISE LOCATION	COVER SITE DATA	SURVEY TYPE
Cover site type: At cover site: Not at cover site: burrow <input type="checkbox"/> entering <input type="checkbox"/> in open <input type="checkbox"/> pallet <input type="checkbox"/> exiting <input type="checkbox"/> other <input type="checkbox"/> shrub <input type="checkbox"/> on mound <input type="checkbox"/> _____ caliche cave <input type="checkbox"/> inside <input type="checkbox"/> _____ rock shelter <input type="checkbox"/> _____	For tortoises ≤140 mm MCL orientation _____ length _____ height _____ width _____ soil cover _____ location _____	coverage 1 <input type="checkbox"/> coverage 2 <input type="checkbox"/> juv. search <input type="checkbox"/> other <input type="checkbox"/>

TORTOISE ACTIVITY
 resting walking Interacting with other tortoise ID & sex of other tortoise _____
 basking feeding Interacting with other animals other species _____
 Describe interaction: _____
 plants/items eaten (be specific): _____

SPACE FOR MORPHOMETRIC MEASUREMENTS,
 ECOLOGICAL DATA, Etc.



BODY MEASUREMENTS
 carapace length at midline, MCL (mm) _____
 plastron length (notch), PLN (mm) _____
 weight (g) _____
 void/feces (g) _____
 total weight (g) _____
 new growth: present absent
 epoxied #: present legible

DRAW LOCATIONS OF NOTCHES (old and new),
 chips, and anomalies, etc.
 Describe anomalies in numbering of marginals and
 any identification problems.
 Other notes: _____

Photo reference: roll _____ frames _____
 Berry/livtort.3-1993(mac)

Downloaded from http://meridian.elsevier.com/jv/article-pdf/37/3/427/2236047/0090-3558-37_3_427.pdf by guest on 09 August 2024

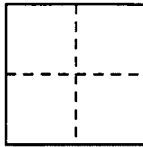
FIGURE 2. Sample data sheet for Live Desert Tortoises.

DO NOT ABBREVIATE

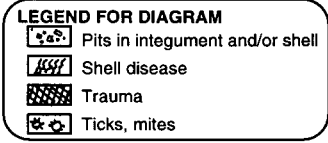
WRITE ON THIS SIDE ONLY

Health Profile Form for Desert Tortoises

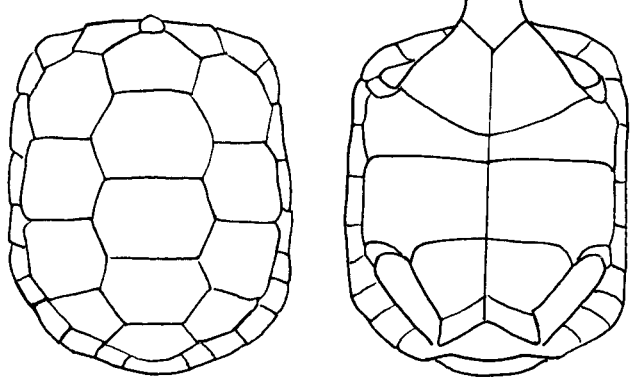
Field Worker _____ Tortoise ID Number _____
 Study site name _____ No. _____ Year first marked _____
 Township _____ Range _____ MCL _____ Weight (g) _____
 Section _____ Grid no. _____ Capture Type _____ Sex _____
 County _____ State _____ Date (day/month/yr) _____
 On Plot _____ Off Plot _____ Time (PST): Start _____ End _____
 Shell Wear Class _____
 ← Location of tortoise in grid



BEAK & NARES			ORAL CAVITY⁴			Urine (vol) _____			
Beak/nares wet	YES <input type="checkbox"/>	NO <input type="checkbox"/>	UNK <input type="checkbox"/>	Observed	YES <input type="checkbox"/>	NO <input type="checkbox"/>	UNK <input type="checkbox"/>	Color _____	
Beak/nose damp	<input type="checkbox"/>	<input type="checkbox"/>	<input type="checkbox"/>	Discharge present	<input type="checkbox"/>	<input type="checkbox"/>	<input type="checkbox"/>	Viscosity _____	
Nasal exudate present	<input type="checkbox"/>	<input type="checkbox"/>	<input type="checkbox"/>	Membranes pink	<input type="checkbox"/>	<input type="checkbox"/>	<input type="checkbox"/>	Particulates _____	
Exudate color: clear	<input type="checkbox"/>	<input type="checkbox"/>	<input type="checkbox"/>	Membranes pale, white	<input type="checkbox"/>	<input type="checkbox"/>	<input type="checkbox"/>	color _____	
cloudy	<input type="checkbox"/>	<input type="checkbox"/>	<input type="checkbox"/>	Smells/mouth rot	<input type="checkbox"/>	<input type="checkbox"/>	<input type="checkbox"/>	Nasal wash sample collected _____	
white	<input type="checkbox"/>	<input type="checkbox"/>	<input type="checkbox"/>	EVIDENCE OF SHELL/BONE DISEASE			No. of needle sticks _____		
yellow	<input type="checkbox"/>	<input type="checkbox"/>	<input type="checkbox"/>	Lesions present	<input type="checkbox"/>	<input type="checkbox"/>	<input type="checkbox"/>	Time of needle sticks _____	
green	<input type="checkbox"/>	<input type="checkbox"/>	<input type="checkbox"/>	Lesions active	<input type="checkbox"/>	<input type="checkbox"/>	<input type="checkbox"/>	Location _____	
Bubble(s) from nares	<input type="checkbox"/>	<input type="checkbox"/>	<input type="checkbox"/>	Lesions healed	<input type="checkbox"/>	<input type="checkbox"/>	<input type="checkbox"/>	PCV% _____	
One nare occluded	<input type="checkbox"/>	<input type="checkbox"/>	<input type="checkbox"/>	Scute laminae peeling	<input type="checkbox"/>	<input type="checkbox"/>	<input type="checkbox"/>	Other samples taken _____	
Both nares occluded	<input type="checkbox"/>	<input type="checkbox"/>	<input type="checkbox"/>	Scutes missing/peeling	<input type="checkbox"/>	<input type="checkbox"/>	<input type="checkbox"/>	Describe/draw parasites _____	
Dirt on nose/beak	<input type="checkbox"/>	<input type="checkbox"/>	<input type="checkbox"/>	Pitting	<input type="checkbox"/>	<input type="checkbox"/>	<input type="checkbox"/>	Other _____	
Dirt in nares	<input type="checkbox"/>	<input type="checkbox"/>	<input type="checkbox"/>	Scutes depressed/concave	<input type="checkbox"/>	<input type="checkbox"/>	<input type="checkbox"/>		
FORELEGS (adjacent to face)			EVIDENCE OF TRAUMA						
Dried dirt on forelegs	<input type="checkbox"/>	<input type="checkbox"/>	<input type="checkbox"/>	Head	<input type="checkbox"/>	<input type="checkbox"/>	<input type="checkbox"/>		
Moisture on forelegs	<input type="checkbox"/>	<input type="checkbox"/>	<input type="checkbox"/>	Gular	<input type="checkbox"/>	<input type="checkbox"/>	<input type="checkbox"/>		
Dried exud. on scales ¹	<input type="checkbox"/>	<input type="checkbox"/>	<input type="checkbox"/>	Forelimbs	<input type="checkbox"/>	<input type="checkbox"/>	<input type="checkbox"/>		
Scales cracking ²	<input type="checkbox"/>	<input type="checkbox"/>	<input type="checkbox"/>	Hindlimbs	<input type="checkbox"/>	<input type="checkbox"/>	<input type="checkbox"/>		
BREATHING: Smooth			Bone/scute replacement						
Wheezing	<input type="checkbox"/>	<input type="checkbox"/>	<input type="checkbox"/>	Shell	<input type="checkbox"/>	<input type="checkbox"/>	<input type="checkbox"/>		
Rasping, clicking	<input type="checkbox"/>	<input type="checkbox"/>	<input type="checkbox"/>		<input type="checkbox"/>	<input type="checkbox"/>	<input type="checkbox"/>		
EYES, CHIN GLANDS Circle eyes or lids:			Describe: _____						
Eyes/lids whitened or discolored	<input type="checkbox"/>	<input type="checkbox"/>	<input type="checkbox"/>	Soil dryness: wet _____ damp _____ dry _____					
Eyelids swollen	<input type="checkbox"/>	<input type="checkbox"/>	<input type="checkbox"/>	Last Precipitation (day/mo/yr) _____					
Eyes/lids wet	<input type="checkbox"/>	<input type="checkbox"/>	<input type="checkbox"/>						
Discharge from eyes	<input type="checkbox"/>	<input type="checkbox"/>	<input type="checkbox"/>						
Eyes sunken	<input type="checkbox"/>	<input type="checkbox"/>	<input type="checkbox"/>						
Eyes clear, bright	<input type="checkbox"/>	<input type="checkbox"/>	<input type="checkbox"/>						
Eyes dull, cloudy	<input type="checkbox"/>	<input type="checkbox"/>	<input type="checkbox"/>						
Chin glands draining	<input type="checkbox"/>	<input type="checkbox"/>	<input type="checkbox"/>						
INTEGUMENT³									
Integument dull	<input type="checkbox"/>	<input type="checkbox"/>	<input type="checkbox"/>						
Integument glossy	<input type="checkbox"/>	<input type="checkbox"/>	<input type="checkbox"/>						
Normal elasticity	<input type="checkbox"/>	<input type="checkbox"/>	<input type="checkbox"/>						
Abnormal skin peeling	<input type="checkbox"/>	<input type="checkbox"/>	<input type="checkbox"/>						
POSTURE/BEHAVIOR									
Alert, responsive	<input type="checkbox"/>	<input type="checkbox"/>	<input type="checkbox"/>						
Lethargic	<input type="checkbox"/>	<input type="checkbox"/>	<input type="checkbox"/>						
Can withdraw tightly into shell	<input type="checkbox"/>	<input type="checkbox"/>	<input type="checkbox"/>						
Limbs, head hanging limp or loose	<input type="checkbox"/>	<input type="checkbox"/>	<input type="checkbox"/>						



DRAW: shape of gulars, location of notches; chips, chews, shell damage, lesions; shell disease; shell abnormalities; scute concavities. Make new drawing at least once/year (spring).



OTHER NOTES: _____

Footnotes: 1 - Shiny integument, glossy with dried exudate. 2 - The integument can crack from effects of the exudate. 3 - Difficult, but try. For normal elasticity, gently pull skin on limb, note how quickly skin returns to position. 4 - Important. DO NOT try to open mouth. Make observations opportunistically, if tortoise opens mouth.
 Berry/HealthProf.4-1995(mac)

FIGURE 3. Sample Health Profile Form.

Downloaded from http://meridian.alleupress.com/jwd/article-pdf/37/3/427/2238047/0090-3558-37_3_427.pdf by guest on 09 August 2024

ing of precipitation, temperatures, and wind speed. Air temperatures, recorded with a Schultheiss or Miller and Weber (Miller & Weber, Inc., Ridgewood Queens, New York, USA) quick-reading thermometer (0–50 C), are taken at 1.5 m, at 1 cm above the soil surface (shaded bulb) and on the soil surface (shaded bulb) at least three times daily (0800, 1200, and 1600 PST) and can be recorded also at the location of capture of each tortoise. Since many facets of tortoise behavior, physiology, and health are closely tied to nutrition and food intake, field workers should record the current and recent availability of fresh, green, succulent plants and recently dried plants used by tortoises for forage. The ability to observe and record such information presupposes that field workers have familiarized themselves with the diet and the locally preferred plant foods and are able to identify the plants in the field.

Journal Notes should contain detailed data on locality of study sites, e.g., latitude, longitude; township, range, and portion of section; universal transverse mercator (UTM) grid coordinates; county; and elevation. Some permanent sites (FWS, 1994; Berry and Medica, 1995) have survey poles at intervals of 100 to 165 m, so that locations of tortoises can then be estimated in meters by pacing to the nearest pole. At other sites, global positioning systems have been used to determine localities within 50 to 100 m. The precise locations of tortoises are critical for interpreting sources of trauma and toxicants and causes of some diseases.

All parameters related to human activities on and in the vicinity of the study site should be recorded both in Journal Notes and on a detailed map, because they may be critical factors in monitoring the long-term well-being of the population (Boyce et al., 1992; FWS, 1994). Examples include: distribution and densities of vehicle tracks, trails, paved and dirt roads; numbers and types of vehicles; numbers of visitors unrelated to research work and their purposes for visitation; sheep and cattle;

observations of individual cats or dogs or packs of dogs; locations and types of refuse or hazardous waste; mining markers or stakes; mill sites; campsites; and evidence of shooting of firearms (shotgun shells, clay pigeons, targets). Historical information should also be recorded when deemed important: abandoned mines and mill sites, abandoned or active railroads, abandoned or active vehicle routes, previous military maneuver or bombing areas, ranching or farming operations, proximity to utility lines and incinerators, etc. Desert tortoises have been found with tar on scutes or caught in tar, with gunshot wounds (Berry, 1986), traumatic and fatal injuries due to military projectiles and tanks, and in the vicinity of hazardous waste materials. Desert tortoises may also become entangled in or consume foreign objects, e.g., string, rubber bands, surveyors tape, aluminum foil (K. Berry, unpubl. data), similar to reports of other chelonians (Balazs, 1985; Reidarson et al., 1994; Mader, 1996).

PROCEDURES TO PREVENT SPREAD OF DISEASES AND PARASITES

Special precautions must be taken to prevent transmission of pathogens causing diseases such as mycoplasmosis (Brown et al., 1994; Jacobson et al., 1995) within and between tortoise populations (Jacobson, 1993, 1994a; Berry, 1997b). The most likely sources of transmission of mycoplasmosis are direct contact, nasal exudate, and aerosols (Brown et al., 1994). The role of mucous droplets in burrows has not been studied and cannot be ruled out.

Each tortoise should be handled with a fresh pair of disposable gloves, which is placed in a plastic trash bag after use and discarded appropriately off-site. Each item of equipment (scales, calipers, ruler) touching the tortoise, including poles used to probe tortoise or other animal burrows and to tap tortoises from burrows (Medica et al., 1986), must be disinfected with a sodium hypochlorite solution (0.175%) or ethanol (70%) immediately after each use

and before being replaced in the carrying case or pack. The sodium hypochlorite solution should be made fresh at least once per week, with both concentrated and diluted solutions protected from excessive heat and sunlight. Precautions must be taken to assure that the tortoise does not touch or rest on the field worker's limbs, clothing, or equipment without protective covering. Other options are to use disposable jump-suits and disposable plastic shoe covers. To prevent contamination, small pieces of disposable paper or plastic sheeting can be placed under the tortoise or on the lap of the field workers. To prevent transmission of disease between study plots, field workers should not travel directly from one site to another without bathing and changing clothes and shoes. Clothes and shoes must be disinfected prior to use on other sites. Depending on the nature of the diseases present at the site, field vehicles may require thorough external and internal cleaning at a car wash.

Careful adherence to the above procedures can also help to reduce transfer of ticks, potential vectors of disease, to humans. The two species of ticks commonly observed on desert tortoises, *Ornithodoros parkeri* and *O. turicata* (Greene, 1983, 1986) are major vectors of the disease agents *Borrelia parkeri* and *B. turicatae* which cause American tickborne relapsing fever in people (Sonenshine, 1993). Humans are rarely involved in the cycle of transmission of these diseases unless they intrude into home sites or nests of the ticks, e.g., tortoise burrows. While no cases of borreliosis transmission from tortoise ticks to humans have been documented, field workers should take precautions when processing tortoises, because *O. parkeri* (and probably *O. turicata*) were found on 5 to 10% of wild desert tortoises in several tortoise surveys conducted between 1970 and 1980 (Greene, 1986). At one site, 43% of active tortoise burrows were infested with *O. parkeri*.

DATA SHEET FOR LIVE DESERT TORTOISES

The Data Sheet for Live Desert Tortoises (Fig. 2) is used for recording basic demographic and ecological data for each tortoise observed and/or captured and contains parameters useful for calculating condition indices and equations related to carapace length and mass. Desert tortoises are long-lived animals, requiring 12 to 20 or more years to reach sexual maturity, and may then live at least 70 or more years (Woodbury and Hardy, 1948; Hardy, 1976; FWS, 1994). Because of their longevity, careful records are essential for determining ecological and behavioral constraints; individual and population growth rates; recruitment of young into adult age classes; survivorship by cohort; causes of mortality; and frequency and types of trauma and disease. Critical parameters include: date, time and precise location of capture; unique tortoise identification number; type of capture (e.g., 1 = first capture, 2 = subsequent recaptures during the year [any year], 3 = first capture of the year for a previously marked tortoise, 5 = a marked tortoise found dead); sex, body measurements and weight; and activities and behaviors.

Each tortoise should be examined to determine whether it is a released captive or previously marked animal from a translocation project or an unauthorized translocation. Signs of previous captivity include: painted initials, numbers, or other writings on the shell; shell discoloration or stains from dyes, ink or paint; file marks or holes drilled in the marginal scutes of the carapace; caked dirt of a different color and type than the parent rock and soils of the study site; and fiberglass, epoxy, or other manufactured materials. Captive tortoises frequently have morphologic anomalies, such as pyramid-shaped scutes (Jackson et al., 1976). Tameness and curiosity are not valid criteria for assessing previous captivity of desert tortoises. Field workers should also ensure that the tortoise is a desert tortoise and not some other *Go-*

pharus spp. or exotic tortoise that was illegally released, by becoming familiar with dichotomous keys and descriptions of similar-appearing species.

Placing a unique identifying mark on a tortoise requires considerable care, because the identification number ideally should last the life of the tortoise. First, field workers must record physical anomalies (shape and number of scutes) on the carapace and plastron diagrams (Fig. 2). Second, based on scutellation, an identifying number is selected and notches are filed in the scutes with a triangular file. Most tortoises ≥ 100 mm mid-carapace length (MCL) are notched on one or more of the marginal scutes using a standard numbering system. Tortoises < 100 mm MCL are notched only on anterior or posterior marginal scutes either with a small triangular file or with nail clippers; the bridge (portion of the shell between the carapace and plastron) is avoided, because notches can penetrate to the bone in this area. Most notches are filed or cut into the keratin of scutes without penetrating to or notching the bone. When scutes are thin, the notch can expose a thin sliver of bone, which may stimulate replacement of both scute and bone and subsequent disappearance of the notch itself. Notches generally are evaluated each year a tortoise population is surveyed and remade or deepened when ambiguous or no longer clearly distinguishable. Notches have remained > 20 yr on some desert tortoises, but may wear away as the tortoise ages, or may disappear if marginal scutes chip or are chewed by predators. Third, the identification number is placed on a scute as a supplemental identification. A dot or smear (about 5–8 mm in diameter) of cream-colored or pale yellow paint is placed on the areola or area formerly covered with the areola of the fourth right costal scute, a site with minimal abrasion, and allowed to dry. Then the number is written on the dried paint. The dot and number should be sufficiently small and obscure to preclude loss of the natural concealing colors of the tortoise

shell. The number is covered with a small dot of Devcon (Devcon Consumer Products, Wood Dale, Illinois, USA) 5 min quick drying epoxy. The number may become obscured if the surface of the epoxy is scratched or covered with dirt, but it can often be read several years later when moistened and rubbed. The painted number reduces field time and handling, because field workers can rapidly identify the tortoise and determine if it was recently processed.

Additional forms of identification include passive integrated transponder (PIT) tags and radio transmitters. The PIT tags can be fastened with epoxy to the dorsal or ventral surface of marginal scutes (Boarman et al., 1998) or injected subcutaneously into the body (a practice which has not been perfected and which we do not advise). The first three forms of identification, coupled with the photographs described below, are essential.

On the first capture of the season and at subsequent capture intervals of two or more weeks, tortoises should be measured for MCL and plastron length from gular to anal notch. We prefer Starrett (L. S. Starrett Co., Athol, Massachusetts, USA) firm joint outside calipers and a 380-mm metal ruler (1 mm increments) for individuals > 125 mm MCL, and dial calipers (130–150 mm, 0.05 to 0.1 mm increments) for individuals < 125 mm MCL, although some researchers use tree calipers. Depending on the size of the tortoise, mass can be recorded using a 100 g Pesola (Geneva, Switzerland) scale (1 g increments) and varying sizes of Chatillon (John Chatillon and Sons, Kew Gardens, New York, USA) scales (1 kg, 20 g increments; 6 kg, 50 g increments; and 12.5 kg, 100 g increments). Tortoises can be suspended in clean plastic bags, or with disposable slings of surveyor's tape or string. Expensive and inexpensive electronic balances are also available but are not necessarily appropriate for carrying in a backpack for processing tortoises a few kilometers from the vehicle.

Several veterinarians have used the relationship of body weight to carapace length to evaluate clinical condition of tortoises, e.g., "Jackson's ratio" (Jackson, 1980; Spratt, 1990; Blakey and Kirkwood, 1995). For the desert tortoise, reliable predictions of health based on weight and carapace length data have not been fruitful, probably because so many different factors (sex, reproductive status, degree of hydration, morphology of the shell) contribute to weight (Jacobson et al., 1993). Another approach is the development of a condition index such as body mass (g) divided by the cube of MCL (Wallis et al., 1999; see also Bonnet and Naulleau, 1994 for a different method).

The sex of each tortoise ≥ 180 mm MCL is assigned using several secondary sex characteristics: MCL, presence and condition of chin or mental glands (Alberts et al., 1994), size and curvature of the gular horn, the presence or absence of a concavity on the posterior plastron, and tail length. Reliable sexing of individuals < 180 mm MCL requires laparoscopy (Rostal et al., 1994b) and is rarely done in the field. Smaller tortoises are assigned, unsexed, to juvenile (< 100 mm MCL) or immature (100–179 mm MCL) size classes. Sexing a young or small adult (180–205 mm MCL) can be difficult, because the upturned gular horn and plastral concavity typical of males are unlikely to be well defined or fully developed until the tortoise is > 210 mm MCL. Gular horns of males are often damaged by predators, and some males may not have an intact gular to evaluate. In contrast to males, the posterior plastron of a female is almost always flat or imperceptibly concave. The female gular is almost always flat, or only the lateral edges are slightly upturned. Tail length, a trait that changes with age, is longer in the male than the female. In young or small adults, the differences can be only a few mm. As the male ages and grows larger, tail length increases and differences between the sexes become more pronounced.

Two paired integumentary chin or mental glands are located below the mandibles (Alberts et al., 1994) and can be used to determine sex in adults. The volume of adult female chin glands is so small that secretion samples cannot be collected. In contrast the volume of adult male chin glands is greater, secretions can be collected, and the gland volume varies according to season. Male chin glands are relatively small in late spring and peak in size in late summer, a time when courtship, mating and aggressive behaviors frequently occur. Mean gland volume of males is also positively correlated with mean plasma testosterone concentration (Rostal et al., 1994a; Alberts et al., 1994) and is generally greater in dominant males than in subordinate males (Alberts et al., 1994). When the sex is in doubt or the field worker has limited experience, 35-mm slides should be taken of the head, chin glands, gular, posterior plastron and tail for retrospective evaluation by an expert.

The precise location of each tortoise is essential to record. Tortoises exhibit fidelity to burrows and dens, have established home ranges, and can spend a lifetime within limited, circumscribed home ranges or activity areas (FWS, 1994). As such, they can serve as sentinels of environmental conditions. When capture sites are accurately recorded, animals can be recaptured more easily for health evaluations, salvage, or demographic studies.

To determine whether the tortoise is or has been actively growing within the last few months, the seams between scutes should be inspected for the presence of a narrow (generally < 2 mm) band of softer grey or lightly pigmented keratin. Within a few months the band will harden and form a new ring, gradually assuming the color of the portions of the scute adjacent to the seam. These lines or rings do not represent annular rings, because no rings or more than one ring may be formed in a single season (Zug, 1991).

THE HEALTH PROFILE FORM

The Health Profile Form (Fig. 3) was developed to assess health and well being of the tortoise and was revised several times between 1989 and 1998. It incorporates standard parameters used to evaluate captive chelonians (Jackson, 1987, 1991; Mautino and Page, 1993; Mader, 1996), as well as new parameters associated with recently described and commonly observed diseases. Field workers preferred the single page, circling or checking responses, and a limited protocol. We obtained the best results from the form shown in Figure 3, coupled with photographs. There is some overlap in the Live Tortoise Form and the Health Profile Form, enabling the development and use of separate databases by interdisciplinary teams of research scientists.

The tortoise should first be observed from a distance, and if possible, before it responds with defensive or aggressive postures or movements. Critical factors include postures, particularly position of the head and limbs, and movement of the limbs and body; activities and behaviors; and general and specific locations in the environment. Shortly after emergence from hibernation in late winter or early spring, the normal suite of behaviors includes: basking at the mouth of the burrow or on the burrow mound with limbs fully extended and directed forward with the plastron on the soil, walking, foraging, resting in the shade of a shrub or tree, or (late in the day) facing into the burrow, partially down or at the end of the tunnel. Atypical and abnormal behaviors include: remaining overnight above ground in freezing temperatures or remaining in the same place outside the burrow for more than one day at any time of year. One abnormal posture signals chronic illness: the tortoise rests with head down and partially withdrawn, forelegs partially spread apart and with the dorsal surface rotated outward and forward. The limbs are limp and the tortoise appears lethargic and weak.

Lethargy and weakness in a free-living tortoise are clinical signs of chronic disease. During the activity season (March–October), most tortoises should be alert and responsive under normal operating temperatures (Berry and Turner, 1986; Zimmerman et al., 1994), and able to withdraw head and limbs quickly and tightly into the shell when prodded. If environmental temperatures are at or near freezing, or skies are overcast and weather generally cold, the responses of a normal, healthy tortoise will be slower.

Observations of the limbs, head, beak, nares, eyes, chin glands, and oral cavity can be difficult or impossible to make if head and limbs are retracted tightly into the shell in a defensive posture. With field time at a premium, the field worker may have to abandon attempts to record most health data on such tortoises. If, however, the health profile evaluation is performed after the Data Sheet for Live Desert Tortoises is filled out, then the tortoise may relax and become curious. One technique to expose the limbs and head is to place the tortoise right side up on an inverted coffee can covered with a single-use clean paper towel. Some tortoises will extend head and limbs and flail, allowing an excellent view and an opportunity to photograph eyes, nares, and head.

The shell and integument should be evaluated when clean. Most shells have a little, easily removable dust and dirt. When wiped and rubbed free of dust and dirt, the integument should be glossy. After rain, some tortoises become so heavily caked in dirt or mud that the shell must be cleaned with a brush and the extremities rinsed with water prior to examination. For the shell and scales, important factors to consider are whether scales and scutes are clean and glossy (similar in appearance to the skin of a snake that has freshly shed) or are dull, dried-out in appearance, discolored, caked with dirt or mucus, or covered with fungi.

The general appearance of limbs and head are indicators of health status. An

emaciated head, sunken eyes, and emaciated or cachectic limbs may be signs of dehydration, starvation or chronic URTD. Other factors to look for include swollen limbs, neck, and cloaca; and swellings in the inguinal or axillary area.

The beak, nares, eyes, and chin glands provide subtle signs indicative of health or disease. Since the desert tortoise lives in an arid environment and frequently experiences drought, dehydration, and accompanying weight loss (Henen et al., 1998), it may not always exhibit obvious clinical disease signs such as nasal and ocular discharges. Nasal and ocular discharges may be intermittent. Therefore, the field worker must look for evidence of recent moisture associated with the eyes, nares, and beak. Tortoises with rhinitis or URTD may have wet or damp nares, and nasal exudate. The amount, color, consistency, and turbidity of any exudate (e.g., clear, cloudy, white, yellow, and green) should be recorded (Jacobson et al., 1991). Tortoises may blow bubbles from the nares or one or both nares may be occluded. On rare occasions, a healthy tortoise may exhibit what appears to be a clear nasal discharge, possibly associated with consumption of lush, succulent vegetation in spring. Dirt adhered to dried mucus on the beak or nares may be a sign of illness, but tortoises that have been drinking from depressions in the soil during a thunderstorm may also have dirt on the beak, nares and forelimbs. Tortoises with a tenacious exudate may have moisture or dried dirt on the medial surface of the forelegs from wiping the face, eyes, and beak with their forelegs. In severe cases, the integument between the scales of the forelegs may have cracked. Inflammation and congestion of the respiratory tract may alter breathing, so respiratory sounds should be evaluated for wheezing, rasping, and clicking noises. Severely affected individuals may extend their necks and open their mouths to breathe. Consequently, breathing may look and sound labored.

The color, surface, and condition of the

beak may reflect health status as well as recently consumed food items. When forage is plentiful, the beak should have green or other colored stains from recently consumed leaves, flowers, and fruits. Occasionally beaks will be caked with dried flesh of cactus fruits or dried sap from plants. In years when forage is plentiful, the observer should suspect illness in a thin, low weight, inactive tortoise that shows no evidence of recent food consumption or color on the beak. The chin or mental glands may be abnormally swollen and draining. If swollen, the dimensions of each gland should be measured to estimate volume (see Alberts et al., 1994 for measurements and formula).

The surface of the eye, appearance of palpebrae (eyelids), and periorcular region should be examined closely for abnormal color; presence of dampness, mucus or drainage; and edema—all of which may be signs of URTD (Jacobson et al., 1991; Brown et al., 1994), rhinitis (Jackson, 1991) or other illnesses. The palpebrae are normally dry, unscaled, wrinkled, and delicate in appearance (Fig. 4A–C). The periorcular area, separated dorsally and ventrally from the palpebrae by a furrow, is covered with small scales and is also normally dry and flat. The normal surface of the globe usually does not have visible strands or patches of mucus. To assess the eye and adnexal structures, we developed a grading scheme for the palpebrae and periorcular areas. Palpebrae should be evaluated for swelling (edema) and dampness (Fig. 4D–L), and the periorcular area surrounding the eye also may be swollen (Fig. 4E–K; also compare Fig. 4C with Fig. 4H). The degree of closure of lids on both eyes should be noted, as well as outward bulging, swelling or a sunken appearance within the orbit (compare Fig. 4C with Fig. 4H and 4L). Clinical signs (Figs. 3, 4) should be rated by degree of severity in each eye, with 1 = normal, 2 = mild, 3 = moderately severe, and 4 = severe or marked. Ratings may be accomplished with supplements (e.g., Appendix 1) to

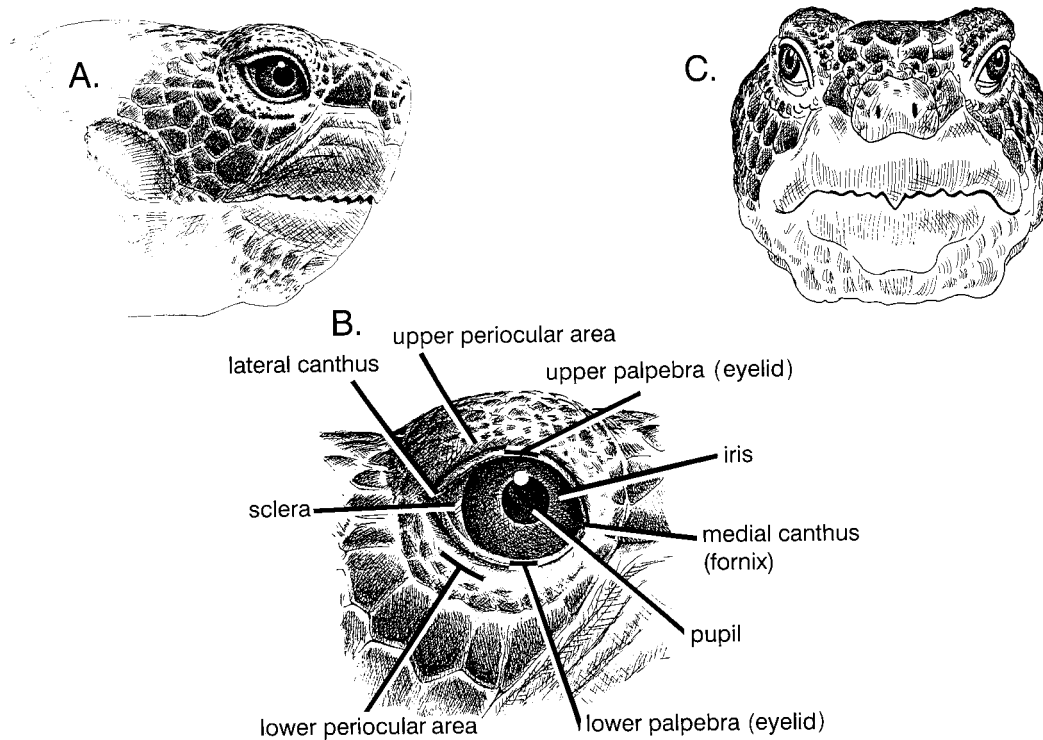


FIGURE 4. A–C. Line drawings of the desert tortoise head depicting anatomical landmarks. A. Lateral view of normal eye, palpebrae (eyelids) and periocular area in the context of the tortoise's head. B. Magnified lateral view of the normal eye, with upper and lower palpebra (lacking scales), periocular areas (scaled) and other anatomical structures denoted. C. Frontal view of the head and normal eye area.

standard health forms (Fig. 3). Appendix 1 is for the well-trained or advanced field biologist working with diseases of the eye or upper respiratory tract.

The mouth of the tortoise is usually closed and separating the jaws is likely to induce additional stress. Unless the research program is focused on health and diseases, we recommend that data on the oral cavity be gathered opportunistically if the tortoise gapes or if the mouth is easily opened. The tongue is covered by a thick

layer of cornified epithelium and the mouth has numerous mucous glands (Barboza, 1995). If the oral cavity is examined, the following data should be recorded: smell; general color and localized spots; and the presence of plaques, swellings, blisters, ulcers, stains, lesions, and foreign objects (e.g., embedded plant spines).

Wild desert tortoises >120 mm MCL are likely to have some lesions on their scutes, underlying dermal bone, and/or extremities. Occasionally to frequently, field

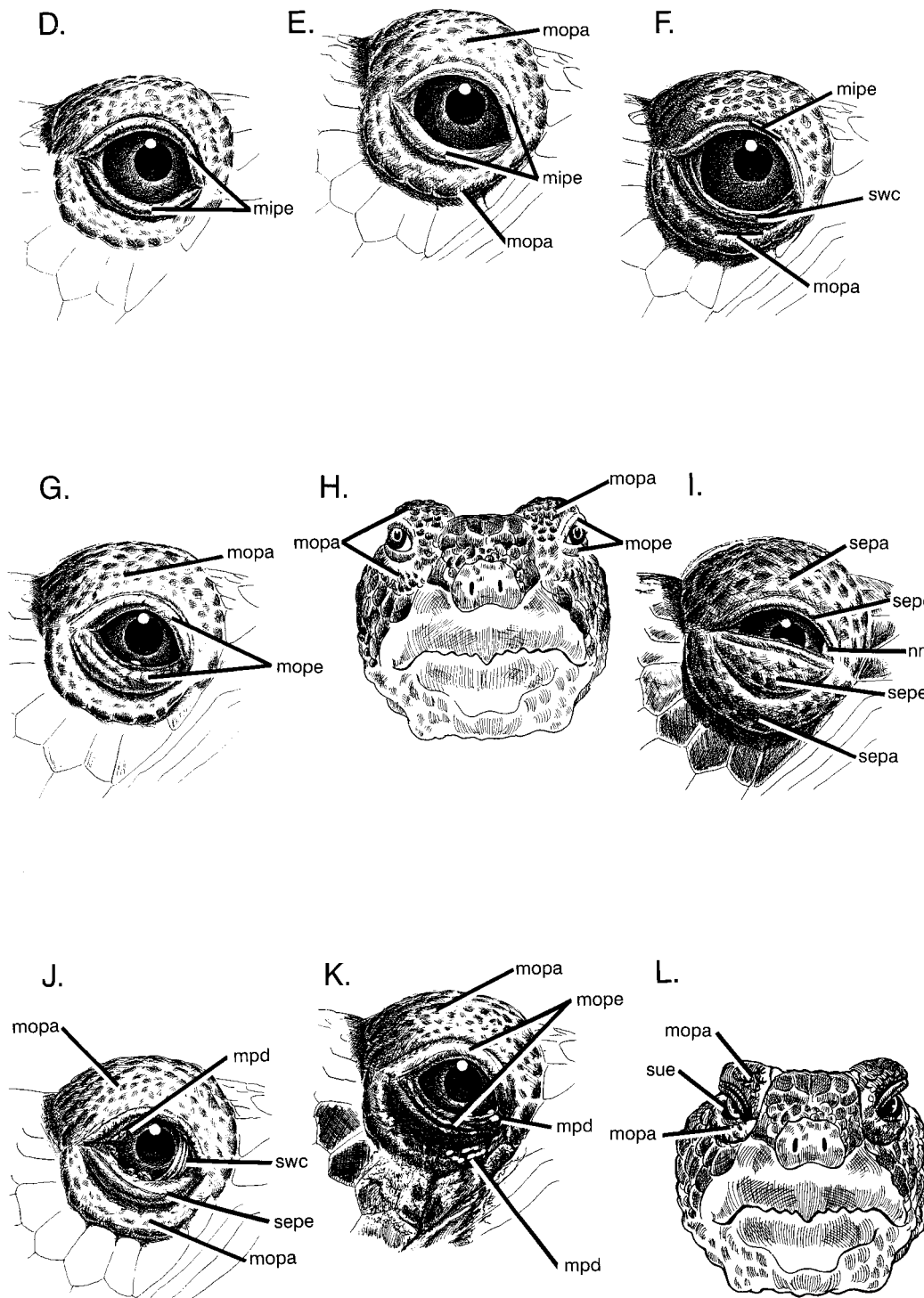


FIGURE 4. D–L. Same as 4 A–C showing ocular abnormalities commonly associated with upper respiratory disease infection and other ocular disorders. Abbreviations for D–L: mipe = mild palpebral edema; mopa = moderate edema of the periocular area; mope = moderate palpebral edema; mpd = mucopurulent discharge; nm = nictitating membrane; sepa = severe edema of the periocular area; sepe = severe palpebral edema; sue = sunken, recessed eyes; swc = swollen conjunctiva. D. Mild edema (chemosis) of the upper and lower palpebrae. E. Moderate edema of the palpebrae, conjunctiva, and upper and lower periocular areas.

biologists observe: chips of keratin and bone missing from marginal scutes; missing limbs, toenails, or scales on limbs; healed or healing tooth marks, chew marks or punctures (penetrating scute to bone) from predators; cutaneous dyskeratosis (Jacobson et al., 1994; Homer et al., 1998); depressions in scutes and underlying bone; and exposed, white or dark discolored bone, potentially indicative of necrosis (Homer et al., 1998). The location of all lesions should be drawn on the diagrams of scutes, described carefully, and photographed. Signs of predator attack should include notes on the potential predator (including feral dogs and cats), as indicated by size, location, and type of puncture, scratch or tear. The relative age of the wound or lesion should be recorded. Wounds or lesions may be fresh, in the process of healing, or evident as scars. Such data, when compiled over several years, can be used to: (1) compare survivorship of the different age classes of tortoises to predator attacks, and (2) measure predator pressures on populations. For example, the technique of recording scars of predator attacks has been successfully used with the scorpion mud turtle (*Kinosternon scorpioides*) to measure predation pressure by jaguars in different habitats (Acuña-Mesen, 1994).

Most desert tortoise populations contain individuals with cutaneous dyskeratosis, as manifested by discolored and flaky scutes. The lesions usually are associated with the seams of the plastron and spread outward from the seams in irregular patterns (Ja-

cobson et al., 1994; Homer et al., 1998). The damaged portions of scutes are whitish grey, sometimes orange, slightly raised and flaking. In severe cases, tortoises with thin, peeling laminae and exposed bone may be more vulnerable to bacterial and fungal infections and predation (Homer et al., 1998). Cutaneous dyskeratosis and other shell diseases should be graded by distribution on the shell, severity, and approximate age of lesion or chronicity for each of three body regions, the carapace, plastron, and limbs (Table 1). A variation of the scale shown in Table 1 can also be used to record the presence of fungi, which may be present on tortoises that hibernated in damp or wet burrows.

Depressions in scutes should be recorded on the Health Profile Form and carefully photographed. Depressions in juvenile and immature tortoises (<180 mm MCL) may be due to malnutrition and metabolic bone disease, whereas in old adult tortoises the depressions may be a normal part of the aging process. Vermiculations between the scute and bone should be noted.

If the tortoise urinates (which frequently occurs when a hydrated tortoise is handled), the amount, color, viscosity and size of particles in the urine sediment should be evaluated. The color of normal urine is dependent on the level of hydration, with colorless, clear urine produced by a fully hydrated animal and very dark brown and concentrated urine typical of a tortoise dehydrated from prolonged drought (Nagy and Medica, 1986; Peterson, 1996a). The

←

F. Mild edema of the upper and lower palpebra, moderate edema of the periorbital areas. G. Moderate edema of the palpebrae, with dorsal and lateral displacement of the eye from moderate edema within or adjacent to the orbit. Palpebra with this degree of swelling may appear translucent. H. Frontal view of 4G. I. Marked or severe edema of the upper and lower palpebrae and periorbital areas, with bulging of the eye laterally. The scaled periocular area is swollen into prominent folds or bags, resulting in partial closure of the eye. The nictitating membrane (3rd eyelid) is visible in the fornix (arrow). J. Similar to 4G, with mucus on the eyeball surface, spilling onto lower lid, and swollen conjunctiva. K. Moderate edema of the palpebrae and periorbital areas. Mucoid or mucopurulent discharge has accumulated in the medial canthus (fornix) area and spilled over onto the surrounding skin. Dirt may admix with the mucus, resulting in dried dirty crusts around the eye. L. The sunken eye, partially closed.

TABLE 1. System for grading shell lesions such as cutaneous dyskeratosis in desert tortoises. The carapace, plastron, and integument on limbs and head should be rated separately.

I. Shell lesions: source
1 = From trauma
2 = From disease (specify cutaneous dyskeratosis, necrosis, fungi, or other)
II. Distribution: specify by plastron, carapace, limbs, or head
1 = Not present, no signs of lesions
2 = Mild, lesions manifested primarily at seams, covers less than 10% of plastron (or carapace or limbs, etc.)
3 = Moderate, covers 11%–40%
4 = Severe, covers > 40%
III. Severity of lesions (from disease, e.g., cutaneous dyskeratosis)
1 = No lesions
2 = Mild, discoloration follows edges of lifting laminae, lightly discolored, flaking
3 = Moderate, discoloration extends over several layers of laminae, edges of laminae flaking, scutes may be thin in small areas, and potential exists for small holes and openings exposing bone
4 = Severe, some scutes or parts of scutes eroded away or missing and bone exposed, eroded, or damaged
IV. Chronicity of lesions (from disease, e.g., cutaneous dyskeratosis)
1 = No lesions
2 = Old lesions, no apparent recent activity, signs of regression or recovery; development of healthy, normal laminae is apparent at seams of scutes
3 = Active, current lesions

urine may be various shades of yellow, burgundy, or brown color and contain gelatinous material and precipitated urate crystals ranging from greyish white to pink, yellow, and brown in color. Since survivorship of tortoises may be affected by loss of bladder fluid (Averill-Murray, 1998), protocols for handling tortoises should minimize contact time. Fecal samples should be collected when available for analysis of internal parasites.

All ectoparasites on tortoises should be considered significant (Jacobson, 1994b). Ticks can injure a tortoise or transmit parasites, spirochetes, or viruses (Sonenshine, 1993). Records should be compiled by species of tick and should include (for each tick): numbers, attachment site or location in general (e.g., number and name of scute), specific attachment site or location (pit, chip, seam, new growth tissue, injury), size, developmental stage, sex, degree of engorgement, and activity (resting, feeding, moving) (Fig. 3). Recent attachment sites, such as small bloodied areas of seam between scutes, should also be recorded. Reference specimens should be collected and stored in appropriate museum collections, and the taxonomic identification should be confirmed (see Sonenshine, 1993 for methods). The ticks should be removed for accurate counts, identification, and determination of sex.

The most common ectoparasites recorded for desert tortoises are the nidicolous Argasid ticks, *Ornithodoros parkeri* and *O. turicata* (Greene, 1986). Their life span is at least several years (20 years in the case of some argasid ticks), and they can survive long periods of starvation (Sonenshine, 1991). All stages of these ticks parasitize wild desert tortoises (Greene, 1986). They tend to be found on the posterior carapace, often attaching at the seams between scutes, or at the site of old injuries. Attachment at a site of injury is also typical of *Hyalomma aegyptium*, the tortoise tick that parasitizes *Testudo graeca* (Petney and Al-Yaman, 1985). Other ticks, e.g., *Amblyomma marmoratum* on *G. pardalis*, showed patterns of seasonal abundance, as well as gender preferences for site attachments (Rechav and Fielden, 1995).

PERMANENT PHOTOGRAPHIC RECORDS

Full-frame images of the head, carapace, plastron, and the fourth costal scute of each tortoise should be taken with 35-mm slide film at least once during each survey year for identification, to gather data on numbers of growth rings produced and how the growth rings change in appearance over time, to verify how contours of the shell age, and to confirm how damaged shell replaces itself over time. Additional photographs can be taken of recent

or previously healed injuries to the head, limbs, or shell, or unusual abnormalities. The 35-mm slides are useful for confirming identification of tortoises which have not been observed for many years, which had very small notches when marked as juveniles and grew to large adults without being captured in the intervening period, or which have lost one or more notches from predator attacks. The relative sizes of scutes and seams form unique patterns which persist from the late juvenile sizes through life, much like a fingerprint. Slide transparencies and permanent notches on the shell were used to identify desert tortoises illegally taken from the desert in May 1993 and to support a court case (K. H. Berry, unpubl. data). Similarly, the British Chelonian Group has set up a registration program for captive tortoises using photographs for identification (Jackson, 1991).

Even when tortoises have died and only part of the shell persists, the identities can be determined by using a combination of 35-mm slides, numbers on the costal scutes, and notches in one or more scutes. Disarticulated scutes and bones can be re-assembled and the pattern of scutes discerned on the external surfaces of the bones. Notches or the indentation from notches often can be seen in the marginal and bridge bones.

Permanent photographic records have proved invaluable for retrospective analyses of progression and regression of signs of diseases in individual animals and populations, including cutaneous dyskeratosis and other shell lesions (Jacobson et al., 1994; Homer et al., 1998); URTD (Brown et al., 1999); traumatic injuries; and epidemiological research. Photographs also have proven to be a valid and reliable approach for grading trachoma in humans (West and Taylor, 1990). Close-up views of eyes and shells of the tortoises were especially critical for interpretation and grading of diseases and trauma (e.g., Jacobson et al., 1994; Brown et al., 1999; Christopher et al., 1999) and proved more

reliable and consistent than the field evaluations.

Research veterinarians or health specialists can interpret slides and photographs and recommend whether to have a veterinarian visit the animal(s) in the field or to salvage the tortoise for necropsy. For consistent and effective interpretation, the film (manufacturer, brand, and speed) should remain the same for the entire project, because different types of films (with subtle color shading) render consistent interpretation difficult. For ease in storage, handling, and making comparisons, we recommend 35-mm slide transparencies and storage in archival slide sheets. New technologies, e.g., digital images archived on compact disks, are now available and offer numerous opportunities, such as automating assessments of health and disease and comparing different images of the same animal. For long-term projects with long-lived species, researchers should determine the level of detail available from film versus pixelated images, stability and longevity of the media, and ability to retrieve usable images after decades.

Cameras, including macro lenses, should be essential field equipment, and the ability to produce high quality, close-up photographs should be a job requirement. Lighting is critical for photographing animals, so skill with flash units should be another prerequisite for field workers.

SALVAGING ILL TORTOISES FOR NECROPSY

Necropsies of ill, dying, or recently dead wild tortoises provide a wealth of information about causes of death in populations and should be incorporated into field research protocols (Homer et al., 1998). Preparations for salvaging live or dead wild tortoises for necropsies must be made in advance by obtaining appropriate permits from the U.S. Fish and Wildlife Service and state fish and wildlife agencies, arranging for the services of a veterinary pathologist familiar with reptiles, identifying the types of tests to be made, and determining requirements of air freight lines

TABLE 2. General condition of 59 desert tortoises salvaged for necropsies between 1989 and 1996 on the senior author's scientific research permits.

	Condition of tortoises at time of salvage				Pathologist or reference
	Dead	Dying	Ill		
			Alert ^a	Lethargic	
			12		Jacobson et al., 1991
	1		3	2	E. R. Jacobson and J. Gaskin (Bureau of Land Management [BLM] files, 1990)
	1		2	2	J. Klaassen (BLM files, 1991)
	2	3	11	8	Homer et al., 1998
	8	0	4	0	Homer et al., 1998
Totals	12	3	32	12	

^a Ill but alert tortoises were generally salvaged on the basis of clinical evidence of upper respiratory tract disease or shell lesions.

(shipping boxes, shipping papers). If a forensic necropsy is required, a veterinary pathologist with formal training, board certification by the American College of Veterinary Pathologists, and experience with reptiles should be obtained (Wobeser, 1996).

More data can be obtained from a live tortoise than from a dead tortoise. Frozen remains are of limited value for most pathologic studies, other than gross visual examination and toxicant analyses. We ship live tortoises packed in loose newspaper in two sizes (13.5 cm high × 70 cm long × 70 cm wide; 25 cm high × 70 cm long × 70 cm wide) of specially made plywood boxes with screw-top lids cut with 27, 2-cm in diameter holes (nine holes on the top, six holes on each of three vertical sides). The boxes are designed to allow the tortoises to move about, but the limited vertical clearance inhibits climbing and overturning. Information about the live animal, shipping times and routes, name and phone numbers of the receiving veterinarian, the health and scientific research and salvage permits are placed in an envelope and taped to the top of the container. Recently dead (<48 hr) tortoises can be shipped chilled on ice in an ice chest via one of the 24 hr mail services. Frozen remains can be shipped on dry ice.

Decisions on criteria for salvage require

advance planning and can be placed in three categories: (1) opportunistic salvage of recently dead tortoises, (2) opportunistic salvage of severely injured and dying tortoises, and (3) the deliberate and planned salvage of animals with specific behavioral abnormalities, signs of disease or syndromes for special research projects. We retrospectively evaluated records of 59 desert tortoises removed from the wild between 1989 and 1996 (Table 2), and developed salvage criteria using clinical signs of disease and abnormal behavior. The criteria for salvage are met when tortoises have one or more of the following attributes: (1) is severely injured and unlikely to survive as a result of vehicle-related or predator-caused trauma; (2) is lethargic, inactive, or non-responsive during the activity season; (3) is emaciated or severely dehydrated and of very low weight for the carapace length; (4) exhibits progressive weight loss over a 1- to 2-yr period, not associated with drought; (5) exhibits abnormally low growth rates over a several-year period; (6) exhibits weakness associated with limb atrophy; (7) exhibits cachexia with no apparent weight loss (may have uroliths); (8) is incapable of retracting limbs into the shell or is partially paralyzed; (9) has active shell lesions (from cutaneous dyskeratosis or necrosis, not trauma) covering ≥40% of the plastron or car-

apace; (10) has scutes sloughing or loose, if the loosening and sloughing are not part of a healing or scute replacement process from trauma; (11) has scales peeling or sloughing from the limbs or head in patches, not due to trauma; and (12) has moderate to severe edema of the palpebrae and periocular area, especially if accompanied by a mucopurulent nasal or ocular discharge and signs of chronic discharge on forelimbs, eyes, and beak. Salvage is inappropriate solely when a limb is lost from a predator attack, because some tortoises recover and function quite well in the wild. The monitoring of individual tortoises and environmental conditions will help to determine the cause and severity of some clinical signs of disease. For example, weight loss can be an early sign of disease (Jackson, 1980; Oettle et al., 1990), as well as a normal response to drought, hibernation, and estivation (Peterson, 1996a, b; Henen, 1997).

Subtle behaviors can provide evidence of illness and justification for salvage. Each of the lethargic and inactive tortoises and some of the alert and active tortoises (Table 2) provided one or more additional behavioral clues of their status for several weeks or months prior to death: they were active and above ground at inappropriate times of year, failed to emerge or were late (several weeks or months) in emerging from hibernation, failed to return to burrows and typical sleeping places at night or during hot times of day (see also Oettle et al., 1990), remained in a resting position in one place day after day, and failed to eat when forage was readily available or failed to drink during a warm rain.

Decisions about salvage, whether for a specific research project or because the tortoise may have reached a “point of no return” can be difficult. An animal can only be evaluated in the field up to a point; without a necropsy there is no total certainty about physical status. Difficult cases may be resolved through a team effort between the wildlife health specialist, research veterinarian, and field biologist us-

ing a cell phone from the field (a requirement now for our field staff) or a visit to the field. No substitutes exist for experience, good judgment and common sense, however.

SUMMARY

Health assessments of wild animals are becoming more common, and often include blood sampling, complete blood counts and biochemical profiles, as well as analyses for vitamins, minerals, and organochemical compounds (e.g., Calle et al., 1994; Dunlap, 1995; Christopher et al., 1999). We recommend that the health assessments described herein become required and standard guidelines for prescreening any animal to be used in a research project, whether the research project is conducted by veterinarians, herpetologists, ecologists, or zoologists. Historically, most researchers have assumed that wild chelonians were healthy without evaluating clinical signs of disease or conducting lab tests. If research animals were ill and the information was not included in methods or results, the results and interpretations may be erroneous. Health assessments are also essential for any chelonian breeding program, as well as translocation, relocation, or repatriation programs (Jacobson, 1993, 1994a, 1994b; Cunningham, 1996).

The evaluation of clinical signs will be most reliable and effective when the clinician or field biologist has a broad knowledge of the wild animal's normal and abnormal appearance, postures, and behaviors by season and region, and a great deal of field experience. Field personnel are likely to be more reliable and consistent observers after viewing hundreds of animals with a wide range of conditions. When the species in question is rare, threatened, or endangered, field sample sizes are usually limited. In such cases the field team may gain experience using dozens of ill and healthy captive tortoises. Field personnel should also take precautions to prevent transmission of pathogens

(e.g., Ahne, 1993; Cunningham 1996) from one individual animal to another and from one population to another.

Field personnel, wildlife health specialists, and veterinarians can use the data obtained through these methods to develop comprehensive databases on clinical and behavioral signs of health and disease for desert tortoises or other species. Clinical and behavioral signs should be quantified using consistent methodologies, and the relationships between clinical signs, behavioral data, and laboratory data compared. New statistical procedures are available to study links between behavioral characteristics and disease (e.g., Escós et al., 1995).

ACKNOWLEDGMENTS

We are grateful to B. L. Burge, B. T. Henen, B. Homer, F. Hoover, E. R. Jacobson, G. McLaughlin, and R. C. Stebbins for constructive comments on the manuscript, and to B. T. Henen and K. A. Nagy who took photographs for tortoises in the health profile research program under Bureau of Land Management (BLM) Contract No. YA651-CT0-340079. T. Shields prepared the illustrations of desert tortoise eyes and R. C. Stebbins, B. T. Henen, and G. McLaughlin provided valuable comments. Dr. Stebbins checked the illustrations of the healthy eye with preserved specimens at the Museum of Vertebrate Zoology, and Dr. Henen compared the illustrations with over one dozen tortoises at the Desert Tortoise Conservation Center in Las Vegas. The BLM and National Biological Service (NBS) supported the work undertaken by K. H. Berry. The BLM and NBS supported M. Christopher through Contracts No. B950-C1-0060 and 14-48-0006-95-003, respectively.

LITERATURE CITED

- ACUÑA-MESEN, R. A. 1994. Variación morfológica y características ecológicas del hábitat de la tortuga candado *Kinosternon scorpioides* en Costa Rica (Chelonia, Kinosternidae). *Revista Brasileira de Biología* 54: 537–547.
- AHNE, W. 1993. Viruses of chelonia. *Journal of Veterinary Medicine* B. 40: 35–45.
- ALBERTS, A. C., D. C. ROSTAL, AND V. A. LANCE. 1994. Studies on the chemistry and social significance of chin gland secretions in the desert tortoise, *Gopherus agassizii*. *Herpetological Monographs* 8: 116–124.
- AVERILL-MURRAY, R. C. 1998. Effects on growth and survival of tortoises voiding their bladders during handling. *In* Proceedings of the Desert Tortoise Council Symposium 1998–1999, B. Bartholomew (ed.). The Desert Tortoise Council, Inc., Wrightwood, California, pp. 99–100.
- BALAZS, G. H. 1985. Impact of ocean debris on marine turtles: Entanglement and ingestion. *In* Proceedings of the Workshop on the Fate and Impact of Marine Debris, R. S. Shomura and H. O. Yoshida (eds.). U.S. Department of Commerce, National Oceanic and Atmospheric Administration and National Marine Fisheries Service, NOAA-TM-NMFS-SWFC-54, Honolulu, Hawaii, pp. 387–429.
- BARBOZA, P. S. 1995. Digesta passage and functional anatomy of the digestive tract in the desert tortoise (*Xerobates agassizii*). *Journal of Comparative Physiology B* 165: 193–202.
- . 1986. Incidence of gunshot deaths in desert tortoises in California. *Wildlife Society Bulletin* 14: 127–132.
- BERRY, K. H. 1997a. The Desert Tortoise Recovery Plan: An ambitious effort to conserve biodiversity in the Mojave and Colorado deserts of the United States. *In* Proceedings: Conservation, Restoration, and Management of Tortoises and Turtles—An International Conference, J. Van Abbema (ed.). Wildlife Conservation Society Turtle Recovery Program and the New York Turtle and Tortoise Society, New York, New York, pp. 430–440.
- . 1997b. Demographic consequences of disease in two desert tortoise populations in California, USA. *In* Proceedings: Conservation, Restoration, and Management of Tortoises and Turtles—An International Conference, J. Van Abbema (ed.). Wildlife Conservation Society Turtle Recovery Program and the New York Turtle and Tortoise Society, New York, New York, pp. 91–97.
- , AND P. A. MEDICA. 1995. Desert tortoises in the Mojave and Colorado deserts. *In* Our Living Resources: A Report to the Nation on the Distribution, Abundance, and Health of U.S. Plants, Animals, and Ecosystems, E. T. LaRoe, G. S. Farris, C. E. Puckett, P. D. Doran, and M. J. Mac (eds.). U.S. Department of the Interior, National Biological Service, Washington D. C., pp. 135–137.
- , AND F. B. TURNER. 1986. Spring activities and habits of juvenile desert tortoises, *Gopherus agassizii*, in California. *Copeia* 1986: 1010–1012.
- BLAKEY, C. S. G., AND J. K. KIRKWOOD. 1995. Body mass to length relationships in chelonia. *Veterinary Record* 136: 566–568.
- BOARMAN, W. I., M. L. BEIGEL, G. C. GOODLETT, AND M. SAZAKI. 1998. A passive integrated transponder system for tracking animal movements. *Wildlife Society Bulletin* 26: 886–991.
- BONNET, X., AND G. NAULLEAU. 1994. Utilisation d'un indice de condition corporelle (BCI) pour

- l'etude de la reproduction chez les serpents. Comptes Rendus de l'Academie des Sciences. Paris, Sciences de la vie, Biologie et pathologie animale. 317: 34–41.
- BOYCE, W., T. YUILL, J. HOMAN, AND D. JESSUP. 1992. A role for veterinarians in wildlife health and conservation biology. *Journal of the American Veterinary Medical Association* 200: 435–437.
- BROWN, D. R., B. C. CRENSHAW, G. S. MCLAUGHLIN, I. M. SCHUMACHER, C. E. MCKENNA, P. A. KLEIN, E. R. JACOBSON, AND M. B. BROWN. 1995. Taxonomic analysis of the tortoise mycoplasmas *Mycoplasma agassizii* and *Mycoplasma testudinis* by 16S rRNA gene sequence comparison. *International Journal of Systematic Bacteriology* 45: 348–350.
- BROWN, M. B., I. M. SCHUMACHER, P. A. KLEIN, K. HARRIS, T. CORRELL, AND E. R. JACOBSON. 1994. *Mycoplasma agassizii* causes upper respiratory tract disease in the desert tortoise. *Infection and Immunity* 62: 4580–4586.
- , K. H. BERRY, I. M. SCHUMACHER, K. A. NAGY, M. M. CHRISTOPHER, AND P. A. KLEIN. 1999. Seroprevalence of upper respiratory tract disease in the desert tortoise in California. *Journal of Wildlife Diseases* 35: 716–727.
- CALLE, P. P., J. RIVAS, M. MUNOZ, J. THORBJARNARSON, E. S. DIERENFELD, W. HOLMSTROM, W. E. BRASELTON, AND W. B. KARESH. 1994. Health assessment of free-ranging anacondas (*Eunectes murinus*) in Venezuela. *Journal of Zoo and Wildlife Medicine* 25: 53–62.
- CHRISTOPHER, M. M., K. H. BERRY, I. R. WALLIS, K. A. NAGY, B. T. HENEN, AND C. C. PETERSON. 1999. Reference intervals and physiologic alterations in hematologic and biochemical values of free-ranging desert tortoises in the Mojave Desert. *Journal of Wildlife Diseases* 35: 212–238.
- CUNNINGHAM, A. A. 1996. Disease risks of wildlife translocations. *Conservation Biology* 10: 349–353.
- DICKINSON, V. M., T. DUCK, C. R. SCHWALBE, AND J. L. JARCHOW. 1995. Health studies of free-ranging Mojave Desert tortoises in Utah and Arizona. A Final Report. Arizona Game and Fish Department, Phoenix, Arizona. Research Branch Technical Report No. 21, 70 pp.
- DUNLAP, K. D. 1995. External and internal influences on indices of physiological stress: II. Seasonal and size-related variations in blood composition in free-living lizards, *Sceloporus occidentalis*. *Journal of Experimental Zoology* 272: 85–94.
- ESCÓS, J. M., C. L. ALADOS, AND J. M. EMLÉN. 1995. Fractal structures and fractal functions as disease indicators. *Oikos* 74: 310–314.
- FISH AND WILDLIFE SERVICE. 1994. Desert Tortoise (Mojave Population) Recovery Plan. U.S. Department of the Interior, Fish and Wildlife Service, Portland, Oregon, 73 pp. with Appendices.
- GREENE, G. E. 1983. Ectoparasites of the desert tortoise, *Gopherus agassizii*, with emphasis on the soft ticks of the genus *Ornithodoros* (Acari: Argasidae). In *Proceedings of the Desert Tortoise Council Symposium*, K. Hashagen (ed.). The Desert Tortoise Council, Inc., Long Beach, California, pp. 117–125.
- . 1986. Ectoparasites of the desert tortoise, *Gopherus agassizii*, with emphasis on soft ticks of the genus *Ornithodoros* (Acari: Argasidae). Thesis for M. S. Degree, California State University, Long Beach, California, 45 pp.
- GROVER, M. C., AND L. A. DEFALCO. 1995. Desert tortoise (*Gopherus agassizii*): Status-of-knowledge outline with references. U.S. Dept. of Agriculture, Forest Service, Intermountain Research Station. General Technical Report INT-GTR-316, Washington, D. C., 134 pp.
- HARDY, R. 1976. The Utah population—A look in the 1970's. In *Proceedings of the Desert Tortoise Council Symposium*, N. J. Engberg, S. Allan, and R. L. Young (eds.), The Desert Tortoise Council, Long Beach, California, pp. 84–88.
- HENEN, B. T. 1997. Seasonal and annual energy and water budgets of female desert tortoises (*Gopherus agassizii*). *Ecology* 78: 283–296.
- , C. C. PETERSON, I. R. WALLIS, K. A. NAGY, AND K. H. BERRY. 1998. Effects of climatic variation on field metabolism and water relations of desert tortoises. *Oecologia* 117: 365–373.
- HOMER, B. L., K. H. BERRY, M. M. CHRISTOPHER, M. B. BROWN, AND E. R. JACOBSON. 1998. Pathology of diseases in wild desert tortoises from California. *Journal of Wildlife Diseases* 34: 508–523.
- JACKSON, C. G., JR., J. A. TROTTER, T. H. TROTTER, AND M. W. TROTTER. 1976. Accelerated growth rate and early maturity in *Gopherus agassizii* (Reptilia: Testudines). *Herpetologica* 32: 139–145.
- JACKSON, O. F. 1980. Weight and measurement data on tortoises (*Testudo graeca* and *Testudo hermanni*) and their relationship to health. *Journal of Small Animal Practice* 21: 409–416.
- . 1987. Signs of ill health. In *Handbook on the maintenance of reptiles in captivity*, K. R. G. Welch (ed.). Robert E. Krieger Publishing Co., Inc., Malabar, Florida, pp. 26–27.
- . 1991. Reptiles, Part One. Chelonians. In *Manual of exotic pets*, P. H. Beynon and J. E. Cooper (eds.). British Small Animal Veterinary Association, Cheltenham, Gloucestershire, UK pp. 221–243.
- JACOBSON, E. R. 1993. Implications of infectious diseases for captive propagation and introduction programs of threatened/endangered reptiles. *Journal of Zoo and Wildlife Medicine* 24: 245–255.
- . 1994a. Causes of mortality and disease in tor-

- toises: A review. *Journal of Zoo and Wildlife Medicine* 25: 2–17.
- . 1994b. Veterinary procedures for the acquisition and release of captive-bred herpetofauna. In *Captive management and conservation of amphibians and reptiles*, J. B. Murphy, K. Adler, and J. T. Collins (eds.). Society for the Study of Amphibians and Reptiles, Ithaca, New York, pp. 109–118.
- , J. M. GASKIN, M. B. BROWN, R. K. HARRIS, C. H. GARDINER, J. L. LAPOINTE, H. P. ADAMS, AND C. REGGIARDO. 1991. Chronic upper respiratory tract disease of free ranging desert tortoises (*Xerobates agassizii*). *Journal of Wildlife Diseases* 27: 296–316.
- , T. J. WRONSKI, J. SCHUMACHER, C. REGGIARDO, AND K. H. BERRY. 1994. Cutaneous dyskeratosis in free-ranging desert tortoises, *Gopherus agassizii*, in the Colorado Desert of Southern California. *Journal of Zoo and Wildlife Medicine* 25: 68–81.
- , M. B. BROWN, I. M. SCHUMACHER, B. R. COLLINS, R. K. HARRIS, AND P. A. KLEIN. 1995. Mycoplasmosis and the desert tortoise (*Gopherus agassizii*) in Las Vegas Valley, Nevada. *Chelonian Conservation and Biology* 1: 279–284.
- , M. WEINSTEIN, K. BERRY, B. HARDENBROOK, C. TOMLINSON, AND D. FREITAS. 1993. Problems with using weight versus carapace length relationships to assess tortoise health. *Veterinary Record* 132: 222–223.
- JOHNSON, T., N. LADEHOFF, C. SCHWALBE, AND B. PALMER. 1990. A summary of the literature on the Sonoran Desert population of the desert tortoise. Arizona Game and Fish Department, Phoenix, Arizona, 63 pp.
- KIRKWOOD, J. K. 1993. Interventions for wildlife health, conservation and welfare. *Veterinary Record* 132: 235–238.
- . 1994. Veterinary education for wildlife conservation, health and welfare. *Veterinary Record* 135: 148–151.
- MADER, D. R. 1996. *Reptile medicine and surgery*. W. B. Saunders Co., Philadelphia, Pennsylvania, 512 pp.
- MAUTINO, M., AND C. D. PAGE. 1993. Biology and medicine of turtles and tortoises. *Veterinary Clinics of North America: Small Animal Practice* 23: 1251–1270.
- MEDICA, P. A., C. L. LYONS, AND F. B. TURNER. 1986. “Tapping”: A technique for capturing tortoises. *Herpetological Review* 17: 15–16.
- NAGY, K. A., AND P. A. MEDICA. 1986. Physiological ecology of desert tortoises in southern Nevada. *Herpetologica* 42: 73–92.
- OETTLE, E. E., Y. G. M. STEYTLER, AND M. C. WILLIAMS. 1990. High mortality in a tortoise colony. *South African Journal of Wildlife Research* 20: 21–25.
- PETERSON, C. C. 1996a. Anhomeostasis: Seasonal water and solute relations in two populations of the desert tortoise (*Gopherus agassizii*) during chronic drought. *Physiological Zoology* 69: 1324–1358.
- . 1996b. Ecological energetics of the desert tortoise (*Gopherus agassizii*): Effects of rainfall and drought. *Ecology* 77: 1831–1844.
- PETNEY, T. N., AND F. AL-YAMAN. 1985. Attachment sites of the tortoise tick *Hyalomma aegyptium* in relation to tick density and physical condition of the host. *The Journal of Parasitology* 71: 287–289.
- RECHAV, Y., AND L. J. FIELDEN. 1995. Seasonal abundance of the tortoise tick *Amblyomma marmoratum* (Acari: Ixodidae) on the leopard tortoise, *Geochelone pardalis*. *Journal of Medical Entomology* 32: 161–165.
- REIDARSON, T. H., C. A. JANTSCH, AND S. M. GENDRON. 1994. Medical treatment for multiple foreign objects in a hawksbill turtle (*Eretmochelys imbricata*). *Journal of Zoo and Wildlife Medicine* 25: 158–160.
- ROSTAL, D. C., V. A. LANCE, J. S. GRUMBLES, AND A. C. ALBERTS. 1994a. Seasonal reproductive cycle of the desert tortoise (*Gopherus agassizii*) in the eastern Mojave Desert. *Herpetological Monographs* 8: 72–82.
- , J. S. GRUMBLES, V. A. LANCE, AND J. R. SPOTILA. 1994b. Non-lethal sexing techniques for hatchling and immature desert tortoises (*Gopherus agassizii*). *Herpetological Monographs* 8: 83–87.
- RUBY, D. E., AND H. A. NIBLICK. 1994. A behavioral inventory of the desert tortoise: Development of an ethogram. *Herpetological Monographs* 8: 88–102.
- , L. C. ZIMMERMAN, S. J. BULOVA, C. J. SALICE, M. P. O’CONNOR, AND J. R. SPOTILA. 1994. Behavioral responses and time allocation differences in desert tortoises exposed to environmental stress in semi-natural enclosures. *Herpetological Monographs* 8: 27–44.
- SCHUMACHER, I. M., M. B. BROWN, E. R. JACOBSON, B. R. COLLINS, AND P. A. KLEIN. 1993. Detection of antibodies to a pathogenic *Mycoplasma* in desert tortoises (*Gopherus agassizii*) with upper respiratory tract disease. *Journal of Clinical Microbiology* 31: 1454–1460.
- SONENSHINE, D. E. 1991. *Biology of Ticks*, Vol. 1. Oxford University Press, New York, New York, 447 pp.
- . 1993. *Biology of Ticks*, Vol. 2. Oxford University Press, New York, New York, 465 pp.
- SPRATT, D. M. J. 1990. “Jackson’s ratio” and the Aldabra giant tortoise (*Geochelone gigantea*). *Veterinary Record* 127: 262–263.
- TURNER, F. B., P. HAYDEN, B. L. BURGE, AND J. B. ROBERSON. 1986. Egg production by the desert tortoise (*Gopherus agassizii*) in California. *Herpetologica* 42: 93–104.

- WALLIS, I. R., B. T. HENEN, AND K. A. NAGY. 1999. Egg size and annual egg production by female desert tortoises (*Gopherus agassizii*): The importance of food abundance, body size, and date of egg shelling. *Journal of Herpetology* 33: 394–408.
- WEST, S. K., AND H. R. TAYLOR. 1990. Reliability of photographs for grading trachoma in field studies. *British Journal of Ophthalmology* 74: 12–13.
- WOBESER, G. 1996. Forensic (medico-legal) necropsy of wildlife. *Journal of Wildlife Diseases* 32: 240–249.
- WOODBURY, A. M., AND R. HARDY. 1948. Studies of the desert tortoise, *Gopherus agassizii*. *Ecological Monographs* 18: 146–200.
- ZIMMERMAN, L. C., M. P. O'CONNOR, S. J. BULOVA, J. R. SPOTILA, S. J. KEMP, AND C. J. SALICE. 1994. Thermal ecology of desert tortoises in the eastern Mojave Desert: Seasonal patterns of operative and body temperatures, and microhabitat utilization. *Herpetological Monographs* 8: 45–59.
- ZUG, G. R. 1991. Age determination in turtles. *Society for Study of Amphibians and Reptiles. Herpetological Circular* 20: 1–28.

Received for publication 4 April 2000.

APPENDIX 1. Supplemental system for grading the beak, nares, eyes, and chin glands of desert tortoises. Instructions: depending on subject, circle one or more options. Rating system: 1 = normal, 2 = mild, 3 = moderate, 4 = severe.

BEAK & NARES			
Site and variables	Presence of moisture	Severity (rate 1–4)	Color and notes
Beak	dry/damp/wet	_____	no foraging evident vs. recent foraging evident (green beak, sap, etc.)
Right Nare	dry/damp/wet	_____	
Left Nare	dry/damp/wet	_____	
Exudate present	no/yes		
Right Nare	none/dried/wet	_____	N = none, C = clear, Co = cloudy W = white, Y = yellow, G = green
Left Nare	none/dried/wet	_____	
Bubble(s) from Nares			
Right Nare	no/yes	_____	
Left Nare	no/yes	_____	
Site	Degree of occlusion of nares		
	Nares occluded		
Right Nare	no/partial/complete		
Left Nare	no/partial/complete		
	Presence of dirt	Amount/Severity (rate 1–4)	
Dirt on beak	no/yes	_____	
Dirt on/in			
Right Nare	no/yes	_____	
Left Nare	no/yes	_____	
EYES: Palpebrae Area, Globe			
Variable	Presence	Severity (rate 1–4)	Location
Condition of Globe			
Right Eye	yes/no	_____	clear/bright/mucus present/dull/cloudy
Left Eye	yes/no	_____	clear/bright/mucus present/dull/cloudy
Other obvious lesions			
Right Eye	yes/no	_____	corneal ulcers/corneal abrasions
Left Eye	yes/no	_____	corneal ulcers/corneal abrasions
Discoloration of globe			
Right Eye	no/yes	_____	Color and location: _____
Left Eye	no/yes	_____	Color and location: _____
Edema of palpebrae			
Right Eye	no/yes/unknown	_____	upper palpebra/lower palpebra
Left Eye	no/yes/unknown	_____	upper palpebra/lower palpebra
Edema of periocular area			
Right Eye	no/yes/unknown	_____	upper periocular area/lower periocular area
Left Eye	no/yes/unknown	_____	upper periocular area/lower periocular area
Discharge from Eye			
Right Eye	none/wet/dried	_____	
Left Eye	none/wet/dried	_____	
Crusts on palpebrae and periocular area			
Right Eye	no/yes	_____	upper palpebra/lower palpebra
Left Eye	no/yes	_____	upper palpebra/lower palpebra
Other lesions of the palpebrae and periocular area			
Right Eye	no/yes	_____	trauma, necrosis: palpebra/periocular area
Left Eye	no/yes	_____	trauma, necrosis: palpebra/periocular area

APPENDIX 1. Continued.

Degree of Closure of Palpebra				
Right Eye	normal (100% open)/partially closed (____ %)			
Left Eye	normal (100% open)/partially closed (____ %)			
Sunken/Recessed Eyes				
Right Eye	no/yes/unknown	_____		
Left Eye	no/yes/unknown	_____		
Eye Swollen or Bulging in Appearance				
Right Eye	no/yes/unknown	_____	dorsal/lateral	
Left Eye	no/yes/unknown	_____	dorsal/lateral	

CHIN GLANDS

Site	Size	Drainage	Severity	Color of Drainage
Right Gland	normal/swollen	present/absent	_____	none/clear/cloudy/white yellow/green
Left Gland	normal/swollen	present/absent	_____	

POSTURE/BEHAVIOR

Behavior appropriate for time of day	yes/no	If no, describe	_____
Behavior appropriate for season	yes/no	If no, describe	_____

FORELIMBS

Right	normal/abnormal	If abnormal, describe:	_____
Left	normal/abnormal	If abnormal, describe:	_____

HINDLIMBS

Right	normal/abnormal	If abnormal, describe:	_____
Left	normal/abnormal	If abnormal, describe:	_____

OTHER

Tail	normal/abnormal	If abnormal, describe:	_____
	normal/abnormal	If abnormal, describe:	_____
